

# **A rare presentation of Scrub Typhus: Multi-Organ Dysfunction [Acute Kidney Injury, Hepatitis] and Acute Respiratory Distress Syndrome**

## **Abstract**

Scrub typhus is an acute febrile illness caused by *Orientia tsutsugamushi*- a gram negative intracellular bacilli. It typically manifests as eschar formation, fever, rash, myalgia and diffuse lymphadenopathy. The clinical severity of scrub typhus ranges from mild fever to a lethal outcome. Complications like sepsis, acute respiratory distress syndrome (ARDS) and multi organ dysfunction syndrome (MODS)--hepatitis, acute kidney injury contribute to the higher mortality rates, which range from 7-30% in untreated cases. Here, we report a case of 35 years old male who presented with complaints of fever, headache, generalised abdominal pain and dry cough for 7 days. The patient was tested positive for Scrub Typhus IgM antibody; and was complicated with MODS- AKI, Hepatitis and ARDS. After extensive intensive care, monitoring and treatment of 15-20 days, the patient recovered. Hence, early diagnosis and prompt treatment aids in decreasing the mortality in such cases.

## **Keywords**

**Orientia tsutsugamushi, scrub typhus, ARDS, MODS**

## **Introduction**

Scrub typhus is a serious public health problem in the "tsutsugamushi triangle" region, which comprises the Asia-Pacific nations and the Indian subcontinent<sup>(1)</sup>. The disease is prevalent in India's Sub-Himalayan region, which extends from Jammu and Kashmir to Nagaland. It is also prevalent in West Bengal, Tamil Nadu, and Kerala<sup>(2,3,4)</sup>. The original name of scrub typhus, which was given by Hashimoto in 1810, is "tsutsugamushi disease"<sup>(5)</sup>. Scrub typhus is a tropical infectious disease caused by *Orientia tsutsugamushi*, a gram-negative, intracellular, obligatory pathogen whose polysaccharides have an antigenic

association with proteus OX-K and are therefore utilised in serologic testing to diagnose scrub typhus<sup>(6)</sup>

Most common presentation includes fever, exanthematous rash, myalgia, headache, gastrointestinal problems, dyspnea, jaundice, and eschar formation. In extreme cases, multiorgan dysfunction syndrome (MODS), meningitis, encephalitis, acute respiratory distress syndrome, acute lung injury (ALI), pre-renal AKI, and myocarditis might occur<sup>(7,8,9,10)</sup>. The severity of renal involvement caused by scrub typhus infection can range from asymptomatic urine abnormalities to renal failure requiring dialysis. Acute arrest of hemopoiesis (AAH) which usually results in pancytopenia, might occur with scrub infection and patients will have a considerable improvement in their blood routine for about a week after receiving supportive care<sup>(11)</sup>. Over the past 20 years, there has been a great deal of variation in the clinical profile, renal involvement, the incidence of multiorgan failure, and mortality among a number of centres in this area. The severity of the disease caused by scrub fever is dependent on the strain of *O. tsutsugamushi* as well as host variables<sup>(12)</sup>. This illness has a high burden of consequences, and case fatality rates without prompt treatment can range from 30 to 70 percent. A serious public health concern is the need for early disease diagnosis and the creation of efficient treatments, controls, and prevention strategies<sup>(13)</sup>.

### **Case presentation**

A 35-year-old male, resident of Madhya Pradesh, farmer by occupation, came to the OPD at Dhiraj Hospital, Vadodara, Gujarat, with complaints of fever with chills and rigors associated with rash [Fig-1], cough with expectoration and headache for 7 days and abdominal pain with vomiting for 3 days. He had no significant past medical, surgical, or familial history of the disease, and he had never consumed alcohol or smoked cigarettes.

The patient was febrile, had a pulse rate of 110/min, a respiratory rate of 16/min, and a blood pressure of 110/60mmHg. Eschar is visible on the umbilicus during physical examination [Fig-2]. All other systemic examination was within normal limits.

Investigations on admission – Patient's on admission report was suggestive of thrombocytopenia, AKI, hepatitis, mild albuminuria, Hypoalbuminemia, hypocalcaemia, hyperphosphatemia and hyperuricemia. Rest other reports were normal.

**Table 1 :Investigations on admission**

Laboratory Data	Results	Reference value
Haemoglobin	12.7	13-17
WBC	9400	4000-11000
Platelet	1.0	1.5-4.5
Urea	160	Oct-52
Creatinine	6	0.6-1.3
Urine Routine Micro	Alb +1, sugar absent, no cast	
RBS	74	70-126
HIV/HCV/HBSAG	Negative	
Sodium/Potassium	134/4.4	135-145/3.5-5.5
Ca/Po4/UA	5.7/6.8/9.0	
T. Bilirubin	8.6	0.2-1.0
CRP	268.8	0-6.0
SGOT	157	Up to 40
SGPT	81	Upto 40
Dengue profile	Negative	
WIDAL	Negative	
P.S. For Malaria	Negative	
Scrub typhus Ig M	Positive	
T. Protein	4.4	
Albumin	2.2	

Inj.Cefepime-Tazobactam, Tab.Doxycycline and other supportive therapy was started for the patient. On the following day, the patient developed minimal basal rales on chest

auscultation which was increased on day 2, along with breathlessness and on the 2<sup>nd</sup> day, patient's saturation dropped and he was shifted to the intensive care unit. Arterial Blood gas analysis (ABG) revealed Type I respiratory failure. Acute respiratory distress syndrome (ARDS) was diagnosed based on bilateral alveolar shadows on a chest radiograph [Fig-3]. The patient was put on continuous Non-invasive positive pressure ventilation for the first 2 days and intermittently for another 3 days during his stay at ICU. During the remaining time, the patient was administered 4-6 litres of oxygen using a face mask. The patient was nebulised with bronchodilators and chest physiotherapy was done. Dialysis was done on 2 consecutive days on the 4<sup>th</sup> and 5<sup>th</sup> day of admission. The blood and sputum culture both were sterile. The final diagnosis of scrub typhus with ARDS was made. On the sixth day, ARDS was cured; there were no abnormalities on the chest radiograph (Fig. 4), and the oxygen requirement was tapered off within a week. Within ten days, the patient's AKI, thrombocytopenia, and abnormal LFT gradually improved, and the patient was discharged.

Investigations on discharge – During the time of discharge, platelet counts returned to normal; AKI and Hepatitis also resolved.

**Table 2 :Investigations on discharge**

<b>Laboratory Data</b>	<b>Results</b>	<b>Reference value</b>
Haemoglobin	10.8	13-17
WBC	7500	4000-11000
Platelet	3.75	1.5-4.5
Creatinine	1.2	0.6-1.3
Sodium/Potassium	141/3.9	135-145/3.5-5.5
T. Bilirubin	1.3	0.2-1.0
SGOT	47	Up to 40
SGPT	61	Up to 40

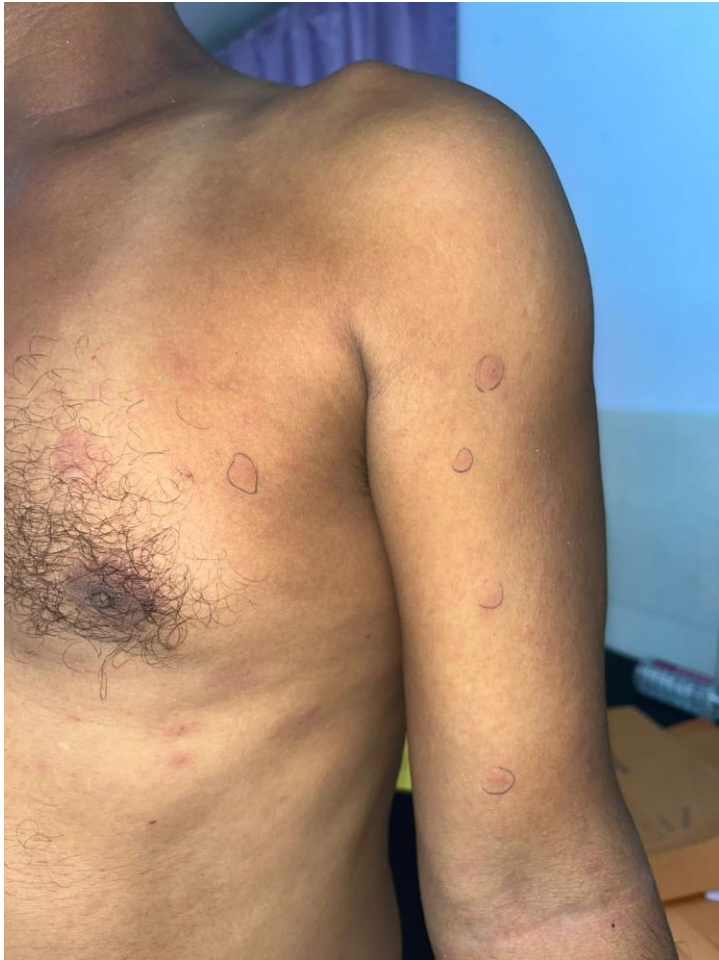

Figure 1 Picture showing rashes in patient of scrub typhus.

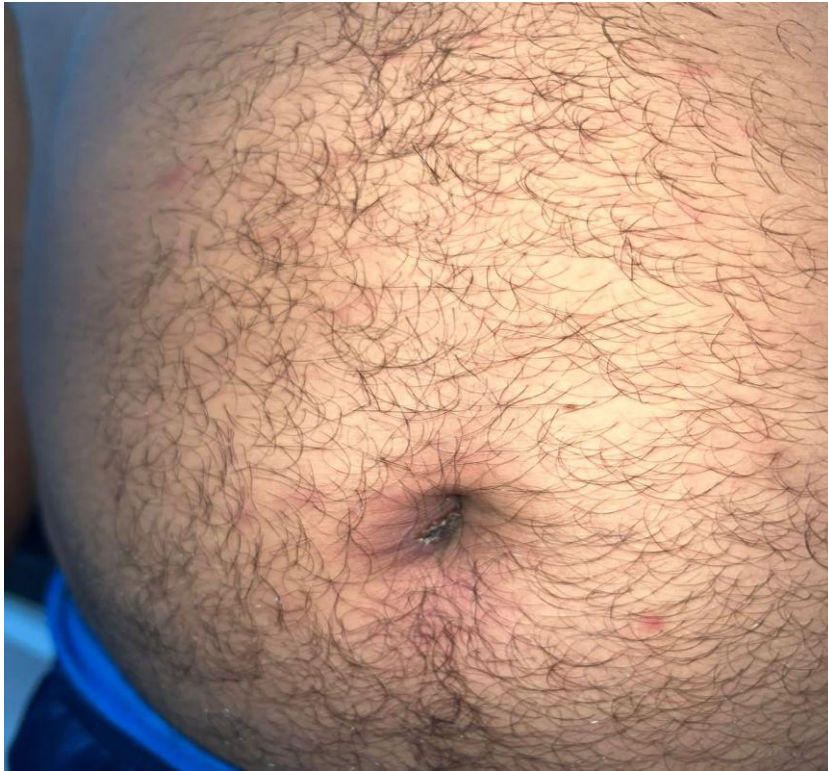

Figure 2 Picture showing eschar on umbilicus – pathognomonic of scrub typhus.

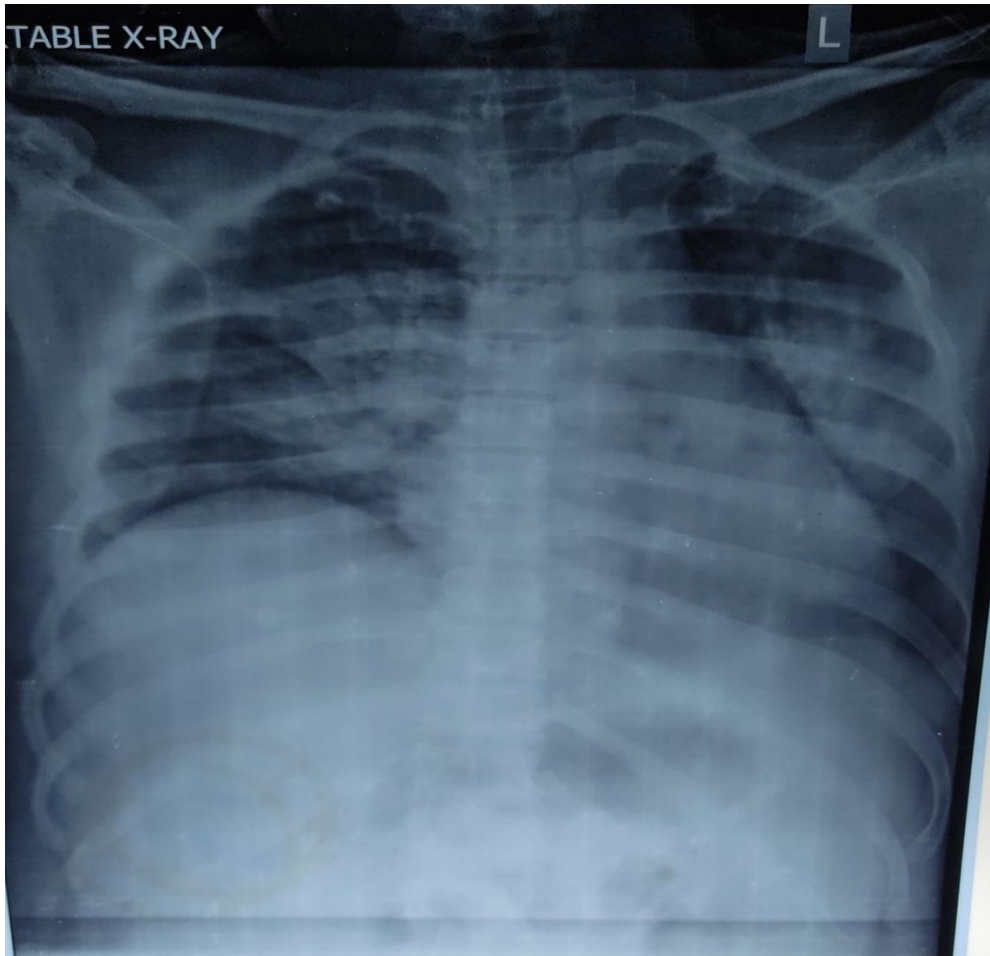


Figure 3 chest radiograph showing acute respiratory distress on the 2nd day.

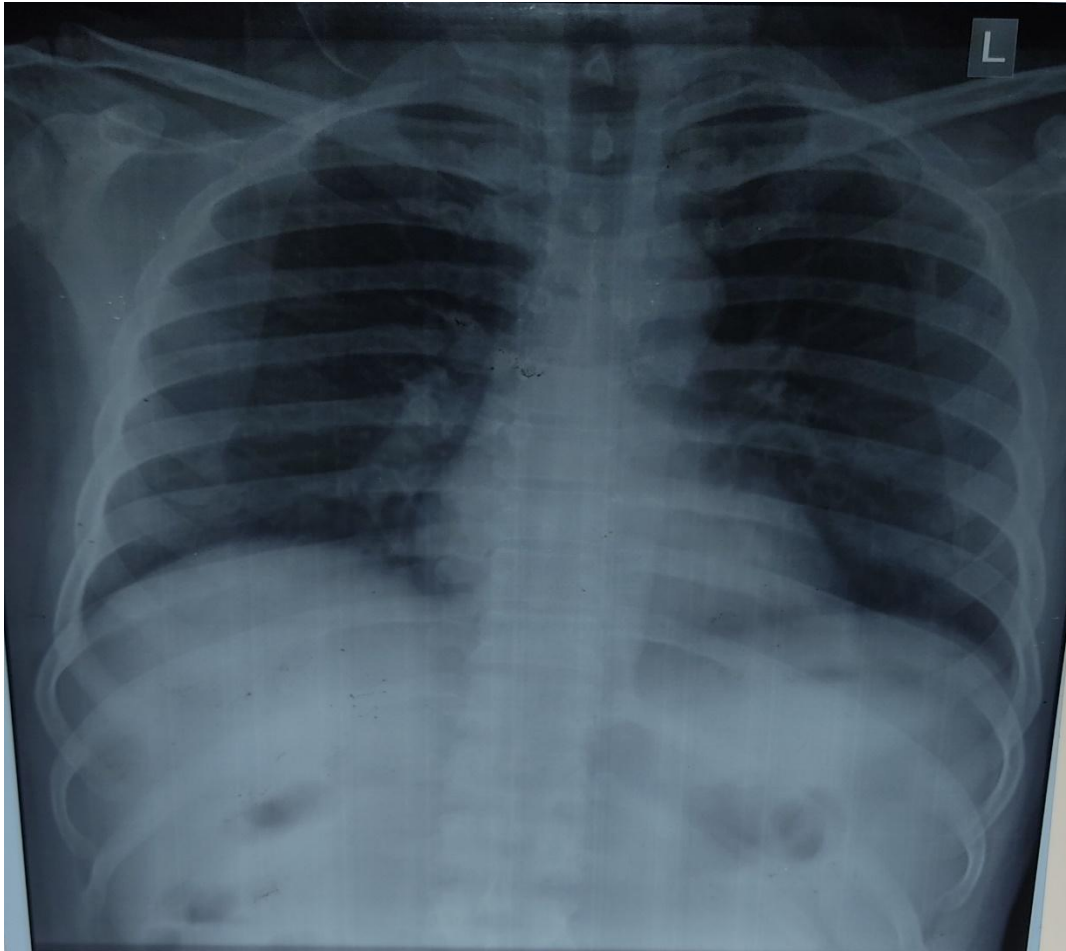


Figure 4 chest radiograph showing no abnormality on discharge.

### **Discussion**

*Orientia tsutsugamushi*, a Gram-negative intracellular bacillus, is the cause of this vector-borne illness called scrub typhus. The larval trombiculid mites, which reside in semi-arid tropical regions with high temperatures and high humidity, are the source of its transmission<sup>(14)</sup>. Scrub typhus is characterized by sudden onset of fever, cough, myalgia, headache, rash, and the development of an eschar<sup>(15)</sup>. All these characteristics were present in the current scenario. The most critical clinical finding for the diagnosis of scrub typhus may be the presence of an eschar<sup>(16)</sup>. Although it is a serious side effect of scrub typhus<sup>(17)</sup>, ARDS is rarely talked about. The most common causes of ARDS include sepsis, aspiration, primary pneumonia, or multiple traumas. It is described as an acute lung inflammation with enhanced vascular permeability<sup>(17)</sup>. Wang et al. conducted case-control research to examine the relationship between ARDS and scrub typhus<sup>(17)</sup>. According to reports, 11% or more of scrub typhus patients went on to develop ARDS. For these ARDS cases, the death rate was

25%. Scrub typhus is frequently linked to jaundice or possibly ALF<sup>(17)</sup>. Encephalopathy or jaundice with a significant rise in liver enzyme values is referred to as ALF<sup>(17)</sup>. Viral hepatitis, malaria, leptospirosis, dengue fever, rickettsial fever, typhoid fever, TB, and amoebic liver abscess are common infectious causes of ALF in India. The causes of AKI and renal involvement in scrub typhus are thought to be multiple. Prerenal failure, septic shock, rhabdomyolysis, vasculitis, acute interstitial nephritis, and direct *O. tsutsugamushi* renal invasion are a few of the potential causes of renal failure<sup>(18,19)</sup>. Doxycycline, chloramphenicol, and azithromycin are some of the antibiotics used to treat scrub typhus. Scrub typhus patients may report to the doctor with the appearance of a common cold or pyrexia of unknown origin because the disease's first clinical symptoms are nonspecific<sup>(20)</sup>. There is a considerable likelihood of early disease misdiagnosis due to the dearth of easily accessible serological diagnostics, particularly in developing nations like India. The likelihood of a missed diagnosis also rises in cases where there is no rash, no characteristic eschar, or where eschar is present on obscure body parts such as the scrotum or axilla. When treating patients with pyrexia of unknown etiology, clinicians should consider scrub typhus as a potential differential diagnosis. If scrub typhus is not treated, it can be dangerous. At the same time, the likelihood of major consequences is decreased by early diagnosis and early treatment. The specificity of the diagnosis is increased when leukocytosis, thrombocytopenia, and elevated serum transaminase are associated<sup>(16)</sup>. Medical professionals' ignorance of this condition could have catastrophic repercussions for the patient. In order to fully understand the pathophysiology, epidemiology, and variety of clinical presentations, diagnoses, and treatments of this lethal disease in India, a further study covering various regions is considered necessary.

## **CONCLUSION**

We are describing this case to emphasize the importance of collecting a comprehensive medical history, performing a clinical examination, and being aware of scrub typhus symptoms such as ARDS, renal failure, and even multiorgan dysfunction. The morbidity and mortality rates are severe in scrub typhus with ARDS. Mortality will be decreased with early detection and treatment. Our patient didn't require invasive ventilation, and non-invasive positive pressure ventilation contributed to a successful outcome.

## Consent

As per international standard or university standard, patient(s) written consent has been collected and preserved by the author(s).

## Ethical Approval:

As per international standard or university standard written ethical approval has been collected and preserved by the author(s).

## Reference

1. Sapkota et al. Acute pancreatitis, shock, and multiple organ dysfunction syndrome in scrub typhus. *Cureus* 2022; 14 (8) : e28233.  
DOI : [10.7759/cureus.28233](https://doi.org/10.7759/cureus.28233)
2. Sivarajan S, Shivalli S, Bhuyan D, Mawlong M, Barman R. Clinical and paraclinical profile, and predictors of outcome in 90 cases of scrub typhus, Meghalaya, India. *Infect Dis Poverty*. 2016;5:91.
3. Walker DH, Dumler S, Marrie T. 211: Rickettsial Diseases. In: Longo DL, Kasper DL, Jameson JL, Fauci AS, Hauser SL, Loscalzo J, et al., (eds.). *Harrison's principles of internal medicine*. 19th ed. New York:McGraw Hill; 2015, pp: 1154-1162.
4. Bhargava A, Kaushik R, Kaushik RM, Sharma A, Ahmad S, Dhar M, et al. Scrub typhus in Uttarakhand & adjoining Uttar Pradesh: Seasonality, clinical presentations & predictors of mortality. *Indian J Med Res*. 2016;144:901–909.
5. Li et al. Scrub typhus with multi-organ dysfunction syndrome and immune thrombocytopenia : a case report and review of the literature. *Journal of Medical Case Reports* 2019; 13 : 358. DOI : <https://doi.org/10.1186/s13256-019-2299-x>
6. Singh et al. Clinical profile of scrub typhus patients during COVID pandemic : a sub-Himalayan single center experience. medRxiv preprint DOI : <https://doi.org/10.1101/2022.08.20.22279010>
7. Kumar V, Kumar V, Yadav AK, et al. Scrub typhus is an under-recognized cause of acute febrile illness with acute kidney injury in India. *PLoS Negl Trop Dis* 2014;8:e2605.
8. Basu G, Chrispal A, Boorugu H, et al. Acute kidney injury in tropical acute febrile illness in a tertiary care centre – RIFLE criteria validation. *Nephrol Dial Transplant* 2011;26:524- 31.
9. Varghese GM, Trowbridge P, Janardhanan J, et al. Clinical profile and improving mortality trend of scrub typhus in South India. *Int J Infect Dis* 2014;23:39-43.
10. Sedhain A, Bhattarai GR. Renal manifestation in scrub typhus during a major outbreak in central Nepal. *Indian J Nephrol* 2017;27:440-5
11. Song et al. A case report of scrub typhus : secondary acute arrest of hemopoiesis with multiple organ dysfunction syndromes. *Open Journal of Blood Diseases* 2022; 12 : 53-59.DOI : <https://doi.org/10.4236/ojbd.2022.123006>
12. Mahajan et al. Spectrum of multiorgan dysfunction in scrub typhus infection. *Journal of Tropical Pediatrics* 2021; 67 (4) : 1-9.DOI : [10.1093/tropej/jmab074](https://doi.org/10.1093/tropej/jmab074)
13. Bonell A, Lubell Y, Newton PN, Crump JA, Paris DH. Estimating the burden of scrub typhus: A systematic review. *PLoS Negl Trop Dis*. 2017;11:e0005838.

14. Raoult D. Scrub typhus. In: Mandell GL, Douglas RG, Bennett JE, Dolin R, editors. Mandell, Douglas, and Bennett's Principles and Practice of Infectious Diseases. 6th ed. Philadelphia, PA: Elsevier/Churchill Livingstone; 2005. p. 2309-10.
15. Sayen J, Pond H, Forrester J. Scrub typhus in Assam and Burma: a clinical study of 616 cases. *Medicine* 1946;25:155–214.
16. Chogle AR. Diagnosis and treatment of scrub typhus—the Indian scenario. *J Assoc Physicians India* 2010;58:11–2
17. Wang CC, Liu SF, Liu JW, Chung YH, Su MC, Lin MC. Acute respiratory distress syndrome (ARDS) in scrub typhus. *Am J Trop Med Hyg* 2007;76:1148–52.
18. Lee S, Kang KP, Kim W, Kang SK, Lee HB, Park SK. A case of acute renal failure, rhabdo- myolysis and disseminated intravascular coa- gulation associated with scrub typhus. *Clin Nephrol* 2003;60:59-61.
19. Kim DM, Kang DW, Kim JO, et al. Acute renal failure due to acute tubular necrosis caused by direct invasion of *Orientia tsutsugamushi*. *J Clin Microbiol* 2008;46: 1548-50.
20. Lee WS, Wang FD, Wang LS, Wong WW, Young D, Fung CP, et al. Scrub typhus complicating acute respiratory distress syndrome: a report of two cases. *Zhonghua Yi Xue Za Zhi* 1995;56:205–10.

#### **Abbreviations**

**MODS – Multi Organ Dysfunction Syndrome**

**ARDS – Acute Respiratory Distress Syndrome**

**AKI – Acute Kidney Injury**

**LFT – Liver Function Tests**

**ALF – Acute Liver Failure**