

# Comparative anatomical study on the hand of some mammalian species and human

## ABSTRACT

**Background:** Morphologically there is a great similarity in the musculoskeletal pattern in different species of the primates especially the development of hands and digits for better functional adaptation to their environment. The factors involved in evolution of modern hand are muscle-tendon architecture, shape, size of bones and articular surfaces in joints. Human hand is functionally highly evolved with manipulative potential for fast and fine skilled activity especially in thumb and index finger as compared with other species.

**Aim:** Present study was undertaken to compare the hand anatomy of the Baboon and Squirrel with the Human.

**Methods:** Two commonly found mammals in Saudi Arabia i.e. Baboon and Squirrel were selected to reflect the different environmental adaptations. The human hands were provided by the Department of Anatomy. The animals were anesthetized, sacrificed at Anesthesia Department. Fixation done by 9% formaldehyde solution, hands dissected under Zeiss dissecting microscope, Muscle groups identified using 5% iodine stain, Bones and cartilages stained by Alizarin red and Alcian blue stain respectively and photographed (Nikon D3200 digital camera). The hand divided into four parts: Wrist, dorsum of hand, palm and fingers.

**Results: Human Hand:** Wrist is wide, bones arranged in two rows gliding over each other for free movements at hand. Dorsum has thin fatty layer, more wrinkles and fewer hairs. Palm has thick skin without hair and well-developed muscles are arranged in groups (Thenar, Hypothenar, Lumbricals and Interossei). Digits have extensor and flexor tendons up to middle and distal phalanx. Thumb is rotated providing opposition and multiaxial movements. **Baboon Hand:** Wrist is short, bones arranged in two rows but fewer movements at hand. Dorsum has fewer wrinkles, more hairs. Palm skin has very thick layer, especially at friction pad located below fingers; muscles are arranged in groups but not fully developed as compared to human. **Squirrel Hand:** Small and close dimensions, five short fingers, pointed, every finger ends with a claw. The skin is thin, covered with hair. Palm is thin but completely free of hair with digital pad. Phalanges are short and all fingers have two phalanges. Thumb has only one phalanx.

**Conclusions:** Human hand structure is evolved for better grip and fine movements of hand providing better functional and artistic capabilities.

**Keywords:** Baboon, Squirrel, Thumb, Wrist, Palm.

## INTRODUCTION

The functional anatomy of the hand has been previously studied (Panchal-Kildare & Malone, 2013; Aversi-Ferreira *et al.*, 2016; Kerkhof *et al.*, 2016; Selby *et al.*, 2016 and Leeuwen *et al.*, 2018). Some investigators reported that the morphology of muscle attachment sites in the human hand does not reflect muscle architecture (Williams-Hatala *et al.*, 2016). In contrast, Meguerditchian *et al.* (2015) showed that the functional anatomy of the hand of primates including human reflects grip precision and manipulation potential especially in the thumb and index finger. They investigated the effect on grip morphology and compared hand use for a bimanual coordinated task in great apes. They showed that gripping by the thumb and index finger was significantly higher in the right hand compared to the left hand.

One of the distinctive features of primates is the development of hands and digits – such a development is necessary to adapt to their environment. Meguerditchian *et al.* (2015) showed that the strength of muscle contraction in the hand of the Bonobo was comparable to that of the human hand except that of the thinner muscles which were more proficient in the human. Molnar *et al.* (2017) demonstrated a great similarity in the musculoskeletal structural pattern in twenty-two species of primates. Moreover, they showed that the human thumb was highly developed as compared with other species. In an analytical study, Popplewell *et al.* (2017) indicated that the finger pad forces and friction using finger nail mounted strain gauges in the human thumb and index finger were highly than those in remaining fingers.

It has been mentioned that the contractions of the external and internal muscles of the thumb were necessary to maintain different patterns of activities during functional tasks of daily life (Kerkhof *et al.*, 2016).

Huang *et al.* (2013) described the intimate relation of muscle, tendon and bone during joint movement. They demonstrated that tendon attachment and muscle activity enabled active relocation of functional myofibers. Adams *et al.* (2012) indicated that various factors are involved in grip function. Similarly, Diogo *et al.* (2012) indicated that coordinated thumb movements have a role in the evaluation of modern thumbs.

The difference in bending of articular surfaces and ligament sites has been investigated. Thorington & Darrow (2000) reported that in the squirrels there is a joint between pisiform, scaphoid and lunate which provided a more stable base for cartilage formation. The differences in bending at articular surfaces and ligament sites are also associated with the differences in the degree and type of movement in the joint.

In the light of this, the present study was undertaken to study the anatomy of the hands of Baboon and Squirrel, and to compare these hands structures with that of the human hand.

## **MATERIALS AND METHODS**

### **Animals:**

Two mammalian species were selected in the present study, namely the Baboon and Squirrel. They are found in Saudi Arabia; the former was obtained from Taif city, while the latter obtained from the Hafoof city. These two species were selected to reflect the different environmental adaptations. The human hands were provided by the Department of Anatomy, College of Medicine, Imam Abdulrahman bin Faisal University (IAU).

## **Anesthesia:**

The animals were anesthetized using Hydromorphene (oxymorphone, morphine, or fentanyl) based on the availability of the anesthetic provided by the Department of Anesthesia, College of Medicine, IAU. The dosage varied according to the type of anesthetic used as follows: 0.05 to 0.10 mg/kg for oxymorphone, 0.05 to 1.0 mg/kg for morphine, and 0.005 to 0.01 mg/kg for fentanyl. The anesthetic was administered via intramuscular injections carried out by a staff member from Anesthesia Department.

The animals were sacrificed following injection and perfusion of 9% formaldehygole solution. Following fixation, the hands were amputated and placed in formaldehyde fixative solution. The rest of the body was immersed in the fixative for picture use by other investigators. The animals were handled during acquisition, feeding, anesthesia, sacrifice, dissection, and disposal of residences in accordance with the standards and Regulations of the IAU ethics of Scientific Research. The hands were dissected under Zeiss dissecting microscope and photographed with a Nikon D3200 digital camera.

**Classification of research animals:** Based on Macdonald (2007)

<b>Systematic rank</b>	<b>Baboon</b>	<b>Squirrel</b>
<b>Kingdom</b>	Animalia	Animalia
<b>Subkingdom</b>	Metazoa	Metazoa
<b>Phylum</b>	Chordata	Chordata
<b>Subphylum</b>	Vertebrata	Vertebrata
<b>Superclass</b>	Gnathostomata	Gnathostomata
<b>Class</b>	Mammalia	Mammalia
<b>Subclass</b>	Eutheria	Eutheria
<b>Order</b>	Primates	Rodentia
<b>Family</b>	Cercopithecidae	Sciuridae
<b>Scientific name</b>	<i>Papio hamadryas</i> (Fig. 1)	<i>Tamias striatus</i> (Fig.2)



## **Procedure of the work:**

The animals were anesthetized using one of the following drugs: Hydromorphone (Oxymorphone, Morphine, Fentanyl) according to the materials available in the Anesthesiology Department at the Faculty of Medicine, during the anesthesia procedure (0.10 to 0.20 mg/kg).

The different muscle groups were identified using 5% iodine stain, and then the parts were visualized by Camera Lucida Bock (2001). For the internal structures of hand bones (phalanges,

metacarpals and carpals), alizarin red stain for bone staining and Alcian blue stain for cartilage were used. The fixation process is first performed in 10% formalized formaldehyde solution for at least 24 hours. Then it washed by installing the sample in distilled water to remove the used initial fixation solution. The fixation is then repeated using 70% ethanol and the sample is left in this solution for a long period of time. The sample skin is then carefully machined for dyeing. For bone dyeing, the sample was transferred to 0.05% of water potassium hydroxide and red alizarin's dye is added in powder until the solution becomes dark purple. Leave the sample in this solution for 36 hours. Then, dehydration of the sample was carried out for 48 hours. Finally, permanent storage is carried out by transferring the sample in pure glycerol. For cartilage staining, the cartilage of the hand structure was stained by 0.02% of the ethylene blue prepared in ethanol and acetic acid for two days. Then it washed in 70% ethanol and 30% acetic acid, then soaked in absolute ethanol and treated with distilled water for two or three days **Salaramoli et al., (2015)**.

## RESULTS

### 1. Human hand:

The hand divided into four parts: finger, palm, the dorsum of the hand and wrist. Fingers are extensions of the hand (palm of hand), these fingers enable the human to pick up the smallest things. There are 5 fingers in hand; they are thumb, index finger, middle finger, ring finger and small finger. Each finger ends from the dorsal side with a nail (**Fig. 3**). The appearance of the hand (visible palm) is the back part of the hand that shows the wrinkles. The wrist is the point of contact between the arm and the hand, which gives the hand its ability to move. The skin that covers the appearance of the hand is very different form. This skin is thin, flexible and contains a lot of wrinkles and a little hair. While, the skin of the palm surface of the hand is thick, free of hair and this feature gives the skin stability to accommodate the function of strong hand grip (**Figs. 4 & 5**).

When removing the surface layers of visible skin of the hand, the fatty layer scattered around the hand and fingers, as well as the tendons of the hand were appeared (**Fig. 6**). The tendons gradually begin to appear when the fat layer is removed as tendon of extensor indices and tendon of extensor digiti minimi (**Fig. 7**). A group of flexor tendons was observed such as extensor digitum muscle tendon, extensor pollicis brevis tendon of extensor pollicis longus muscle. There is a connection known as the inter-tendon's connection, and the first dorsal interosseous muscle was appeared (**Fig.8**).

After dissecting of hand palm, a group of individual small muscles in the hand was observed, in addition to tendons muscles of the forearm which works together to provide flexible and precise movements that are essential to the activities and tasks performed by the hand. These are: thenar muscle (located at the base of the thumb), hypothenar muscle (located next to the small of the palm) and intermediate muscle (located in the center of the hand). The muscles of the prominence forming a bulge of muscles in the base of the thumb, they are necessary to give the thumb its ability to move in front of the rest fingers. Abductor pollicis brevis muscle which works opposite the abductor digiti minimi muscle which is located on the limit ulnar stop hand it arises from the bone pisiform and the tendon ulnar bent of the wrist and ends with flat tendon which divides into two parts: the first is located on the limit ulnar of peritoneum (**Fig. 9**).

When gradually remove layers, especially around the fingers, the fibrous digital sheath and tendons of flexor digitorum superficial muscles are seen, and at the end of the finger from the bottom there are lumbrical muscles which consists of four small bundles (**Fig. 10**). Associated with these packages stromal with deep tendons of the flexor of the fingers, the first and second arises from the radial side and rest stop tendons index finger and middle respectively. While the third package arises from the lateral neighboring tendons package central and ring in steps, and finally the fourth package arising from the two sides adjoining tendons for the ring and pinkie fingers. With the continuation of anatomy we observe the emergence what is known as the pre-tendinous band as well as flexor tendon especially at the ring finger (**Fig. 11**). Next to the flexor tendon there is the proximal transverse, but near the wrist there is a group of flexor tendons of the fingers (**Fig. 12**). On the stretch of the flexor tendons down on the forearm there is a palmaris longus tendon (**Fig. 13**). Muscles prominence is a small swelling of the muscles in the medial side of the palm of the hand opposite to muscles prominence palmer, these muscles work together to give the extent of the movement top to the small finger. The presence of the opponens pollicis muscle which originate from the proximal bone and the opponens digiti minimi muscle which arise from the convexity of the hamate bone and adjacent to the mooring of the carpal browser, the finger was allowed to catch the finer things (**Fig.14**).

The hand contains 27 bones which give a hand precision in motion, such as the carpals which give the hand flexibility and support; metacarpals which are long, thin, stretching from the wrist to each finger (thumb, index finger, middle finger, small finger). Phalanges, each finger contain three phalanges except the thumb which contains only two shorter phalanges. Phalanges are rectangular in shape and finite with the bones of metacarpals articulates at the finger base known as the proximal phalanx and the phalanges at the end of each finger is known as the distal phalanx, Middle phalanx exist between the nearby phalanges and the distant phalanx (**Fig. 15**). The bones that form the wrist are flexible and consists of eight arranged bones in two rows each of four bones, the near row consists of the scaphoid, lunate, triquetrum and pisiform, the long row consist of the trapezium, trapezoid, hamate and capitate (**Fig. 16**).

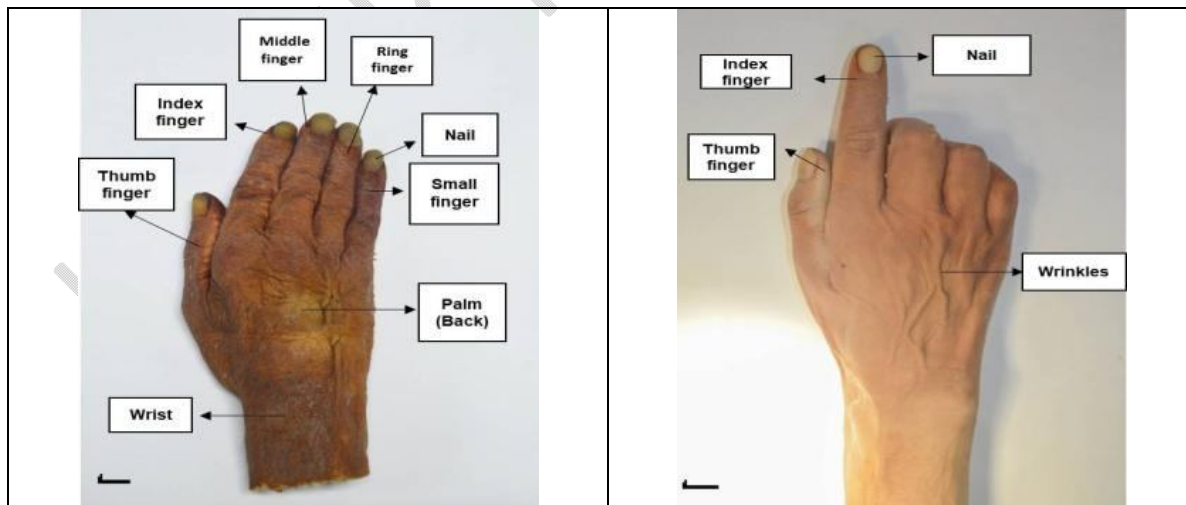


Figure (3): Dorsal view of human hand showing that hand contains five different fingers.

Figure (4): Dorsal view of human hand showing index finger, thumb and wrinkles on hand.

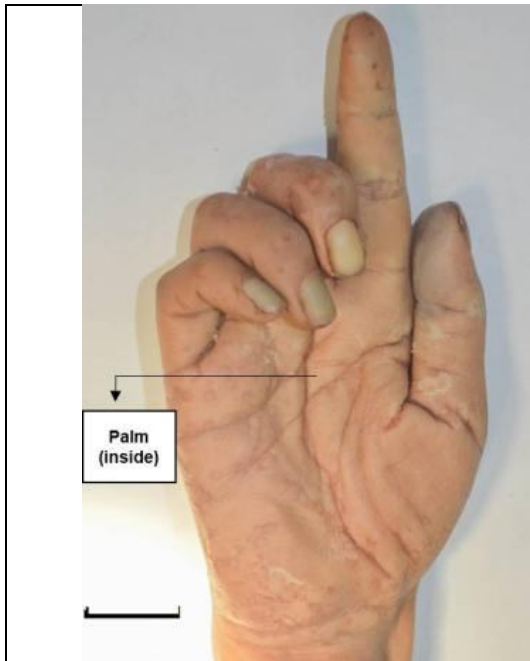


Figure (5): Ventral view of human hand showing hand palm.

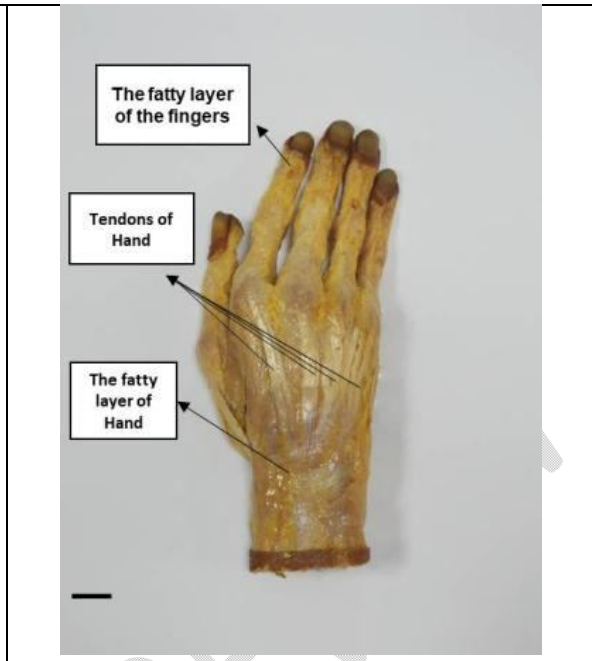


Figure (6): Dorsal view of human hand showing fatty layer of hand and fingers and tendons.

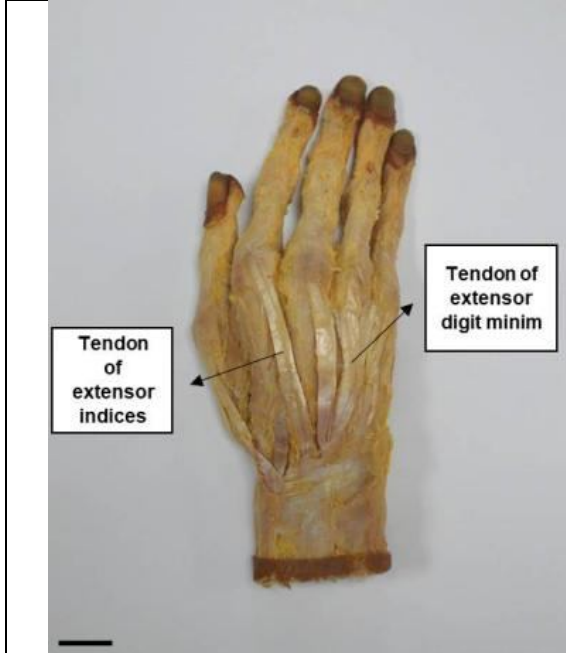


Figure (7): Dorsal view of human hand showing different dorsal tendons.

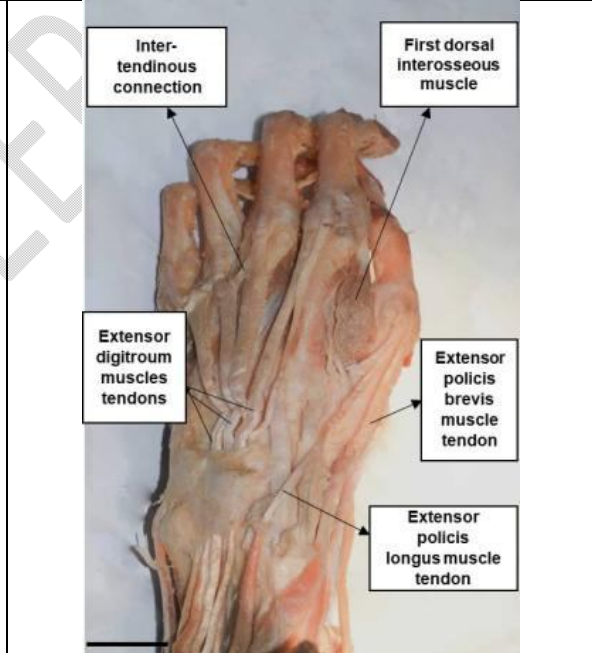


Figure (8): Dorsal view of human hand showing connection between tendons and different muscles of the hand.

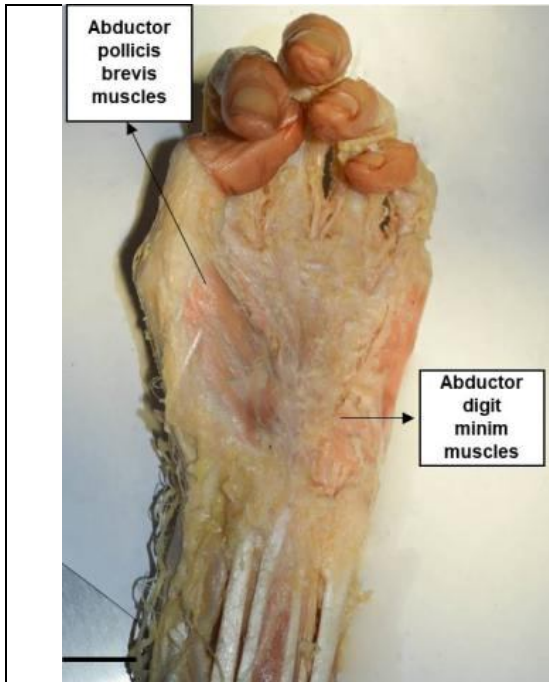


Figure (9): Ventral view of human hand showing abductor digiti minimi muscles.

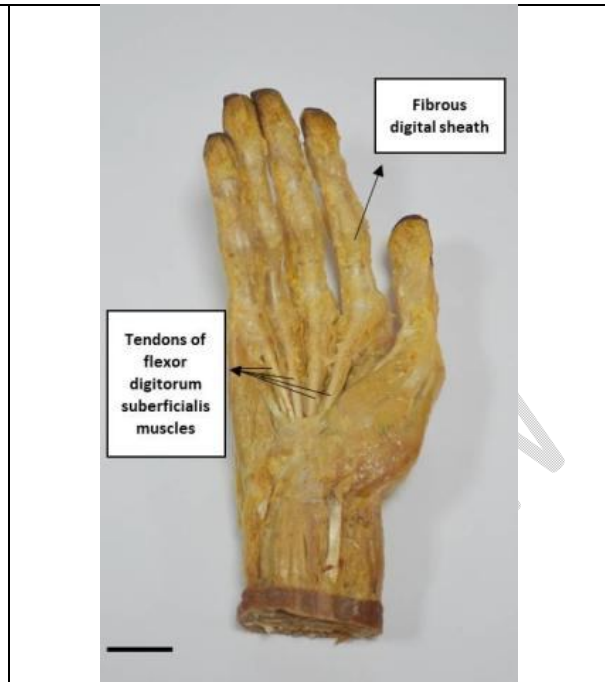

Figure (10): Ventral view of human hand showing fibrous digital sheath, tendons of flexor digitorum superficialis and lumbrical muscles.

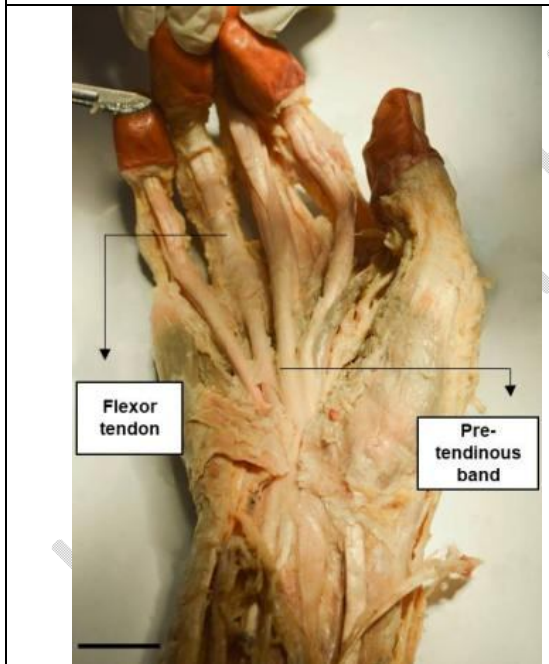


Figure (11): Ventral view of human hand showing flexor tendon and pre-tendinous band.

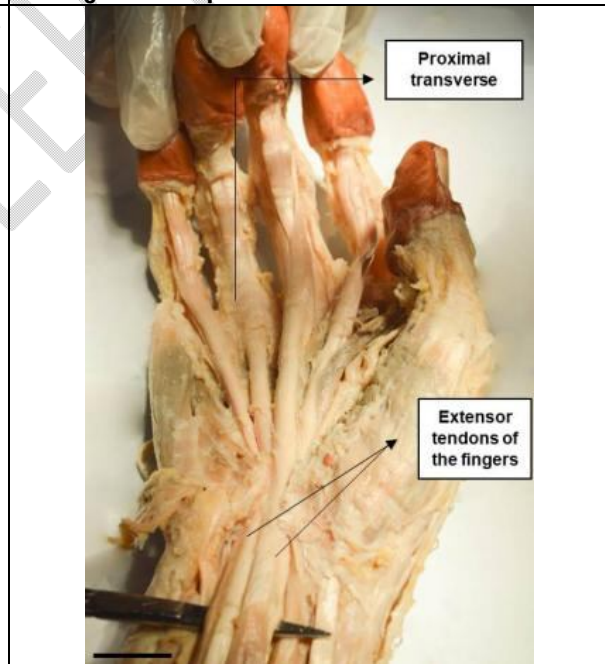


Figure (12): Ventral view of human hand showing proximal transverse and Flexor tendons of fingers.

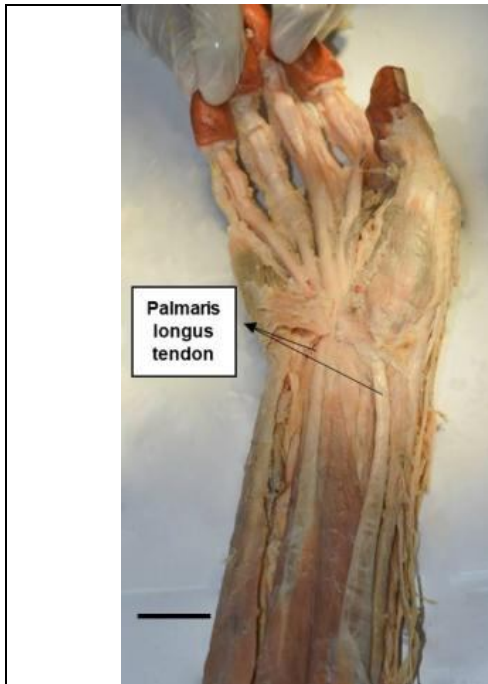


Figure (13): Ventral view of human hand showing palmaris longus tendon.

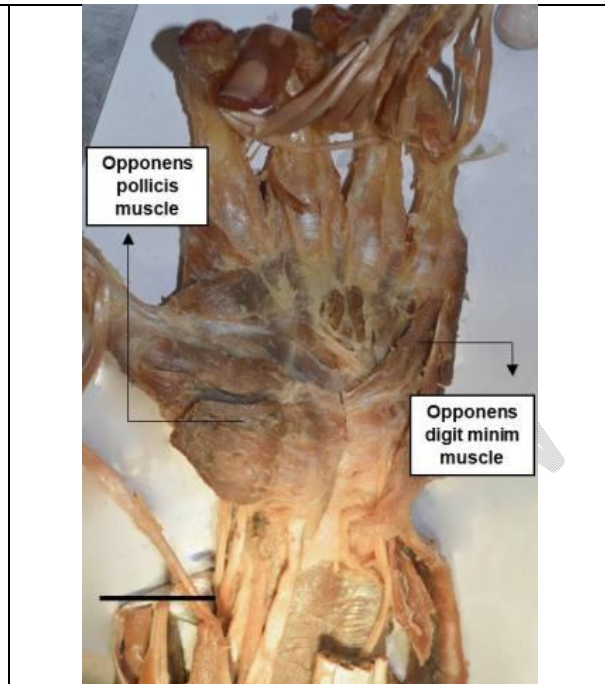


Figure (14): Dorsal view of human hand showing opponens pollicis and digiti minimi muscles.

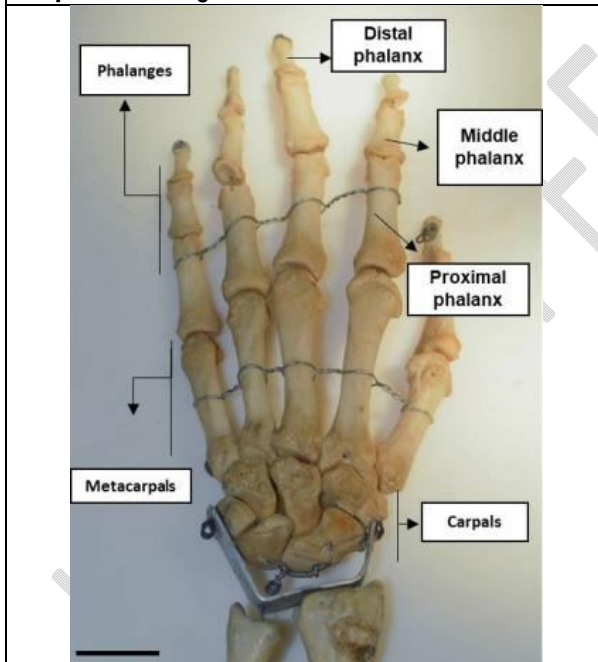


Figure (15): Dorsal view of human hand showing different phalanges, metacarpals and carpals.

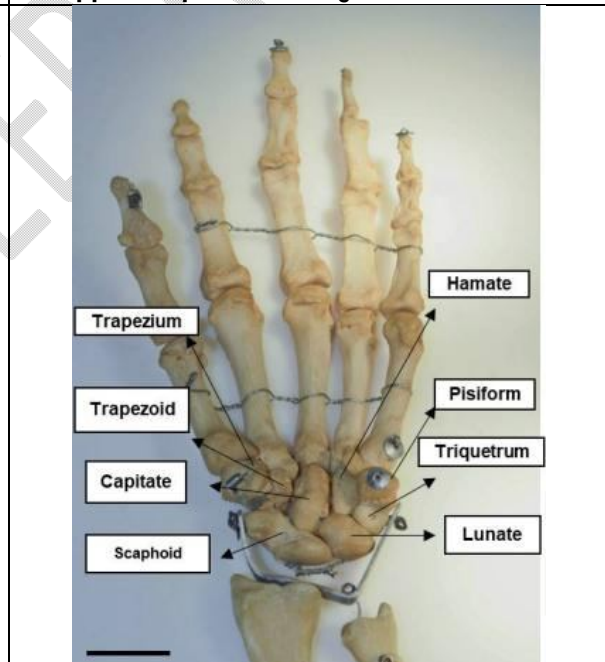


Figure (16): Dorsal view of human hand showing different hand carpals.

## **2. Baboon hand:**

Hand of monkey divided into four main parts fingers, palm, the dorsum of hand and wrist which represents the point of contract between arm and hand. Five fingers are drawn from the palm of the hand close to the length, its thumb finger short and pointed shape, index finger, middle finger, ring finger and small finger. From dorsal, each finger ends with very thick nail. Skin of the hand is characterized by a thick layer of hair and less wrinkles at the fingertips and finally the short wrist; it is the contact point between arm and hand (**Fig. 17**).

The palm of the hand of baboon is characterized by a very thick layer of skin, especially in the area of friction pad located below the fingers and covering most of the palm area (**Fig. 18**). After removing the surface layer of the skin of the baboon's hand, a very thin fatty layer has been highlighted between hand finger and near the wrist which is called the fatty layer of fingers and hand (**Fig. 19**). Tendons are also appeared, such as tendon of extensor digit minim, the tendon of extensor indices, tendon of extensor policies brevis (**Fig. 20**).

As the autopsy continues, a series of extensor muscle tendons is shown to the fingers known as extensor digitum muscles tendons, extensor policies brevis muscle, and extensor policies longus muscle. The presence of short communication between the tendons (inter-tendinous connection) is noticed (**Fig. 21**). After removal of the tendons covering the wrist, simple muscles are observed between the bones (interosseous muscles); the opponents digit minim muscle is also appeared (**Fig. 22**). After removing all the tendons and skin follicle of the hand, the structure of the hand is appeared and the membrane covering the fingers joint which is known capsule s of finger joints (**Fig. 23**). After directly dissecting the hand palm, a dense fatty layer is observed under the skin (the fatty layer of the palm) (**Fig. 24**); and the palm tendons began to appear (tendons of flexor digitorum superficialis muscle). Also, the fibrous digital sheath is appeared. It is thin and is located above the fingers joints (**Fig. 25**). The pre-tendinous bond is observed at the tendons ending of the hand palm, and the flexor tendon is located at the extension of the fingers towards the palm of the hand (**Fig. 26**); palmaris longus tendon and extensor tendon of the fingers are also observed, which extend towards the forearm (**Fig. 27**).

Under the tendon layer, the muscle layer looks exactly like abductor policies brevis muscle and abductor digit minim muscle (**Fig. 28**). After removal of the tendons from the hand palm, the adductor pollicis muscles were observed on its sides they are opponens pollicis muscle and the opponens digit minim muscle (**Fig. 29**).

After removing all the muscles and tissues covering the hand, some parts of hand skeleton are appeared (**Fig. 30**). The phalanges and metacarpals are appeared with staining by alizarin red stain and alcian blue stain (**Figs. 31 & 33**). Because of the lack of clarity in the structural parts of the dyed hand, the hand was simply diagrammed to highlight the proximal phalanx, middle and distal phalanges for all the fingers except the thumb which contains only two phalanges. Hand metacarpals are five elongated and extended to the five fingers of the hand. The hand carpals are the scaphoid (it is the largest bone of the wrist and the first hand thumb), the lunate (a second hand thumb), triquetrum (it is the third of the hand thumb), pisiform (the last of the hand thumb), trapezium (it is connected to metacarpal bone and it is the first hand bones of the second row), trapezoid (from the side of the thumb) capitate and hamate which represent the last bones in the second row of the thumb (**Figs. 32 & 34**).

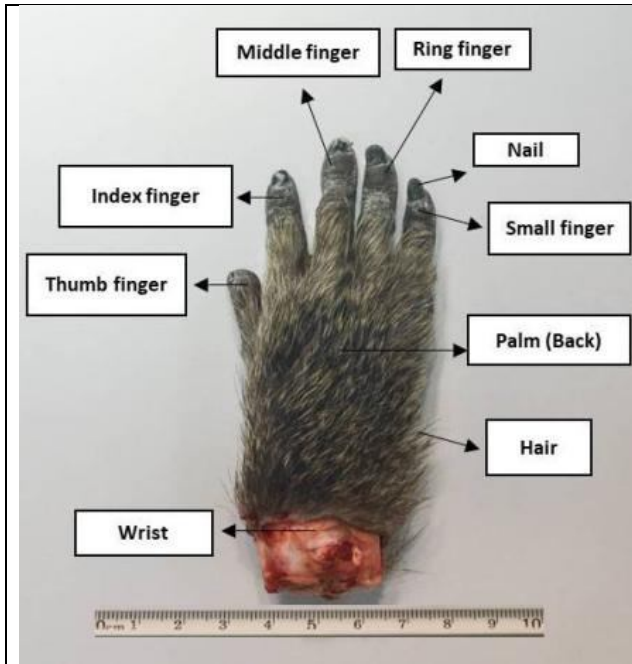


Figure (17): Dorsal view of Baboon hand showing fingers having different lengths.

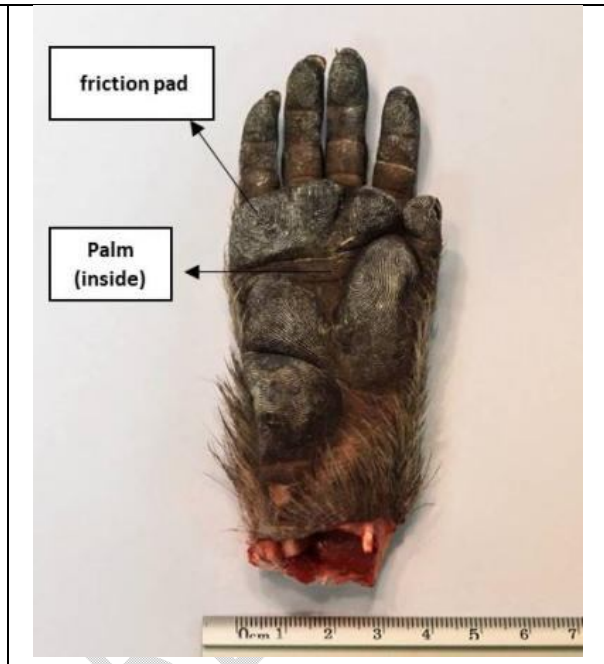


Figure (18): Ventral view of Baboon hand showing friction pad and hand palm.

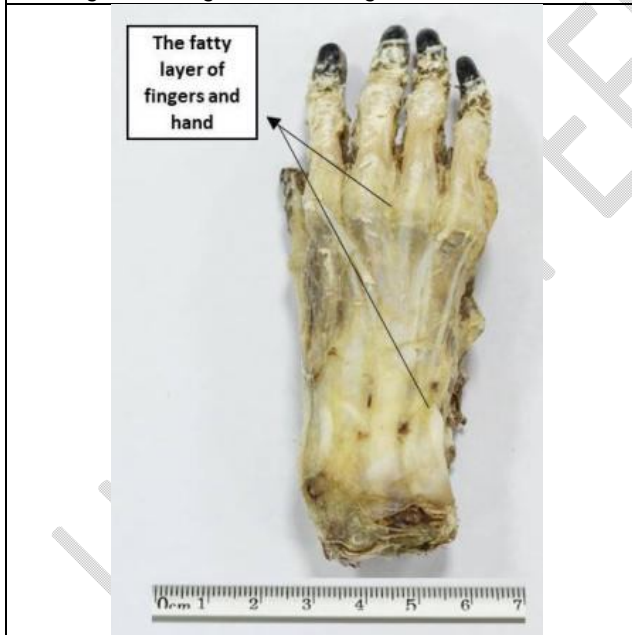

Figure (19): Dorsal view of Baboon hand Showing the fatty layer of fingers and hand.

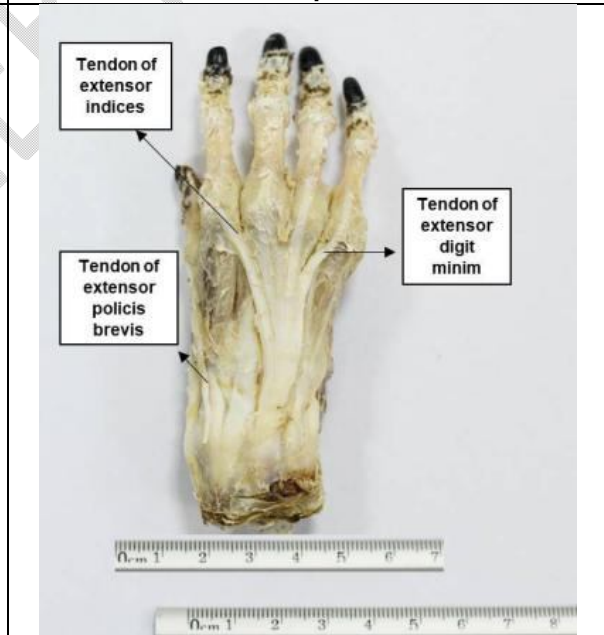


Figure (20): Dorsal view of Baboon Hand Showing the tendon of extensor indices, tendon of extensor pollicis brevis.

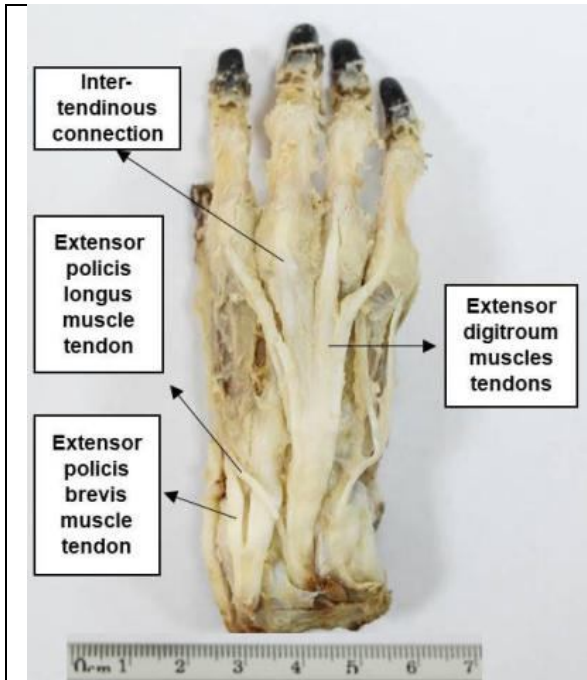


Figure (21): Dorsal view of Baboon hand showing the inter-tendinous connection and different muscle tendons.

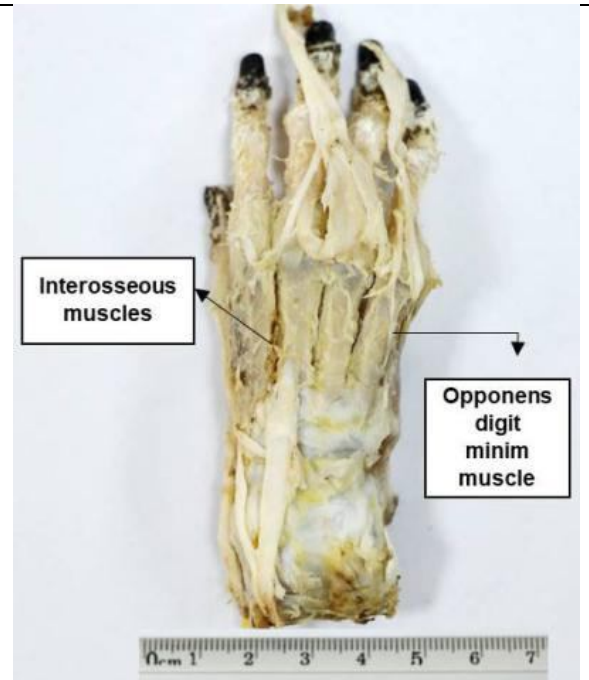


Figure (22): Dorsal view of baboon hand showing the interosseous and opponens digiti minimi muscles.

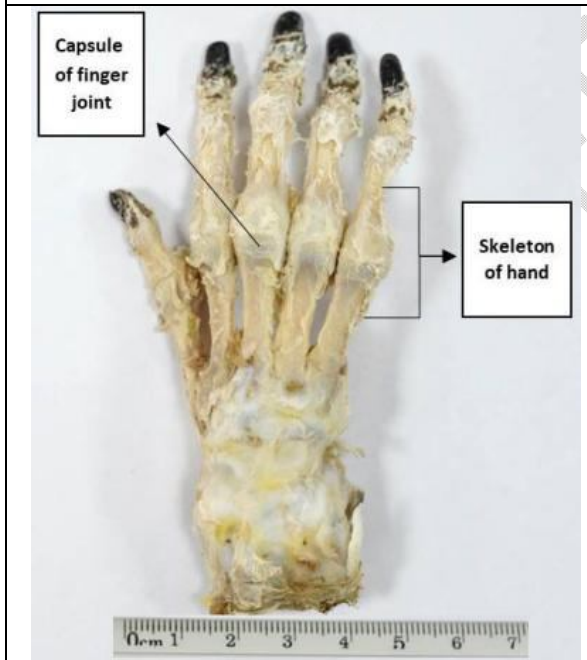


Figure (23): Dorsal view of Baboon hand showing capsule finger joint and skeleton of hand.

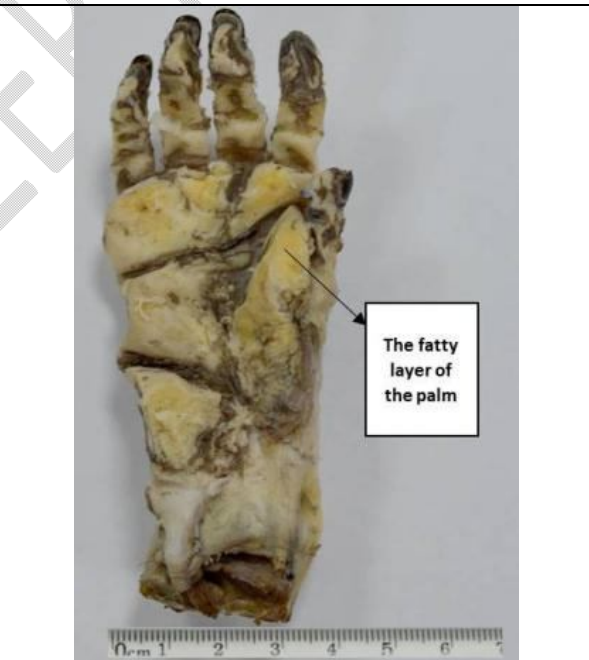

Figure (24): Ventral view of Baboon hand showing fatty layer of the palm.

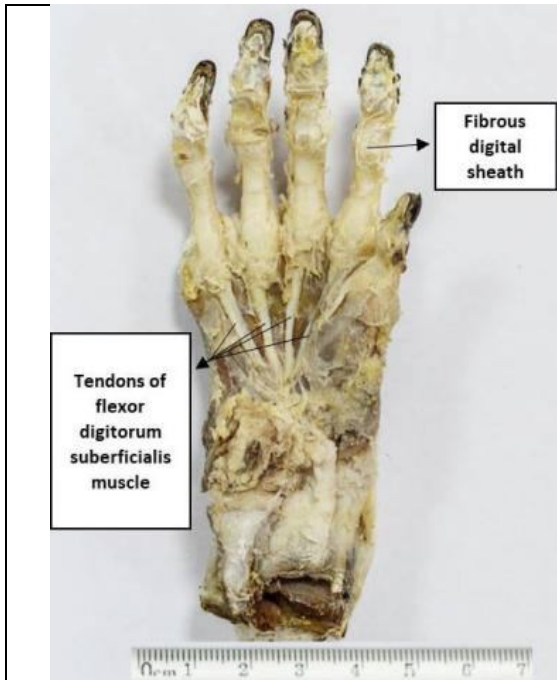


Figure (25): Ventral view of Baboon hand showing fibrous digital sheath and tendons of muscle.

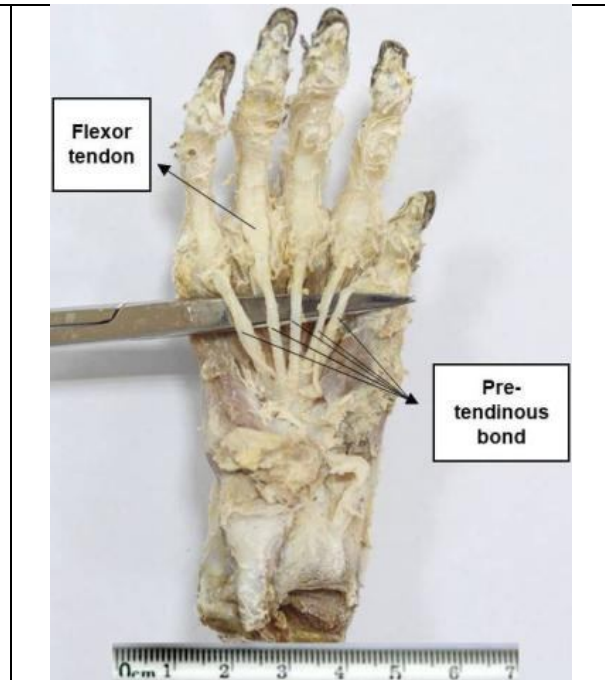


Figure (26): Dorsal view of Baboon hand showing flexor tendon and pre-tendinous band.

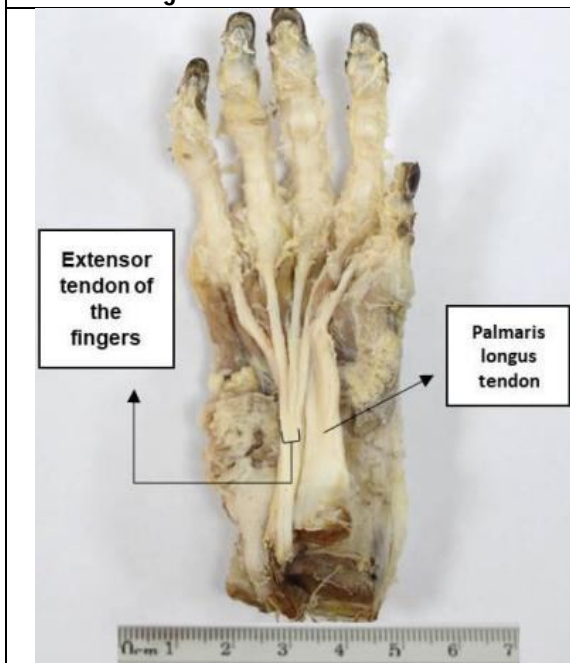


Figure (27): Ventral view of Baboon hand showing flexor tendon of fingers and palmaris longus tendon.

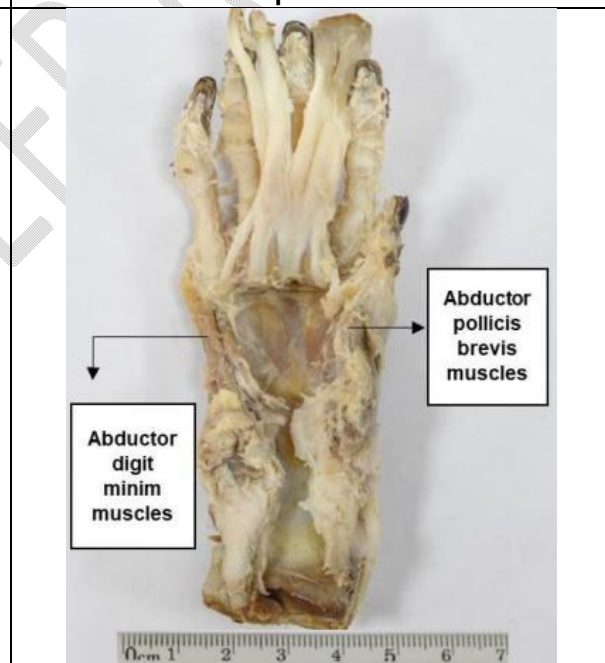


Figure (28): Ventral view of Baboon hand showing abductor pollicis brevis muscles and abductor digiti minimi muscles.

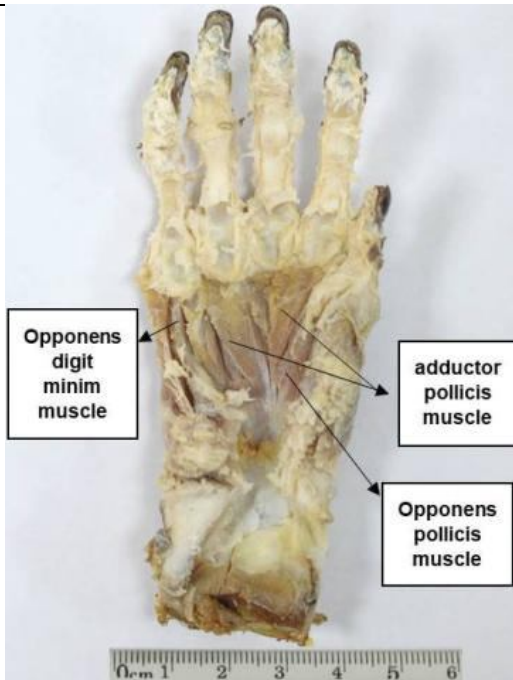


Figure (29): Ventral view of baboon hand showing abductor pollicis muscle, opponens pollicis muscle and opponens digiti minimi muscles.

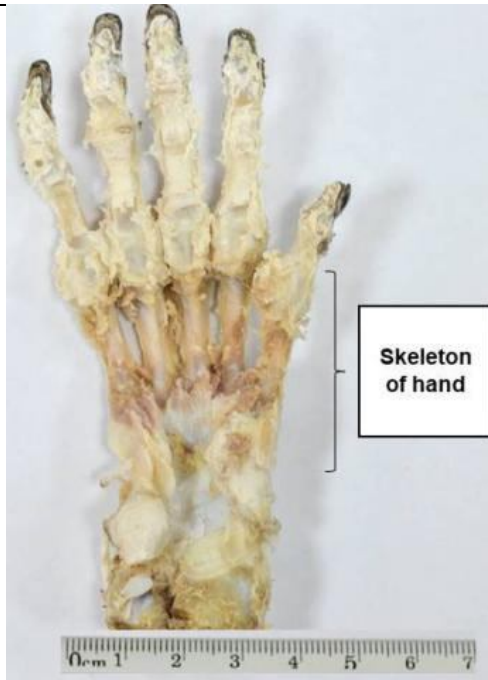

Figure (30): Ventral view of Baboon hand showing skeleton of the hand.

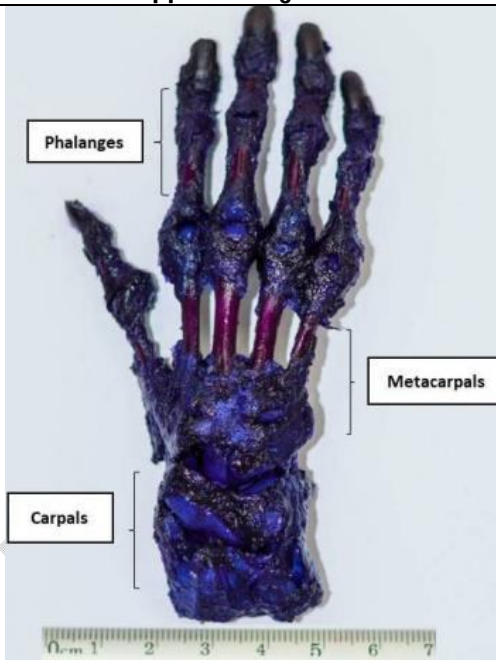


Figure (31): Dorsal view of Baboon hand skeleton showing phalanges, metacarpals and carpals.

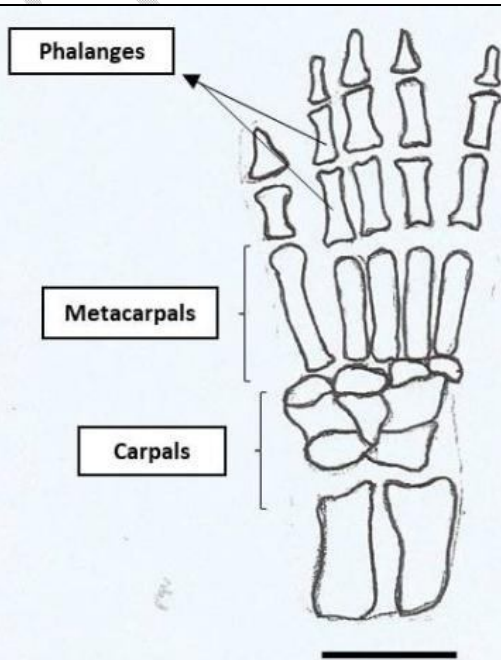


Figure (32): Diagram of Baboon hand skeleton from dorsal view showing phalanges, metacarpals and carpals.

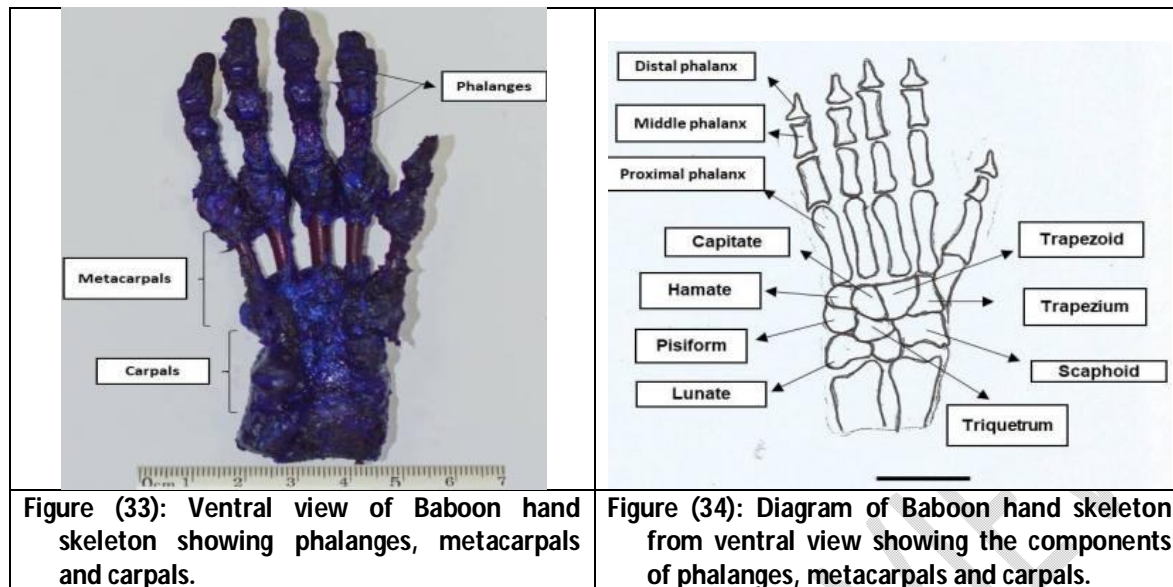


Figure (33): Ventral view of Baboon hand skeleton showing phalanges, metacarpals and carpals.

Figure (34): Diagram of Baboon hand skeleton from ventral view showing the components of phalanges, metacarpals and carpals.

### 3. Squirrel hand:

Hand of squirrel is small and closed dimensions, made up of five short fingers pointed (thumb, index finger, middle finger, ring finger, and small finger). Every finger ends with a claw tapered and sharp with a curved end. The hand skin is thin and covered with hair and dense dryness gradually decreased at the fingers and is almost empty (Fig. 35). Palm of the hand is also thin but completely free of hair. There are palm pad at the end of the fingers; there is a digital pad with cardiac shape (Fig. 36).

After removal of the outer skin covering the appearance of the hand and the appearance of the fingers, a very thin fatty layer was noticed on the dorsal of hand and fingers (Fig. 37). With anatomy of the hand dorsal surface, the tendons of the hand such as extensor digiti muscles tendons and tender of extensor digiti minimi were observed (Fig. 38). After lifting a set of visible hand tendons, a set of muscles known as muscles of hand (back) was observed (Fig. 39). When the palm rest was gradually dissected, a denser fatty layer was noticed, also palm tendons (digitorum profundus) which appeared as five tendons of flexor (fig. 40). These tendons were pulled down at the wrist to give flexor carpi ulnar tendon (Fig. 41). The range of tendons extending from the palm of the hand to the wrist area is known as the extensor tendons of the fingers (Fig. 42). After lifting the extend tendons of the fingers, the muscles of the palm are appeared, the lumbrical muscles which is located under the tendons directly at the middle of the palm, and on its sides at the thumb, the opponens pollicis muscle, and at the small finger the opponens digit minim muscle was found (Fig. 43).

After the hand was stained with alizarin red stain and alcian blue stain, parts of the hand skeleton was beginning to appear such as phalanges, metacarpals and carpals (Figs. 44 & 46). Since they did not give quite clear results, it has been the manual drawing of the hand skeleton of squirrel from the dorsal and ventral surfaces to illustrate the phalanges and metacarpals. The phalanges are short and all fingers contain two phalanges, the proximal phalanx and the distal phalanx except the thumb, it contains only one phalanx. The metacarpals are five and longer than the phalanges (Figs. 45 & 47). Finally, the wrist bone has been observed as six carpals of different shapes they are trapezium, trapezoid, magnum, unciform finally the ulnar (Fig. 48).

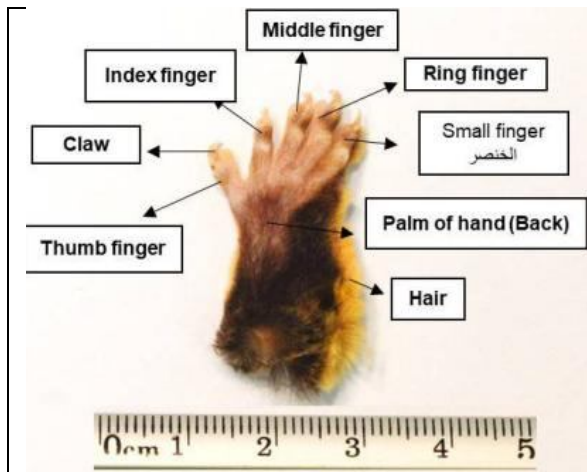


Figure (35): Dorsal view of squirrel hand showing different fingers of the hand.

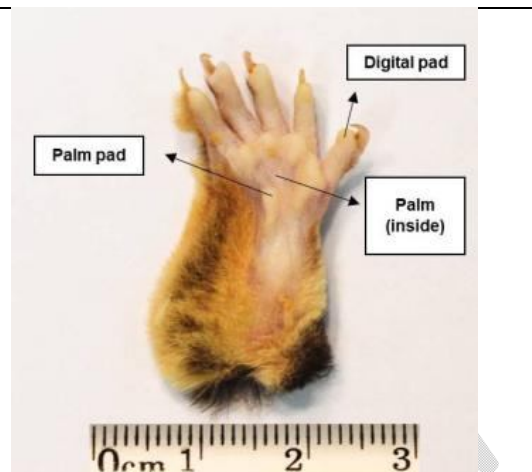

Figure (36): Ventral view of squirrel hand showing digital pad, palm pads and the palm.

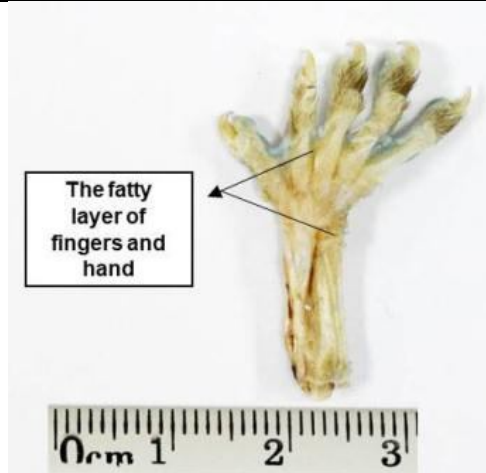

Figure (37): Dorsal view of squirrel hand showing fatty layer of fingers and hand.

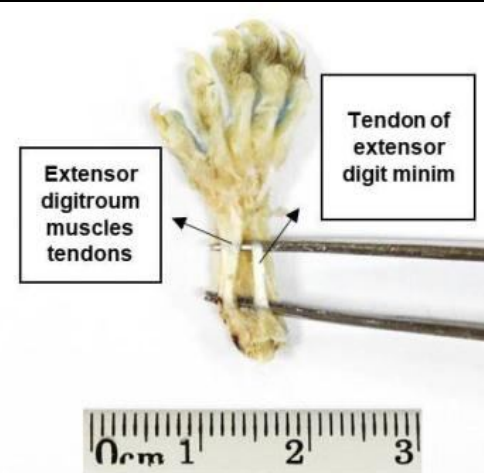


Figure (38): Dorsal view of squirrel hand showing different tendons of muscles.

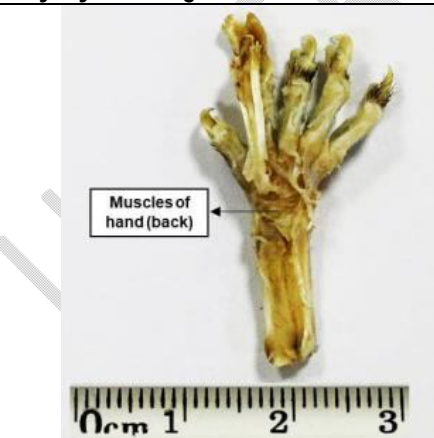

Figure (39): Dorsal view of squirrel hand showing muscles of hand dorsum.

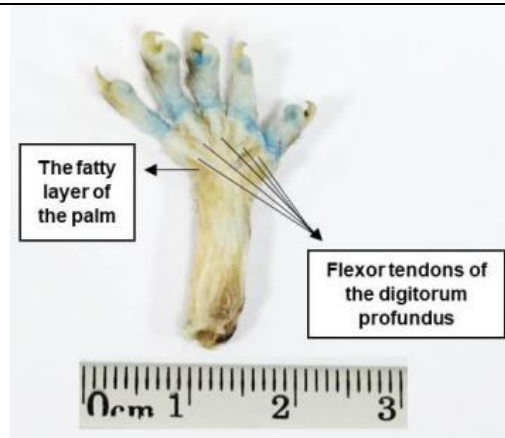


Figure (40): Ventral view of squirrel hand showing fatty layer of palm and flexor tendons of digitorum profundus.

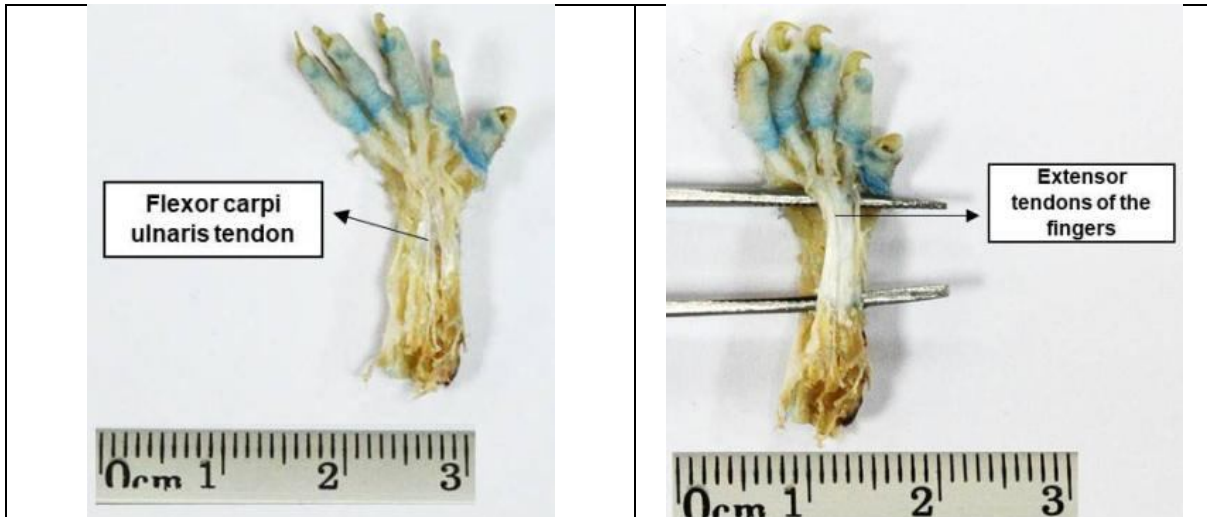


Figure (41): Ventral view of squirrel hand showing flexor carpi ulnaris tendon.

Figure (42): Dorsal view of squirrel hand showing extensor tendons of fingers.

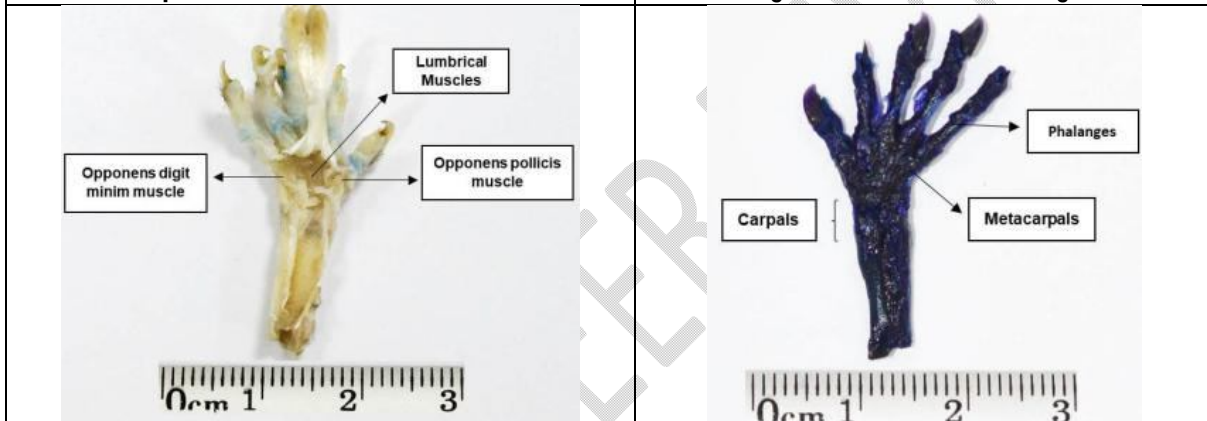


Figure (43): Ventral view of squirrel hand showing lumbrical, opponens digit minimi and opponens pollicis muscles.

Figure (44): Dorsal view of squirrel hand skeleton showing phalanges, metacarpals and carpals.

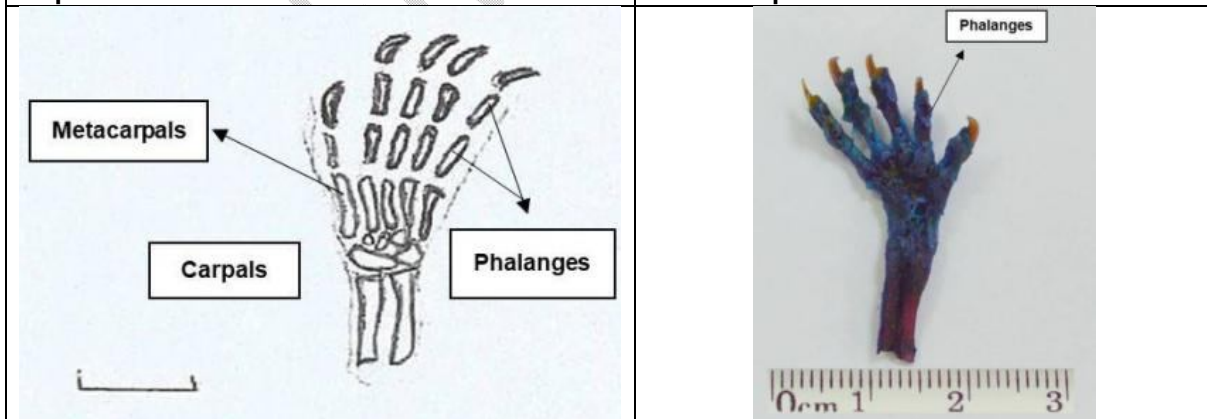
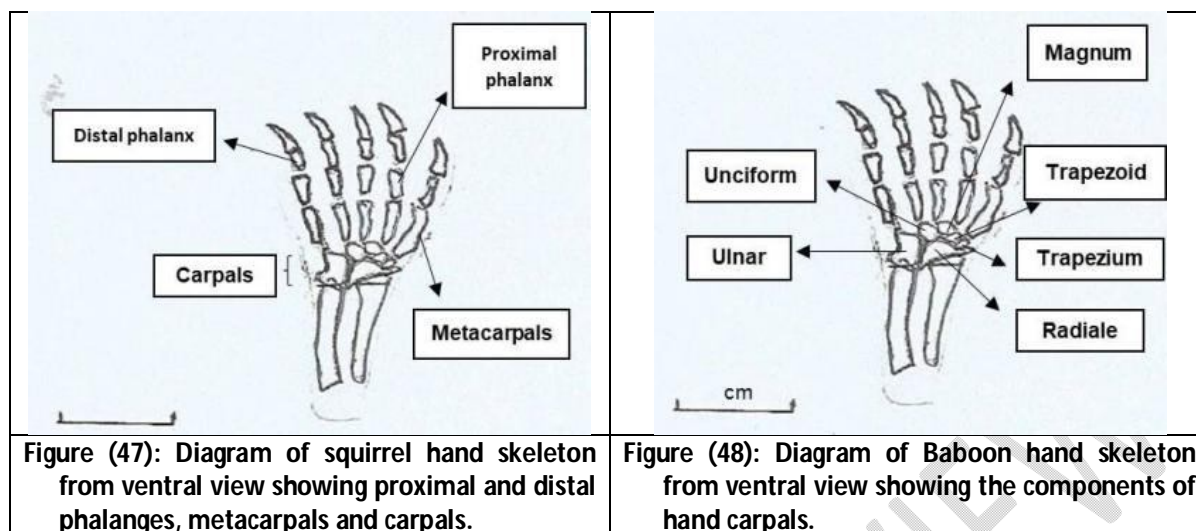


Figure (45): Diagram of squirrel hand skeleton from dorsal view showing phalanges, metacarpals and carpals.

Figure (46): Ventral view of squirrel hand skeleton showing phalanges, metacarpals and carpals.



## DISCUSSION

The human finger system has a fundamental structure and consists of five fingers that are parallel to the lengths and they are also pentagon in the baboon and monkey, while being short pointed in the squirrel. These results agree the descriptions presented in numerous studies (Laurin *et al.*, 2000; Panchal-Kildare & Malone, 2013; Selby *et al.*, 2016 and Nishimoto & Logan, 2016).

From examination of the appearance and palm of hand in human, baboon and squirrel, it is clear that the appearance of the hand is varied. There are wrinkles on the surface of the dorsal surface if compared to the abdominal surface in each of the studied animals. But these wrinkles appear more in the human than the monkey, which is limited to the presence of wrinkles on the end of the fingers only, while the dorsal surface of squirrel hand is empty from wrinkles. The hair grows heavily on the appearance skin of baboon and squirrel hands comparing to human hand. Thumb finger is characterized as an independent unit of high mobility and flexibility in humans and less efficiency in the monkey and squirrel. These findings agree with many authors (Meguerditchian *et al.*, 2015; Molnar *et al.*, (2017 and Popplewell *et al.*, 2017).

Each finger of human hand ends from the dorsal side with a thin nail, and each finger of baboon ends with very thick nail, while every finger of squirrel ends with a claw tapered and sharp with a curved end. These results indicated that the structural development is necessary to adapt these animals to their environment. Such conclusion agrees Smith & Smith (2013) who reported that Callitrichid monkey species have fingers end with climbing claws.

The fatty layer scattered under the skin of the fingers and hand in human is thick, while in baboons and squirrel fat layer is thin this area be encouraged to the role of that class in linking the dermis with muscles and bones, which are more advanced in human. The tendons in the human hand are similar to the visible tendons of the baboon monkey such as the tendon of extensor digiti minimi and the tendon of extensor indices, tendons of the extensor pollicis brevis muscle, tendon of extensor pollicis longus muscle and a group of tendon of extensor flexor and finally privileged communication between the tendons, while the squirrel is compatible with human and baboon only the presence of tendon extensor flexor and tendon of extensor digiti minimi humiliation as from the dorsal that's

what note when they are described to dissect the palm and the tendon in the human (**Gordon *et al.*, 2012**).

The existence of a group of those tendons similar in human and baboon achieves a pattern of constipation and realize dynamic somewhat evenly matched, so the study agrees (**Huang *et al.*, 2013**) that the origin of the movement is a force transmitted by the tendons of the hand to the structure. It is noted that to be the presence of muscular part in the dorsal surface of the human hand as the first dorsal muscle between the bones matched by simple muscles between the bones of a baboon and squirrel. Then, the muscles have control and control over flexion fingers and reminded each of **Huang *et al.* (2013)** and **Alsukaini *et al.* (2016)**.

It showed the comparative anatomy of the palm of the human hand and a baboon and a squirrel that pre-tendinous is distinctive and consistent in the rest of those organisms and also the extensor tendons of the fingers, but it is characterized by human and baboon for squirrel presence flexor tendon and tendons flexor muscles of the fingers and tendon palmaris longus tendon and this corresponds with **Meguerditchian *et al.* (2015)**.

Examines the muscles of the human hand palm found that hypothenar muscle which is one of the major muscles of the palm of the hand is characterized by a small bulge besides the small finger on the ulnar side of the hand (**Pasquella & Levin, 2012**). When dissecting human hand, they found opponens pollicis muscle of thumb opponens digiti minimi muscle of the small finger in humans and baboons and squirrel with a different degree of composition of the strongest to force at least due to a functional role in motor behavior such as the grip of human and climbing tree for monkey and squirrel. This is consistent with the description of **Aversi-Ferreira *et al.* (2016)**.

The anatomical features vary according to the kinetic behavior of Japanese and Indian monkeys. The dissection of the muscles into the human hand showed the abductor pollicis brevis muscles of the thumb and abductor digiti minimi muscle of the **small finger have a high thickness resulting in the movement and the accuracy of the strong grip of thumb and high rise in the fingers and manipulate; this is consistent with Diogo *et al.* (2012) and Feix *et al.* (2015) who found that the thumb muscles and the strong flexion with its synchronized movements** reflect the ability to control the thumb when using the tools **Kerkhof *et al.* (2016)**.

The thumb has a markedly muscular activity, while the abductor digiti minimi of the thumb and pinki in the baboon is a thickness of less than human, and this is due to the functional role played by those muscles in the participation of a hand in the non-kinetic roles also. The presence of lumbar muscles in the human hand and the squirrel is considered the strength of the fingers extensions. This is inconsistent with many authors (**Von Schroeder & Bottee, 2001; Patel *et al.*, 2015 and Leeuwen *et al.*, 2018**).

It is noted that the sheath of the fibrous finger in both the human and the baboon monkey is clear after the complete anatomy of the hand, the **baboon monkey is characterized by the presence of the thickest sheath and the presence of the finger in both the human, baboon monkey and squirrel the structural of the hand is shown in its main parts, which are phalanges, hand metacarpals and wrist bones. The phalanges characterized in human hand and a baboon with three phalanges of each finger except the thumb it contains two phalanges, while in squirrel phalanges are short and each finger contains two phalanges except the thumb contain only one.** This is agrees with **Casanova & Sanz-**

**Ezquerro (2007)** who concluded that phalanges have a role in formation of the fingertips and it is the last step in the design of the structure.

## **Conclusion**

In the present study, metacarpals of the human hand the monkey are five long and thin metacarpals but squirrel metacarpals are short. **Panchal-Kildare & Malone (2013)**, through their study on the anatomy of the hand structure, found that these metacarpals and phalanges move from each other in a similar manner. The last major part of the hand structure is the elastic wrist bones and is arranged in two rows of four bones of the human hand (hamate, pisiform, triquetrum, lunate, trapezium, trapezoid, capitate and scaphoid) which are syntactically and functionally compatible with the monkey hand. While the wrist of squirrel hand has a distinctive shape of six bones in two rows (magnum, trapezoid, trapezium, radial, uniciform and ulnar). This indicated that different shapes and sizes of bones structure are of critical importance in the movement (**Panchal-Kildare & Malone, 2013; Provot et al., 2013 and Williams-Hatala et al., 2016**). **Selby et al. (2016)** concluded that the articular joints in the baboon monkey are sophisticated and modified for functional adjustment in large monkeys physically sized and possessing distinctive rattles that give them adjustment when attached and vertical climbing.

## **ETHICAL CONSIDERATION**

The authors ensured that all ethical and other basic principles were considered. A permission to carry-out this study was given by the Institutional Review Board Committee of the Deanship of Scientific Research, with the IRB number (**IRB-PGS-2017-10-076**).

## **REFERENCES**

- Adams, M.J.; Johnson, S.A. and Lefèvre, P. (2012)** Finger pad friction and its role in grip and touch. *J R Soc Interface*, **10**(80):20120467.
- Al-Sukaini, A.; Singh, H.P. and Dias, J. (2016)** Extrinsic versus intrinsic hand muscle dominance in finger flexion. *J. Hand Surg. (Eur.)*, **41**(4):392–399.
- Aversi-Ferreira, T.A.; Aversi-Ferreira, R.A.; Bretas, R.V.; Nishimaru, H. and Nishijo, H. (2016)** Comparative anatomy of the arm muscles of the Japanese monkey (*Macaca fuscata*) with some comments on locomotor mechanics and behavior. *J Medical Primatology*, **45**(4): 165–179.
- Bock, W.J. (2001)** Functional Morphology of the Woodpecker Feeding Apparatus. In: Dutta HM, Munshi JSD, editors. *Vertebrate Functional Morphology*. Enfield, NH, USA: Science Publishers, P: 295–314.
- Casanova, J.C. & Sanz-Ezquerro, J.J. (2007)** Digit morphogenesis: is the tip different?. *Develop. Growth Differ.*, **49**(6): 479–491.

- Diogo, R.; Richmond, B.G. and Wood, B. (2012)** Evolution and homologies of primate and modern human hand and forearm muscles, with notes on thumb movements and tool use. *J Hum Evol.*, **63**(1): 64–78.
- Feix, T.; Kivell, T.L.; Pouydebat, E. and Dollar, A.M. (2015)** Estimating thumb-index finger precision grip and manipulation potential in extant and fossil primates. *J. R. Soc. Interface*, **12**(106): 20150176.
- Gordon, J.A.; Stone, L. and Gordon, L. (2012)** Surface markers for locating the pulleys and flexor tendon anatomy in the palm and fingers with reference to minimally invasive incisions. *J. Hand Surg. Am.*, **37**(5): 913–918.
- Huang, A.H.; Riordan, T.J.; Wang, L.; Eyal, S.; Zelzer, E. and Brigande, J.V. (2013)** Repositioning forelimb superficialis muscles: tendon attachment and muscle activity enable active relocation of functional myofibers. *Dev Cell.*, **26**(5): 544–551.
- Kerkhof, F.D.; Deleu, G.; D'Agostino, P. and Vereecke, E.E. (2016)** Subject-specific thumb muscle activity during functional tasks of daily life. *J. Electromyogr Kinesiol.*, **30**: 131–136.
- Laurin, M.; Girondot, M. and de Ricqlès, A. (2000)** Early tetrapod evolution. *Trends Ecol. Evol.*, **15**(3): 118–123.
- Leeuwen, T.V.; Vanhoof, M.J.M.; Kerkhof, F.D.; Stevens, J.M.G. and Vereecke, E.E. (2018)** Insights into the musculature of the bonobo hand. *J. Anat.*, **233** (3): 328-340.
- Macdonald, D.W. (2007)** *The Encyclopedia of Mammals*. 3<sup>rd</sup> ed. Oxford University Press.
- Meguerditchian, A.; Phillips, K.A.; Chapelain, A. et al. (2015)** Handedness for Unimanual Grasping in 564 Great Apes: The Effect on Grip Morphology and a Comparison with Hand Use for a Bimanual Coordinated Task. *Front Psychol.*, **6**: 1794.
- Molnar, J.; Esteve-Altava, B.; Rolian, C. and Diogo, R. (2017)** Comparison of musculoskeletal networks of the primate forelimb. *Scientific Reports*, **7**(1): 10520.
- Nishimoto, S. & Logan, M.P. (2016)** Subdivision of the lateral plate mesoderm and specification of the forelimb and hindlimb forming domains. *Seminars in Cell & Developmental Biology*, **49**: 102–108.
- Oberlin, C. (2006)** Anatomie comparée de la main [Comparative anatomy of the hand]. *Chirurgie de la Main*, **25**(3-4):111–118.
- Panchal-Kildare, S. & Malone, K. (2013)** Skeletal anatomy of the hand. *Hand Clin.*, **29**(4): 459–471.
- Pasquella, J.A. & Levine, P. (2012)** Anatomy and function of the hypothenar muscles. *Hand Clinics*, **28**(1): 19–25.
- Patel, B.A.; Wallace, I.J.; Boyer, D.M.; Granatosky, M.C.; Larson, S.G. and Stern, J.T. Jr. (2015)** Distinct functional roles of primate grasping hands and feet during arboreal quadrupedal locomotion. *J. Hum. Evol.*, **88**:79–84.
- Popplewell, H.; Carre, M. and Lewis, R. (2017)** Measurement of finger pad forces and friction using finger nail mounted strain gauges. *Wear*, **376**: 295-304.

- Provot, S.; Schipani, E.; Wu, J. Y. and Kronenberg, H. (2013)** Development of the Skeleton. In: Osteoporosis 4<sup>th</sup> ed., chapter 6: 97-126.
- Salaramoli, J.; Sadeghi, F.; Gilanpour, H.; Azarnia, M. and Aliesfehni, T. (2015)** Modified double skeletal staining protocols with Alizarin red and Alcian blue in laboratory animals. *Annals of Military & Health Sciences Research (AMHSR)*, **13**(2): 76-81.
- Selby, M.S.; Simpson, S.W. and Lovejoy, C.O. (2016)** The Functional Anatomy of the Carpometacarpal Complex in Anthropoids and Its Implications for the Evolution of the Hominoid Hand. *Anat Rec (Hoboken)*, **299**(5): 583–600.
- Smith, J.M. & Smith, A.C. (2013)** An investigation of ecological correlates with hand and foot morphology in callitrichid primates. *Am. J. Phys. Anthropol.*, **152**(4): 447–458.
- Thorington, R.W. Jr & Darrow, K. (2000)** Anatomy of the squirrel wrist: bones, ligaments and muscles. *J. Morphol.*, **246**(2): 85–102.
- Von Schroeder, H.P. & Bottee, M. (2001)** Anatomy and Functional Significance of the Long Extensors to the Fingers and Thumb. *Clinical Orthopaedics and Related Research*, **383**: 74-83.
- Williams-Hatala, E.M.; Hatala, K.G.; Hiles, S. and Rabey, K.N. (2016)** Morphology of muscle attachment sites in the modern human hand does not reflect muscle architecture. *Scientific Reports*, **6** (28353): 1-8.