

Case study

A Case Series on Complicated Diaphragmatic Hernias in Adults

ABSTRACT

Aims: To describe the diagnosis, evaluation and management of cases of complicated diaphragmatic hernias in adults.

Study design: Observational descriptive study

Place and Duration of Study: Department of Surgery (Unit V), SMS Medical College and Hospital, Jaipur, between February 2022 and August 2022.

Methodology: We identified all adult patients diagnosed with diaphragmatic hernia and treated operatively during a period of 6 months in a single tertiary care centre. Data on patient demographics, clinical course, surgical characteristics, mortality and morbidity were collected.

Results: A total of 6 patients were identified (4 males, average age: 46.6 years). 3 patients were diagnosed with left Bochdalek hernia (BH), 1 with right BH, 1 with Morgagni-Larry hernia and 1 with traumatic diaphragmatic hernia (TDH). The most common presenting symptoms were abdominal pain and vomiting (50%). 2 patients were operated laparoscopically and 4 via a laparotomy. The most commonly herniated organs were stomach and colon. Postoperative length of stay was 8.25 days on average. 2 deaths occurred in the post-operative period, and no recurrences were reported upon long-term follow-up.

Conclusion: Diaphragmatic hernias in adults present a substantial diagnostic and therapeutic challenge. Minimally invasive approach is associated with quicker recovery, while laparotomy may be reserved for emergencies. Higher degree of clinical suspicion is required to detect and confirm the diagnosis and must be followed by immediate surgical intervention without any “waiting period”.

Keywords: Diaphragmatic hernia, emergency surgery, traumatic diaphragmatic hernia, congenital diaphragmatic hernia, strangulation, gut gangrene, case series

1. INTRODUCTION

Diaphragmatic hernia is the protrusion of abdominal contents into the thoracic cavity through a defect in the diaphragm. It can be either congenital or acquired. The incidence of congenital diaphragmatic hernia (CDH) is reported to be 1 in 3,000-5,000 live births [1]. In most patients, CDH is diagnosed in infancy, but smaller hernias may remain asymptomatic during childhood and present later in adult life, where acquired diaphragmatic hernias secondary to blunt or penetrating trauma are more common and are termed as traumatic diaphragmatic hernia (TDH) [2]. [3]. The reported incidence of TDH varies from 0.4 to 8% [4, 5] Left-sided diaphragmatic hernias are more common (80–90%) because of the earlier closure of the right pleuro-peritoneal canal, weakness of the left diaphragm along the lines of embryonic fusion and the protection of right hemi-diaphragm by liver. 6, 7 most diaphragmatic hernias are asymptomatic in adults [8] and are detected incidentally, but in some cases, patients present with symptoms that arise from incarceration or strangulation

of the a viscera within the chest cavity [9], long after the hernia first originated. Urgent surgical intervention is mandatory once the diagnosis has been established, to prevent the high mobility and mortality rates associated with complicated CDH or TDH. We present our experience with the management of various types of complicated diaphragmatic hernias in a series of six patients.

The following case series has been reported in accordance with the STROBE guidelines.

2. PRESENTATION OF THE CASES

1. A 52 year old male presented with complaints of abdominal pain since 5 days associated with abdominal distension since 2 days. He had no significant medical or surgical history. On examination, the abdomen was tender in the left hypogastric region, and breath sounds were reduced over the left lower chest. A routine chest X-ray was suggestive of the presence of bowel loops in the left thoracic cavity with right mediastinal shift. A high resolution CT scan of the chest was obtained and the diagnosis of left Bochdalek Diaphragmatic hernia was made, possibly containing stomach, omentum, spleen and left kidney.

After obtaining written informed consent, the patient was taken up for surgery. An abdominal laparoscopic approach was used. Intraoperatively, spleen was found to be densely adhered to the diaphragm. Unable to visualize the lateral surface of the spleen, we converted the procedure to a laparotomy using the left-sided J-shaped incision. Adhesiolysis was completed and stomach, spleen, splenic flexure of colon, and omentum were found to be the contents of the hernial sac. The contents were reduced into the abdominal cavity and the sac was excised. An intercostal drainage tube was inserted into the left thoracic cavity under direct vision, and the diaphragm was repaired using thick, non-absorbable sutures and SR75® linear cutter. A composite mesh was placed over the defect site and fixed used tacks. An abdominal drain was placed in the splenic fossa and the abdominal wall was closed, with a vacuum suction drain in the subcutaneous plane.

The post-operative period was uneventful. The patient was started on liquid diet on day 3. Drains were removed on day 4. The patient was discharged on day 6 on soft solid diet. He reported for follow up one week later with no complications and continues to do well.

2. A 37 year old female presented to emergency with complaints of chest pain and repeated episodes of vomiting. The patient had a history of burning sensation in the chest since 5 months, associated with nausea after meals. Patient was a chronic tobacco chewer since 15 years but had no other significant past history. On examination, patient was hypotensive, breath sounds were markedly reduced over the left chest, and abdomen was soft, non-tender. A chest X-ray revealed possibility of dilated bowel loops in the left thoracic cavity. Patient was adequately resuscitated with intravenous fluids and nasogastric tube suctioning. The patient later showed an abdomino-thoracic CT scan report five months old, that was suggestive of a left diaphragmatic hernia.

A diagnosis of obstructed diaphragmatic hernia was made and the patient was taken up for a laparoscopic trans-abdominal repair after written informed consent. Intraoperatively, a large left Bochdalek hernia was confirmed with stomach, spleen and large bowel as the contents. The viscera were intact with no gangrene and were reduced into the abdomen. A left intercostal drainage tube was inserted under vision and the diaphragm repaired using continuous, self-retaining, non-absorbable sutures. A composite mesh was then placed over the defect and fixed with tacks.

The patient made an uneventful recovery. The nasogastric tube was removed after 24 hours. She was started on liquid diet on day 2 and soft diet on day 5. The intercostal

drain (ICD) continued to have a moderate output of around 150ml per day and hence the patient was discharged with ICD in-situ on day 6. The patient followed up after a week. The ICD had minimal output and a chest X-Ray showed complete expansion of the left lung. Hence the ICD was removed. She continued to stay in regular follow-up and continues to be well.

3. A 54 year old male presented with complaints of right upper abdominal pain since 2 weeks which increased in severity in last 3 days. He had no significant past history. On examination, the abdomen was tender in the right hypogastric region, and the upper border of liver seemed to be between 3rd to 4th intercostal spaces on percussion. A chest X-ray showed a gas shadow above the right dome of diaphragm. Contrast enhanced CT scans of abdomen and thorax were obtained and revealed a large defect in the right dome of diaphragm with herniation of the right lobe of liver, right kidney and hepatic flexure of colon into the thoracic cavity.

The patient was taken up for a laparoscopic trans-abdominal repair after written informed consent. Intra-operatively, a diagnosis of incarcerated right Bochdalek hernia was made containing the right lobe of liver, right kidney, omentum and hepatic flexure of colon. Careful adhesiolysis was performed, the contents were reduced into the abdomen, an ICD was placed in the right thoracic cavity under vision and diaphragmatic repair was done using continuous, self-retaining, non-absorbable sutures. A circular 15X15cm mesh was then placed over the defect and fixed with tacks.

The patient was started on liquid diet on day 2, and soft solid diet on day 4. The ICD showed a high volume output of 350ml on day 1, gradually reducing to 100ml over 24 hours on day 6. The patient was discharged with ICD in situ on day 6. He followed up after a week and the ICD was removed. He remained in regular follow up and continues to be well.

4. A 58 year old female presented to emergency with complaints of recurrent vomiting since last 15 days. She had a history of repeated episodes of vomiting since 2 months, which aggravated rapidly to an extent that she was unable to tolerate any oral feed since last 4 days. She had a past history of a road traffic accident 2 years ago, in which she sustained fractures of multiple ribs on the left side and was managed successfully conservatively. She had been diagnosed with a left diaphragmatic hernia 5 months back, which was revised to a large hiatal hernia 1 month later following an upper GI endoscopy, but the patient refused surgical intervention.

On examination, the patient was severely malnourished, anaemic, hypotensive and had altered sensorium. The upper abdomen was distended and rigid on palpation. She was stabilized with rapid administration of intravenous fluids, nasogastric tube suctioning and analgesics. The nasogastric tube aspirate showed feculent content and patient was immediately taken for emergency laparotomy under high risk after taking written informed consent.

A midline laparotomy incision was made. The abdomen showed a large, left antero-lateral diaphragmatic hernia (Morgagni-Larry hernia), with protrusion of stomach, spleen, transverse colon and omentum into the thoracic cavity. The viscera had become strangulated, with gangrene of the entire herniated segment of transverse colon and a gangrenous patch over the spleen showing active oozing of blood. All the contents were reduced into the abdomen, a splenectomy was performed, the gangrenous colon was resected and the ends taken out as a double barrel colostomy. An ICD was placed in the left thoracic cavity, and diaphragm repaired with interrupted sutures of polypropylene. She received transfusion of two bags of packed red cells intraoperatively, and had to be started on inotropic support to maintain blood pressure. The patient was shifted to ICU on ventilator support.

The patient improved gradually and was extubated the next day. She was started on parenteral nutritional supplementation and was shifted to the ward on day 2. The patient

started developing shortness of breath within the next 24 hours, and had to be shifted back to ICU for monitoring. She improved on injections of short acting corticosteroids and oxygen supplementation via face mask. The patient was started on oral sips on day 4. However, respiratory efforts continued to worsen, and ABG revealed hypoxemia with respiratory acidosis. She developed gasping and had to be re-intubated on day 5. She developed bilateral moderate pleural effusion, and diffuse atelectasis of the left lung and was diagnosed with acute respiratory distress syndrome (ARDS). She eventually succumbed to respiratory failure and was declared dead on day 9.

5. A 43 year old male presented to the emergency with complaints of abdominal pain since 7 days, rapidly increasing in severity and associated with obstipation and vomiting since 3 days. He was a known case of coronary artery disease (CAD) with inferior wall myocardial infarction with left ventricular ejection fraction of 40%, and underwent coronary stenting 2 months ago. On examination, the patient was tachycardic with a pulse rate of 116/minute and abdominal examination showed diffuse distension, tenderness and guarding. The chest X-ray showed poor chest condition but was otherwise unremarkable.

With no improvement in pain and distension on conservative management, the patient was taken up for emergency laparotomy after getting a written informed consent. A midline laparotomy incision was given, and transverse colon and omentum were seen herniating via a large left Bochdalek hernia into the thoracic cavity. The contents were reduced into the abdomen and showed gangrene of the strangulated omentum. An omentectomy was performed, an ICD placed in the left thorax, and diaphragm repaired using interrupted sutures of polypropylene.

The patient was shifted to the ICU for monitoring. He developed sudden onset tachypnea from day 1, which did not respond to conservative management. Cardiac failure was suspected, but ECG was negative for a myocardial infarction. A repeat serum profile showed massively deranged renal function with serum creatinine of 6.36 and blood urea at 160 mg/dl. Generalized thrombo-embolism secondary to CAD was suspected. The patient developed recurrent episodes of high grade fever and was started on higher antibiotics but he continued to worsen, with no response to conservative management, and had to be re-intubated on day 3. He eventually succumbed and was declared dead on day 3.

6. A 36 year old male was referred to our trauma emergency with a history of road traffic accident one day ago. The patient had right hip dislocation, and fractures of the shaft of right femur and 9th rib. He was referred with complaints of shortness of breath. On examination, he had a pulse rate 112/minute, and was tachypneic. The patient complained of heaviness in the chest upon abdominal examination. Suspecting abdominal injury, abdominal and chest CT scans were ordered which showed herniation of bowel through a rent in the left hemi-diaphragm along with a massive left pleural effusion.

Emergency ICD insertion was done which showed a feco-bilious output. The patient was taken up for emergency laparotomy after taking a written informed consent. The abdomen showed around 500ml of bilious contamination. Stomach and small bowel was seen herniating into the left thoracic cavity through a tear in left hemi diaphragm. The herniated contents were reduced and a 1 X 1cm gangrenous patch was noted on the anterior wall of stomach with perforation, which was excised and a Modified Graham Patch repair of the stomach was done. On further exploration, a large mesenteric tear was noted along a 30cm segment of small bowel, about 20cm proximal to the IC junction, along with gangrene and multiple perforations in the adjacent ileum. The gangrenous segment was resected and end-to-end anastomosis of the remaining ileum was done. A thorough lavage of peritoneal and thoracic cavity was done. 20cm proximal to the site of anastomosis, the ileum was exteriorized as a loop ileostomy. The

diaphragm was repaired using interlocking continuous sutures with polypropylene. A pelvic drain was placed and the abdomen closed in layers.

The patient was extubated and shifted to ICU. The patient developed severe sepsis and was started on inj. Tigecycline and polymixin B on day 8 and responded well. Once the infection improved, the nasogastric tube was removed and patient was started on oral liquids on day 11. On day 14, the patient was initiated on a soft solid diet, which was tolerated well. The drains were eventually removed and patient was discharged on post-operative day 15. The patient remained on regular follow-ups and continues to do well.

3. RESULTS

We analyzed six patients of complicated diaphragmatic hernias, out of which four were males and two were female. The most common presenting symptom was abdominal pain (3/6, 50%) and vomiting (3/6, 50%), followed by chest pain, shortness of breath and obstipation (1 each). Chest X-ray was characteristic and was suggestive of the correct diagnosis in 4 out of 6 patients.

A contrast enhanced CT was either done or had previously been done before presentation, to confirm the diagnosis in 4 out of 6 patients, excluding 2 patients where immediate surgery was required.

All patients were operated with a trans-abdominal approach. 3 patients were operated via laparoscopic approach and 3 via laparotomy. One of the laparoscopic cases had to be converted to a laparotomy. Mesh repair was done in all laparoscopic cases, while no mesh was placed in all the emergencies (3/6). Intraoperatively, the following types of diaphragmatic hernias were diagnosed. [Table 1]

Type	Number
Bochdalek	4
Morgagni-Larry	1
TDH	1

*Table 1: Diagnosis
TDH: Traumatic diaphragmatic hernia*

The most commonly herniated organ was stomach, omentum and colon (4/6), followed by spleen (3/6), kidney (2/6), liver and ileum (1 each). In all cases, at least 2 different organs were contents of the hernial sac.

Gut gangrene was present in 3/6 (50%) cases, and strangulation of stomach with gangrene and perforation was noted in 1 patient. Splenectomy had to be performed in 1 patient.

Days to diet	Mean	Maximum	Minimum
Liquid diet	4.5	11	2
Soft diet	7.25	14	4

Table 2: Diet initiation

Postoperative length of stay was 8.25 days on average. It was 6 days for all laparoscopically operated patients and one patient where laparoscopy was converted to laparotomy, while it was 15 days for the case of TDH.

Out of the 6 patients who were operated, 2 succumbed to complications and died.

4. DISCUSSION

We analyzed six patients of complicated diaphragmatic hernias, out of which four were males. Diaphragmatic hernias can be congenital or acquired. The 3 basic types of CDH include the Bochdalek hernia (posterolateral), the Morgagni hernia (anterior/ parasternal), and the hiatus hernia, with a left Bochdalek hernia being the most common [11, 12]. The same was observed in our cases, with 3/6 patients diagnosed with left Bochdalek hernia (BH). Usually CDH is diagnosed in infancy but some may remain asymptomatic and persist till adulthood. In traumatic cases, the diaphragmatic rupture process can be divided into three phases, acute, latent and obstructive [13], where the latter two are described as “delayed presentation.” The acute phase is the time when the diaphragm is injured; during this phase, symptoms of a TDH may be absent or masked by co-existing injuries. Among our patients, however, we report a rare instance of a TDH presenting with strangulation in the acute phase. We also reported 2 rare presentations of CDH, with one patient each diagnosed with a right Bochdalek hernia and a left Morgagni-Larry hernia.

Most common presenting symptoms in our patients were abdominal pain and vomiting (3/6, 50%), and only one patient had complaints of shortness of breath. We found that a chest X-ray is sufficiently able to suggest a diagnosis of DH, which can then be unequivocally confirmed with a CT scan. Owing to its rarity and a prolonged asymptomatic period, DH can frequently be overlooked in patients presenting with vague complaints like vomiting and shortness of breath. In our experience, a high degree of clinical suspicion should always be practiced in these cases, and may be of more value than previously thought.

Surgical intervention is necessary and should be done as soon as possible. Mild symptoms can precede the stage of strangulation by months to years. [15] If a DH is diagnosed incidentally in a patient with no or mild symptoms, a “wait-and-watch” policy should not be undertaken, and can have catastrophic results. [16, 17]

Surgery can be performed via a trans-thoracic or trans-abdominal approach. Recently, minimally invasive surgery, including thoracoscopic and laparoscopic surgery, has been used to repair adult DH with good results [18, 19, 20]. Laparoscopic approach was used in 3 of our patients, and one had to be converted to a laparotomy in view of dense adhesions. All three patients had good recovery, with quicker initiation of liquid and soft diet. But in cases of strangulation or perforation of the viscera, an urgent laparotomy is necessary for quicker access to the hernial sac and a better field of view.

Surgeries for DH are associated with many complications in the post-operative period and a multidisciplinary effort is required to ensure good lung recovery. Pulmonary atelectasis in the immediate postoperative period due to sudden re-expansion of the lung is an important complication to be remembered. A longer duration of ventilator support may be of help in maintaining proper alveolar expansion, as quick extubation in one of our patients eventually lead to widespread atelectasis and ARDS. Special caution needs to be practiced in known cases of CAD as they tend to be at a high risk of developing cardiac failure due to surgical stress, and CAD is an independent risk factor for venous thrombo-embolism. [21] This complicated the recovery of one of our patients, and ultimately was the cause of his death.

The strength of our study is the wide variety of diaphragmatic hernias that we have been able to manage and observe. We recommend clinicians adopt a higher degree of suspicion for diaphragmatic hernia in cases with vague abdominal or respiratory symptoms not responding to initial medical management. Once diagnosed, a surgical intervention should be performed on an urgent basis and one should not wait and rely only on conservative management. Two of our patients had been diagnosed with a DH 5 months prior to presenting to our institute with complications. While one of them was successfully managed, the other patient presented with severe complications and eventually succumbed to them. A larger, multi-centric trial is necessary to substantiate these recommendations and adopt them into routine clinical practice.

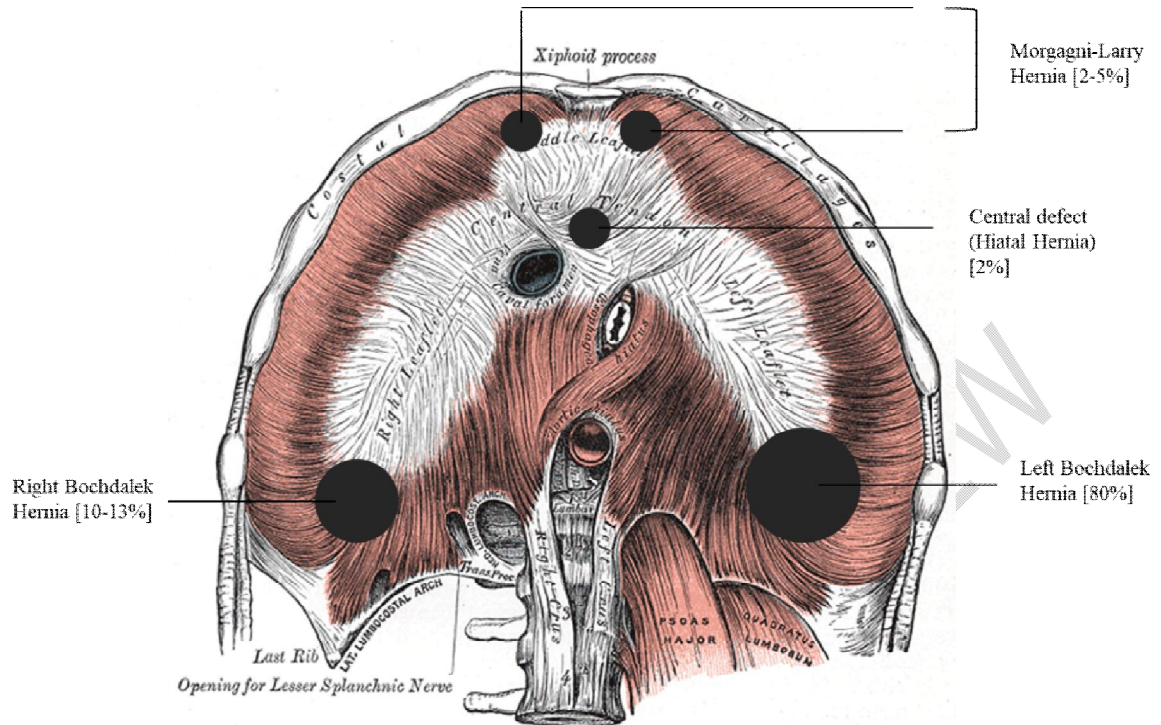


Figure 1: Types of Diaphragmatic hernia

4. CONCLUSION

Diaphragmatic hernias present a diagnostic and surgical challenge, but must be kept higher on the list of suspected diagnoses while assessing patients. There is no role of waiting once a diagnosis has been confirmed and must be followed promptly by a surgical intervention. Since screening for a rare disease such as DH is logistically impossible, clinical training should include identification of possible symptoms arising from an undiagnosed DH and how to manage such a case, including early referral to a higher centre. Patients need to be educated about risks of delayed treatment, and a good doctor-patient communication is required to avoid any "waiting period" and prevent morbidity and mortality.

CONSENT (WHERE EVER APPLICABLE)

All authors declare that 'written informed consent was obtained from the patient (or other approved parties) for publication of this case report and accompanying images. A copy of the written consent is available for review by the Editorial office/Chief Editor/Editorial Board members of this journal

REFERENCES

1. Zhou Y, Du H, Che G: Giant congenital diaphragmatic hernia in an adult. *J Cardiothorac Surg.* 2014, 9:31. 10.1186/1749-8090-9-31
2. Travaline JM, Cordova F. Agensis of the diaphragm. *The American journal of medicine.* 1996;100(5).

3. Killeen KL, Mirvis SE, Shanmuganathan K. Helical CT of diaphragmatic rupture caused by blunt trauma. *AJR. American journal of roentgenology*. 1999 Dec;173(6):1611-6.
4. Chughtai T, Ali S, Sharkey P, Lins M, Rizoli S (2009) Update on managing diaphragmatic rupture in blunt trauma: a review of 208 consecutive cases. *Can J Surg* 52:177–181
5. Furák J, Athanassiadi K. Diaphragm and transdiaphragmatic injuries. *Journal of Thoracic Disease*. 2019 Feb;11(Suppl 2):S152
6. Torfs CP, Curry CJ, Bateson TF, Honoré LH. A population -based study of congenital diaphragmatic hernia. *Teratology*. 1992;46:555–65.
7. Rashid F, Chakrabarty MM, Singh R, Iftikhar SY. A review on delayed presentation of diaphragmatic rupture. *World Journal of Emergency Surgery*. 2009 Dec;4(1):1-7.
8. Testini M, Girardi A, Isernia RM, De Palma A, Catalano G, Pezzolla A, Gurrado A. Correction to: Emergency surgery due to diaphragmatic hernia: case series and review. *World journal of emergency surgery: WJES*. 2019;14.
9. Warsinggih W, Uwuratuw JA, Arsyad A, Faruk M. A Strangulated Congenital Diaphragmatic Bochdalek Hernia Diagnosed in an Adult. *Case Reports in Medicine*. 2022 Jul 20;2022.
10. Cuschieri S. The STROBE guidelines. *Saudi journal of anaesthesia*. 2019 Apr;13(Suppl 1):S31.
11. Robin H Steinhorn MD. Pediatric congenital diaphragmatic hernia [Internet]. *Practice Essentials, Background, Pathophysiology*. Medscape; 2020 [cited 2022Dec27]. Available from: <https://emedicine.medscape.com/article/978118-overview#a6>
12. Bianchi E, Mancini P, De Vito S, Pompili E, Taurone S, Guerrisi I, Guerrisi A, D'Andrea V, Cantisani V, Artico M. Congenital asymptomatic diaphragmatic hernias in adults: a case series. *Journal of medical case reports*. 2013 Dec;7(1):1-8.
13. Furák J, Athanassiadi K. Diaphragm and transdiaphragmatic injuries. *Journal of Thoracic Disease*. 2019 Feb;11(Suppl 2):S152.
14. Swain JM, Klaus A, Achem SR, Hinder RA. Congenital diaphragmatic hernia in adults. In *Seminars in laparoscopic surgery* 2001 Dec (Vol. 8, No. 4, pp. 246-255). Sage CA: Thousand Oaks, CA: Sage Publications.
15. Spiridakis KG, Flamourakis ME, Gkionis IG, Kaloeidi EI, Fachouridi AI, Konstantoulaki SE, Tsagkatakis ES, Giakoumakis MI, Vassilogiannakis EA, Kostakis GE, Christodoulakis MS. Right-sided strangulating diaphragmatic hernia in an adult without history of trauma: a case report. *Journal of Medical Case Reports*. 2021 Dec;15(1):1-4.
16. Elhalaby EA, Abo Sikeena MH. Delayed presentation of congenital diaphragmatic hernia. *Pediatr Surg Int*. 2002;18:480–5.
17. Hosgor M, Karaca I, Karkiner A, *et al*. Associated malformations in delayed presentation of congenital diaphragmatic hernia. *J Pediatr Surg*. 2004;39:1073–6.
18. Rombolá CA, Genovés Crespo M, Tárraga López PJ, García Jiménez MD, Honguero Martínez AF, León Atance P, *et al*. Is video-assisted thoracoscopic diaphragmatic plication a widespread technique for diaphragmatic hernia in adults? Review of the literature and results of a national survey. *Cir Esp*. 2014;92:453–62.
19. Brown SR, Horton JD, Trivette E, Hofmann LJ, Johnson JM. Bochdalek hernia in the adult: demographics, presentation, and surgical management. *Hernia*. 2011;15:23–30.
20. Hietaniemi H, Järvinen T, Ilonen I, Räsänen J. Congenital diaphragmatic hernia in adults: a decade of experience from a single tertiary center. *Scandinavian Journal of Gastroenterology*. 2022 Jun 2:1-5.
21. Hong C, Zhu F, Du D, Pilgram TK, Sicard GA, Bae KT. Coronary artery calcification and risk factors for atherosclerosis in patients with venous thromboembolism. *Atherosclerosis*. 2005 Nov 1;183(1):169-74.