

Case study

Caecal volvulus: a fairly frequent emergency Of acute intestinal obstruction

Abstract:

The volvulus of the cecum is a surgical emergency, in frequency, the second part of the colon concerned by the volvulus after the sigmoid and before the transverse colon. This pathology occurs at the level of the cecum of an abnormal mobility.

The mechanism of this pathology can be summarized as: either by torsion or by tilting. The clinical picture is that of an acute intestinal occlusion by strangulation. The unprepared abdomen (ASP) and the abdominal CT scan are the radiological examinations of first choice for the diagnosis. This is a surgical emergency and the course of action is to perform an ileo-caecal resection. We report the case of a caecal volvulus admitted to the emergency room with an acute intestinal obstruction, the diagnosis was confirmed by an abdominopelvic CT scan and the treatment consisted of an ileocaecal resection with immediate restoration of continuity by anastomosis between ileum and colon, the postoperative course was simple.

Keywords: Twisted cecum Bowel obstruction Manual untwisting Resection and anastomosis

Introduction:

Caecal volvulus, first described by Rokitansky in 1837, is a condition that occurs in abnormally mobile caecal. The mechanism of volvulus is torsion or tilting. It is the second part of the colon concerned by volvulus after the sigmoid. It is responsible for 25-40% of all colonic volvulus

The clinical picture is that of an acute intestinal obstruction by strangulation. The clinical signs are not specific and the diagnosis may be delayed. Unprepared abdomen (UAP) and abdominal CT are the radiological examinations of first choice for diagnosis. The only effective treatment for cecal volvulus is surgical intervention.

We report the case of a cecal volvulus that was managed in the emergency department for cecal volvulus.

Case presentation:

The patient was 69 years old, followed for hypertension, admitted to the surgical emergency department with an acute intestinal obstruction with cessation of feces and gas, diffuse abdominal pain and bilious vomiting evolving abruptly for 4 days before the consultation. The clinical examination revealed: a distended abdomen, hypertympanic with diffuse abdominal sensitivity, the hernial orifices were free and the rectal ampulla was empty. The biological workup showed a hyperleukocytosis of $14810/\text{mm}^3$, a CRP of 13.8 mg/l , and normal renal function. The patient underwent an abdominal CT scan (Figure 1), which revealed a significant distension of the cecum estimated at 71 mm with individualized turn of the spiral, and a moderate amount of peritoneal effusion. The patient was operated on in the emergency department by median laparotomy with ileo-coecal resection and manual ileo-colic anastomosis. The patient was operated on in the emergency room, approached by laparotomy with the exploration we found a volvulated cecum realizing 1 turn of a spire in the anticlockwise direction (Figures 2,3), the patient had an ileocecal resection with manuaileocolic terminal-lateral anastomosis. anatomopathological examination of the surgical specimen showed haemorrhagic and oedematous changes with no specific lesion and no malignancy. The postoperative course was simple.

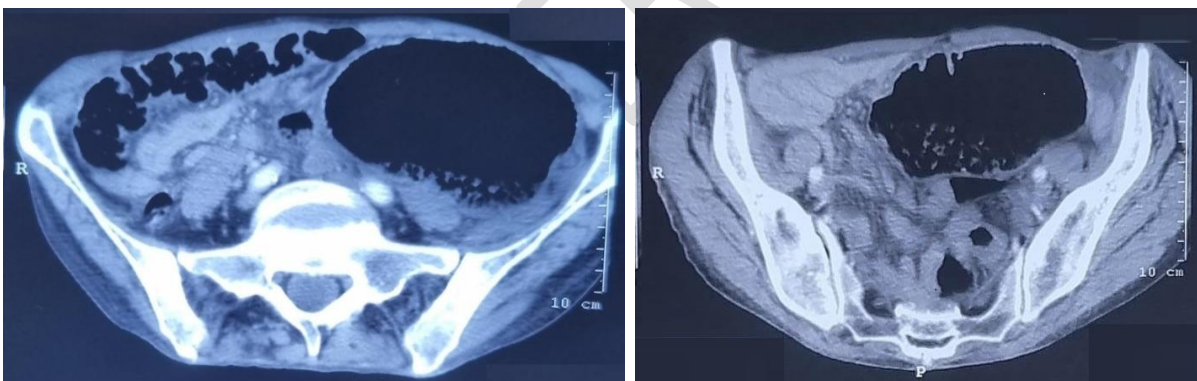


Figure 1: Transversal cut Abdominal CT.

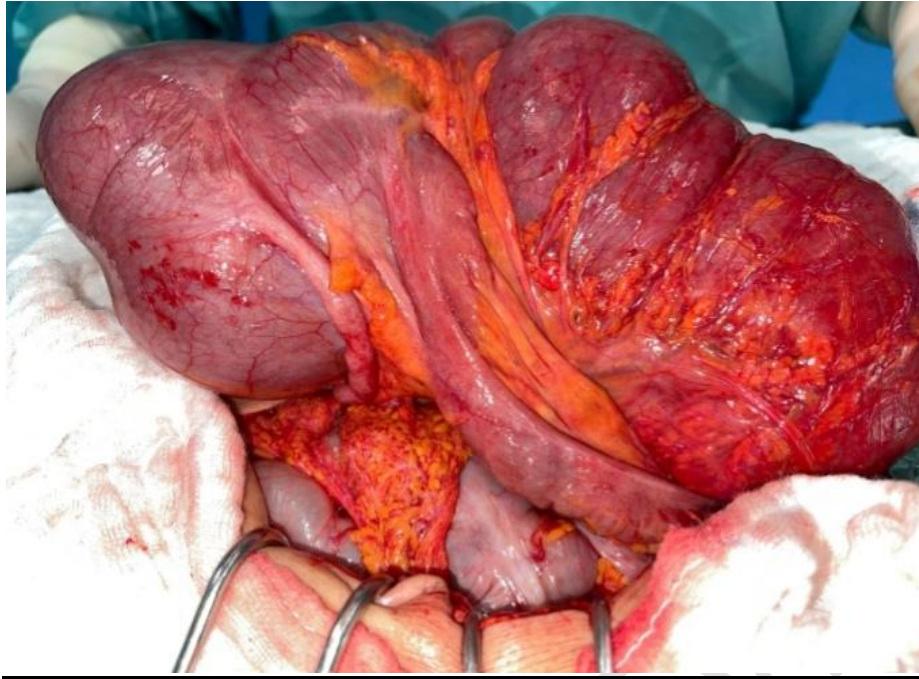


Figure 2 : Intraoperative view showing unfixed Cecum to the retroperitoneum after manual untwisting and Appendix

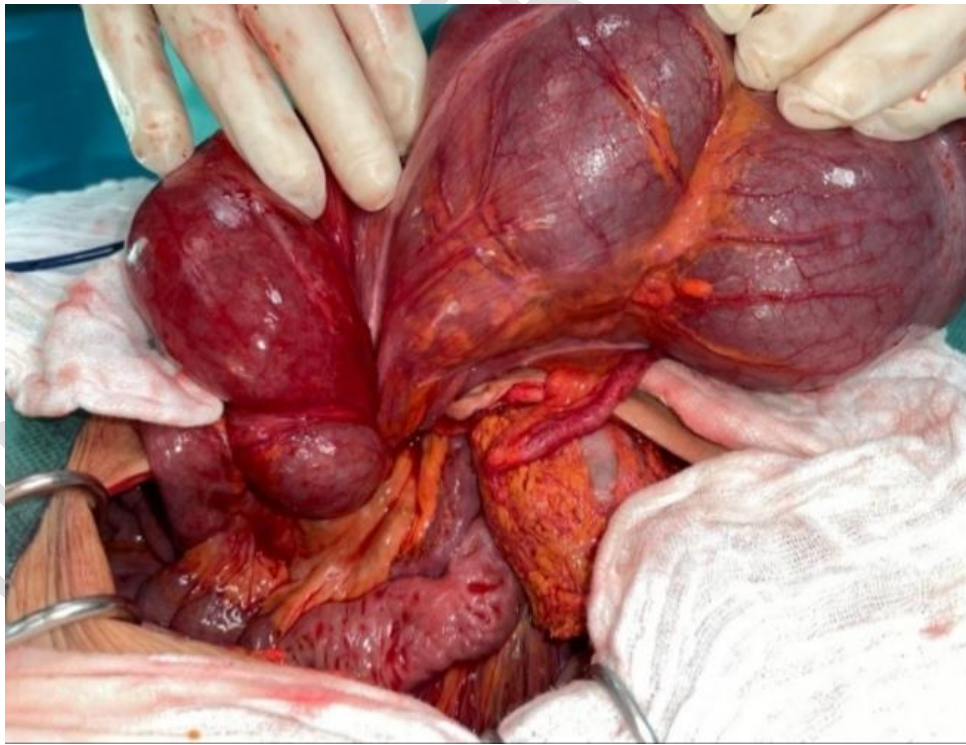


Figure 3 : After operative view showing

Discussion:

Caecal volvulus is a rare cause of colonic obstruction. It is the second part of the colon concerned by volvulus after the sigmoid and before the left angle and transverse colon and represents between 10 and 40% of all cases(1).

It is a torsion of the right colon around its mesenteric axis which is only possible if the proximal colon is mobile. Excessive mobility of the cecum is due to incomplete embryological rotation of the bowel or failure of the ascending colon to attach to the posterior parietal peritoneum(2) .

Various factors have been associated with the development of cecal volvulus, such as post-surgical adhesions, congenital malformations, Hirschsprung's disease or pregnancy. However, the literature mentions that unlike sigmoid volvulus, which develops in the elderly, cecal volvulus usually develops in younger patients especially in women(3) (4) (5).

Caecal volvulus is classified into 3 types:

- Type 1: This caecal volvulus is formed by axial clockwise torsion or long axis torsion of the cecum. The volvulus of the cecum is in the right lower quadrant.
- Type 2: This caecal volvulus develops from a counterclockwise torsion or twist of part of the cecum and part of the terminal ileum. The location of the cecum is in the left upper quadrant
- Type 3: Under the name caecal tilt it is the folding of the cecum. There is no axial torsion(6).

The clinic is that of an acute intestinal obstruction. The onset is often abrupt, marked by paroxysmal abdominal pain located in the right iliac fossa, the right flank, or the right hypochondrium before becoming generalized. Nausea, vomiting, and cessation of feces and gas are associated. Physical examination shows generalized or localized and asymmetric tympanic meteorism with painless pelvic touching(7).

Imaging allows the diagnosis. The unprepared abdominal film leads to the diagnosis in 70% of cases. A large hydroaerobic level is found, transversely located, lateralized to the left hypochondrium. The typical "coffee bean" image is found in half of the cases.

The CT scan is the reference examination to make the diagnosis. The sign of the "swirl" sign should be sought. It reflects abnormal stretching of the feeding mesenteric vessels associated with twisting turns of the right colon, cecum and ileum. In addition, this examination highlights the abnormal position of the cecum. The water-soluble enema shows an absence of opacification of the cecum while the rest of the colon is of normal diameter, the "bird's beak" stop of the contrast product can be found(7). It is no longer of any interest in emergencies at present. CT has replaced it because of its rapidity, sensitivity and the possibility of a complete study of the abdomen(8).

Colonoscopy as a diagnostic and therapeutic modality can be used in certain cases if the general condition of the patient allows it. It is less invasive than surgery (9). Its success rate is only 30% and given the risk of perforation.

It is generally accepted that the only effective treatment for caecal volvulus is surgical intervention. (10). When the cecum is viable, several fixation procedures are possible after detorsion: caecopexy, appendicostomy, caecostomy, and ileo-caecal resection. Isolated detorsion without fixation should be avoided because of the risk of recurrence. Caecopexy to the parietal peritoneum has variable success rates: 0 to 28% recurrence. Appendicostomy or caecostomy provides both colonic decompression and cecal fixation(4). In case of intestinal or gangrenous perforation, surgical resection by open or laparoscopic approach is inevitable. The choice between one-stage ileo-colic anastomosis and ileostomy with colostomy depends on local and/or general conditions(4,6).

Conclusion:

The volvulus of the cecum is a rare condition it occurs on a mobile cecum following an axial torsion of the cecum around its mesentery. The diagnosis is most often delayed due to non-specific clinical signs. Abdominal CT is the key examination for diagnosis. Diagnostic difficulties should not delay the surgical procedure. The choice of the operative technique is conditioned by the local condition of the colonic wall and the general condition of the patient. The prognosis is related to the terrain and the delay in diagnosis and treatment.

References :

1. Ramírez-Ramírez MM, Villanueva-Sáenz E, Ramírez-Wiella-Schwuchow G. Elective laparoscopic right colectomy for cecal volvulus: report of a case and review of the literature. *Cir Cir. Janv* 2017;85(1):87-92.
2. Mazine K, Elbouhaddouti H, Toughrai I, Mouaqit O, Benjelloun E, Ousadden A, et al. Volvulus du cæcum: a rare cause of intestinal occlusion: à propos de deux cas. *Pan Afr Med J [Internet]*. 2017 [I quoted May 19, 2022];28. Available south: <http://www.panafrican-med-journal.com/content/article/28/162/full/>
3. Pirró N, Corroller LE, Solari C, Merad A, Sielezneff I, Sastre B, et al. Volvulus du cæcum: bases anatomiques et physiopathologie. *Morphologie*. 2006 Dec 1;90(291):197-202.
4. Bougtab A, Amraoui M, Benchekroun BA, Echarrab M, Louchi MNA, Laaroussi M, et al. VOLVULUS DU COECUM. 1996;3.
5. Ruiz-Tovar J, Calero García P, Morales Castiñeiras V, Martínez Molina E. Caecal volvulus: presentation of 18 cases and review of literature. *Cir Esp Engl Ed. janv* 2009;85(2):110-3.
6. Sikakulya FK, Kiyaka SM, Masereka R, Onyai P, Okedi XF, Anyama P. Cecal volvulus in an adult male: A rare cause of intestinal obstruction: A case report. *Int J Surg Case Rep. août* 2021;85:106186.
7. Abita T, Lachachi F, Durand-Fontanier S, Maissonnette F, Roudaut PY, Valleix D, et al. Les volvulus du cæcum. *J Chir (Paris)*. juill 2005;142(4):220-4.
8. Breda R, Mathieu L, Mlynski A, Montagliani L, Duverger V. Volvulus du cæcum. *J Chir (Paris)*. 2006 Oct;143(5):330-2.
9. Hasbahceci M, Basak F, Alimoglu O. Cecal Volvulus. *Indian J Surg*. 2012 Dec;74(6):476-9.
10. Zabeirou AA, Belghali H, Souiki T, Ibn Majdoub K, Toughrai I, Mazaz K. Acute cecal volvulus: A diagnostic and therapeutic challenge in emergency: A case report. *Ann Med Surg*. Dec 2019;48:69-72.