

## Case study

# ADENOID CYSTIC CARCINOMA OF THE EXTERNAL AUDITORY: ABOUT A CASE

### Abstract

---

**Objective**—To describe a case of adenoid cystic carcinoma of the external auditory canal without bone lysis.

**Material and methods**—A 60-year-old female patient presented to our department with a stenotic mass in the external auditory canal that was progressively increasing in size over time, evolving for 5 years of incidental finding. The imaging, as well as the clinical and biological picture evoked a tumor of the external acoustic meatus, at the anapath a grade 2 adenoid cystic carcinoma was diagnosed.

**Results**—The treatment was surgical and the patient benefited from excision of the mass in one piece of the external auditory canal. A potent irradiation terminated the treatment. The suites were simple. The follow-up is 2 months without recurrence.

**Findings**—Adenoid cystic carcinoma of the external acoustic meatus is a rare malignant tumor whose diagnosis is often late. Due to their initial symptomatology similar to that of other benign conditions of the ear which makes their prognosis pejorative whose cure depends essentially on local control. Its metastatic potential justifies aggressive treatment.

**Comment [RP1]:** In Case reports, it is not necessary to put materials and methods. An unstructured abstract is appropriate for case reports. So, it is advised to rewrite the abstract.

---

### 1 Introduction

---

Carcinomas of the external auditory canal (EAC) and middle ear are rare. They represent less than 1% of malignant tumors of the head and neck (1). More than half of CAE carcinomas are squamous cell carcinomas (1, 2). Glandular origin is rarer, affecting mostly older adults. It is represented, in decreasing order of frequency, by adenoid cystic carcinoma (ACK) or cylindrome, adenocarcinoma, and mucoepidermoid tumors [3]. Non-specific and heterogeneous clinical symptoms are often responsible for late diagnosis. The advanced stages of these tumours, where metastases are frequent, complicate the therapeutic approach, which is not yet well codified.

**Comment [RP2]:** The short form for EAC does not match with External Auditory Canal.

---

### 2 Case Présentations

---

A 60-year-old patient, with no particular pathological history, in particular no immunosuppression factors, was referred for a mass in the external auditory canal of progressive installation, progressively evolving in size for 5 years, of incidental discovery associated with otalgia, tinnitus and persistent progressive hypoacusis, the clinical examination found a rounded and superinfected budding mass filling the entire external auditory canal the rest of the examination was

**Comment [RP3]:** More details on history

unremarkable, in particular no facial paralysis no retroauricular infiltration of the concha and pinna the ear, the ganglionic areas were free, forwards and downwards, no signs of extension to the temporomandibular joint (TMJ) or to the contents of the parotid compartment, nor to the skin of the cervico-parotid region.

**Comment [RP4]:** A significant number of grammatical errors and punctuation mistakes.

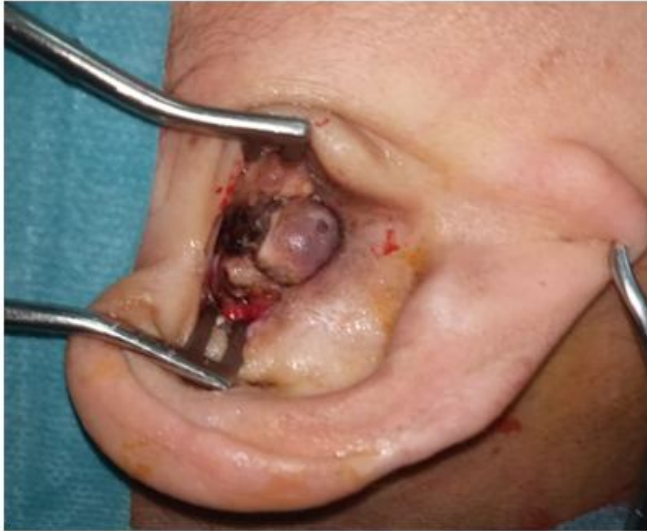

figure1 IMAGE OF A WELL-LIMITED ROUNDED MASS FILL-UP THE ENTIRE EXTERNAL AUDITORY CANAL

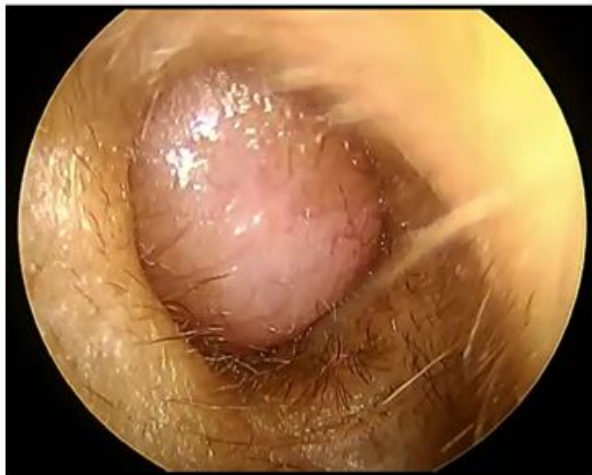

figure2 OTOSCOPY OF THE RIGHT EAR ROUND MASS FILL-UP THE ENTIRE EXTERNAL AUDITORY CANAL

A CT scan of the rocks was requested showing the presence of a tissue mass of the right external auditory canal with a well-limited tissue density coming into contact with the tympanic membrane without extension to the middle ear or bone lysis measuring 20\*12 mm.

**Comment [RP5]:** What does this mean? What form of CT scan is sent? HRCT???? Cuts???

**Comment [RP6]:** Incomplete finding descriptions

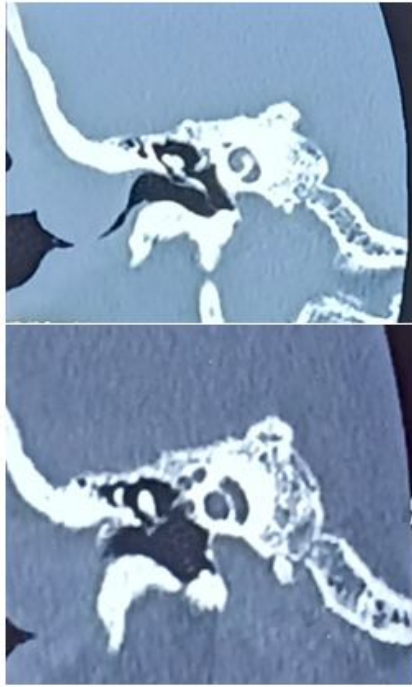


figure3 CT OF ROCKS IN CORONAL AND AXIAL CUTS MASS OCCUPYING THE EXTERNAL AUDITORY CANAL WELL LIMITED OF TISSUE DENSITY WITHOUT EXTENSION IN THE MIDDLE EAR NOR BONE LYSIS.

Comment [RP7]: Inappropriate terminologies

A biopsy of the mass was performed, concluding in the presence of a grade 2 adenoid cystic carcinoma without perineural sheathing or vascular emboli.

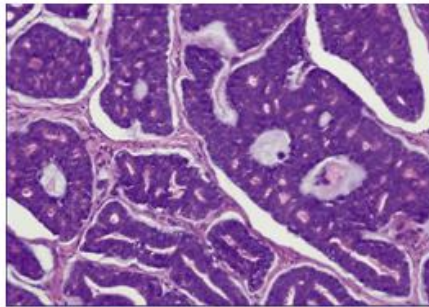


figure4 HISTOLOGICAL SECTION SHOWING INFILTRATION OF THE DUCT BY A CYSTIC ADENOID CARCINEMA WITH TUBULAR AND CRIBRIFORM ASPECTS.

As part of an extension assessment, a parotid ultrasound and a chest X-ray were requested, which did not reveal any abnormality. A one-piece resection of the mass was performed with anterior, posterior and internal resections. The post-operative follow-up was simple. The definitive histological examination concluded that there was an adenoid cystic carcinoma of the external auditory meatus with healthy surgical margins and no signs of malignancy at the anterior, posterior and internal resections. The multidisciplinary consultation meeting (RCP) recommended carrying out complementary radiotherapy. The initial hearing result was excellent. The follow-up is 2 months with no sign of recurrence.

Comment [RP8]: Pure Tone Audiogram???  
Missing or it is not done??

---

### 3 Discussion

---

Malignant tumors of the EAC and middle ear are rare. Due to their initial symptomatology similar to that of other benign ear diseases, they are frequently diagnosed at a late stage (2). There is a wide variety of histological types: carcinomas are the most frequent pathological forms (2); squamous cell carcinoma represents more than 50% (1, 4), and undifferentiated carcinoma is very exceptional. Generally, these carcinomas occur from the age of 50, and most often in men in most published series (2).

The integument of the external auditory canal covering the cartilage is thick and rich in hair follicles. It contains sebaceous glands (superficial) and ceruminous glands (deep) which are modified apocrine sweat glands. The mixture of secretions from the sebaceous glands and the ceruminous glands constitutes earwax. CAK is mainly found in the salivary glands, respiratory mucous membranes and lacrimal glands. More rarely, localizations in the breast, cervix, skin, Bartholin's and Cowper's glands are described. The histogenesis of this tumor is discussed. It is currently accepted that CAK comes from modified apocrine cells [5,6]. The histological diagnosis of these tumors requires a deep and large enough biopsy so as not to misunderstand the characteristics of this tumor [2,7,8]. Immunohistochemistry techniques can refine the diagnosis of CAK [8].

The diagnosis is evoked clinically in front of a suspicious tumor mass in the EAC, painful, ulcerated or budding, which may be associated with purulent otorrhea and paresis or facial paralysis. The biopsy confirms the histological diagnosis. It must be carried out in depth of the mass. There is no consensus regarding the performance of imaging for the staging assessment. The local assessment uses the scanner, more or less associated with an MRI. The remote assessment requires a chest X-ray or a chest CT scan. It is to be discussed on a case-by-case basis, depending on the location and tumor size. In our case, the normal chest X-ray. The pathophysiology of EAC and middle ear carcinomas remains poorly understood. Their etiological factors could be exposure to X-rays and ultraviolet rays, a history of chronic suppurative otitis media repeatedly caused by carcinogen-producing germs (*Aspergillus* and *Pseudomonas*), cholesteatoma and the use of chlorinated disinfectants (9, 10). EAC squamous cell carcinoma has a poor prognosis: the 5-year survival rate varies from 35 to 63% depending on whether or not the resection margins are affected and depending on the published series (10, 11). The poor prognostic factors are the T4 stage, the undifferentiated or poorly differentiated nature of the carcinoma, the presence of facial paralysis, invasion of the dura mater and distant metastases (9, 12). a history of chronic suppurative otitis media repeatedly caused by carcinogen-producing germs (*Aspergillus* and *Pseudomonas*), cholesteatoma and the use of chlorinated disinfectants (9, 10). EAC squamous cell carcinoma has a poor prognosis: the 5-year survival rate varies from 35 to 63% depending on whether or not the resection margins are affected and depending on the published series (10, 11). The poor prognostic factors are the T4 stage, the undifferentiated or poorly differentiated nature of the carcinoma, the presence of facial paralysis, invasion of the dura mater and distant metastases (9, 12). a history of chronic suppurative otitis media repeatedly caused by carcinogen-producing germs (*Aspergillus* and *Pseudomonas*), cholesteatoma and the use of chlorinated disinfectants (9, 10). EAC squamous cell carcinoma has a poor prognosis: the 5-year survival rate varies from 35 to 63% depending on whether or not the resection margins are affected and depending on the published series (10, 11). The poor prognostic factors are the T4 stage, the undifferentiated or poorly differentiated nature of the carcinoma, the presence of facial paralysis, invasion of the dura mater and distant metastases (9, 12). the 5-year survival rate varies from 35 to 63% depending on whether the edges of resection are affected or not and depending on the series published (10, 11). The poor prognostic factors are the T4 stage, the undifferentiated or poorly differentiated nature of the carcinoma, the presence of facial paralysis, invasion of the dura mater and distant metastases (9, 12). the 5-year survival rate varies from 35 to 63% depending on whether the edges of resection are affected or not and

depending on the series published (10, 11). The poor prognostic factors are the T4 stage, the undifferentiated or poorly differentiated nature of the carcinoma, the presence of facial paralysis, invasion of the dura mater and distant metastases (9, 12).

The therapeutic modalities with a curative aim for primary tumors are surgery, radiotherapy or a combination of the two. Chemotherapy is offered mainly for palliative purposes. Local recurrences are preferentially treated by brachytherapy (13). Regarding surgery, most authors agree that wide en bloc resection of the tumor with healthy surgical margins is the optimal and standard treatment for CAKs (11, 14). Depending on the stage of tumor extension, excision may consist of external petrectomy (stage T1, T2), subtotal (stage T3) or total (stage T4) [9, 13].

Parotidectomy is essential, because the parotid can be the site of recurrences and local invasions by tumor dissemination along the perineurium of the facial nerve[15]. Dissection of the homolateral cervical lymph node is discussed by some authors because it would not change the locoregional prognosis due to the low lymphophilia of the CAK of the MAE. Selective hollowing out can be discussed on a case-by-case basis, depending on tumor extension. In our case, the tumor was at a localized stage without signs of clinical radiological or pathological extension. We decided to perform a large single-block resection of the tumor with respect for the surgical margins.

Complementary radiotherapy is not indicated in case of wide resection with healthy margins[15]. The effectiveness of postoperative radiotherapy in the control of tumors with residual lesions at the edges of resection is widely proven. It is sometimes used exclusively in early tumors limited to EAC, but most often it follows surgery for stages T2, T3 and T4 (16). The irradiation doses vary depending on whether or not there is damage to the edges of the resection: a dose of 54 to 60 Gy is delivered in the event of radical resection; if the margins are invaded, irradiation is done at a dose of 66 Gy or more (11). Brachytherapy can control a locally advanced or recurrent tumour, while avoiding the complications of external radiotherapy (13, 11). The combination of chemotherapy and radiotherapy has recently been tried by some authors with the aim of obtaining healthy surgical margins (11). Exclusive chemotherapy is indicated for palliative purposes for advanced stages of the tumor (T4) and in the event of distant metastases. The combination of 5-FU and cisplatin seems to be the most suitable protocol for CAE carcinoma (9).

EAC squamous cell carcinoma has a poor prognosis: the 5-year survival rate varies from 35 to 63% depending on whether or not the resection margins are affected and depending on the published series (10, 11). The prognosis of EAC CAK depends on local resection margins, bone invasion, initial parotid involvement, and nerve invasion.[3.15]stage T4, undifferentiated or poorly differentiated character of the carcinoma, presence of facial paralysis, invasion of the dura mater and distant metastases (9, 11). The localization of the CAK at the external acoustic meatus increases the aggressiveness of this tumour. The risk of recurrence by its metastatic power is estimated at 30% according to some authors[5]. Secondary locations are mainly pulmonary, but also bone, kidney and brain[17].

In the literature, the diagnosis of primary cutaneous CAK can only be considered after having strictly eliminated a cutaneous extension of a tumor developed in a neighboring structure or a distant metastasis of a salivary CAK.[18].

**Comment [RP9]:** The significance of findings is missing.

---

#### 4 Conclusion

---

Undifferentiated carcinomas of the EAC are extremely rare, often diagnosed at a late stage when the tumor has already invaded the EAC and the middle ear simultaneously. The diagnosis is based on histological examination optimized by a deep and wide biopsy. The treatment is above all surgical with an excision which must be large, total from the outset and sometimes radical. The particularity of CAKs is their nervous tropism. It is important to combine the excision procedure with a parotidectomy with dissection of the facial nerve, in order to control any possible dissemination

along the perineurium of this nerve. Cervical lymph node dissection should be discussed given the low lymphophilia of this tumour. The rapid evolution and the early and distant metastases make it a tumor with a very poor prognosis. Complementary external radiotherapy is indicated according to most authors in order to reduce the risk of local recurrence, which remains the primary prognostic factor. Treatment is difficult and must be aggressive. It involves surgery followed by radiotherapy. Chemotherapy can only be used for palliative purposes at the metastatic stage.

## REFERENCES

1. Magliulo G, Fusconi M, Pulice G. Mucoepidermoid carcinoma of the external auditory canal – case report. *Am J Otolaryngol* 2003; 24:274-7.
2. Lobo D, Llorente JL, Suárez C. Squamous cell carcinoma of the external auditory canal. *Skull base* 2008;18:167-72
3. Dehesdin D, Andrieu-Guitrancourt J, Hemet J, Cauchois P, Marie JP, Vinel V. Glandular tumors of the external auditory canal. *Ann Otolaryngol Chir Cervicofac* 1993;110:70-4.
4. Thevarajah S, Carew J, Selesnick SH et al. Bilateral squamous cell carcinoma of the external auditory canal. *Otolaryngol Head Neck Surg* 2005;132:960-2.
5. Wassef M, Thomas V, Deffrennes D, Lacau Saint-Guilly J. Primary cutaneous adenoid cystic carcinoma. *Ann Pathol* 1995;15:150-5.
6. Fenniche S, Haouet S, Mdimagh H, et al. Tumors of the ceruminous glands. *Ann Pathol* 1995;15:147-9.
7. Lassaleta L, Patron M, Oloriz J, Perez R, Gavilan J. Avoiding misdiagnosis in ceruminous gland tumor. *Auris Nasus Larynx* 2003;30:287-90.
8. Hicks GW. Tumors arising from the glandular structures of the external auditory canal. *Laryngoscope* 1983; 93:326-40.
9. Schmerber S, Righini Ch, Soriano E et al. Results of treatments for malignant tumors of the external auditory canal. *RevLaryngolOtolRhinol (Edge)* 2005;126:165-70.
10. Thevarajah S, Carew J, Selesnick SH et al. Bilateral squamous cell carcinoma of the external auditory canal. *Otolaryngol Head Neck Surg* 2005;132:960-2
11. Ogawa K, Nakamura K, Hatano K. Treatment and prognosis of squamous cell carcinoma of the external auditory canal and middle ear: a multi institutional retrospective review of 87 patients. *Int J Radiat Oncol Biol Phys* 2007; 68:1326-34.
12. Lobo D, Llorente JL, Suárez C. Squamous cell carcinoma of the external auditory canal. *Skull base* 2008;18:167-72
13. Pfreundner L, Schwager K, Willner J et al. Carcinoma of the external auditory canal and middle ear. *Int J Radiat Oncol Biol Phys* 1999;44:777-88
14. Madsen AR, Gundgaard MG, Hoff CM et al. Cancer of the external auditory canal and middle ear in Denmark from 1992 to 2001. *Head Neck* 2008;30:1332-8
15. Perzin KH, Gullane P, Conley J. Adenoid cystic carcinoma involving the external auditory canal. A clinicopathologic study of 16 cases. *Cancer* 1982; 50:2873-83.
16. Pemberton LS, Swindell R, Sykes AJ. Primary radical radiotherapy for squamous cell carcinoma of the middle ear and external auditory canal – an historical series. *Clin Oncol (R Coll Radiol)* 2006;18:390-4.
17. Conlin P, Mira JL, Graham S, Kaye KS, Cordero J. Ceruminous gland adenoid cystic carcinoma with contralateral metastasis to the brain. *Arch Pathol Lab Med* 2002; 126:87-9.
18. Bassereau G, Brasnu D, Roux FX, Menard M, Laccourreye H. Primary carcinoma of the external auditory canal and middle ear (about 14 cases). *Ann Otolaryngol Chir Cervicofac* 1989;106:169-75.