

**Diffuse large B cell lymphoma of the maxilla. A rare case report
emphasizing differential diagnosis of maxillary involvement.**

ABSTRACT

Aims: Report a rare case of Diffuse large B cell lymphoma (DLBCL) of the maxilla which is difficult to diagnose clinically and radiographically with a wide array of differential diagnosis lists.

Presentation of case: A case of a 16-year male with well-defined swelling in the posterior region of the **right maxilla** associated with pain, paraesthesia, and **abnormal mobility** of teeth which mimicked **a** localized periodontal abscess. The clinical diagnosis of DLBCL poses a challenge opening a wide array of false diagnostic impressions.

Discussion: Traditionally lymphoma is classified into Hodgkin's (HL) and non-Hodgkin's lymphoma (NHL) and NHL involves the extra-nodal site including the gastrointestinal tract, central nervous system, skin **as well as** in the head and neck area involving waldeyer's ring, buccal mucosa, tongue, maxilla, and mandible

Conclusion: The diagnosis of DLBCL may get delayed with a wide range of differentials in the jaw. A false diagnosis like periapical pathology or other benign lesions would delay the treatment plan. Clinically any lesion suspicious of malignancy in the jaw requires the attention of clinicopathological and radiographic correlation with special diagnostic techniques like immunohistochemistry.

Keywords – **maxillary tumours**, *B cell lymphoma, diagnosis, non-Hodgkin's lymphoma,*

INTRODUCTION

Lymphomas are **second** most common malignant tumours and are categorized into Hodgkin's and non-Hodgkin's lymphoma (NHL). It represents 3.5% of all intraoral malignancies and is commonly seen in the sixth to the seventh decade **of life** with men's predilection.^[1] Diffuse large B cell lymphoma is the most common tumour of NHL and it can be subcategorized by gene expression profiling into germinal center B cell-like (GCB) and activated B cell-like (ABC type or non-GCB) subtypes.^[2] Our case was documented in the non-GCB subtype of DLBCL. In the oral cavity, the non-NHL is relatively very rare and most commonly occurs in the gingiva followed by the hard palate, and in the head-neck region in the palatine tonsil followed by the parotid gland.^[3] The aetiology of DLBCL is still uncertain but associated predisposing factors include human T cell lymphotropic virus (HTCL-1), Epstein-Barr virus (EBV), human immunodeficiency virus (HIV), human herpes virus (HHV-8), and hepatitis B and C. **some** microorganism **implication has been suggested** including chlamydia and helicobacter pylori.^[4]

Genetic mutation with overexpression B cell surface markers like CD45, CD20, CD3, and KI67 along with genetic rearrangement of c-MYC and BCL-2 and/or BCL-6 have DLBCL and BCL-2 and /or BCL- 6 are considered as double hit or triple hit hypothesis.^[5] In this case overexpression B cell surface markers i.e., CD45, CD20, CD3, and KI67 were observed. DLBCL, a diagnostic workup is aided by cell surface marker expression. Also, 60% of DLBCL patients can be **medically treated** by using R-CHOP therapy (rituximab, cyclophosphamide, doxorubicin, vincristine, and prednisone).^[2] Early diagnosis of lymphoma in the jaw gives prognostic treatment value with an increased disease-free survival rate. But clinician faces a challenge in the diagnosis of DLBCL, as benign odontogenic and non-odontogenic cyst and tumour, periapical pathology, and salivary gland tumour **difficult the differential diagnosis**. This differential list is ruled out by histopathological and immunohistochemistry techniques **plus with** the clinicopathological correlation.^[3] Here we discuss clinical and radiographical features which mimic the cyst and **the** tumour of DLBCL.

CASE REPORT

A 16-year-old male presented in the oral medicine and radiology department with complaints of pain, swelling, and abnormal mobility in the upper right posterior region of the jaw over fifteen days. The history had revealed that swelling was insidious at the onset and gradually increases, so the patient reported to the local dentist and got prescribed antibiotics and analgesics. But the patient did not get relief instead the patient noticed an abnormal mobility in the 14,15,16,17 regions. There was no trauma history and family, medical, and personal history were non-contributory.

On general examination, there were no significant findings. On extra oral examination, no gross facial asymmetry was seen or facial palsy was seen. On palpation, tenderness was present in the right malar region, and no lymph node was palpable in the cervicofacial region. (Figure -1A)

Intraoral examination revealed, diffuse swelling in the palatal region on the right side associated with grade 2 mobility of teeth 14,15,16,17. On palpation, the swelling was soft to firm in consistency and tender. (Figure-1B) The provisional diagnosis was a periodontal abscess with 14,15,16,17, region and the differential diagnosis was a pleomorphic adenoma, mucoepidermoid carcinoma, ossifying fibroma, periapical abscess, and others cyst and tumours

To rule out pathology the patient has realized computed tomography (CT) and orthopantomogram (OPG). OPG was revealed that ill-defined radiolucency was seen in apical regions of the 14,15,16,17 regions which extend superoinferiorly from the infraorbital margin to the alveolar process on the right side and mesiodistally from the apical region distal surface of 14 to mesial surface 18 regions.

The effect of surrounding structure includes loss of lamina dura in premolars and molars regions and loss of inferior, medial, and posterior borders of the maxillary sinus. Internally the lesion was partially a looking mix of radiopaque and radiolucent structures. (Figure -2A and 2B)

CT revealed that a well-defined hypodense lesion was present in the right maxillary sinus with the destruction of the anterior and posterior walls. Medially thinning and medial displacement of the medial wall of the sinus in the right nasal cavity and compression of the middle and inferior turbinate. Superiorly, eroding floor right orbit, anteriorly extending into the premaxillary subcutaneous tissue, posteriorly retro antral and pterygopalatine fossa, inferiorly eroding the upper alveolar arch in the premolar and molar region and nasal septum deviated to the left side. (Figure-2B)

Radiographically, the image was suggestive of Ewing sarcoma and the differential diagnosis list included Langerhans cell histiocytosis, osteomyelitis, osteolytic osteosarcoma, fibrosarcoma another benign lesion including fibro-osseous lesion, adenomatoid odontogenic tumour, and calcifying odontogenic tumour.

Histopathological examination revealed the presence of some bone trabeculae showing lacunae with osteocytes and sheets of small uniform, basophilic

neoplastic round cells separated by fibrovascular septae. Diffuse chronic inflammatory cell infiltrate chiefly that of lymphocytes and plasma cells were seen. Suggestive of small round cell tumour (Figure 3).

Due to its aggressivity the sample was sent for immunohistochemistry study. It revealed positivity for markers including CD20, CD45, CD3, Ki67, BC2, and BCL6 with genetic rearrangement (Table-1). The final diagnosis of DIFFUSE LARGE B CELL LYMPHOMA was made with the immunohistochemistry and the clinicopathological correlation.

This case was treated surgically with resection of the tumour and the tissues involved and curettage of the right maxillary sinus region (Figure-4A and 4B). The reconstruction was made with local flaps. The patient was sent for complementary treatment with radiotherapy. Postoperative was successful with no postsurgical complications and good healing of tissue (Figure-5A, Figure-5B). Six months later, there was no clinical or radiological recurrence.

DISCUSSION

Lymphomas are malignant neoplasms of lymphocytes and their precursor cells. Freeman et al reported 28% of extra-nodal sites of NHL in the head and neck area and 2% in the oral cavity.^[6] Traditionally lymphoma is classified into Hodgkin's (HL) and non-Hodgkin's lymphoma (NHL) and NHL involves the extra-nodal site including the gastrointestinal tract, central nervous system, and skin as well as in the head and neck area involving Waldeyer's ring, buccal mucosa, tongue, maxilla, and mandible.^[7]

The DLBCL of the jaw and maxilla is difficult to diagnose due to clinical and radiographic features which are not specific to NHL. The clinically differential diagnosis of maxillary swelling includes salivary gland tumour, pyogenic granuloma, periapical abscess, fibroma, lymphoid hyperplasia, and peripheral osteoma.^[8]

Pleomorphic adenoma is most common salivary gland tumour. It developed on the palate, with slow growing, asymptomatic, soft to firm in consistency, and is more common in females patients in the 4th to 6th decade of life. Our case is highly aggressive, symptomatic, with mobility of teeth and in younger age.^[9]

Pyogenic granuloma has the presence of nodular or sessile lobulated swelling which is in gingival origin and is most commonly seen in pregnant women due to high levels of oestrogen. In our case, swelling was diffuse.^[10] A palatal abscess is typically seen as a palatal diffuse swelling originating from the source of pulpal and periodontal tissue associated with a nonvital tooth and it is a purely odontogenic origin.^[11] In our case possibility, all teeth were vital (pulp vitality test positive) and the swelling was of bony origin.

Fibroma of the palate typically is asymptomatic slow growing sessile or pedunculated swelling commonly on gingiva associated with local irritation or history of trauma. In our presented case showing painful diffuse swelling without a history of trauma.^[12]

Peripheral osteoma shows firm to bony hard swelling usually asymptomatic sessile growth with facial asymmetry seen. In our case the swelling was painful and soft to firm in consistency to easily rule out peripheral osteoma.^[13]

World health organization (WHO) 2022 5th edition made diagnostic criteria, the diagnosis of DLBCL can be ruled out by differentiating the benign odontogenic and non-odontogenic tumour based on age, gender, and location of lesions. A calcifying odontogenic tumour is more common in the 4th decade, with no gender predilection and the principal location is the body of the mandible. Adenomatoid odontogenic tumour is more common in the 2nd to 3rd decade and in the anterior maxilla. Complex odontoma in the posterior body of the mandible and compound odontoma in the anterior region of maxilla, both are more common in the 2nd to 3rd decade with no gender predilection. A radicular cyst is

commonly seen in the 4th to 5th decade, slightly more common in males and in the anterior maxilla associated with non-vital teeth.^[14]

We exclude all, presenting the case using the above diagnostic criteria, as diffuse swelling in the posterior region of the hard palate at a younger age has the radiographical feature of malignant lymphoma. The radiographical picture characteristically was showing ill-defined radiolucency with severe bone resorption if involved in the maxilla and mandible. It extends into the maxillary sinus and the alveolar process leads to the mobility of teeth. If mandible involvement is seen, the resorption is mostly seen in buccal cortical bone.^[15]

Radiographically differential diagnosis was made with other lesions including Ewing sarcoma, and osteomyelitis of the jaw. Ewing sarcoma shows mottled and ill-defined radiolucency expansile bony destructive lesion with onion skin periosteal reaction. Ewing sarcoma shows a mix of radiopaque and radiolucent images in the maxilla and mandible.^[16]

Osteomyelitis also mimics the lesion and extensive destruction of the maxilla and mandible. Our presented case shows radiographically extensive destruction of the maxillary sinus associated with radiopacity internally and bony expansion extending up to the infraorbital margin.^[17]

The diagnosis of DLBCL is based on clinical, morphological, radiographic, and histopathological examination. The first line therapy of treatment of DLBCL is CHOP (cyclophosphamide, hydroxy doxorubicin, oncovin, and prednisolone). The early stage of DLBCL is managed by both combinations of chemotherapy and radiotherapy.^[6]

CONCLUSION- The diagnosis of DLBCL is difficult and may get delayed because a wide range of differentials diagnostic in the jaws bone. A false diagnosis like periapical pathology or other benign lesions would delay the treatment plan. Clinically any lesion suspicious of malignancy in the maxillary bone requires the attention of clinicopathological and radiographic correlation with special diagnostic techniques like immunohistochemistry.

Consent

As per international standard or university standard, parental(s) written consent has been collected and preserved by the author(s).

Ethical Approval:

As per international standard or university standard written ethical approval has been collected and preserved by the author(s).

Acknowledgement

Nil

References

1. Liu K, Gao Y, Han J, Han X, Shi Y, Liu C, et al. Diffuse Large B-Cell Lymphoma of the Mandible Diagnosed by Metagenomic Sequencing: A Case Report. *Front Med (Lausanne)*. 2021;8:752523.
2. Sehn LH, Salles G. Diffuse Large B-Cell Lymphoma. *N Engl J Med*. 2021 Mar 4;384(9):842–58.
3. Bugshan A, Kassolis J, Basile J. Primary Diffuse Large B-Cell Lymphoma of the Mandible: Case Report and Review of the Literature. *Case Rep Oncol*. 2015 Dec;8(3):451–5.
4. Jayapalan CS, Pynadath MK, Mangalath U, George A, Aslam S, Hafiz A. Clinical diagnostic dilemma in an uncharacteristic rapidly enlarging swelling of the anterior maxilla: extranodal diffuse large B cell lymphoma. *BMJ Case Rep*. 2016 Mar 30;2016:bcr2015213141.
5. Liu Y, Barta SK. Diffuse large B-cell lymphoma: 2019 update on diagnosis, risk stratification, and treatment. *Am J Hematol*. 2019 May;94(5):604–16.
6. Coskunes FM, Cilasun Ü, Celik Topcu P, Tokuc B. Primary diffuse large B-cell lymphoma of the mandible: A case report. *Gerodontology* 2020 Sep;37(3):307-311 DOI: [10.1111/ger.12470](https://doi.org/10.1111/ger.12470)
7. Zou H, Yang H, Zou Y, Lei L, Song L. Primary diffuse large B-cell lymphoma in the maxilla: A case report. *Medicine (Baltimore)*. 2018 May;97(20):e10707.
8. Ozden B, Bas B, Duran H, Celenk P, Gunhan O. Arteriovenous malformations in the differential diagnosis of palatal swellings. *J Istanbul Univ Fac Dent*. 2016; 50(1): 55–58 doi: [10.17096/jiufd.86859](https://doi.org/10.17096/jiufd.86859)

9. Yousra Z, Saliha C. Pleomorphic adenoma of hard palate: a case report. *Pan Afr Med J.* 2021;38:146.
10. Amirchaghmaghi M, Falaki F, Mohtasham N, Mozafari PM. Extralingival pyogenic granuloma: a case report. *Cases J.* 2008 Dec 3;1(1):371.
11. Sumer A, Celenk P. Palatal Abscess in a Pediatric Patient: Report of a Case. *European journal of dentistry.* 2008 Nov 1;2:291–3.
12. Tsikopoulos A, Festas C, Fountarlis A, Sidiropoulou V, Chaitidis N, Symeonidis A, et al. Large irritation fibroma of hard palate: a case report of a rare clinical entity. *Pan Afr Med J.* 2021; 38: 61 doi: [10.11604/pamj.2021.38.61.27662](https://doi.org/10.11604/pamj.2021.38.61.27662)
13. Cincik H, Gungor A, Ertugrul E, Cekin E, Dogru S. Peripheral osteoma of the mandible mimicking a parotid mass. *Eur Arch Otorhinolaryngol.* 2007 Apr;264(4):429–31.
14. Soluk-Tekkesin M, Wright JM. The World Health Organization Classification of Odontogenic Lesions: A Summary of the Changes of the 2022 (5th) Edition. *Turk Patoloji Derg.* 2022;38(2):168–84.
15. Yasuyuki Michi, Hiroyuki Harada, Yu Oikawa, Kohei Okuyama, Takuma Kugimoto, Takeshi Kuroshima et al. Clinical manifestations of diffuse large B-cell lymphoma that exhibits initial symptoms in the maxilla and mandible: a single-center retrospective study - *BMC Oral Health.* 2022; 22: 20. doi: [10.1186/s12903-022-02056-x](https://doi.org/10.1186/s12903-022-02056-x)
16. Ahuja US, Puri N, Gupta D, Singh S, Kumar G. Ewing's Sarcoma of Mandible: A Case Report with Review. *International Journal of Clinical Pediatric Dentistry,* Volume 12 Issue 5 (September–October 2019) doi: [10.5005/jp-journals-10005-1665](https://doi.org/10.5005/jp-journals-10005-1665)
17. Nilesh K. Extensive maxillary osteomyelitis following tooth extraction in a patient with osteopetrosis. *BMJ Case Rep* 2020;13:e235091. doi: [10.1136/bcr-2020-235091](https://doi.org/10.1136/bcr-2020-235091)

IMMUNOHISTOCHEMISTRY MARKERS	RESULT
---------------------------------	--------

Tables

Table -1 immunohistochemistry markers and result

CD45	Immunoreactive, score +4 in lesional cells
CD3	Immunoreactive, score +1 in reactive T cell
CD 20	Immunoreactive, score+3 in neoplastic b cell
KI67	60 to 70% proliferation index
BCL2	Immunoreactive, score+3 in neoplastic b cell
BCL6	Immunoreactive, score+3 in neoplastic b cell
MUM1	Immunoreactive, score+3 in neoplastic b cell
INTERPRETATION	
RESULT	SCORE
NON IMMUNOREACTIVE	0
IMMUNOREACTIVE IN 1-25% CELL	1+
IMMUNOREACTIVE IN 26-50% CELL	2+
IMMUNOREACTIVE IN 51-75% CELL	3+
IMMUNOREACTIVE IN 76-100% CELL	4+

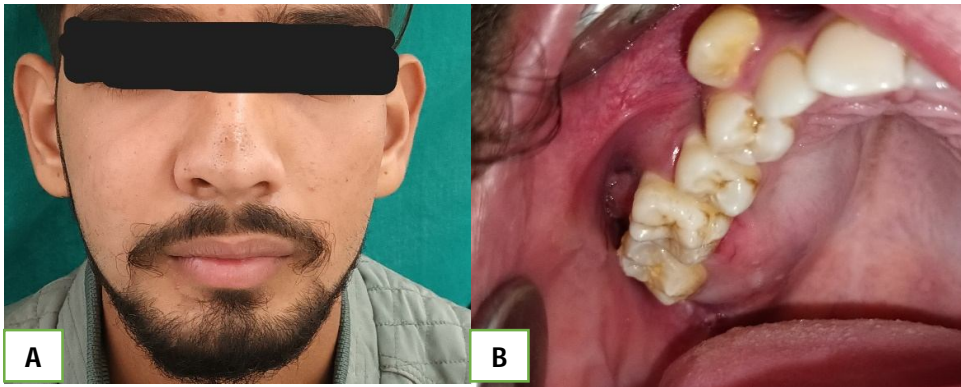


Figure 1: A – The image shows no gross facial asymmetry or any erythematous surface seen on the right malar region. **B-** Diffuse swelling with obliteration of buccal vestibule and mild erythematous surface in the palatal region on the right side associated 14,15,16,17 teeth regions of the maxillary jaw

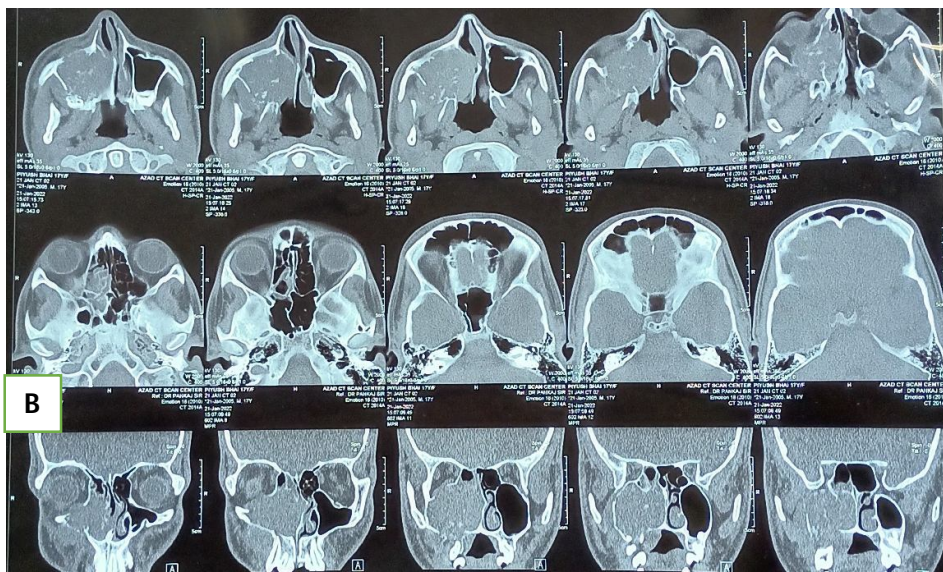
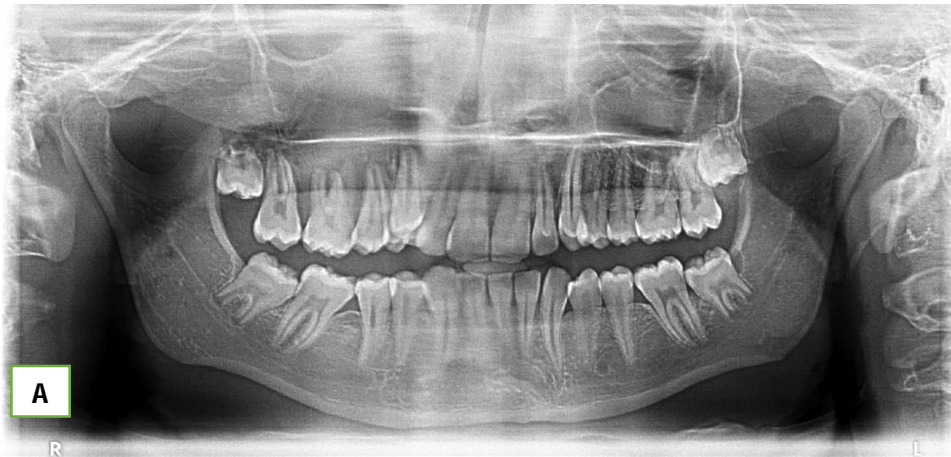

Figure 2: A- The image shows ill-defined radiolucency with the apex of 14,15,16,17 teeth regions. extend superoinferiorly from the infraorbital margin to the alveolar process and mesiodistally from the apical region distal surface of 14 to mesial surface 18 regions. The effect of surrounding structure includes loss of lamina dura in premolars and molars regions and loss of inferior, medial, and posterior borders of the maxillary sinus. **B-** Well-defined hypodense lesion was present in the right maxillary sinus with the destruction of the anterior and posterior walls. Medially thinning and medial displacement of the medial wall of the sinus in the right nasal cavity and compression of the middle and inferior turbinate. Superiorly, eroding floor right orbit, inferiorly eroding the upper alveolar arch in premolar and molar region and nasal septum deviated to the

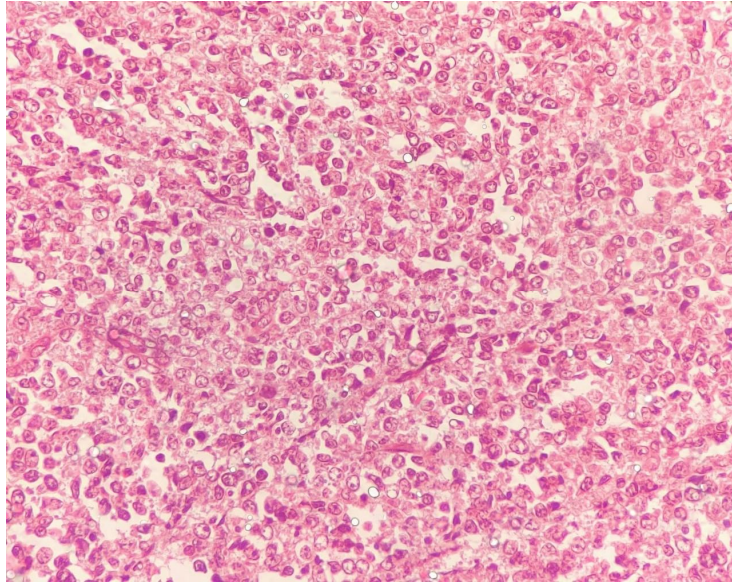
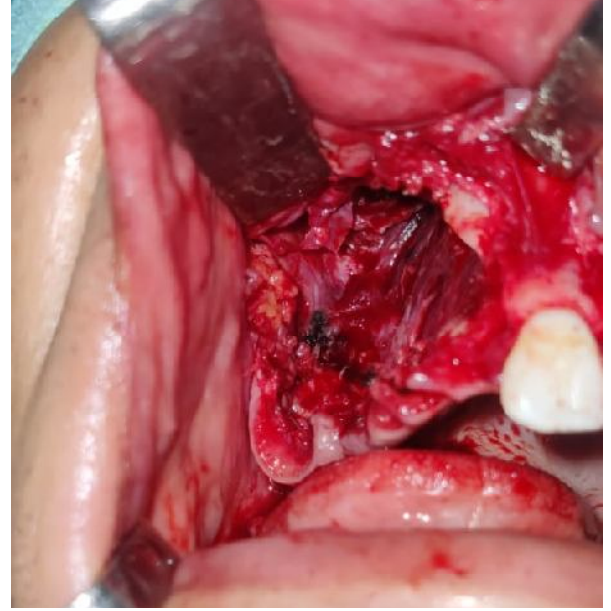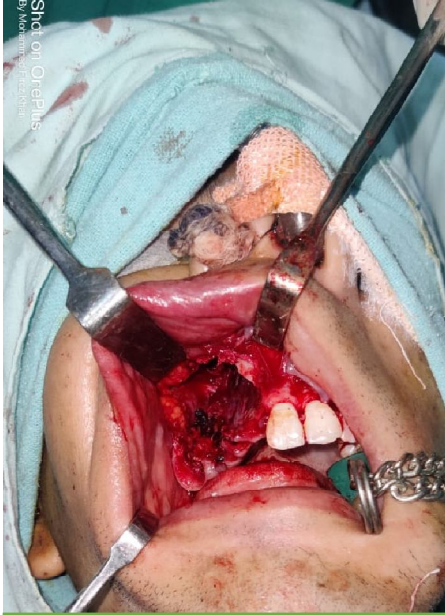
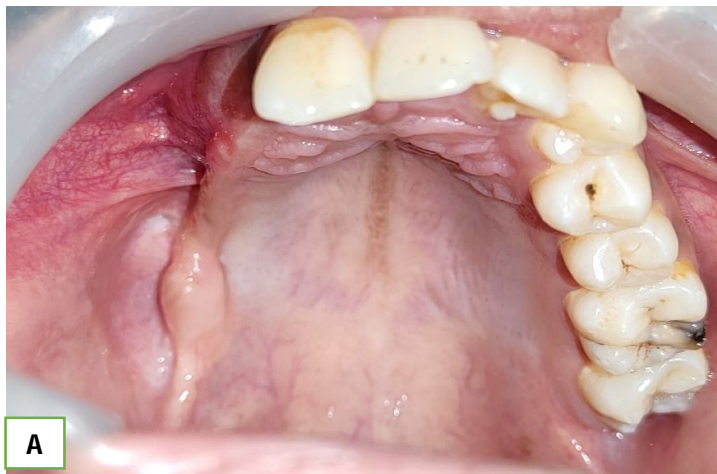


Figure 3 -Histopathological examination revealed the presence of many bone trabeculae showing lacunae with osteocytes and sheets of small uniform, basophilic neoplastic round cells separated by fibrovascular septae. Diffuse chronic inflammatory cell infiltrate chiefly that of lymphocytes and plasma cells are seen. Suggestive of small round cell tumor



Figures -4: A AND B intra operative image showing the resection of tumour mass of right maxilla under general anaesthesia

B



A

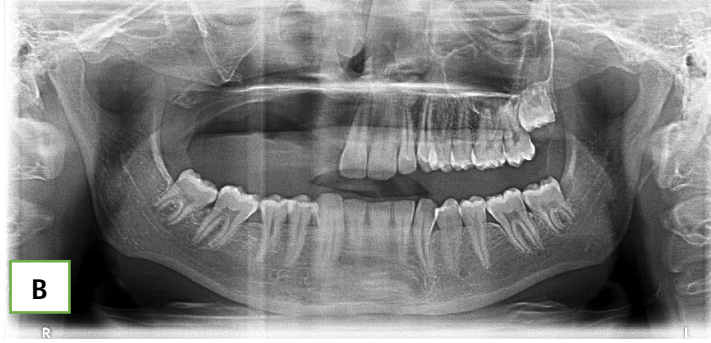

Figure 5: **A-** Image shows post-surgical with good healing of tissue on the right side of the palate **B** – Post-surgical OPG images show good healing of bone