

Case report

Tuberculous osteomyelitis of mandible in a young child– A diagnostic dilemma

Abstract

Aims: To report a case of Tuberculous osteomyelitis of mandible in a young child and highlights the difficulties in establishing diagnosis with clinical and cone beam computed tomography (CBCT) imaging findings. **Presentation of Case:** A case of 8-year old child with osteomyelitis of the mandible who presented with diffuse swelling of the cheek without the evidence of any active primary foci of tuberculosis. On the basis of clinical findings and radiographic analysis, antitubercular therapy (ATT) was started and on a follow-up visit after six months, the patient showed a resolution of the mandibular lesion. **Discussion:** In the oral cavity osteomyelitis commonly occurs due to an odontogenic source of infection. Tuberculosis (TB) is a worldwide public health problem, osteomyelitis due to tuberculosis infection is a rare phenomenon and jaw involvement is even rarer and usually affects older individuals. **Conclusion:** Tubercular osteomyelitis should be considered in the differential diagnosis because early identification and rapid implementation of a successful regimen are crucial in minimizing morbidity and the emergence of tuberculosis.

Key words: Osteomyelitis, tuberculosis, mandible, cancellous bone

Introduction

“Osteomyelitis has been defined as an inflammatory state of bone and cancellous bone. Which can be either acute or chronic. The term chronic osteomyelitis is used for primary or secondary cases with duration of more than 4 weeks from the onset of symptoms”⁽¹⁾. Nonbacterial chronic inflammatory disease of unknown etiology is known as primary chronic osteomyelitis (PCO), which can be associated with autoimmune diseases and syndromes such as “SAPHO (Synovitis, Acne, Pustulosis, Hyperostosis, and Osteitis) syndrome,” Majeeed syndrome, and cherubism. “Secondary chronic osteomyelitis of the jaw is usually caused by bacterial infection with odontogenic source being one of the most common causes of osteomyelitis. Osteomyelitis due to tuberculosis is a rare phenomenon with oral TB showing an incidence of 1.4%”⁽²⁾. Oral TB is presented in two forms namely the primary form and the secondary form. Secondary form of tuberculous infections is commonly seen as oral lesions (secondary to primaries in the lungs). “In primary oral tubercular lesions, there is no pulmonary involvement thus making the diagnosis very difficult. Osteomyelitis of the mandible due to tuberculosis is a rare phenomenon observed in <2% of skeletal TB”^(3,4). In literature, there are no clinical or radiological signs pathognomonic for diagnosis of tubercular osteomyelitis of the mandible. Here we report a case of osteomyelitis of the mandible without any evidence of active primary foci of tuberculosis and on the basis of clinical findings and CBCT analysis antitubercular therapy (ATT) was started and the patient

showed a resolution of the mandibular lesion thus confirming the diagnosis of tuberculous osteomyelitis. The present case highlights the clinical presentation of mandibular tuberculous osteomyelitis with difficulties in establishing diagnosis with clinical and CBCT image findings.

Case report:

An 8-year-old girl child came to the department of Oral Medicine and Radiology with a complain of swelling on right side parotid region since 6 months associated with pus draining sinus. The swelling was slow growing and not associated with toothache, fever or pain. There was no history of contact with tuberculosis and no prior medical and family history of treatment for any chronic infective disease. The patient was immunised with Bacille Calmette-Guerin (BCG) vaccine and no sign of any abnormality was detected on physical examination. Local examination revealed diffuse extra oral swelling involving right side of face extending superior-inferiorly from infra-orbital margin to the submandibular region and antero-posteriorly from commissure of mouth upto the tragus of ear, firm to hard in consistency and non-tender on palpation(Figure 1). Pus draining sinus was present on right sub mandibular region with enlarged right submandibular lymph node which was firm, matted, mobile and non-tender(Figure 1). Intra oral examination did not reveal any source of inflammatory dental foci. Based on the history and clinical examination a provisional diagnosis of chronic infection with abscess was given with a differential diagnosis of osteomyelitis and malignancy. All the hematological investigations were within the normal limit. Orthopantomogram (OPG) and Cone-beam computed tomography(CBCT) revealed loss of coronoid process of mandible on the right side (Figure2). Ultrasonography(USG) of the region revealed heterogenous and bulky right parotid region with multiple enlarged conglomerated lymph node with loss of fatty hilum with the largest one measuring approx. 2.3x1.4 cm suggestive of an infective etiology. On further investigation Mantoux test came out to be positive (size of induration in the present case was 18mm which was more likely to be suggestive of tubercular infection) and HIV was non-reactive. Magnetic resonance imaging (MRI) showed focal destruction of the right ramus and angle of mandible with marrow edema and discontinuity of the cortex with collection around the effected region suggestive of osteomyelitis. The patient was then referred to the department of Respiratory Medicine where Cartridge- Based Nucleic Acid Amplification test (CBNAAT) of sputum and chest X ray was advised which showed no significant pathology. On the basis of clinico-radiological judgment ATT Category 1 was started for a period of six months with intensive phase of 2 month and continuous phase of 4 month under National tuberculosis elimination program (NTEP) after which the patient condition improves with reduced swelling and new bone formation in the effected region (Figure 3-4).

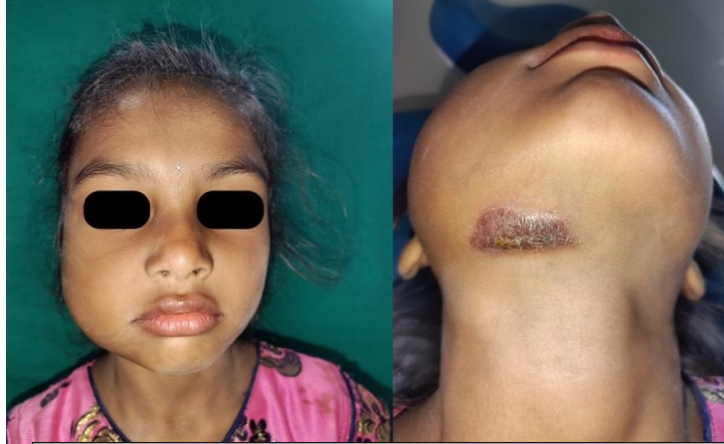

Figure 1: Extra-oral image showing swelling on right side of face and red nodule with draining sinus in right submandibular region.

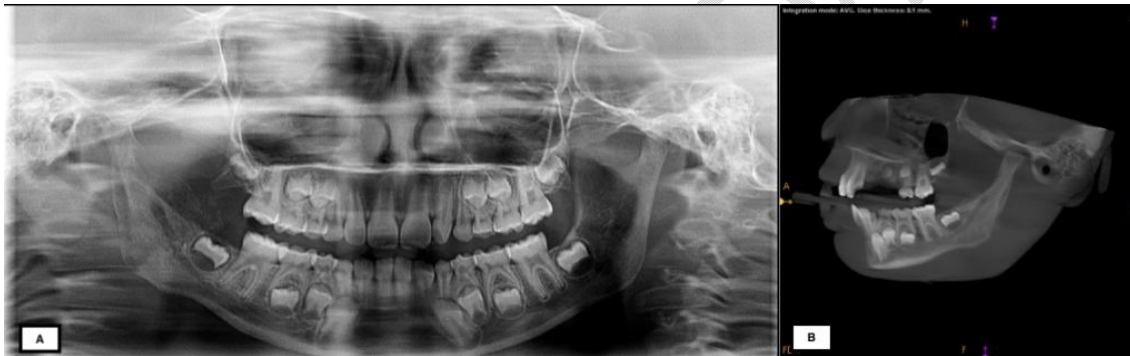

Figure 2: Orthopantomogram(A) and CBCT sagittal view showing bone resorption involving the right coronoid process.

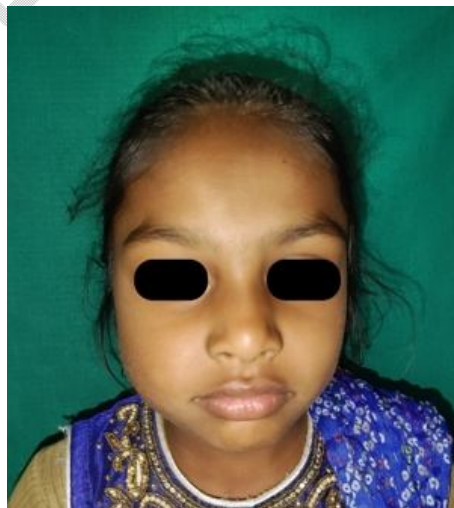

Figure 3: Post treatment extra-oral image showing reduced facial swelling on right side.

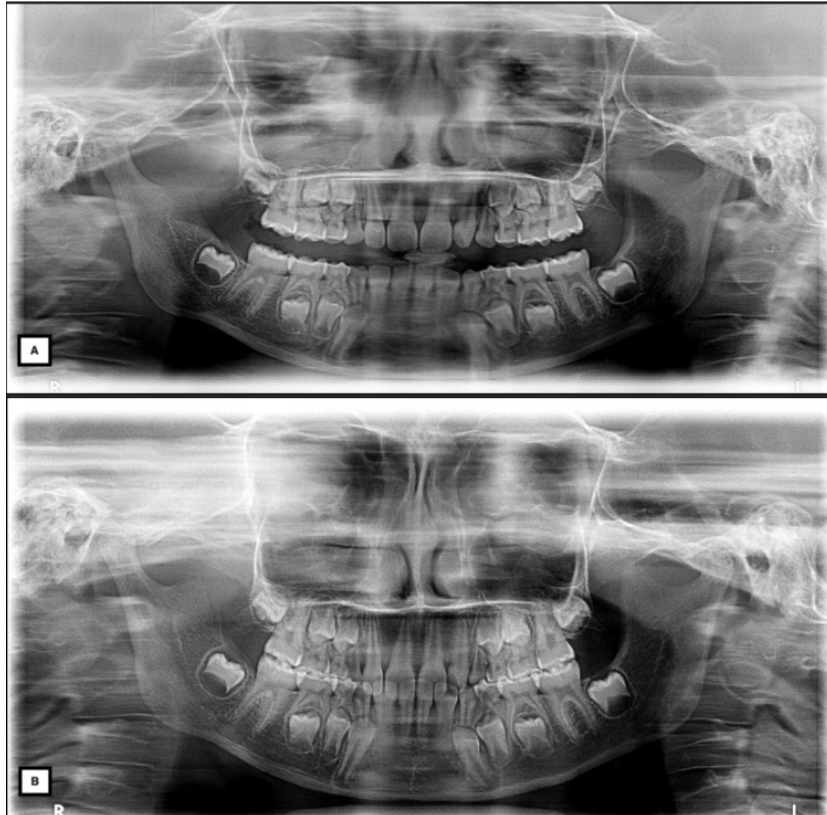


Figure 4: Orthopantomogram A (after completion of ATT), B (5 month after completion of ATT) showing new bone formation in the region of right coronoid process

Discussion:

“Oral lesions of TB are uncommon, but have a spectrum of manifestations and can mimic various other lesions involving the oral cavity. The common presentations of tuberculous infection in the oral cavity are ulcers, granulomas, pain and swelling, loosening of tooth, and displacement of tooth buds. One of the commonest areas of involvement is the tongue although involvement of other tissues such as gingiva, palate, maxillary and mandibular bone, temporomandibular joint and salivary glands are also reported”⁽⁵⁻⁶⁾. “Although involvement of the mandible is extremely rare, it is more commonly involved than the maxilla, with alveolus and angle of mandible being the most frequently involved areas”⁽⁷⁾. In literature there are no signs pathognomic for diagnosis of tubercular osteomyelitis of the mandible.

The present case of cheek swelling, without any acute symptoms and constitutional symptoms, added to the diagnostic difficulty. Although some investigations gave a direction

to this case namely USG, Mantoux test and radiograph while others were non-specific for making a final diagnosis. The USG imaging features considered in tubercular lymphadenitis include numbers, size, shape (determined by the short-to-long axis (S/L) ratio), echogenic hilus, edge, internal echogenicity, calcification, necrosis, matting of lymph node and adjacent soft tissue oedema ⁽⁸⁾. Some of these pathognomonic feature were reported in the present case.

“Though Mantoux test was positive but it is not considered a confirmatory test for diagnosis of tuberculosis as it is reported that not all reactions to tuberculin are attributed to infection with *Mycobacterium tuberculosis*. Larger the size of induration at the test site, higher is the probability of presence of infection with *Mycobacterium tuberculosis*. This is supported by the observation that morbidity with TB increase with the size of induration. Almost all reactions with induration of 15 mm or more in size may be considered attributed to infection with tubercle bacilli, irrespective of the presence or absence of BCG scar” ⁽⁹⁾. The size of induration in the present case was reported to be 18mm.

In literature it is reported that mandibular tubercular osteomyelitis lesions do not present a specific radiographic pattern, and appear as an ill-defined radiolucency with erosion of cortex. “Tuberculous osteomyelitis is more often seen in short tubular bones, like phalanges, metacarpals and metatarsals with the disease process starting in the medullary cavity resulting in patchy destruction of the involved bone. The entire diaphysis sequesters due to a combination of two interrelated pathological processes. First, the periosteum gets lifted up due to granulation tissue and this results in the formation of involucrum and consequently sequestration of the diaphysis occurs. Secondly, because of deficient anastomosis of the osseous arteries in childhood, the thrombosis caused by TB pathology leads to sequestration of the diaphysis. The radiological features of sequestration and subperiosteal new bone formation are diagnostic”⁽¹⁰⁾. Response to antituberculosis drugs is favourable and with early treatment, sequestra may revascularize and get incorporated like a graft and nearly complete restoration of osseous structure occurs. In the present case the periosteum is lifted up on lateral surface of ramus as seen in reconstructed 3D CBCT image (figure 4) and restoration of osseous structure was reported after antitubercular therapy.

“The diagnosis of osteoarticular tuberculosis in endemic areas like India is basically clinico-radiological which is based on a presumably better clinical insight due to high patient load, the easy availability of imaging modalities (like CBCT, CT and MRI), the shortage of laboratory facilities, and slow culture and drug sensitivity results” ⁽¹¹⁾. “It is justified to treat the patients clinico-radiologically in classical lesions of the bone, to avoid delay in diagnosis and after 8-12 weeks the clinical and radiological response can be observed especially in endemic area. However, there are some uncertain cases where biopsy is required to confirm the diagnosis”⁽¹²⁾. The disadvantages of clinico-radiological diagnosis are increased risk of missing TB mimics and drug-resistant TB ⁽¹¹⁾. “The mainstay treatment for tuberculous osteomyelitis is antitubercular therapy (ATT) as advised in present case. Antitubercular therapy (ATT) for 6–9 months as advocated by the National tuberculosis elimination program (NTEP) and other anti-TB programs globally was suggested in literature

and it was also quoted that the cases of minimal destructive lesions only required medical intervention of antitubercular therapy to achieve resolution, precluding the need for surgical treatment of the lesion. Surgical treatment as an adjunct to chemotherapy includes unresponsiveness to and noncompliance with medical therapy and the presence of large or otherwise undrainable abscess was also indicated”⁽¹³⁾.

In the present case chest X-ray and CBNAAT of sputum did not show any primary infection and on the basis of clinical judgment ATT was initiated. On follow up examination after 6 months it was observed that the cheek swelling was reduced in size which can be appreciated clinically (Figure 3) and radiographically where new bone formation can be appreciated in right coronoid region (Figure 4). A high degree of suspicion was the key in diagnosing and treating the patient in the present case with vague features and destructive bone lesions.

Conclusion

In developing country like India where the incidence of tuberculosis is high tubercular osteomyelitis should be considered in differential diagnosis. Early identification and rapid implementation of a successful regimen play a crucial impact in minimising morbidity and emergence of tuberculosis. Further consultation with specialist is mandatory before reaching a conclusion.

Consent

As per international standard or university standard, parental(s) written consent has been collected and preserved by the author(s).

Ethical Approval:

As per international standard or university standard written ethical approval has been collected and preserved by the author(s).

Reference:

1. Berglund C, Ekströmer K, Abtahi J. Primary Chronic Osteomyelitis of the Jaws in Children: An Update on Pathophysiology, Radiological Findings, Treatment Strategies, and Prospective Analysis of Two Cases. *Case Rep Dent*. 2015;2015:152717.
2. Vishwakarma SK, Jain S, Gupta M. Primary lingual tuberculosis presenting as cold - Abscess tongue: A case report. *Indian J Otolaryngol Head Neck Surg*. 2006 Jan;58(1):87-8.
3. Kalaiarasi R, Vijayakumar C, Archana R, Natarajan R. Pediatric Primary Tuberculous Osteomyelitis of the Mandible Mimicking Parotitis. *Cureus*. 2018 Jan 15;10(1):e2071.
4. Sambyal SS, Dinkar AD, Jayam C, *et al* Primary tuberculous osteomyelitis of the mandible in a 3-year-old child *Case Reports* 2016;2016:bcr2016216854.
5. Bhatt AP, Jayakrishnan A. Tuberculous osteomyelitis of the mandible: a case report. *Int J Paediatr Dent* 2001;11:304–8.
6. Wood RE, Housego T, Nortje CJ, *et al*. Tuberculous osteomyelitis in the mandible of a child. *Pediatr Dent* 1987;9:317–20.
7. Ebenezer J, Samuel R, Mathew GC, *et al*. Primary oral tuberculosis. Report of two cases. *Ind J Dent Res* 2006;17:41–4.
8. Yu, TZ., Zhang, Y., Zhang, WZ. *et al*. Role of ultrasound in the diagnosis of cervical tuberculous lymphadenitis in children. *World J Pediatr* 17, 544–550 (2021).
9. Gothi GD, Nair SS, Pyare Lal. Some epidemiological aspects of tuberculous disease and infection in pediatric age group in a rural community. *Indian Pediatrics* 1971;8:186-94.
10. Sharma SK, Mohan A. *Textbook of tuberculosis & non-tuberculous mycobacterial diseases*, 3rd ed., editors. Jaypee Brothers Medical Publishers.

11. Agashe VM, Johari AN, Shah M, Anjum R, Romano C, Drago L, Sharma HK, Benzakour T. Diagnosis of Osteoarticular Tuberculosis: Perceptions, Protocols, Practices, and Priorities in the Endemic and Non-Endemic Areas of the World-A WAIOT View. *Microorganisms*. 2020 Aug 28;8(9):1312.
12. Jain, A. K., Jena, S. K., Singh, M. P., Dhammi, I. K., Ramachadran, V. G., & Dev, G. (2008). Evaluation of clinico-radiological, bacteriological, serological, molecular and histological diagnosis of osteoarticular tuberculosis. *Indian journal of orthopaedics*, 42(2), 173–177. <https://doi.org/10.4103/0019-5413.40253>
13. Mohad N, Dabir A, Vahanwala J, Padhye M, Patwardhan J. Tuberculous osteomyelitis in condyle of mandible: A case report. *Advances in Oral and Maxillofacial Surgery*. 2021 Apr 1;2:100064

UNDER PEER REVIEW