

# Buccal fat pad removal for thinner cheeks: a case report

## ABSTRACT

**Aims:** In recent years there has been an increasing number of procedures for removing the buccal fat pad, also known as cheek reduction or face thinning surgery. Bichat buccal fat can be used as part of the therapeutic procedure in several cases of oroantral communication and in other oral surgery procedures. The objective of this case report was to demonstrate the procedure for removing the buccal fat pad for aesthetic purposes.

**Study design:** Case report

**Place and Duration of Study:** case carried out in 2021 in a private dental office in the city of Santos-SP- Brazil

**Presentation of case:** After completing the anamnesis and oral clinical assessment, the patient underwent laboratory tests for preoperative evaluation and magnetic resonance imaging of the malar region. Buccal fat pad removal is a minor procedure, and the surgical technique is considered simple and safe if performed by trained and experienced professionals. The postoperative period requires rest in the first days and limited mouth opening is a common symptom, and the use of analgesics and anti-inflammatories adequately controls any painful symptoms.

**Results:** The procedure can be performed by a dentist if the practitioner has a local anatomical knowledge, follows the indication for each case, and take all pre and postoperative care that is necessary to avoid complications.

**Conclusions:** When we have the correct indication, preoperative exams that indicate that everything is correct in relation to the presence of buccal fat pad and their relationship with adjacent structures and the execution of the technique with postoperative control, there is no way that professionals and patients cannot be happy with the buccal fat pad removal results.

*Keywords: Adipose Tissue; Buccal Mucosa; Magnetic Resonance Imaging*

## 1. INTRODUCTION

“The adipose tissue of the cheeks, buccal fat pad, presents a lobulated mass formed by a central body and four extensions: buccal, pterygoid, pterygomaxillary and temporal. The body is centrally positioned and is located above the parotid duct, behind the zygomatic arch and is divided into three lobes: anterior, intermediate, and posterior. The anterior lobe is located below the zygomaticus and extends to the front of the buccinator muscle, mandible, and deep space of the quadratus labii superioris muscle. The parotid gland passes through the back and the anterior facial vein passes through the anteroinferior margin. The anterior lobe also surrounds the orbital vessels”. [1] “The ramification of the facial nerve is located on the outer surface of the fat pad capsule” [2] “The intermediate lobe is located in and around the posterior lobe and side jaw. The function of Bichat's buccal fat pad is to protect the sensitive anatomical structures around as vessels and nerve trauma and participates in functions of chewing and sucking especially in children”. [3,4]

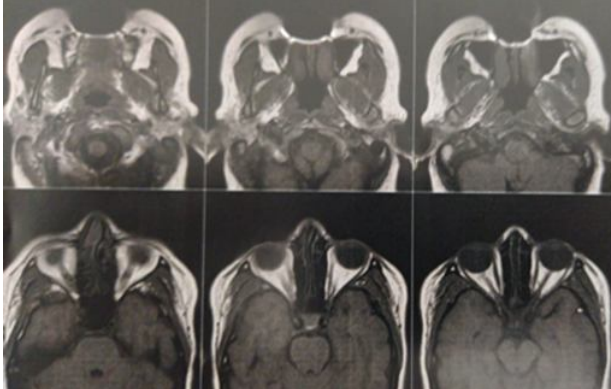
“Egyedi first described the use of a flap containing Bichat's fat pad as treatment to cover intraoral defects in 1977”. [5] “During the last three decades, it has been used as a standard procedure in closing oroantral communications and is a well established tool in oral and maxillo-facial surgery”. [6-8] “The cheek reduction surgery or simply the surgery to narrow down the cheek is a surgical procedure that removes all or part of buccal fat pad”. [9,10] “A patient candidate for this type of surgery typically has an excessive facial circumference; in some cases, lacerate the tissue of the buccal mucosa due to constant bites at the this location”. [11,12]

“In the past few years, it has increased the number of procedures for removing the Bichat's buccal fat pad with aesthetic purpose, and both the plastic surgeon and the dental surgeon can perform it”. [17] Unfortunately, studies that provide guidelines by emphasizing volumetric and technical details are limited. Buccal fat pad removal is an effective technique for refining the facial silhouette that should be reserved for patients with increased buccal fat pad volume. The purpose of this case report was to demonstrate the removal procedure of buccal fat pad, with aesthetic purpose.

## 2. PRESENTATION OF CASE

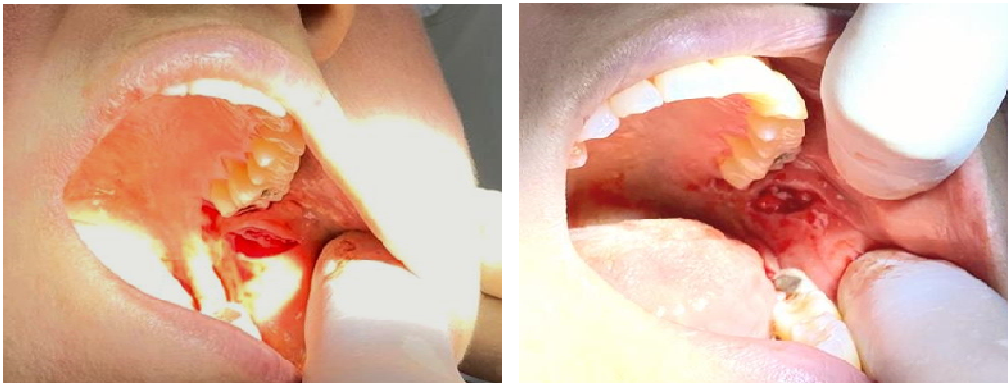
Female patient, 38 years old, was referred to the dental care in surgery specialty, indicating the technique of cheek reduction surgery. Patient was not aesthetically satisfied because of a rounded face and constant bites at the oral mucosa. After completing the anamnesis and oral clinical assessment, the patient underwent laboratory tests for preoperative evaluation (complete blood count, fasting blood glucose and coagulation) and magnetic resonance imaging of the malar region on the right and left sides (Figure 1). After planning, we opted for treatment with removal of buccal fat pad bilaterally.

Figure 1: Magnetic resonance imaging of the malar region on the right and left sides.



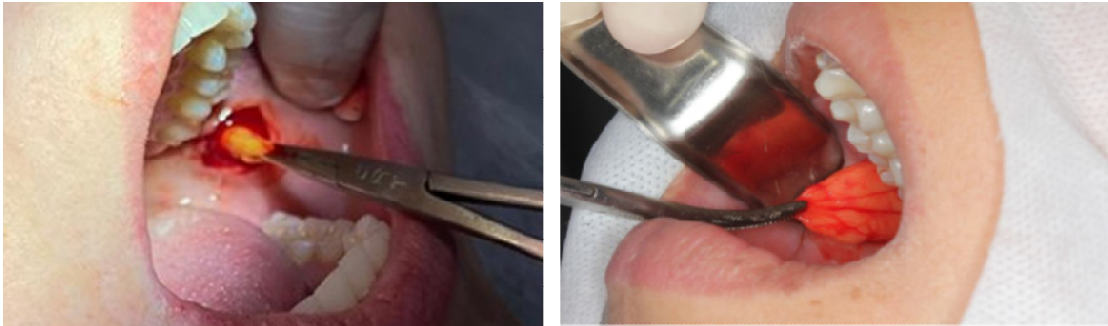
To access the buccal fat pad, a small incision (Figure 2) of a maximum of 2 cm in length was made in the soft tissue located in the lower portion of the zygomatic process, in the direction of the buccal surface of the upper second molar, taking care to visualize and adequately obliterate the parotid gland orifice with the retractor. After this incision, the fat pad was dissected with fine scissors or a hemostat, and light and delicate movements should be performed.

Figure 2: 1.5 cm horizontal incision in the buccal mucosa - 1 cm posterior to the duct, in front of the 2nd molar and identification of the buccal fat pad.



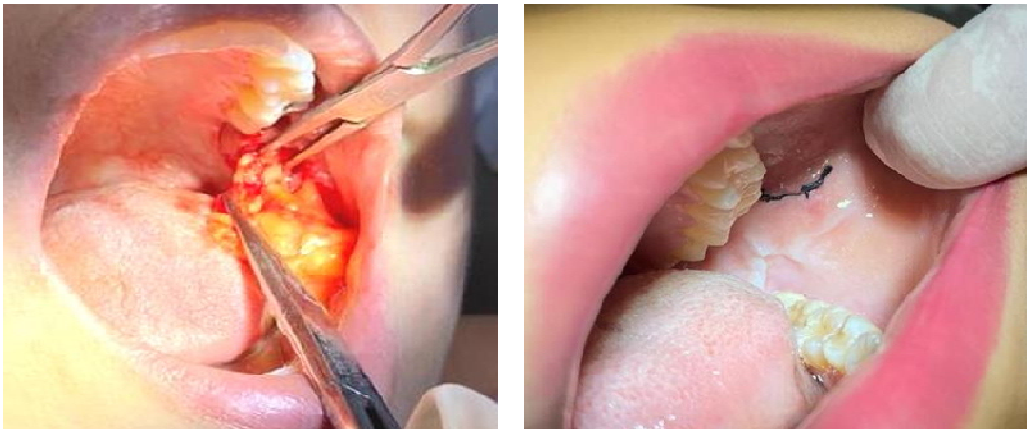
It is very important to preserve the fascial lining of the fat pad, as this will allow the removal of the buccal fat pad in one go. The rupture of the lining of the buccal fat pad can cause pieces of fat to be scattered in the region and the removal can lead to an increase in surgical time. With a long hemostat inserted into the fatty area, a portion of the fat pad is pulled out (Figure 3). Gradually, the entire fat pad is removed with the aid of another hemostat until the pedicle can be visualized.

Figure 3 : Buccal fat pad traction in a light and delicate way.



At this point, the pedicle can be cut, and the fat pad released. A small suction tip can be inserted into the area to clean out any fat that may have remained during the divulsion. A simple suture is performed closing the incision, simple sutures facilitate postoperative removal (Figure 4).

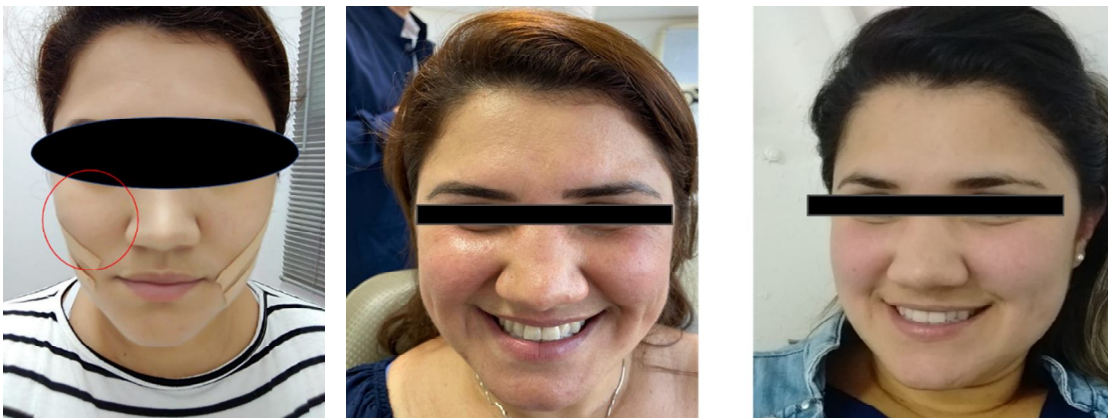
Figure 4: Tweezers exchange movement should be initiated to remove the buccal portion of the fat ball and simple suture



When there are no changes observed in the macroscopic fat pad, there is no need to send it for additional histopathology tests.

Postoperative care includes intensive cryotherapy within 48 hours, analgesics and anti-inflammatories. In the case presented here, the patient had more edema on the left 5 days after the surgery. After communicating with the patient, she was asked to rest and use corticosteroids for 3 days, resolving the intercurrent (Figure 5).

Figure 5: Local edema 4 days after removal of the buccal fat pad, Before buccal fat pad removal and 4 months after removal.



The patient returned to her routine about 5 days after surgery and mandibular movements were normal after 15 days. The final result of buccal fat pad removal can be observed 4 to 6 months after surgery (Figure 5).

### 3. DISCUSSION

The objective of cheek reduction surgery can be aesthetic: to reduce the volume of the lower face by slimming the chin and protruding the nose. But it can also be due to bites in the jugal portion that can lead to the appearance of lesions and ulcers. "However, this surgery is controversial for some professionals, as this region of the face tends to lose fat with increasing age and the removal of these fat pads can result in a more aged appearance, especially if the removal is total. It is important to note that, over the years, the face begins to suffer a loss of fat and collagen". [11] "Therefore, people who have this surgery may need fillers later to regain a more youthful appearance. When properly indicated, it promotes functional and aesthetic results". [12] However, they only show good results for people who have exaggerated circumference in the face shape. [3.7-9]

"It is important a clinical evaluation by the professional who will perform the surgery so that he can diagnose whether there is indication and what are the expectations of the patient and the treatment". [17] It is important that the patient make pre-surgical tests, including complete blood count, coagulation and blood glucose to see if he is healthy enough to perform the surgery and go through the assessment of a cardiologist. Imaging exams are fundamental and can avoid surprises, as demonstrated in the study by Hwung et al. 2005, in which there is a 26.3% chance of buccal branch injury during buccal fat pad removal. [13]

"The anatomical knowledge of this region is essential to avoid iatrogenesis in surgical procedures, which can result in temporary or permanent sequelae". [14] "Among the complications of greater complexity in buccal fat pad removal there are: trismus, hemorrhages, facial infections, lesion of the duct of the parotid gland and facial paralysis, however common complications that are related to any surgical procedure can occur, such as edema and hematoma, despite being considered a technically simple procedure". [2]

"Among the most reported postoperative complications are hematomas, partial necrosis, infection or injury to the facial nerve. Exaggerated incisions can leave the tissue without adequate blood supply, leading to necrosis". [10] "Preservation of the fascia covering the fat pad improves the prognosis and reduces surgical time, as rupture would require suction and curettage of the area, so gentle removal is essential". [1] "The region where the buccal fat pad is located is close to two of the branches of the trigeminal nerve, the maxillary branch (which follows the entire upper jaw) and the mandibular branch (which follows the lower jaw) and care must always be taken. Like many other nerves in the face, the trigeminal nerve is a sensory nerve that controls sensations in the face, sending messages to the brain". [11] If the practitioner is inexperienced, the damage can be irreversible and can cause facial paralysis. The procedure is contraindicated in patients with any acute pathology, in patients with a sharp nose and protruding chin, as the removal of the buccal fat pad will further accentuate this projection, patients with oral conditions of inflammation and/or infection must first be cured of the oral condition to subsequently perform the buccal fat pad removal surgery. The buccal fat pad removal has a low incidence of major complications, and this incidence decreases more with a bandage use. Bandages are effective in the decrease of major complications related to procedure. Kinesio® tapes have a bandage effect and must be placed following the guidelines of the technique to be application should be made from muscle insertion to muscle origin for rehabilitation, in cases of muscle overuse and inflammation. [15]

"In the case presented in this study, intraoral healing was observed within 15 days, mouth opening movements also returned within 15 days, and the end of facial edema after 4 weeks, the same as reported in the literature".[16]

#### 4. CONCLUSION

The procedure can be performed by a dentist as long as the professional has good local anatomical knowledge, follows the indication for each case and takes all the necessary pre- and post-operative care to avoid complications. When we have the correct indication, preoperative exams that indicate that everything is normal in relation to the presence of fat balls and their relationship with adjacent structures and the execution of the technique with postoperative control, professional and patient are satisfied and happy with the results of removing the buccal fat pad.

#### Ethical approval and Consent

The patient was informed of all the risks and benefits of the procedure, had access to the consent form and agreed with the publication of the photos for scientific purposes. The procedure was approved by the Research Ethics Committee of the Metropolitan University of Santos under number 69652817.6.0000.5509

#### REFERENCES

1. Alcântara MT, Ribeiro NR, Abreu DF. Complications associated with bichectomy surgery: a literature review. *Minerva Dent Oral Sci.* 2021 Aug;70(4):155-160.
2. Benjamin M, Reish RG. Buccal Fat Pad Excision: Proceed with Caution. *Plast Reconstr Surg Glob Open.* 2018 Oct 16;6(10):e1970.
3. Brucoli M, Arcuri F, Borello G, Benech A. Surgical technique of the transoral approach to remove a lipoma of the buccal fat pad. *J Craniofac Surg.* 2011; 22(6):2415-8.
4. Zhang HM, Yan YP, Qi KM, Wang JQ, Liu ZF. Anatomical structure of the buccal fat pad and its clinical adaptations. *Plast Reconstr Surg.* 2002 Jun;109(7):2509-18.
5. Egyedi P. Utilization of buccal fat pad for closure of oroantral and/or oronasal communications. *J Maxillofacial Surg.* 1977; 5:241-4.
6. Shrivastava G, Padhiary S, Pathak H, Panda S, Lenka S. Buccal Fat Pad to Correct Intraoral Defects. *Int J Sci Res Publ.* 2013; 3(2): 1-4.
7. Holton LH 3rd, Rodriguez ED, Silverman RP, Singh N, Tufaro AP, Grant MP. The buccal fat pad flap for periorbital reconstruction: a cadaver dissection and report of two cases. *Plast Reconstr Surg.* 2004 Nov;114(6):1529-33.
8. Alkan A, Dolanmaz D, Uzun E, Erdem E. The reconstruction of oral defects with buccal fat pad. *Swiss Med Wkly.* 2003 Aug 23;133(33-34):465-70.
9. Matarasso A. Buccal fat pad excision: aesthetic improvement of the midface. *Ann Plast Surg.* 1991; 26(5):413-8, 1991.
10. Rohrich RJ, Pessa JE. The fat compartments of the face: anatomy and clinical implications for cosmetic surgery. *Plast Reconstr Surg.* 2007 Jun;119(7):2219-2227.
11. Traboulsi-Garet B, Camps-Font O, Traboulsi-Garet M, Gay-Escoda C. Buccal fat pad excision for cheek refinement: A systematic review. *Med Oral Patol Oral Cir Bucal.* 2021 Jul 01;26(4):e474-e481.
12. Sezgin B, Tatar S, Boge M, Ozmen S, Yavuzer R. The Excision of the Buccal Fat Pad for Cheek Refinement: Volumetric Considerations. *Aesthet Surg J.* 2019 May 16;39(6):585-592.
13. Hwang K, Cho HJ, Battuvshin D, Chung IH, Hwang SH. Interrelated buccal fat pad with facial buccal branches and parotid duct. *J Craniofac Surg.* 2005 Jul;16(4):658-60.
14. Pimentel T, Hadad H, Statkiewicz C, Alcântara-Júnior AG, Vieira EH, Souza FÁ, Garcia-Júnior IR. Management of Complications Related to Removal of the Buccal Fat Pad. *J Craniofac Surg.* 2021 May 01;32(3):e238-e240.
15. Roman-Torres C, Domingues NRAP, Pimentel AC, Marão HF, Sendyk WR. Post-Operative Evaluation of the Intra-Oral Buccal Fat Pad Removal Technique: A Prospective Study. *The Open Dent J.* 2020, 14: 324-328.

16. Grillo R, de la Puente Dongo JL, de Moura Moreira L, Dos Santos Queiroz AG, Teixeira RG. Effectiveness of bandage in the incidence of major complications on bichectomy: literature review and case series of 643 bichectomies. *Oral Maxillofac Surg.* 2022 Sep;26(3):511-517.
17. Roman-Torres CV, Sani AJ, Cordeiro Filho J, SM SR. Bichat's buccal fat pad removal: cheek reduction surgery. *J Dent Health Oral Disord Ther.* 2017;7(4):00250.