

Original Research Article

Single Versus Double Layer Amniotic Membrane Transplantation in Management of Resistant Infective Corneal Ulcer

Abstract:

Background: Infectious keratitis is an important and preventable cause of monocular blindness. It is caused by bacteria, fungi, viruses, or parasites, It is a potentially sight-threatening disease of the eye as a result of corneal opacities, persistent epithelial defects, thinning or corneal melting.²

This urgent ophthalmic condition needs to be treated with appropriate antimicrobial agents. However, some ulcers do not respond to conventional antimicrobial treatments and need further intervention.⁴

Amniotic membrane transplantation (AMT) may be a tool to suppress inflammation in infectious keratitis and promote epithelial regeneration after sufficient antibiotic eye medications, thus improving the situation of the eye for subsequent surgeries, such as penetrating keratoplasty (PK).²

Aim of the study: This prospective, comparative, interventional and randomized study aimed to compare efficacy and safety of single versus double layer amniotic membrane transplantation (AMT) in treatment of resistant infectious keratitis.

Patients and Methods: The study was carried out on 40 eyes with resistant infectious keratitis not respond to specific antimicrobials for two weeks (20 eyes treated by single layer of amniotic membrane (group A) and 20 eyes treated by double layer amniotic membrane (group B) .

Results: The mean age of group (A) was (54.250 ± 12.561) years while in group (B) was (52.250 ± 14.722) years. The gender distribution of group (A) was 13 male and 7 female , group (B) was 14 male and 6 female .According to corneal cultures there were 6 cases (30%) fungal , 3 cases (15%) bacterial and 11 cases (55%) mixed bacterial and fungal infection in group (A),While in group (B) there were 7 cases (35%) fungal and 13 cases (65%) mixed bacterial and fungal

infection. The healing time ranged from 3 to 8 weeks with mean 5.214 ± 1.888 weeks in group (A), While in group (B) ranged from 3 to 6 weeks with mean 4.412 ± 0.712 weeks. The study revealed no significant difference in pre-operative and post-operative best corrected visual acuity in both groups as in group A vision improved in 5 cases, remain unchanged in 9 cases and worsened in 6 cases while in group B vision improved in 5 cases, remain unchanged in 12 cases, and worsened in 3 cases. There was significant difference between two groups in healing of severe corneal ulcer as in group A all cases with severe corneal ulcer not achieve successful healing, While in group B successful healing occurred in 83.33% of severe cases.

Conclusion: There is no significant difference between single layer and double layer AMT in management of resistant infectious keratitis especially mild and moderate corneal ulcers.

In severe corneal ulcer it is better to do double layer AMT to restore integrity of corneal stroma and promote healing.

Keywords: Amniotic membrane transplantation (AMT), Resistant infective corneal ulcer.

Introduction:

“Corneal ulceration is usually caused by keratitis, including infectious keratitis, traumatic keratitis, and keratitis related to autoimmune and systemic diseases. Therefore, It is divided into two types: infectious keratitis and non-infectious keratitis”.¹

“Infectious keratitis is an important and preventable cause of monocular blindness. It is caused by bacteria, fungi, viruses, or parasites, It is a potentially sight-threatening disease of the eye as a result of corneal opacities, persistent epithelial defects, thinning or corneal melting”.²

“The presence of a predisposing factor makes the corneal epithelium more susceptible to microbial infections. Contact lens (CL) wearing is frequently

associated with severe forms of microbial keratitis. Corneal trauma, previous ocular surgery, ocular surface diseases, systemic illnesses and the abuse of topical ophthalmic drugs especially corticosteroids and immunosuppressive drugs are significantly associated with high rates of infectious keratitis”.³

“ This urgent ophthalmic condition needs to be treated with appropriate antimicrobial agents. However, some ulcers do not respond to conventional antimicrobial treatments. Resistance of microbes to antibiotics is one of the main causes of treatment failure. Furthermore, severe and resistant corneal ulcers are usually associated with corneal melting”.⁴

Amniotic membrane transplantation (AMT) may be a tool to suppress inflammation in infectious keratitis and promote epithelial regeneration after sufficient antibiotic eye medications, thus improving the situation of the eye for subsequent surgeries, such as penetrating keratoplasty (PK)”.²

“The amniotic membrane (AM), a thin membrane on the inner side of the placenta, is an effective material that can restore integrity of the ocular epithelium and prevent symblepharon and corneal perforation. What makes the AM play a therapeutic role are its special 3-layer structure (from inside to outside: the epithelial layer, the thick basement membrane, and the avascular mesenchymal tissue) and its biological viability (antiinflammatory, antibacterial, antiviral, low immunogenicity, antiangiogenic, and proapoptotic)”.⁵

Materials and method

This prospective, comparative, interventional and randomized study was carried out on 40 eyes with resistant infectious keratitis of patients who attended to outpatient clinic and corneal unit of the ophthalmology department at Tanta University Hospital from December 2020 to November 2021.

Patients received specific antimicrobial according to results of culture and sensitivity for two weeks but no improvement achieved or complications appeared so they are managed by amniotic membrane transplantation. Patients are subdivided into two groups:

Group A: Twenty eyes were managed by single layer AMT.

Group B: Twenty eyes were managed by double layer AMT.

Inclusion criteria:

- 1- Resistant infectious keratitis (infectious keratitis not respond to specific antimicrobial treatment and shows no signs of healing after two weeks of continuous medical treatment).
- 2- Corneal stromal thinning (50% or more of stroma lost).
- 3- Descemetocoele.

Exclusion criteria:

- 1- Noninfectious keratitis proved by negative results of culture and sensitivity.
- 2- Perforated corneal ulcer.
- 3- Total corneal melting.
- 4 - Endophthalmitis.

Surgical technique:

Anesthesia: Retrobulbar and topical anesthesia was applied to most of case while in cases with descemetocoele or young patients AMT was done under general anesthesia.

-After local anesthesia: Sterilization of skin by 5% Bovidine iodine , Draping of eye, Opening eye by speculum then debridement of ulcer base and necrotic tissue with microspong was performed.

-The amniotic membrane used was wet cryopreserved AM Prepared under sterile conditions. It was taken from placenta after cesarean section and screening the donor for HIV, hepatitis B and C, and syphilis.

- AM was washed by saline and antibiotic before applying it to cornea.

-Group A: Single layer of amniotic membrane was sutured with the epithelium/ basement membrane side facing outwards so that neighboring epithelial cells of the recipient would migrate over the amniotic membrane allowing ulcer healing.

-Group B: Double layers of amniotic membrane were applied as sandwich technique (AM spread over cornea with basement membrane facing up then folded up on itself as double layer.

-The amniotic membrane in both groups was spread over whole cornea and was sutured paralimbal using monofilament nylon 10/0 interrupted sutures in single row of sutures.

- Trimming edges of AM slightly larger than cornea.

- Bandage contact lens was applied to all cases till complete epithelization.

- Patients continued specific antimicrobial treatment according to culture and sensitivity and supportive treatment as preoperative.

- Patients were followed up every 2 days for 2 weeks then twice weekly till complete healing.

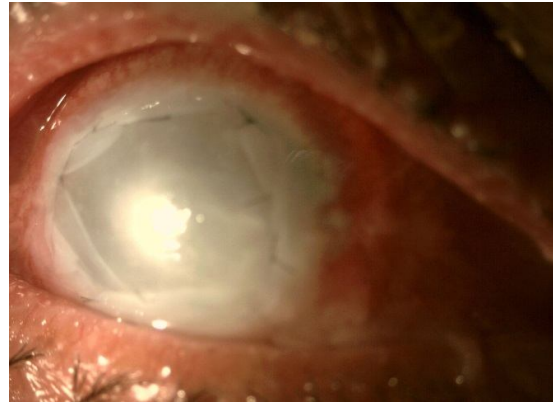
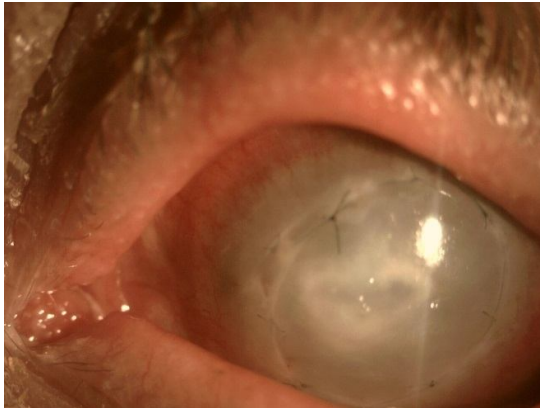


Figure1: Single layer AM sutured to cornea.

Figure2: Double layer AM sutured to cornea

Results :

The mean age of group (A) was (54.250 ± 12.561) years while in group (B) was (52.250 ± 14.722) years. The gender distribution of group (A) was 13 male (65%) and 7 female (35%), group (B) was 14 male (70%) and 6 female (30%). There were no statistically significant differences between two groups regarding age (P- value = 0.647) and gender distribution (P-value = 0.736).

.Table 1: Age (years) and Gender distribution of two groups of the study

		Groups						T-Test	
		Group A			Group B			t	P-value
Age (Years)	Range	23	-	74	20	-	73	0.462	0.647
	Mean \pmSD	54.250	\pm	12.561	52.250	\pm	14.722		
Chi-Square		N		%		N		%	
Sex	Male	13		65.00	14		70.00	0.114	0.736
	Female	7		35.00	6		30.00		

According to corneal cultures there were 6 cases (30%) fungal , 3 cases (15%) bacterial and 11 cases (55%) mixed bacterial and fungal infection in group (A).While in group (B) there were 7 cases (35%) fungal and 13 cases (65%) mixed bacterial and fungal infection There were no statistically significant differences between two groups.

Table 2: Results of culture and sensitivity of both groups in the study.

Culture	Groups				Chi-Square	
	Group A		Group B		X ²	P-value
	N	%	N	%		
Fungal	6	30.00	7	35.00	3.244	0.198
Bacterial	3	15.00	0	0.00		
Mixed	11	55.00	13	65.00		
Total	20	100.00	20	100.00		

Patients in two groups showed overall success rate of healing 77.5% (31 cases) and failure rate 22.5% (9 cases). In group (A) successful healing was achieved in 14 cases (70%) while in group (B) successful healing was achieved in 17 cases (85%). The healing time ranged from 3 to 8 weeks with mean 5.214 ± 1.888 weeks in group (A). While in group (B) ranged from 3 to 6 weeks with mean 4.412 ± 0.712 weeks. There were no statistically significant differences between two groups (P-value =0. 0.116).

Table 3. Data statistics

		Groups						T-Test	
		Group A			Group B			t	P-value
Healing (Weeks)	Range	3	-	8	3	-	6	1.622	0.116
	Mean \pmSD	5.214	\pm	1.888	4.412	\pm	0.712		
Chi-Square		N		%		N		%	
Healing	Success	14		70.00		17		85.00	
	Failure	6		30.00		3		15.00	

Patients in group A showed no significant change in best corrected visual acuity (BCVA). There were 5 (5%) patients with 1/60 visual acuity , only one patient (5%) with CF visual acuity ,11(55%) patients with HM visual acuity and 3 (15%) patient with PL visual acuity pre-operative but 3 months post-operative there were one patient (5%) with 1/60 visual acuity , 5(25%) patients with CF, 10(50%) patients with HM and 4(20%) patients with PL visual acuity.(P-value = 0.137)

Patients in group (B) showed no significant improvement in best corrected visual acuity. There were 15(75%) patients with HM visual acuity and 5 (25%) patient with PL visual acuity pre-operative but 3 months post-operative there

were only one (5%) patients with 1/60 or better, 16 (80%) patients with HM and 3 (15%) patient with PL visual acuity. (P-value = 0.465)

Table 4: Preoperative and postoperative visual acuity in both groups.

		Groups				Chi-Square	
		Group A		Group B		X ²	P-value
		N	%	N	%		
UCVA	PL	3	15.00	5	25.00	9.441	0.024*
	HM	11	55.00	15	75.00		
	CF	1	5.00	0	0.00		
	1/60 or better	5	25.00	0	0.00		
BCVA	PL	4	20.00	3	15.00	8.472	0.037*
	HM	10	50.00	16	80.00		
	CF	5	25.00	0	0.00		
	1/60 or better	1	5.00	1	5.00		
P-value		0.137		0.465			

Discussion:

In our study we found no statistically significant differences between two groups regarding age (P- value = 0.647) and gender distribution (P-value = 0.736).According to demographic data of both groups, The mean age of patients in group A was (54.250 ± 12.561) years while that in group B was (52.250 ± 14.722) years. The gender distribution in group (A) was 13 male (65%) and 7 female (35%) While in group (B) was 14 male (70%) and 6 female (30%). This reflects that infective corneal ulceration is more common in middle aged males older than 50 years. This may be due to the fact that males are more liable to trauma specially plant origin trauma as males are more likely to be involved in agriculture, as well as other outdoor work.

This coincides with, Mohan et al study, which was conducted on 28 eyes with non healing corneal ulcer treated with AMT and found that corneal ulcers are commoner in males than females because males are more exposed to external environment and trauma than females (57.1 % male, 42.8 % female) and the majority of patients in the study (60.7 %) were between 40 and 60 years of age.⁶

In our study, Results of cultures were 6 (30%) cases fungal , 3 (15%) cases bacterial and 11 (55%) cases mixed bacterial and fungal infection in group (A), While in group (B) there were 7 (35%) cases fungal and 13 (65%) cases mixed bacterial and fungal infection. There were no statistically significant differences between two groups. This reflected that mixed infection is more common than pure infection and this may be due to superadded infection or contamination during culture technique.

On the contrary of our study, Mandour et al study that was carried out on 340 eyes of 340 patients with microbial keratitis attending at the outpatient clinic of Ophthalmology Department of Menoufia University Hospital reported that bacterial affection was recorded as the main causes of the resistant corneal ulcer cases. Pure bacterial organisms (single + mixed) occurred in 55.9% of cases, while fungal organisms occur in 20.6%.⁷

In our study, Double layer AMT show slightly shorter epithelial healing time than single layer. The epithelial healing time ranged from 3 to 6 weeks with mean 4.412 ± 0.712 weeks in group (B) while in group (A) ranged from 3 to 8 weeks with mean 5.214 ± 1.888 weeks. There were no statistically significant differences between two groups (P-value = 0.0116). That is in agreement with Kruse et al study which reported that epithelium healed above all corneal ulcers treated by double layer AMT within 4 weeks and remained stable in 9 of 11 patients for 1 year.⁸ Also, Dekaris et al study was conducted on deep corneal ulceration treated by monolayer and multilayer AMT and reported that epithelial healing in monolayer group was 4-6 wks while in multilayer group was 3-4 wks.⁹

On contrary to our study, Prabhasawat et al study, The total mean epithelialization time after AMT was 2.1 weeks (range 0.5–8 weeks), with 3.5 (2.6) weeks in group A, 1.5 (1.0) weeks in group B and 1.1 (0.5) weeks in group C. Among these three groups, epithelial defects in groups B and C healed more rapidly than those in group A ($p = 0.003$, $p = 0.017$, and $p = 0.009$). This study reported that epithelial defects of the patients who underwent multilayer AMT healed significantly faster than those who underwent a single layer method.¹⁰

Our study shows no significant difference in healing success rate between mild, moderate and severe ulcers in group B as it achieve successful healing in 77.78% of mild cases, 100% of moderate cases and 83.33% of severe cases. while in group A shows significant difference in healing success rate between mild, moderate and severe ulcers as it showed successful healing in 91.67% in mild corneal ulcers, 60% in moderate ulcers and no successful healing was achieved in

severe cases. This reflects that double layer AMT is more effective than single layer in severe corneal ulcers.

That is in agreement with Dekaris et al study which was conducted on 28 cases with deep corneal ulcers and divided into 2 groups: one group treated by monolayer AMT and the other group treated by multilayer AMT reported that better effectiveness of multilayer technique as compared to the monolayer technique. In the group of monolayer procedure AMT was successful in 10 (64%), out of 17 patients. In 6 eyes (60%) ulcer has healed after first transplantation, while in 4 patients (40%) second transplantation was necessary. In multilayer procedure group, transplantation was successful in 8 (72%) out of 11 patients after the first surgery, while in 2 cases it had to be repeated.⁹

According to our results, there was no significant difference in postoperative best corrected visual acuity between 2 groups as vision remain unchanged in most cases and improved in few cases in both groups. This reflects that main role of AMT is to restore integrity of corneal epithelium and stroma and its role in vision improvement is not clear.

In agreement with our study, Mohan et al study reported that the immediate post-operative period (day 1), the BCVA deteriorated in all patients because of the presence of amniotic membrane (multilayer) over the cornea. The BCVA started improving 1 month after the procedure and improved to pre-operative values at 3 months.⁶ Also, Uhlig et al study reported no significant change in BCVA between baseline and last follow up either in overlay(single and double) or sandwich technique group.¹¹

Contrary with our results, Liu et al study reported statistically significant difference in vision improvement rate between single and multilayer as vision improved more in single layer AMT as it applied to superficial ulcers. The pooled VIR of the 3 subgroups, in the order of SOI, MUI, and SAN, was 76 , 61% and 50% respectively.¹ Also, Chen et al study reported that postoperative vision improved in 14 cases , worsened in one case , remained unchanged in 8 cases in both groups of single and double layer AMT applied to fungal corneal ulcer. In this study single layer AM was applied to most of cases.¹²

Conclusion:

Amniotic membrane is very effective tool in surgical management of resistant infectious keratitis as it promote healing and prevent complications as corneal perforation that need urgent therapeutic keratoplasty.

There is no significant difference between single layer and double layer AMT in management of resistant infectious keratitis especially mild and moderate corneal ulcers .In sever corneal ulcer it is better to do double layer AMT to restore integrity of corneal stroma and promote healing.

Consent

As per international standard or university standard, patient(s) written consent has been collected and preserved by the author(s).

References:

1. Liu J, Li L, Li X. Effectiveness of Cryopreserved Amniotic Membrane Transplantation in Corneal Ulceration : A Meta-Analysis. 2019;454–62.
2. Keratoplasty P, Hoffmann S, Szentmáry N, Seitz B. Amniotic Membrane Transplantation for the Treatment of Infectious Ulcerative Keratitis Before Elective. 2013;32(10):1321–5.
3. Ibrahim YW, Boase DL, Cree IA. Epidemiological characteristics, predisposing factors and microbiological profiles of infectious corneal ulcers: The Portsmouth corneal ulcer study. *Br J Ophthalmol.* 2009;93(10):1319–24.
- 4- Zamani M, Panahi-Bazaz M, Assadi M. Corneal collagen cross-linking for treatment of non-healing corneal ulcers. *J Ophthalmic Vis Res.* 2015;10(1):16–20.
5. Toda A, Okabe M, Yoshida T, Nikaido T. The potential of amniotic membrane/amnion-derived cells for regeneration of various tissues. *J Pharmacol Sci.* 2007 Nov;105(3):215–28
- 6- Mohan S, Budhiraja I, Saxena A, Khan P, Sachan SK. Role of multilayered amniotic membrane transplantation for the treatment of resistant corneal ulcers in North India. *Int Ophthalmol.* 2014;34(3):485–91.
- 7- Mandour SS, Marey HM, Farahat HG. Resistant Microbial Keratitis in South Nile Delta, Egypt: Influence of Regional Risk Factors. *Semin Ophthalmol.* 2016 Sep 2;31(5):473–8.
- 8- Kruse FE, Rohrschneider K, Vo HE. Transplantation for Reconstruction of Deep Corneal Ulcers. 1999;1504–11.
- 9- Dekaris I, Gabrić N, Mravičić I, Karaman Z, Katušić J, Lazić R, et al. Multilayer vs. monolayer amniotic membrane transplantation for deep corneal ulcer treatment. *Coll Antropol.* 2001;25(SUPPL. 1):23–8.
- 10- Prabhasawat P, Tesavibul N, Komolsuradej W. Single and multilayer amniotic membrane transplantation for persistent corneal epithelial defect with

and without stromal thinning and perforation. *Br J Ophthalmol.* 2001;85(12):1455–63.

11- Uhlig CE, Frings C, Rohloff N, Harmsen-Aasman C, Schmitz R, Kiesel L, et al. Long-term efficacy of glycerine-processed amniotic membrane transplantation in patients with corneal ulcer. *Acta Ophthalmol.* 2015;93(6):e481–7.

12- Chen HC, Tan HY, Hsiao CH, Huang SCM, Lin KK, Ma DHK. Amniotic membrane transplantation for persistent corneal ulcers and perforations in acute fungal keratitis. *Cornea.* 2006;25(5):564–72.

UNDER PEER REVIEW