

COLONOSCOPY: A DIAGNOSTIC TEST FOR EARLY COLON CANCER DIAGNOSIS

ABSTRACT: Colonoscopy is a medical test to help find potential problems, such as colorectal cancer or polyps. Polyps are small growths, they are not cancer, but they can turn into cancer. Data from the World Health Organization (WHO), shows that Cancer is a leading cause of death worldwide, accounting for nearly 10 million deaths in 2020, or nearly one in six deaths, the most common cancers are breast, lung, colon and rectum and prostate cancers. Also, the WHO data shows that colorectum (colon and rectum) cancer alone in 2020 had 1.93 million cases and resulted in 916,000 deaths. Data from the World Cancer Research Fund International (WCRF) showed that Colorectal cancer is the 3rd most common cancer worldwide. It is the 3rd most common cancer in men and the 2nd most common cancer in women. And lastly, data from the American Cancer Society (ACS) estimates that the number of colorectal cancers in the United States for 2023 are 106,970 new cases of colon cancer, and 46,050 new cases of rectal cancer. Overall, the lifetime risk of developing colorectal cancer is about 1 in 23 for men and 1 in 26 for women, however, each person's risk might be higher or lower than this, depending on their risk factors for colorectal cancer. In the United States, colorectal cancer is the third leading cause of cancer-related deaths in both men and women, and it's the second most common cause of cancer deaths when numbers for men and women are combined. It's expected to cause about 52,550 deaths during 2023. This article was written with the aim of explaining and providing up-to-date information on the progress made in the field of colonoscopy and its use in diagnosing colorectal/colon cancer.

Keywords: Colorectal cancer, colonoscope, colonoscopy, colon, polyps, cancer, rectum.

1. INTRODUCTION:

“Colonoscopy is an endoscopic procedure that allows visualization of the entire mucosa of the large intestine and distal terminal ileum. It’s a type of endoscopy, which means that it uses an endoscope (colonoscope), a flexible tube with a lighted camera on the end that’s inserted into the body through the anus all the way to the terminal ileum (TI)” (Rex et al, 2009; Ko et al 2010). “Furthermore, it enables tissue sampling for histopathology as well as an opportunity for therapeutic procedures such as polypectomy or dilatation of a stenosis” (Hazewinkel et al, 2011). A colonoscopy involves inserting a colonoscope via the rectum and anus into the colon. It transmits images of the large intestine’s mucosa to a screen to be viewed by an endoscopist. It is useful for identifying pathologies such colon cancer, polyps, swollen or inflamed tissues, colitis, and inflammatory bowel disease (Ray-Offor et al,2019). “When compared to other types of examinations including the stool occult blood test, barium enema, and computed tomography colonography, colonoscopy offers superior diagnostic specificity and sensitivity. As a result, the demand for colonoscopies has quickly increased in recent years. The colonoscopy has gained widespread acceptance as a reliable screening method for the early diagnosis of CRC since it was first introduced in 1969. Additionally, it is crucial in preventing CRC by diagnosing and removing adenomatous polyps (pre-malignant lesions of CRC). As a result, there is a steadily increasing need for screening colonoscopies worldwide” (Lee et al, 2014). “Among other indications, colonoscopy is considered as the ‘gold standard’ for early detection and removal of colorectal cancer (CRC) and its precursors” (Hazewinkel et al, 2011).

2. COLONOSCOPE

A flexible equipment with a light and lens at its tip for visibility, the modern colonoscope (Fig. 1) is a useful tool. It is normally 160–170 cm long and has four-way tip deflection. Two dials at the instrument's head are used to control cables that run the length of the shaft (Fig. 2). A fiber-optic cable that is visible at the shaft's tip connects the head to the light, and this cable—often referred to as "the umbilical cord"—connects the imaging console to the head. A color monitor is put in front of the endoscopist for vision thanks to fiber-optic connections that enable image presentation. The endoscopist and the assistant can see lesions and coordinate the use of therapeutic equipment when images are displayed in this way. Because many individuals may view the process in real time, it also enables teaching throughout the exam (Schmidt, 2004).

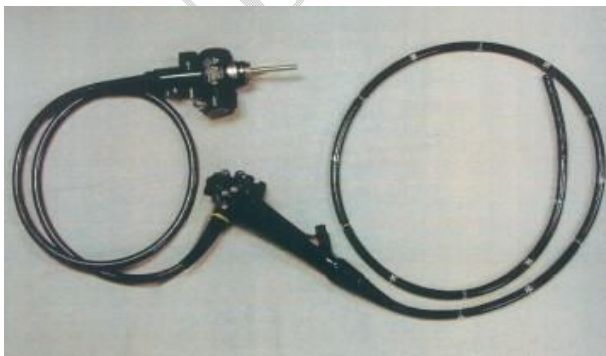


Figure 1. The modern colonoscope

Near the control dials on colonoscopes, there are two buttons (Fig. 2). One button causes the colon's contents to be suctioned via the colonoscope and into a waste canister when pressed. By sealing a tiny hole in the second button's middle, the endoscopist insufflates the colon. This button sprays water over the lens after being fully depressed to clean it (Schmidt, 2004). One or two channels are positioned beneath the instrument head in colonoscopes (Fig. 2). Due to the fact that they can be used for both, these are frequently referred to as suction or instrument channels. The passageways enable endoscopists to suck out any leftover feces or blood after flushing the colon with water. The endoscopists can suction out air or tiny polyps that have been removed. Prior to being suctioned into the primary trash canister, polyps are gathered in a trapping device. The same channels are used to provide all treatment tools (Schmidt, 2004). Some producers recently introduced colonoscopes with adjustable stiffness features. By doing this, the endoscopist can stiffen the colonoscope as it is being advanced through the colon. With these more recent colonoscopes, several studies have found that cecal intubation rates are quicker and patient satisfaction is higher. Fig. 2 shows an illustration of this kind of colonoscope in use (Schmidt, 2004).



Figure 2. The instrument head: (A) control dials; (B) suction button; (C) air/water button; (D) instrument/suction channel; (E) colonoscope stiffening control knob.

3. BODY POSITIONING FOR COLONOSCOPY

“Many gastroenterologists maintain patients in the left lateral position, changing only when difficulty is encountered” (Weinstock, 2009). The patient should be positioned in the left lateral decubitus position. However, if the situation calls for it, some medical professionals might prefer

the patient to be on their back or right side. To protect the bony prominence and to help with positioning, the patient should be lying on their left side with their legs bent and pillows positioned around their head, back, and in the space between their knees. In order to maintain stability and stop the patient from rolling forward or backward, the technician or nurse is present to help. Additionally, they help the endoscopist navigate corners and turns by applying counterpressure to the abdomen (Stauffer, 2022). The patient should be in front of the endoscopist. A digital rectal exam (DRE) with a water-soluble lubricant must be performed before inserting the scope. The clinician should now feel the patient for any masses, rectocele, lumps, or bulges. The level of sedation the patient has attained must also be considered, since this may have an impact on the anus tone. The clinician's left hand should hold the scope's handle, and the endoscope should be held in the right hand around 10 to 20 cm from the scope's working end or lens (Lin et al, 2020; Stauffer, 2022).

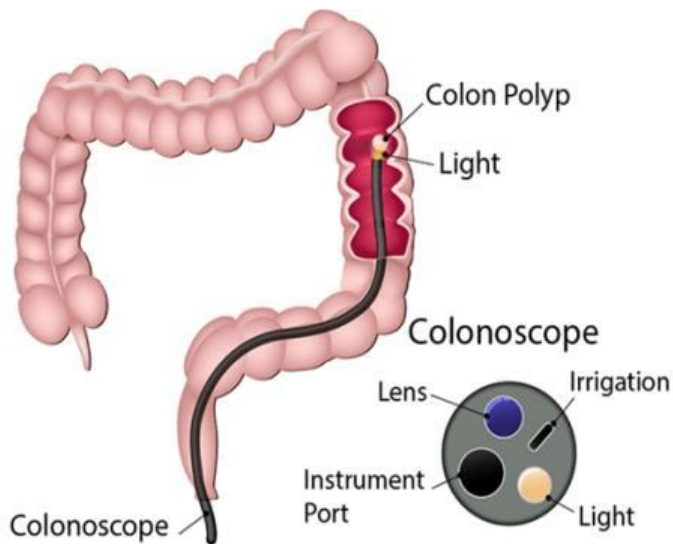


Figure 3: Image showing a colonoscope fully inserted into the colon of a patient, and also a well labelled tip of a colonoscope (John Hopkins Medicine, 2023)

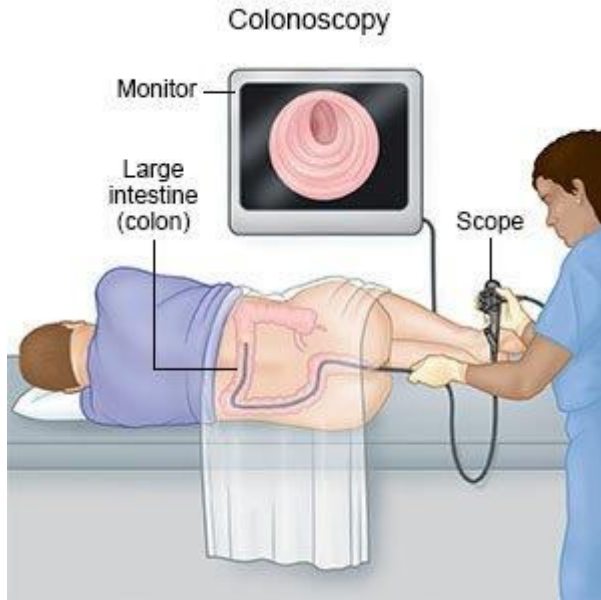


Figure 4: Image showing a patient in the left lateral decubitus position and a colonoscope fully inserted into the colon of the patient through the anus, alongside as monitor to view feedback images from the colonoscope (Drugs.com, 2023)

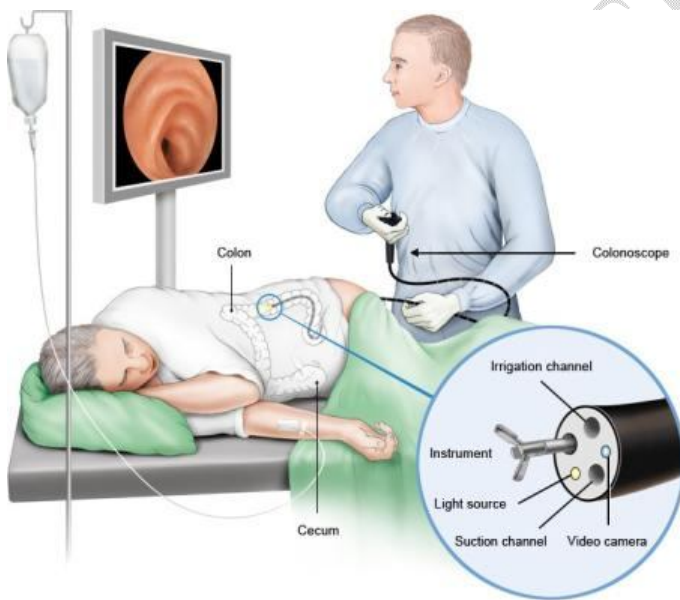


Figure 5: Image showing a patient in the right lateral decubitus position and a colonoscope fully inserted into the colon of the patient through the anus, alongside as monitor to view feedback images from the colonoscope (Informedhealth.org, 2021)

4. COLONOSCOPY PROCEDURE DESCRIPTION

The large intestine (colon) is a long tubular organ that begins at the cecum (CC) and ends at the rectum (Figure 6). Therefore, the cecum is the proximal part of the colon and the rectum is the distal part. However, since the colonoscope is inserted from the anus and passes through the rectum first, the procedure will be explained in that order.

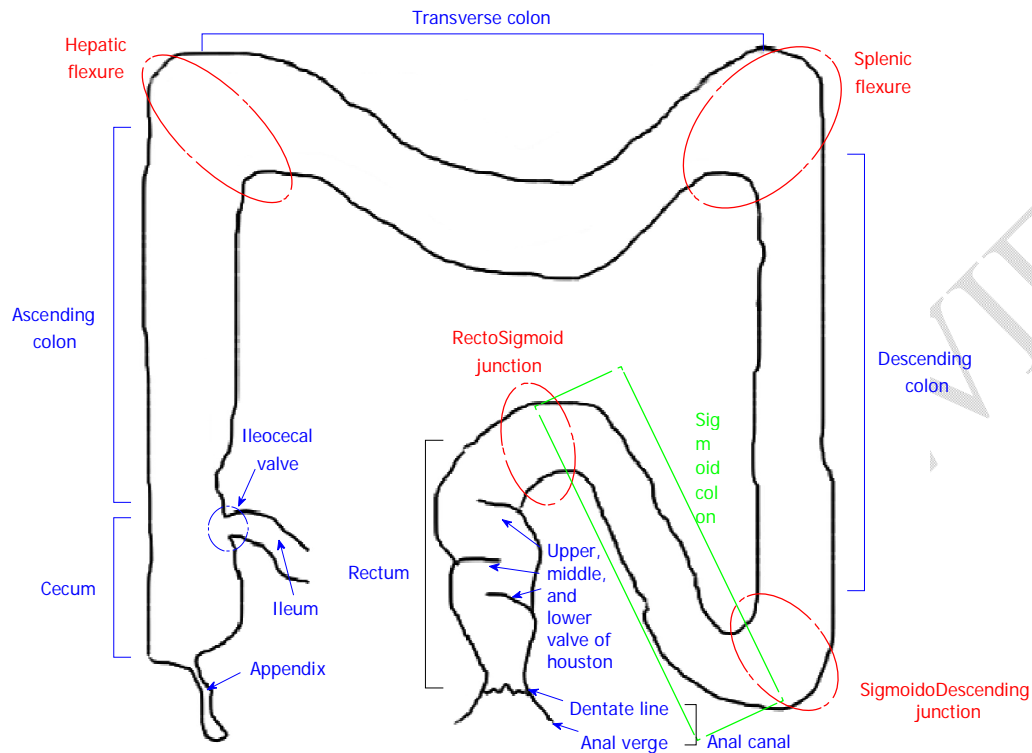


Figure 6: Schematogram of large intestine. Red dotted circles (rectosigmoid junction, sigmoidodescending junction, splenic flexure, hepatic flexure) and green dotted box (sigmoid colon) are potential difficult segments during the procedure (Lee et al, 2014).

4.1. Pre-Intubation

The patient is initially placed on the examination table in the left lateral decubitus position with knees bent and pulled up (Figure 7A). The examination begins with an inspection of the perianal region (Figure 7B). A simple inspection can detect various perianal lesions such as skin tags, scarring, anal fistulae and fissures, hemorrhoids, and prolapse (Figure 7C). Also, the digital rectal examination with topical anesthetic jelly (usually lidocaine jelly) should be performed to prelubricate the anal canal and relax the sphincters.

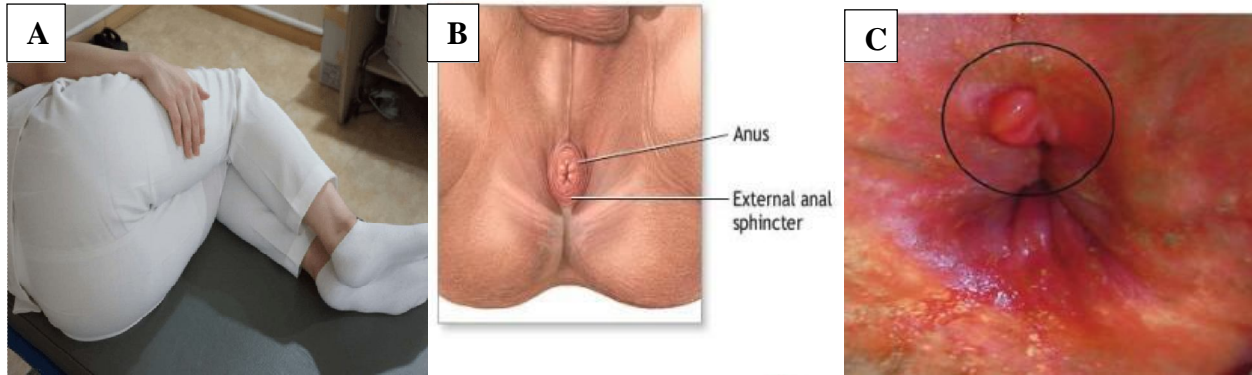


Figure 7: Procedure description. A: Diagram showing the left lateral decubitus position (the examinee with knees bent and pulled up); B: Perianal lesion; C: Anal lesions (Lee et al, 2014).

4.2. Anal Canal

“The anal canal, which connects the anal verge to the dentate line, is the terminal portion of the large intestine and is located between the rectum and anus, below the level of the pelvic diaphragm” (Yamada et al, 2022). “When the colonoscope is intubated, a red-out sign usually occurs (Figure 8A). As a result, the air/water infusion valve button must be used to inflate the anus with air. The colonoscope can be inserted without red-out when the anus has been aired out. Due to its short length and the anal sphincter, the anal canal cannot be completely viewed when the colonoscope is being inserted. The scope should be retroflexed once it has been withdrawn to the level of the distal rectum. The distal region of the rectum can be seen during retroflexion (also known as the "U-turn maneuver"), which is easier to see during insertion (Figure 8B)” (Lee et al, 2014).

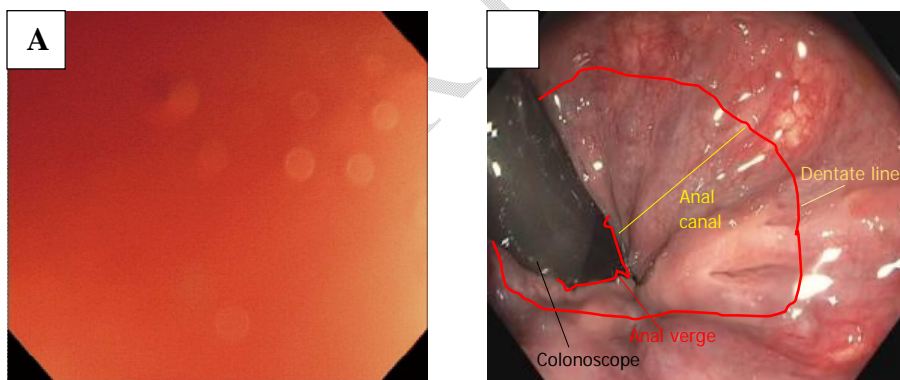


Figure 8: A: Red-out sign; B: Anal canal and distal rectum (Retroflexion view) (Lee et al, 2014).

4.3. Rectum

The rectum, which starts in front of the third sacral vertebra's body, is the sigmoid colon's natural continuation. The ventral concavity of the sacrum is aligned with the longitudinal direction of the rectum (Mahadevan, 2010). The rectum is the intestinal segment that extends from the dentate

line to the rectosigmoid junction, measuring about 15 cm (RSJ). The colonoscope can be advanced easily through this area due to the rectum's close to immobile attachment to the retroperitoneal wall. In the rectum, one can typically see Houston's valves (Figure 9). Typically, they are aligned left-right-left. Push forward (PF) with left and right twists should allow the colonoscope to move through this section without difficulty (Lee et al, 2014).

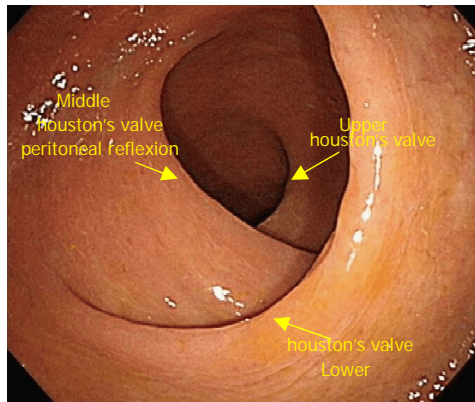


Figure 9: Rectum (Lee et al, 2014)

4.4. Rectosigmoid Junction

The rectosigmoid junction is the limit separating the sigmoid colon and rectum (Massalou et al, 2018). The region of the large intestine where the sigmoid mesocolon terminates, located between the sacral promontory and the lower margin of S2, is known as the rectosigmoid junction. Although it is morphologically regarded as a component of the sigmoid colon, the RS is more appropriately thought of as a component of the rectum since it shares a surgically significant circulatory system with the rectum above the peritoneal reflection (Mukai et al, 2011). This area is typically the first to present difficulties during colonoscope intubation. The outcome of the colonoscopic examination itself is frequently based on how well the colonoscope passes through the RSJ. The lumen typically opens to the left axis (Figure 10), and the SC-rectum junction frequently manifests as an abrupt bend in the lumen. When the colonoscope is advanced solely by pressing, a loop may form, making further advancement challenging. In light of this, it is typically beneficial to move the colonoscope while using a left torque and gentle pushing (Lee et al, 2014).

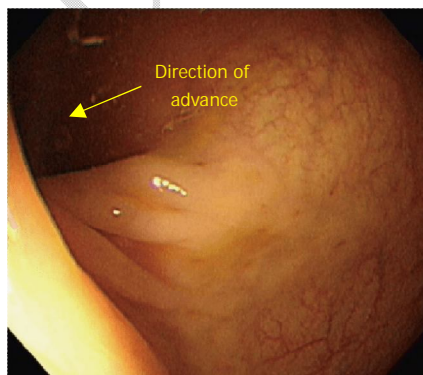


Figure 10: Rectosigmoid Junction (Lee et al, 2014)

4.5. Sigmoid Colon (Sc) And Sigmoidodescending Junction (SDJ)

“The sigmoid colon is the terminal portion of the large intestine before reaching the rectum. It connects the descending colon with the rectum” (Harkins et al, 2022). In general, especially for novice and unskilled endoscopists, the SC and SDJ are the most challenging segments to scope during insertion and the most frequent locations of iatrogenic perforation. As a result, paying extra attention is required as you move through these places. The SC is intraperitoneal and its length varies greatly (ranging from 20 to 90 cm). Additionally, the SC contains several folds that form different curves (Figure 11A), thus when the scope enters the SC, extraneous folds obliterate the lumen. It could be essential to inflate the air sufficiently to see the lumen. As the colonoscope advances inward, SC looping is inevitable, but the endoscopist can reduce loop creation utilizing a variety of techniques (jiggling, shaking, and RTS with a constant right torque). The fundamental strategy in this area is to do half-suction while making left and right bends to prevent lumen adhesion. Additionally, the assistant's manual abdominal compression and shifting the examinee's position may be beneficial. Depending on the patient, the colonoscope should be introduced for about 40 cm if progress has been made up to these segments with little loop development during intubation. In some cases, negotiating the SC's marked angle may require substantial turning of the scope tip, torquing, accordionization, and dithering techniques. When the SDJ is acutely angulated, the SC might become too aerated (Figure 11B), which makes it challenging to progress the colonoscope. Once these areas are passed without or with minimal loop formation, it should not be difficult to progress up to the CC (Lee et al, 2014).

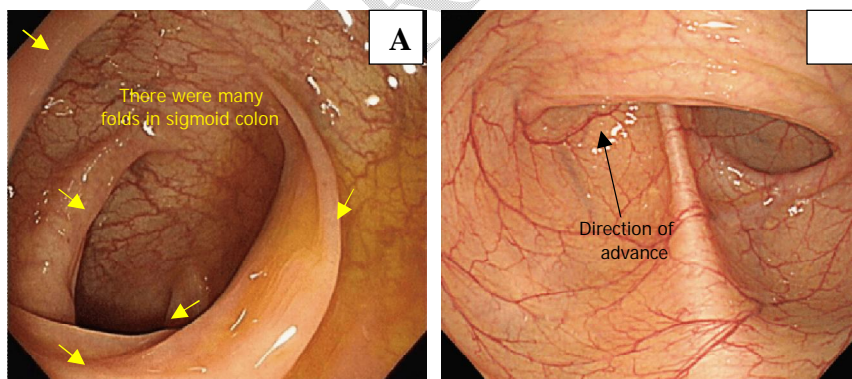


Figure 11: A: Sigmoid colon (SC); B: Sigmoidodescending junction (SDJ) (Lee et al, 2014).

4.6. Descending Colon (DC)

“The descending colon, which is between 25 and 30 cm long, descends from the left colic flexure in the left hypochondrium to the level of the iliac crest, where it curves medially anterior to the iliopsoas to become the sigmoid colon” (Lee et al, 2015). The DC appears as a long tube with concentric haustra after passing through the SDJ (Figure 12A). Typically, it has a fluid level that is horizontal and is to the right of the DC lumen (Figure 12B). PF typically suffices to pass through this area, and the DC is typically covered in a few seconds with a brief "straight" advance. Both the AC and the DC, which are linked to the retroperitoneal wall, are immobile (Lee et al, 2014).

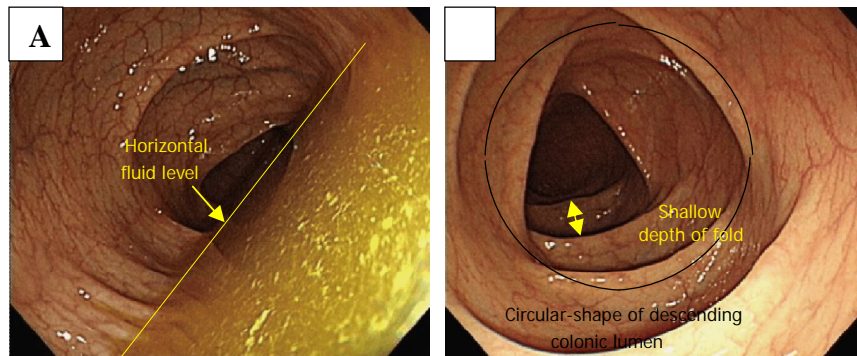


Figure 12: A: Descending colon with horizontal fluid; B: Descending colon (fluid-removal view) (Lee et al, 2014).

4.7. Splenic Flexure (SF)

“The splenic flexure is the bend where the transverse colon and descending colon meet in the upper left part of your abdomen. It is the highest point your colon reaches in your body” (Huang et al, 2022). The splenic spot visible through the intestinal lumen in the SF can be identified (Figure 13A), however it is typically less noticeable than in the HF. The highest part of the colon, the SF, is found directly behind the diaphragm (Figure 13B). To prevent the walking-stick phenomena, it is advised to progress the colonoscope through this segment with the up/down control knob in the neutral position. If progress is difficult, the examiner may switch the position of the subject and/or ask a helper to apply abdominal compression. Additionally, the non-sedated examinee may benefit from the breath holding technique since it widens the angle of the SF by bringing the diaphragm down (Lee et al, 2014).

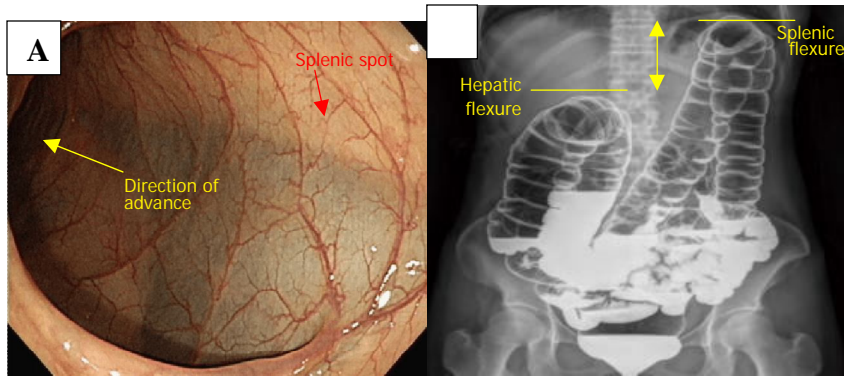


Figure 13: A: Splenic flexure and spot; B: Comparison of splenic and hepatic flexures (barium study view) (Lee et al, 2014).

4.8. Transverse Colon (TC)

“The transverse colon is a segment of the large intestine that passes horizontally across the abdomen and sits beneath other organs in the abdominal cavity” (Stelzner et al, 2016). Similar to the SC, the TC has a highly mobile lumen that is typically more triangular than the DC's (Figure 14). Since the colonoscope moves forward in relation to the air suction, air suction is useful in this situation. If progress is challenging, instruct a helper to provide abdominal compression to the umbilical region. This will stop the TC from descending to the pelvis, which will stop loop development (Lee et al, 2014).

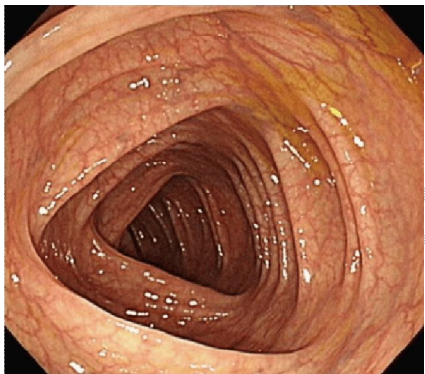


Figure 14: Transverse colon (Lee et al, 2014).

4.9. Hepatic Flexure (HF)

The hepatic flexure, also known as the right colic flexure, is made up of a curve where the transverse colon meets the liver. This part of the large intestine is most likely supported by a peritoneal fold that extends from the hepatorenal ligament. Most of the time, the hepatic spot may be seen through the mucosa, making it simple to identify the end of the TC (Figure 15A and 15B). The next section's AC lumen is typically found on the right side. Most of the time,

insertion through this portion may be accomplished without difficulty by applying air suction and a right turn in the predicted direction of the lumen. Shifting the examinee to a supine position may be useful if progress gets challenging (Lee et al, 2014).

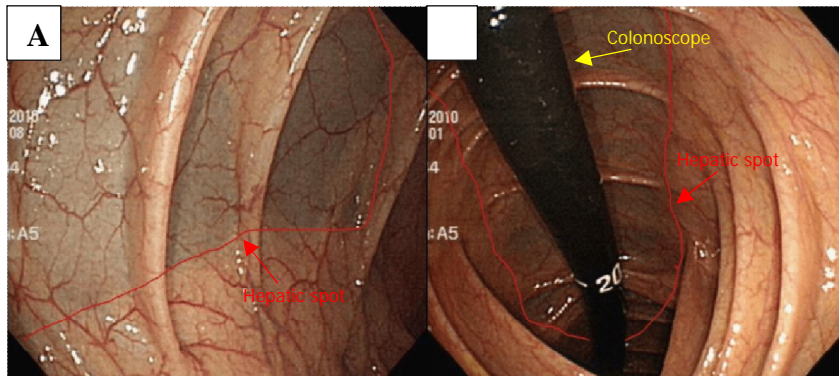


Figure 15: A: Hepatic flexure and spot; B: Hepatic flexure and spot (retroflexion view) (Lee et al, 2014).

4.10. Ascending Colon (AC)

“In front of the quadratus and transversus abdominis muscles, on the right side of the abdominal cavity, is the ascending colon. It measures 12 to 20 cm in length on average and extends from the cecum to the hepatic flexure” (Bocharova et al, 2020). Compared to the other colonic segments, the AC has thicker folds and a more triangular form (Figure 16). A straightforward straight push will advance the colonoscope to the CC, the colon's terminal point, as it is linked to the retroperitoneal wall and has limited movement (Lee et al, 2014).

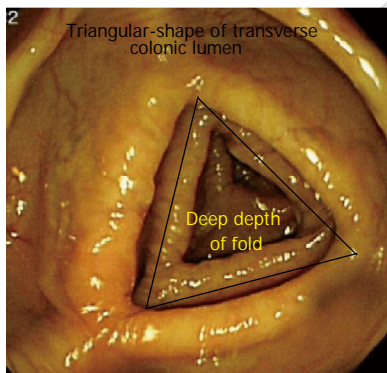


Figure 16: Ascending colon (Lee et al, 2014).

4.11. Cecum (CC)

The cecum is a blind sac that lies between the ileum's end and the large intestine's beginning (Coria-Avila et al, 2007; Guven et al, 2014). “The cecum spans the ileocecal valve (ICV) to the

cecal base. It is important to check for the ICV (Figure 17A) and the appendix orifice (Figure 17B) in order to confirm the scope's location in the cecum. If progression becomes difficult, air **insufflation** in the lumen will usually resolve the problem. Otherwise, the examiner can ask the helper to provide abdominal compressions or change the patient's position” (Lee et al, 2014).

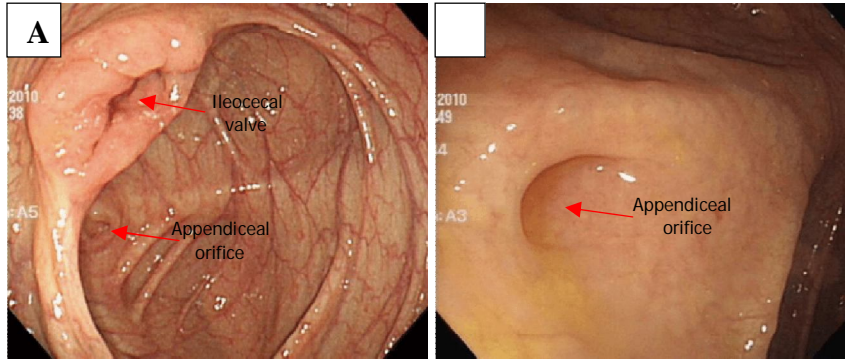


Figure 17: A: Cecum and ileocecal valve; B: Cecal base and appendix orifice (Lee et al, 2014).

4.12. Terminal Ileum (TI)

When the colonoscope reaches the CC, the ICV is typically visible on the left side of the colonoscopy screen. Normally closed, it can be opened by the scope by deflecting its tip as it approaches the ICV. The tester should repeatedly approach the ICV while utilizing air **insufflation** to open the entry. Once the ICV opens, progression will result in a red-out indicator and the visualization of the terminal ileum (Ti). The Ti is the terminus of the small intestine, and several techniques, including water filling (Figure 18A), indigocarmine dye (Figure 18B), and narrow-band imaging mode (Figure 18C), can be used to observe its distinctive villi (Lee et al, 2014).

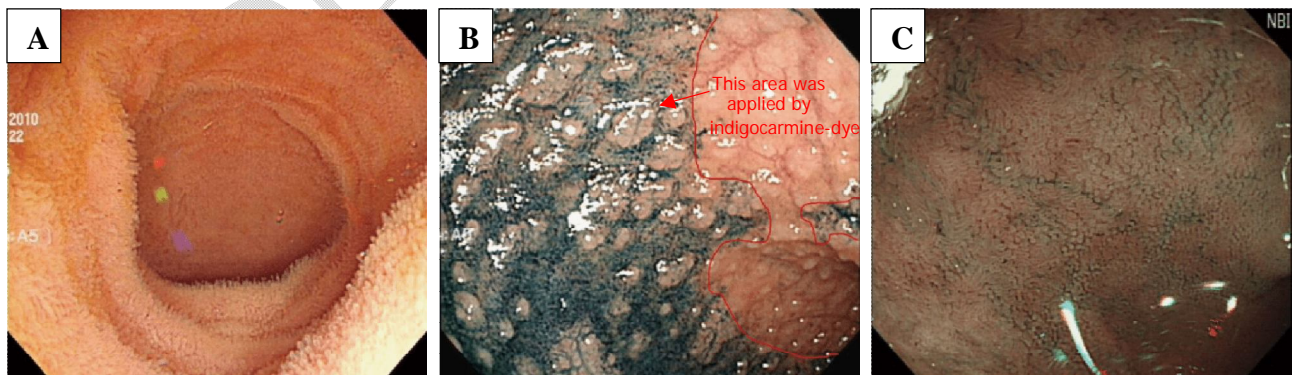


Figure 18: A: Terminal ileum (water filling view), B: Terminal ileum (indigocarmine-dye view), C: Terminal ileum (narrow-band imaging view) (Lee et al, 2014).

UNDER PEER REVIEW

5. ENDOSCOPIC ASSESSMENT OF POLYP OR CANCER IN THE COLON.

The prognosis of individuals with colorectal cancer (CRC) is undeniably reliant on the early identification and treatment of premalignant and malignant lesions. Since neoplastic polyps have been proven to be premalignant lesions, they are the primary cause of most CRCs. Histologically, colorectal polyps are classified as neoplastic (adenoma, adenocarcinoma) or non-neoplastic (hyperplastic, inflammatory, hamartomatous, *etc.*). The ideal endoscopic management of colorectal polyps involves two steps. First, any mucosal lesions need to be detected. Second, the lesions require to be characterized based on mucosal surface architecture and vessel changes; which led to an endoscopic judgment of whether the lesion is neoplastic or non-neoplastic. However, conventional white-light endoscopy is inadequate in the real-time characterization of detected lesions. For the purpose of diagnosing gastrointestinal illnesses with magnified observations, magnifying endoscopy was developed. Endoscopists are able to observe intricate features of the vascular architecture and mucosal surface pattern. Chromoendoscopy, a development in endoscopy that increased the recognition of mucosal pit pattern, was launched in 1980. Magnification endoscopy combined with narrow band imaging (NBI) is widely used in the area of advanced endoscopy (Li et al, 2014; Kanao et al, 2008).

5.1. POLYPS SURFACE PATTERN

5.1.1. Pit Pattern Classification of Polyps: Clinical introduction of magnifying endoscopic observation of the large intestine is largely attributable to the establishment of pit pattern diagnosis by Kudo et al., and the development of a magnifying video colonoscope that is capable of facilitating an *in vivo* diagnosis. The optical zoom option makes it simple to magnify an object for improved observation. High-resolution magnification video colonoscopies are currently employed in routine clinical evaluations and treatment of the alimentary canal.

Kudo *et al* first highlighted the feasibility of applying the “pit patterns” to distinguish neoplastic and nonneoplastic polyps *via* magnifying endoscopy. (Kudo *et al*) classification of colorectal polyps according to their appearance, structure and staining patterns. Type \square pits appear as roundish pits (indicates nonneoplastic mucosa); Type \square pits appear as stellar or papillary pits (indicates hyperplastic polyp or superficial type serrated adenoma and sessile serrated adenoma/polyp (SSA/P)); Type \square -s pits are small roundish, tubular pits (is characteristic of a depressed lesion and primarily indicates tubular adenomas, also is smaller than Type \square) and Type \square -L are roundish and tubular pits (primarily indicates a protruded, nodule aggregated type lesion, or an adenoma with mild to moderate atypia, also is larger than Type \square); Type \square pits appear as branch-like or gyrus-like pits (is an index for adenoma with severe atypia or SM carcinoma) and Type \square pits appear as non-structured pits. The type V pit pattern is subclassified into type VI, tumors with an irregular glandular structure, and type VN, tumors with a clear amorphous area. Type VI is an index for adenoma with severe atypia or SM carcinoma. Type-VN is an index for carcinoma with deep SM invasion. Pit pattern diagnosis using this classification can reveal the histological grade and invasion depth of lesions (Tanaka et al, 2013). Type \square and \square are considered benign changes (*e.g.*, normal, hyperplastic, inflammatory polyps),

whereas pit pattern classes □-□ are considered to show neoplastic and malignant changes (Li et al, 2014; Kanao et al, 2008).

Pit-pattern classification

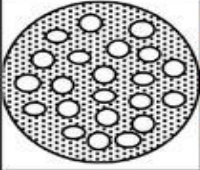

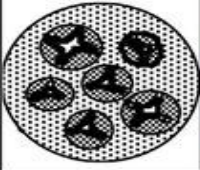

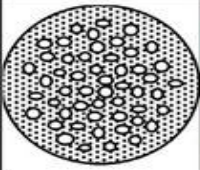







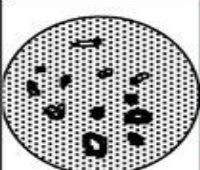

Type	Schematic	Endoscopic	Description	Suggested Pathology	Ideal Treatment
I			Round pits.	Non-neoplastic.	Endoscopic or none.
II			Stellar or papillary pits.	Non-neoplastic.	Endoscopic or none.
III _s			Small tubular or round pits that are smaller than the normal pit	Neoplastic.	Endoscopic.
III _L			Tubular or roundish pits that are larger than the normal pits.	Neoplastic.	Endoscopic.
IV			Branch-like or gyrus-like pits.	Neoplastic.	Endoscopic.
V _i			Irregularly arranged pits with type III _s , III _L , IV type pit patterns.	Neoplastic (invasive).	Endoscopic or surgical.
V _N			Non-structural pits.	Neoplastic (massive submucosal invasive).	Surgical.

Figure 19: Current pit-pattern classification of colorectal neoplasms showing description and suggested pathology (Tanaka et al, 2006).

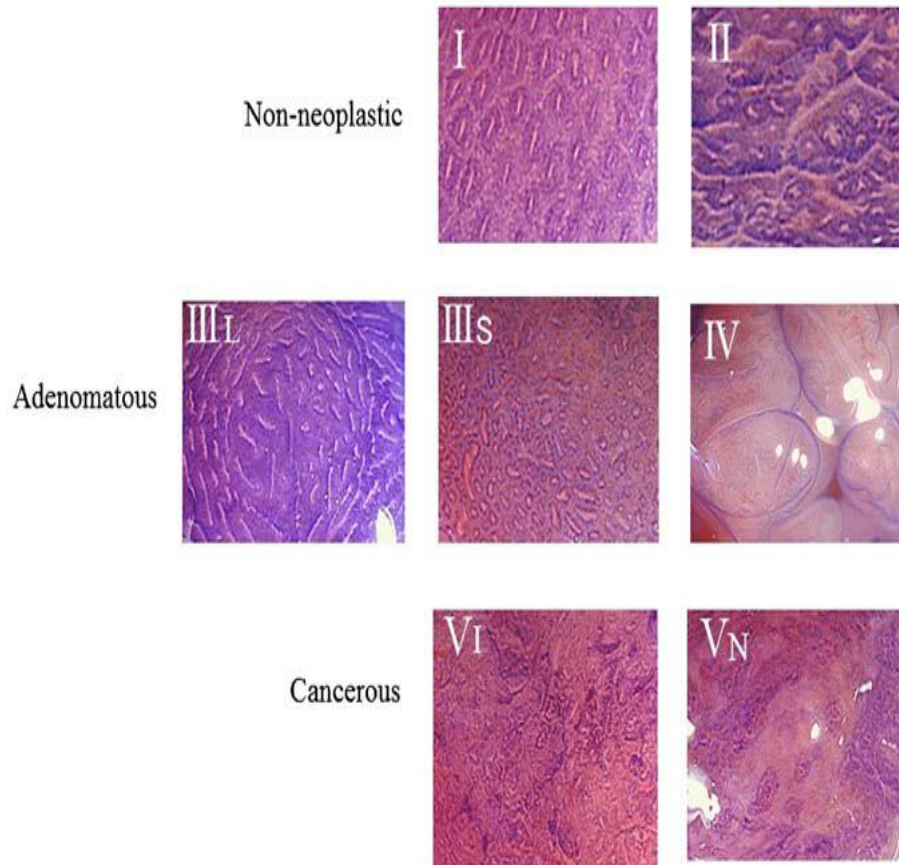


Figure 20: Kudo's pit pattern classification was composed seven type pit pattern. Type I and II indicate non-neoplastic lesions, type III_L, III_S and IV indicate adenomatous, and type VI and V_N indicate cancerous.

6. HISTOLOGICAL ASSESSMENT OF COLORECTAL POLYPS

Determining whether an endoscopic resection was effective depends on accurate histological evaluation.

6.1. DEPTH OF INVASION

6.1.1. Haggitt classification of pedunculated polyps: Haggitt et al developed “a classification system to describe the level of invasion in pedunculated polyps. This system categorizes polyps into five classes: level 0 to 4” (Figure 21). “Level 0 corresponds to neoplastic cells limited to the mucosa without breaching the muscularis mucosa, thereby not meeting the clinical definition of CRC. Level 1 corresponds to those pedunculated polyps in which cancer cells have invaded the submucosa of the polyp head. Level 2 and 3 indicate cancer cells invading into the submucosa of the neck (junction between head and stalk) and any region of the stalk, respectively. Lastly, level

4 denotes invasion of cancer cells into the submucosa of the colorectal wall below the stalk of the polyp, but not into the muscularis propria” (Mathews et al, 2021).

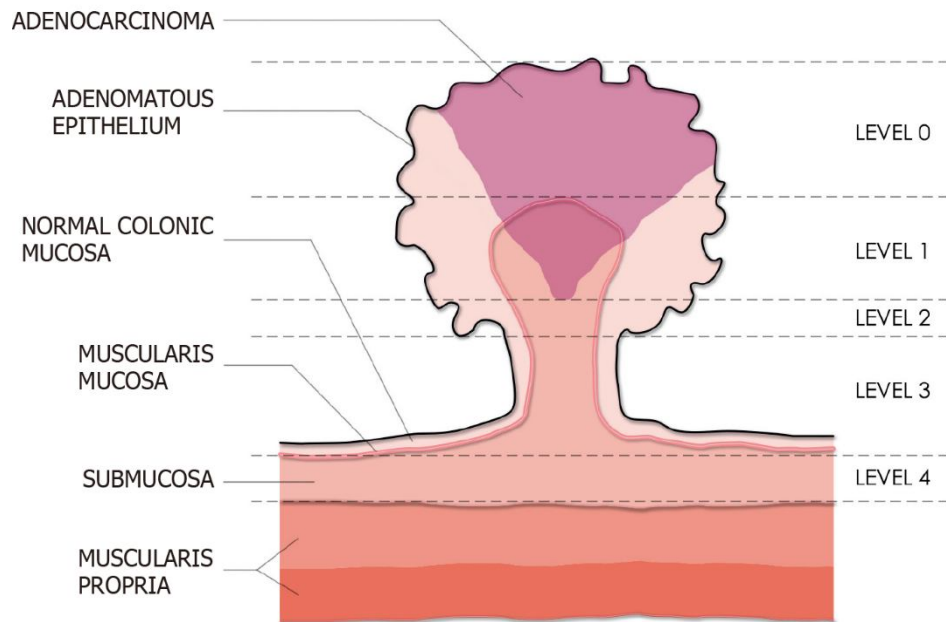


Figure 21: Haggitt classification system of pedunculated polyps (Adapted from Haggitt et al, 1985). This system categorizes polyps into five levels (level 0 to 4) based on the degree of invasion.

7. COMPLICATIONS OF COLONOSCOPY.

- A reaction to the sedative used during the exam
- Bleeding from the site where a tissue sample (biopsy) was taken or a polyp or other abnormal tissue was removed
- A tear in the colon or rectum wall (perforation)

8. RESULTS OF A COLONOSCOPY TEST

A colonoscopy is considered negative if the doctor doesn't find any abnormalities in the colon.

A colonoscopy is considered positive if the doctor finds any polyps or abnormal tissue in the colon.

CONCLUSION

The need for colonoscopy is expected to rise in the nearest future due to the expected rise in the cases of colon cancer. Colonoscopy has proved to be one of the most efficient ways to diagnose for colon cancer, and early diagnosis of cancer will lead to early intervention and help save lives. Despite the development of other screening methods, colonoscopy remains the gold standard for colon cancer detection. Research indicates that colonoscopies – regardless of whether they are performed in the hospital or at an outpatient facility, colonoscopy yield up to 94 percent accuracy rate. In this paper, we reviewed the concept of colonoscopy, the procedures, and the risk attached to it.

REFERENCE

- Ray-Offor, E., Abdulkareem, F. B. (2019). Screening colonoscopy in Port Harcourt, Nigeria. *Gastroenterology Insights*. 10:7987. doi:10.4081/gi.2019.7987.
- Rex, D. K., Johnson, D. A., Anderson, J. C., Schoenfeld, P. S., Burke, C. A., Inadomi, J. M. (2009). American College of Gastroenterology guidelines for colorectal cancer screening 2008. *American Journal of Gastroenterology*. 104(3):739–750.
- Ko, C. W., Riffle, S., Michaels, L., Morris, C., Holub, J., Shapiro, J. A., Ciol, M. A., Kimmey, M. B., Seeff, L. C., Lieberman, D. (2010). Serious complications within 30 days of screening and surveillance colonoscopy are uncommon. *Clinical Gastroenterology and Hepatology*. 8(2):166–173.
- Lee, S. H., Park, Y. K., Lee, D. J., Kim, K. M. (2014). Colonoscopy procedural skills and training for new beginners. *World J Gastroenterol*. 20(45): 16984-16995.
- Hazewinkel, Y. & Dekker, E. (2011). Colonoscopy: basic principles and novel techniques. *Nat. Rev. Gastroenterol. Hepatol*. 8: 554–564.
- Schmidt, T. D. (2004). Colonoscopy. *Encyclopedia of Gastroenterology*. 449-456.
- Vila, S., Garcia-Enicas, C., Piscocoya, A., Rios, R. E., Pinto, J., Huerta-Mercado, J., Bussaileu, A. (2009). [Use of glycerol trinitrate in an ointment for the management of chronic anal fissure at the National Hospital "Cayetano Heredia"]. *Revista de gastroenterologia del Peru: organo oficial de la Sociedad de Gastroenterologia del Peru*. 29(1):33-9.
- Yamada, Z., Saiki, Y., Komori, K., Shiomi, A., Ueno, A., Ito, M., Hida, K., Yamamoto, S., Shiozawa, M., Ishihara, S., Kanemitsu, Y., Ueno, H., Kinjo, T., Maeda, K., Kawamura, J., Fujita, F., Takahashi, K., Mizushima, T., Shimada, Y., Sasaki, S., Sunami, E., Ishida, F., Hirata, K., Ohnuma, S., Funahashi, K., Watanabe, J., Kinugasa, Y., Yamaguchi, S., Hashiguchi, Y., Ikeda,

M., Sudo, T., Komatsu, Y., Koda, K., Sakamoto, K., Okajima, M., Ishida, H., Hisamatsu, Y., Masuda, T., Mori, S., Minami, K., Hasegawa, S., Endo, S., Iwashita, A., Hamada, M., Ajioka, Y., Usuku, K., Ikeda, T., Sugihara, K. (2022). Characteristics of anal canal cancer in Japan. *Cancer Medicine*. 00:1–9.

Mahadevan, V. (2010). The anatomy of the rectum and anal canal. *Surgery*. 29:1

Massalou, D., Moszkowicz, D., Baque, P., Camuzard, O., Bronsard, N. (2018). Is it possible to give a single definition of the rectosigmoid junction? *Surg Radiol Anat*. 40(4):431-438.

Mukai, M., Kishima, K., Yamazaki, M., Aoki, H., Izumi, H., Yamamoto, S., Tajima, T., Tobita, K., Sadahiro, S., Yasuda, S., Ogoshi, K. (2011). Stage II/III Cancer of The Rectosigmoid Junction: An Independent Tumor Type? *Oncology Reports*. 26: 737-741.

Harkins, J. M., Sajjad, H. Anatomy, Abdomen and Pelvis, Sigmoid Colon. [Updated 2022 Jul 25]. In: StatPearls [Internet]. Treasure Island (FL): StatPearls Publishing; 2022 Jan-.

Lee, I., Baek, S., Kim, H., Jo, H., Oh, N., Ko, S. (2015). Survival analysis for colon subsite and rectal cancers: Experience from a single surgeon. *Korean Journal of Clinical Oncology*. 11(2): 114-119.

Huang, M. J., Wang, X. J., Shao, Y., Huang, S. H., Huang, Y., Chi, P. (2022). Surgical Treatment of Splenic Flexure Colon Cancer: Analysis of Short-Term and Long-Term Outcomes of Three Different Surgical Procedures. *Frontiers in Oncology*. 12:884484.

Stelzner, S., Hohenberger, W., Weber, K., et al. (3 more authors) (2016). Anatomy of the transverse colon revisited with respect to complete mesocolic excision and possible pathways of aberrant lymphatic tumor spread. *International Journal of Colorectal Disease*. 31(2): 377-384.

Bocharova, N., Katz, I. (2020). Absence of Ascending Colon, Persistent Transverse Colon, and Highly Movable Cecum: A Rare Congenital Abnormality with High Risk of Volvulus Formation. *ACS Case Reviews*. 2(5): 36-39.

Coria-Avila, G., Gavrilu, A., Menard, S., Ismail, N., Pfaus, J. G. (2007). Cecum location in rats and the implications for intraperitoneal injections. *Lab Anim*. 36:25-30.

Guven, H., Koc, B., Saglam, F., Bayram, I. A., Adas, G. (2014). Emergency right hemicolectomy for inflammatory cecal masses mimicking acute appendicitis. *World J Emerg Surg*. 9:7.

Stauffer, C. M. (2022). Continuing Education Activity. <https://www.statpearls.com/ArticleLibrary/viewarticle/19735>. 31th Jan, 2022.

Weinstock, L. B. (2009). Body positions for colonoscopy: value of Trendelenburg. *Gastrointestinal Endoscopy*. 69(7): 1409-1410.

Lin SY, Yaow CYL, Ng CH, Wong NW, Tham HY, Chong CS. Different position from traditional left lateral for colonoscopy? A meta-analysis and systematic review of randomized control trials. *Chronic Dis Transl Med*. 2020 Oct 22;7(1):27-34. doi: 10.1016/j.cdtm.2020.09.002. PMID: 34013177; PMCID: PMC8110879.

John Hopkins Medicine. (2023). Colonoscopy. Available at: <https://www.hopkinsmedicine.org/health/treatment-tests-and-therapies/colonoscopy> (Accessed: 3rd February, 2023).

Drugs.com. (2023). Colonoscopy. Available at: <https://www.drugs.com/cg/colonoscopy.html>. (Accessed: 3rd February, 2023).

Informedhealth.org. (2021). Colorectal cancer. Available at: <https://www.informedhealth.org/colonoscopy-information-for-men.html> (Accessed: 3rd February, 2023).

Li, M., Ali, S. M., Umm-a-Omarah Gilani, S., Liu, J., Li, Y., Zuo, X. (2014). Kudo's pit pattern classification for colorectal neoplasms: A meta-analysis. *World Journal of Gastroenterology*. 20(35): 12649-12656.

Tanaka, S., Hayashi, N., Oka, S., Chayama, K. (2013). Endoscopic Assessment of Colorectal Cancer with Superficial or Deep Submucosal Invasion Using Magnifying Colonoscopy. *Clinical Endoscopy*. 46:138-146.

Kudo, S., Tamura, S., Nakajima, T., Yamano, H., Kusaka, H., Watanabe, H. (1996). Diagnosis of colorectal tumorous lesions by magnifying endoscopy. *Gastrointestinal Endoscopy*. 44:8-14.

Tanaka, S., Kaltenbach, T., Chayama, K., Soetikno, R. (2006). High-magnification colonoscopy (with videos). *Gastrointestinal Endoscopy*. 64:604-613.

Kanao, H., Tanaka, S., Oka, S., Kaneko, I., Yoshida, S., Arihiro, K., Yoshihara, M., Chayama, K. (2008). Clinical significance of type VI pit pattern subclassification in determining the depth of invasion of colorectal neoplasms. *World Journal of Gastroenterology*. 14(2): 211-217

Mathews, A. A., Draganov, P. V., Yang, D. (2021). Endoscopic management of colorectal polyps: From benign to malignant polyps. *World Journal of Gastroenterology*. 13(9): 356-370 [PMID: [34630886](#) DOI: [10.4253/wjge.v13.i9.356](#)]

Haggitt, R. C., Glotzbach, R. E., Soffer, E. E., Wruble, L. D. (1985). Prognostic factors in colorectal carcinomas arising in adenomas: implications for lesions removed by endoscopic polypectomy. *Gastroenterology*. 89:328-336.

UNDER PEER REVIEW