

What is market in yellow is the part to review
In green is the explanation

Case report

A case report on Adenoid cystic carcinoma of nasal cavity: Successfully treated by endoscopic surgical excision

Abstract:

The sinonasal tract, which is made up of the nose, paranasal sinuses, and nasopharynx, seldom develops malignancies. It is not like this. It is not uncommon to see patients with carcinomas in these locations. That term is not correct. Only a few studies have been published, despite the fact that adenoid cystic carcinoma (ACC) is the second most prevalent cancer to develop in the sinonasal tract. It primarily consists of a minor salivary gland cancer that is located in the sinonasal cavity. We are providing a case report of a male patient, age 55, who underwent successful endoscopic endonasal treatment for a left sided nasal tumour. The reader who is looking for information reads the summary and if it is not striking, he does not read the work. Please improve the summary, say where it is done, time, evolution, etcetera...

You have 250 words to develop the summary.

Keywords: Sinonasal malignancy, adenoid cystic carcinoma, minor salivary gland, endoscopy, surgical excision

Introduction

Adenoid cystic carcinoma (ACC) is a rare malignant epithelial tumor, described at first in 1859 as "cylindroma" by Bill Roth [10]. It's common in minor salivary glands around the mouth, uncommon in parotids and rare in paranasal Sinuses and nose [11,12]. Tumors of the sinonasal tract commonly present with symptoms that are identical to those caused by inflammatory sinus disease, such as nasal obstruction, nasal discharge, epistaxis, headache, facial pain and cheek swelling [13]. We present a case report on Adenoid cystic carcinoma of nasal cavity of a 56-year-old male patient.

Where are the first bibliographies?

The introduction is very short. It should provide more epidemiological data on this tumor that demonstrate the importance of publishing this article.

At the end of the introduction the objective should appear. Without objective, why is the work done??????

Case report:

A 56-year-old male patient arrived at our Apollo E.N.T. hospital complaining of a left sided nasal blockage for the past 12 months. Over time, he became aware of a pinkish tumour in the left side of the nasal cavity. He had a history of a headache on the left side and an eye discharge. He also lamented the nasal quality of his voice. He denied any addiction. No trauma, nasal haemorrhage, anosmia, or hyposmia were in his past. No prior history of cheek fullness existed. His sight was unimpaired. On anterior rhinoscopy, the inferior turbinate was enlarged and discharged mucopurulent material. The intraoral and neck examinations were normal. Which???? On diagnostic nasal endoscopy (figure 1), Include the figures here, where they are mentioned, for a better understanding. Not at the end of the article the septum was being pushed toward the right side by a reddish mass that filled the whole left side of the nasal cavity. A contrast-enhanced computed tomography scan had been recommended noo, was indicated for the patient (Figures 2 and 3), which suggested a left-sided nasal mass occupying the left nasal cavity. The osteomeatal complex was being obstructed, and the septum was migrating to the right side. The ethmoid and maxillary sinus planes were preserved. A biopsy revealed that the patient had adenoid cystic cancer. The patient was scheduled for endoscopic removal of the nasal tumour. The patient had been informed about the nature of the illness and its potential for recurrence. Following agreement, the patient underwent an endoscopic endonasal approach for the removal of a tumour in the nose. During surgery, an endoscopic medial maxillectomy was performed. The nasolacrimal duct was severed. Complete removal of the nasal mass and submission to histology. Patient after surgery moved to recovery and continued receiving intravenous antibiotics for two days. It was identified as an adenoid cystic carcinoma in the histology report. Since the tumour was precisely localised in the nasal cavity and margins were free of tumour, we didn't recommend radiotherapy in this case. Patient had no recurrence throughout his one-year follow-up and was doing well.

This aspect is the most important in this article that corresponds to the presentation of a case. For this reason, everything related to the patient must be explained in detail and in a very thorough way. You have to follow a logical order, exposing each detail sequentially, from when he arrived, where, why.... Your individual health history.... And after everything that was done. It is necessary to provide all possible data written with a scientific nature. Something very important that is missing in this presentation is the tumor classification, it is not possible to take a therapeutic approach without TNM classification of the tumor, and explain the treatment. It is very important to say when it was operated, how long it has evolved. There are many aspects that need to be explained.

Discussion:

The sinonasal tract is home to a number of malignancies with salivary gland origins, such as adenocarcinoma, adenoid cystic carcinoma and mucoepidermoid carcinoma.⁽¹⁾ Adenoid cystic carcinoma (ACC) is the most common minor salivary gland tumour in the sinonasal tract, accounting for 10% to 25% of all ACC in the head and neck.⁽²⁻⁴⁾ Nasal blockage, facial pain, epistaxis, nasal discharge, and loss of smell are among the common presenting symptoms of sinonasal ACC; some symptoms are often seen in patients with sinusitis and inflammatory nasal diseases. Delays in diagnosis and treatment may result from this. The nasal cavity and maxillary sinus are where these tumours most frequently occur.⁽⁸⁾ Patients with nasal cavity tumours had the highest overall and disease-specific survival rates, whereas those with sphenoid tumours had the lowest rates.⁽⁵⁾ Overall, 5-year survival rates for patients with sinonasal ACC from 50% to 86% have been reported.⁽⁸⁾ Additionally, it has been noted that ACC of the paranasal sinuses has a lower metastatic rate than ACC of the primary salivary glands. Surgery is the mainstay of ACC treatment; adjuvant radiation therapy is only used if the tumour has positive margins or is advanced in stage.⁽⁵⁻⁷⁾ This is what I was referring to before, the classification of the tumor and depending on it, the treatment options are shown to the patient so that he can choose the one he prefers. For early incidence, thorough removal of the main tumour with enough tumor-free margin is advised. In contrast to squamous cell carcinomas of the head and neck, ACC rarely develops cervical lymph node metastases. However, it is believed that the occurrence of lymph node metastases is a poor predictor of distant metastasis and survival.⁽⁹⁾ The limited lymphatic distribution in the sinonasal tract and surrounding structures may be the cause of the sinonasal ACC's lower nodal metastasis rate than other ACCs of the head and neck. Patient in the current case study had no prior history of cervical lymphadenopathy. This happened because precisely this location is not characterized by metastasis, that can be explained at work and discussed here.

Although it is a case presentation, reference should be made to other cases, what was done, if there are differences in treatment, evolution

Conclusion:

Compared to other head and neck sites, particularly the minor salivary glands, paranasal sinus tumours are uncommon. Paranasal sinus adenoid cystic carcinoma is a rare condition. When the tumour is adequately localised, surgery is the preferred form of treatment. Depending on the margin situation, adjuvant radiation may or may not be necessary.

These statements are not conclusions derived from this work. And if it has not objective, why does it draw conclusions? You have to write an objective and then draw conclusions that give answers to that objective

Compliance with Ethical Standards:

The procedure performed in this case report was in accordance with the ethical standards of the institutional and/or national research committee and with the 1964 Helsinki declaration and its later amendments or comparable ethical standards.

Ethical Approval:

The study was published with the written consent of the patient.

References:

The references are wrong. They are not in order, and many do not appear in the text. They are not updated.

1. Harbo G, Grau C, Bundgaard T, et al Cancer of the nasal cavity and paranasal sinuses: clinico-pathological study of 277 patients. *Acta Oncol* 1997; 36:45–50.
2. Goepfert H, Luna MA, Lingberg RD, White AK. Malignant salivary gland tumors of the paranasal sinuses and nasal cavity. *Arch Otolaryngol* 1983; 109:662–668.
3. Bhattacharyya N. Factors affecting survival in maxillary sinus cancer. *J Oral Maxillofac Surg* 2003; 61:1016–1021.
4. Jones AS, Hamilton JW, Rowley H, et al. Adenoid cystic carcinoma of the head and neck. *Clin Otolaryngol* 1997;22: 434–443.
5. Lupinetti AD, Roberts DB, Williams MD, et al. Sinonasal adenoidcystic carcinoma: the M. D. Anderson Cancer Center experience. *Cancer* 2007;110(12):2726–2731
6. Pommier P, Liebsch NJ, Deschler DG, et al. Proton beam radiation therapy for skull base adenoid cystic carcinoma. *Arch Otolaryngol Head Neck Surg* 2006;132(11):1242–1249
7. Pitman KT, Prokopakis EP, Aydogan B, et al. The role of skull base surgery for the treatment of adenoid cystic carcinoma of the sinonasal tract. *Head Neck* 1999;21(5):402–407
8. Rhee CS, Won TB, Lee CH, et al. Adenoid cystic carcinoma of the sinonasal tract: treatment results. *Laryngoscope*. 2006; 116:982–986.
9. Spiro RH. Distant metastasis in adenoid cystic carcinoma of salivary origin. *Am J Surg* 1997;174:495–498.
10. Li Y., Hao D., Song X., Zhang C. Computed tomography and magnetic resonance imaging of adenoid cystic carcinoma in the maxillary sinus: a retrospective study with radiologic-histopathologic correlations. *Oral Surg. Oral Med. Oral Pathol. Oral Radiol.* 2020
11. Kumar V.P., Rao P.N., Kumar G.A. Adenoid cystic carcinoma of nasal cavity- a case report. *Indian J. Otolaryngol. Head Neck Surg.* 2003;55(1):43–46.
12. Lahjaouj M, Berrada O, Rayhane A, Abada RA, Rouadi S, Roubal M, Mahtar M. Advanced adenoid cystic carcinoma of maxillary sinus: Rare case report and review of literature. *International Journal of Surgery Case Reports*. 2021 Mar 1;80:105622.
13. Ghani NM, Shukri NM, Mohamad A. 2 Case reports of sinonasal adenoid cystic carcinoma: Review of the literature on surgical approaches. *Egyptian Journal of Ear, Nose, Throat and Allied Sciences*. 2016 Nov 1;17(3):173-6.

UNDER PEER REVIEW

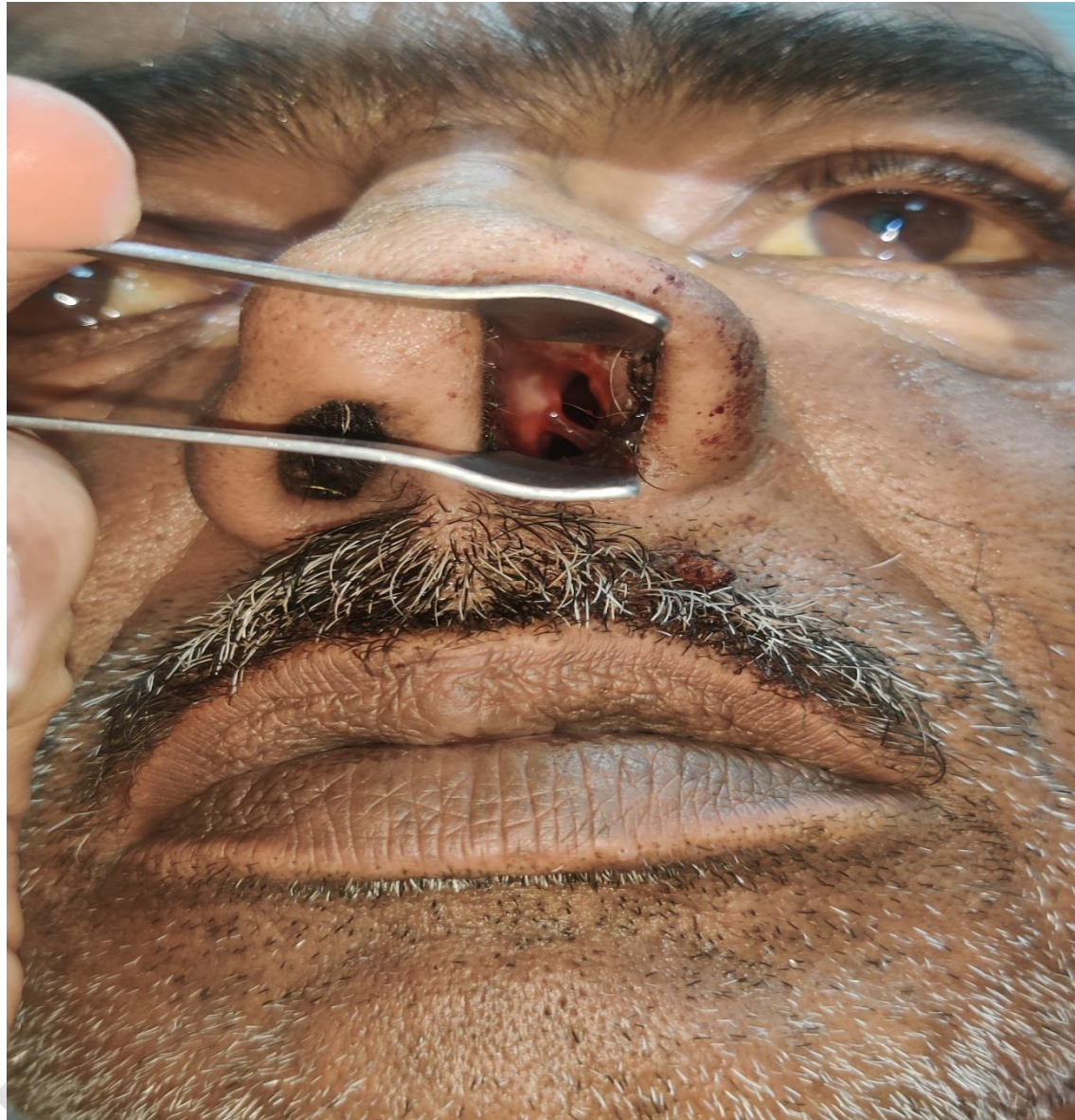

Figure 1.A Anterior rhinoscopy examination of left nasal cavity showing mass. Explain better and you can point. Cover the patient's eyes. All with the help of microsoft paint

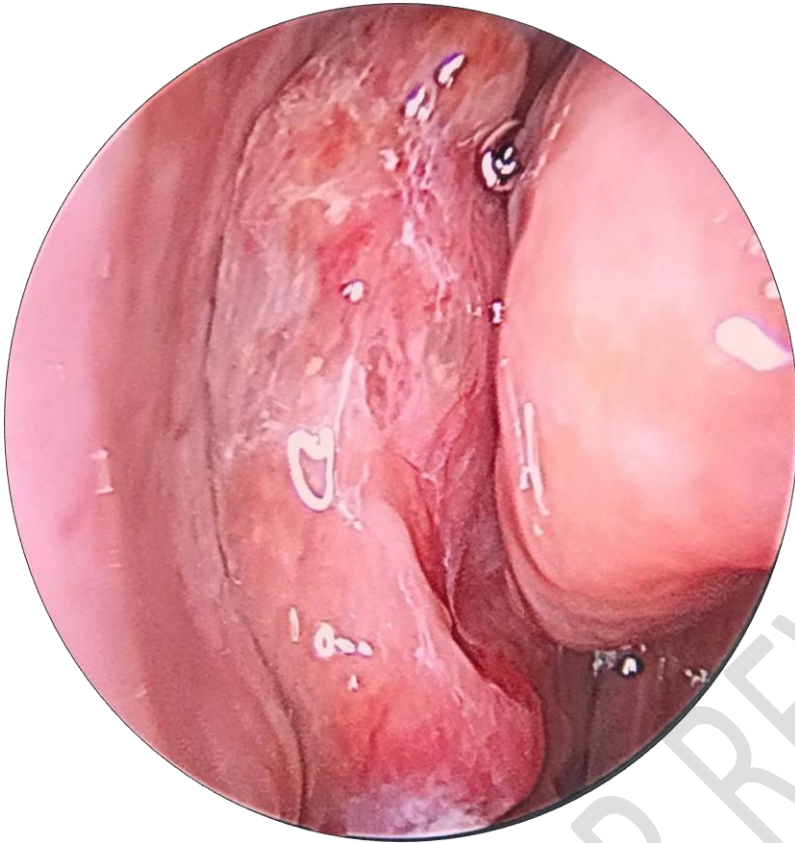


Figure 1B: Diagnostic nasal endoscopy shows nasal mass occupying the left nasal cavity. **explain and point out**

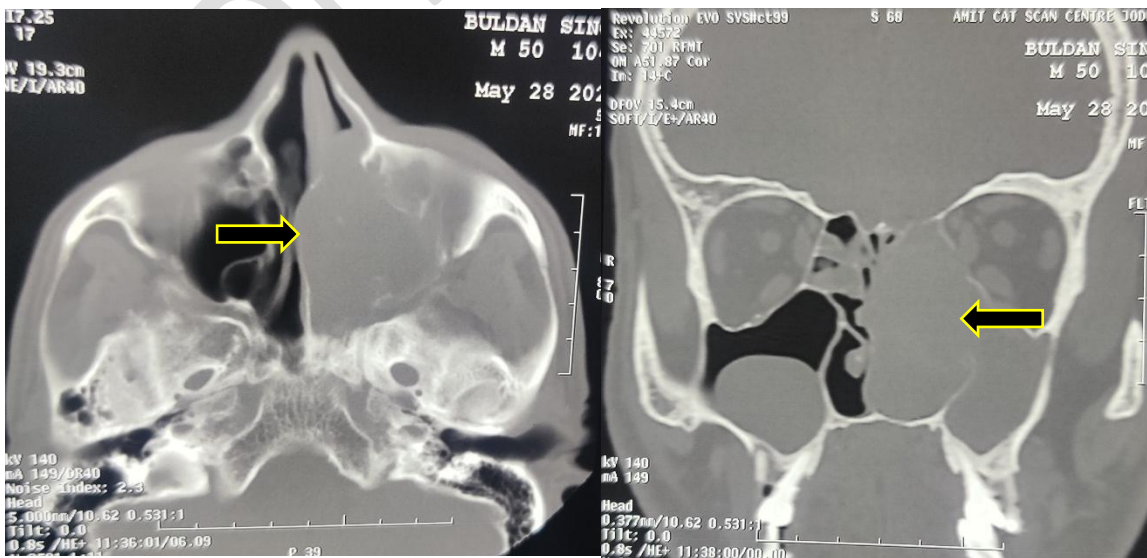


Figure 2: Axial computed tomography scan (Bone window) showing mass occupying the left nasal cavity obliterating the osteomeatal complex without any bone erosion

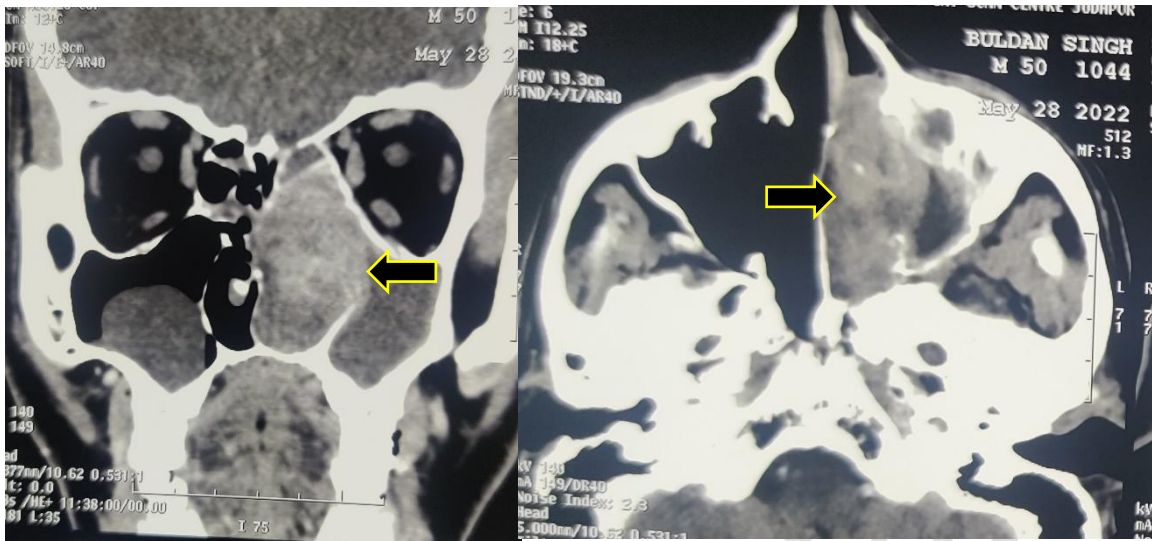

Figure 3: Axial + coronal computed tomography scan (soft tissue window) shows heterogeneously enhanced soft tissue mass occupying left side nasal cavity with retained section in left maxillary sinus. Well done, this is the idea, explained and pointed out

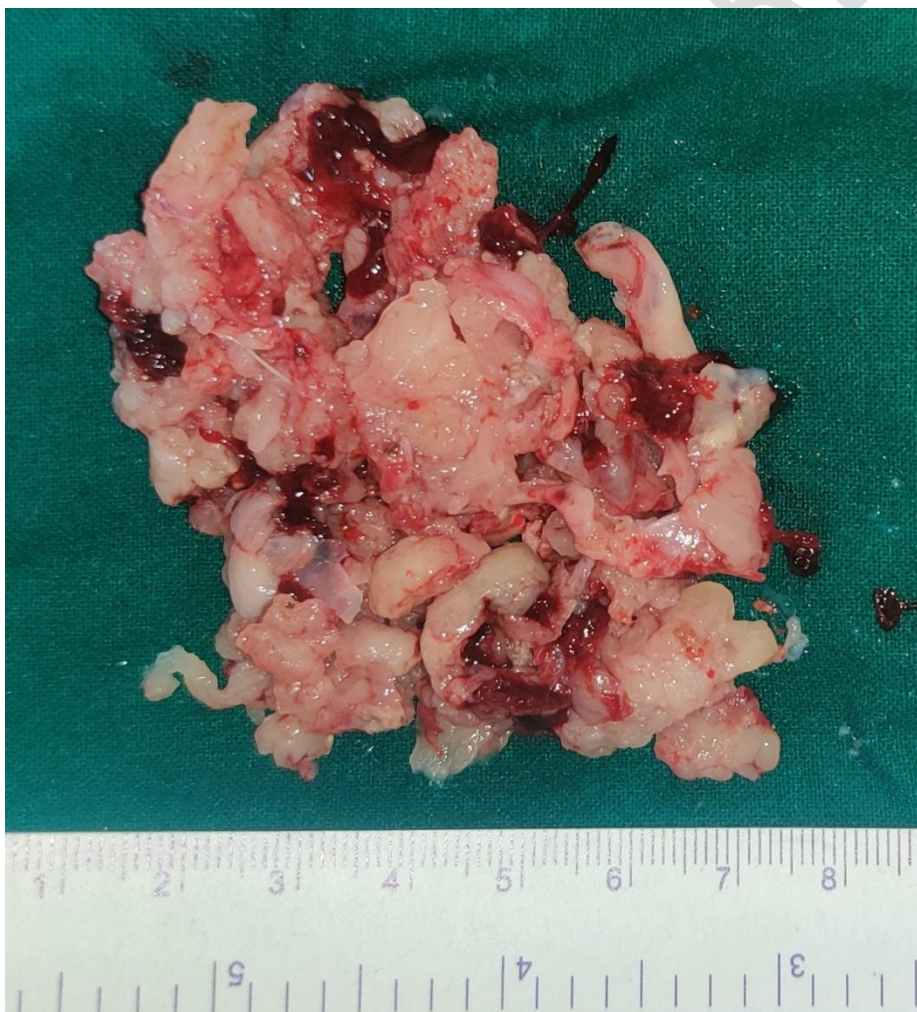


Figure 4: Main Specimen

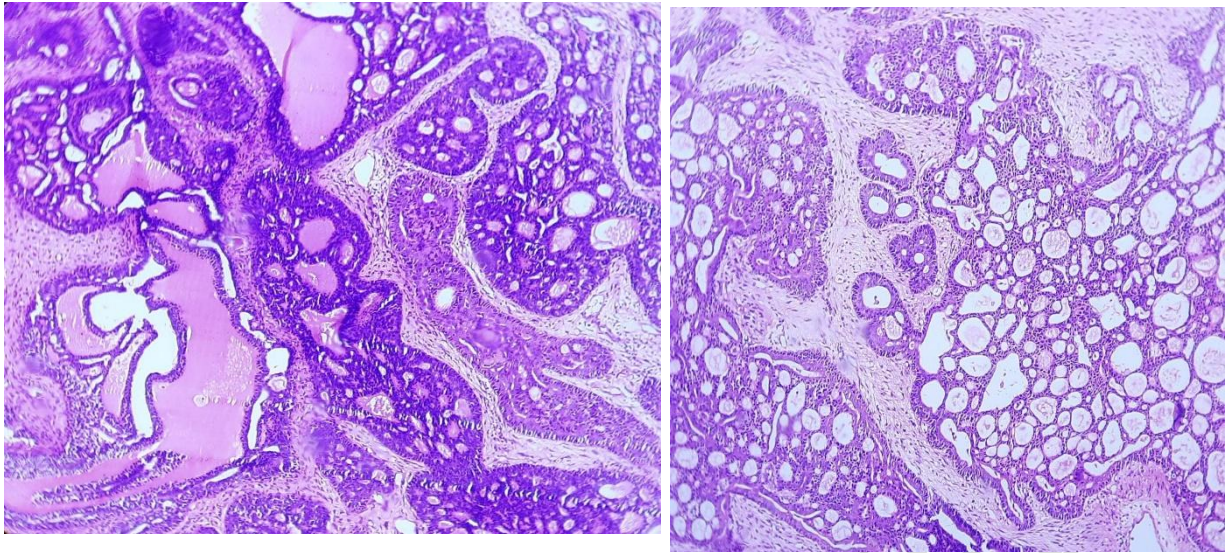


Figure 5: Histopathology slide **Also here, explain the three images**

UNDER PEER REVIEW