

**Post traumatic epilepsy with sequel of frontal contusion and
spontaneous regression of extradural hematoma;
Clinical case and review of the literature**

Abstract

Post traumatic epilepsy are frequent complications of moderate and severe head injuries, they are found in hemorrhagic contusions and hematomas. Several isolated or associated mechanisms are involved in the occurrence of these convulsions (increased inflammatory markers, neuronal cell death, altered blood-brain barrier, changes in astrocytes, and glucose metabolism dysregulation changes in synaptic abundance and function). The first attacks can occur more than 2 years after the head trauma or after cranial surgery. Preventive treatment does not change the course of the disease. Treatment with Valproate and levetiracetam were also compared to phenytoin and no benefit was found in recovery.

The particularity of our patient is the severe head trauma, with regressive frontal contusion with secular lesions, followed by the appearance at nearly three and a half months of the trauma of a fronto-parietal extradural hematoma with mass effect which resolved spontaneously. Two and three years after the trauma, he developed generalized epilepsy, suggesting post-traumatic epilepsy following the sequelae of the hemorrhagic contusion or the extradural hematoma, or the sequelae of these associated lesions. These seizures were treated with sodium valproate. This clinical case challenges clinicians to monitor in severe head injuries the occurrence of complications such as epilepsy that can occur beyond 2 years.

Key words: Epilepsia- prost Traumatic, spontanoues regression SDH,

Introduction

“Seizures were first described in relation to a "gasping wound of the head" in the Edwin Smith papyrus from Babylon, dated circa 1700 BC” (1). “The Hippocratic physicians later recognised post-traumatic convulsions and their lateralisation opposite to the side of injury” (2). Through much of the next 2000 years, Galen's philosophy of humours merged with spiritual explanations of epilepsy and it was not until the nineteenth century that understanding *progressed* to form the basis of current knowledge. In the UK, Gowers recognised the frequency of post traumatic epilepsia (PTE) and its male preponderance (3), which was shortly followed by the first epilepsy surgery of the modern era, conducted on a patient with PTE (4). “Holmes identified epilepsy as a cortical disease and used his extensive experience of traumatic brain injuries from WWI to describe a range of seizures” (5).

Globally, an estimated 2.4 million people are diagnosed with epilepsy each year

“Thus, a new person is diagnosed with epilepsy every 13s. In 60% of those affected, epileptogenesis is initiated by structural causes such as traumatic brain injury (TBI)” (6, 7, and 8). “Traumatic brain injury (TBI) is a common public health concern. More than 50 million new cases of TBI are reported each year worldwide” (9). “Post-traumatic epilepsy (PTE) is one of the most common and disabling sequel of TBI, defined as repeated unprovoked seizures seven days after TBI” (8,9,10) . “The incidence of PTE in the civilian population following TBI is 2 to 17%, and is correlated with the severity of TBI (mild TBI: 2.1%; moderate TBI:4.2%; severe TBI: 16.7%)”(11,12). “Among military patients with penetrating TBI, the incidence of PTE is significantly higher, at 22 to 53% . In terms of composition ratio, PTE accounts for 5% of epilepsy cases and 20% of symptomatic epilepsy cases” (6, 13, 14).

Post-traumatic seizures (PTS) have been classified based on the time of onset after injury (Figure 1). Those occurring within 24 hours are called "immediate." "Early seizures" appear

between 24 hours and one week. Those after one week are "late seizures (15). "In some cases, repeated unprovoked seizures one week after trauma traditionally referred to as "PTE" might occur. These are different from acute episodes (< 1 week), which are mostly triggered. The PTE can lead to a detrimental effect on the quality of life" (9, 10,16)

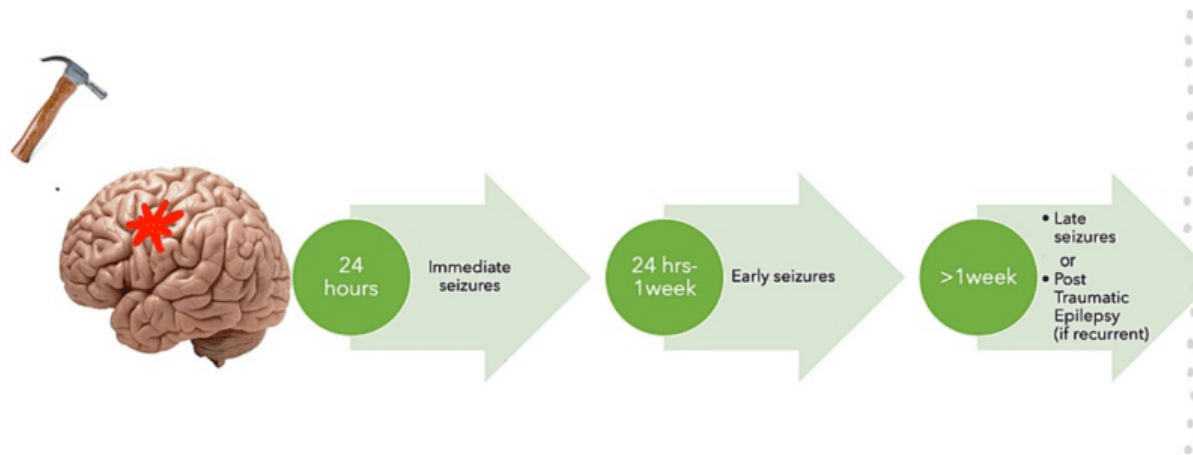


Fig 1: classification of post traumatic seizures

“Approximately 80% of TBI patients who eventually develop epilepsy will receive a PTE diagnosis within 2 years after the TBI .Multiple mechanisms have been explained in the past that led to altered brain activity provoking seizures, including increased inflammatory markers, neuronal cell death, altered blood-brain barrier, changes in astrocytes, and glucose metabolism dysregulation changes in synaptic abundance and function, and just to name a few, have been studied for their role in PTE” (8,16,18,19,20,21)

“Early seizures were seen in 4.5% of a cohort of 1000, unselected patients with head injury in Oxford” (22) and “were associated with skull fracture or intracranial haemorrhage” (5).

“Among patients of seizures due to posttraumatic intracranial hematomas (excluding chronic subdural hematomas), EDH was reported as a cause of early seizures (within 1 week of head injury) in 10% (15/146) and late seizures in 22% (13/59) patients”. (23)

“Early prophylactic antiepileptic drug (AED) therapy after TBI, which can reduce the onset of acute seizures, has not been shown to provide protective effects against the onset of later PTE” (9,24,25), we present a case report of a patient who present PTE 2 years after TBI with

contusion frontal, extradural hematoma appeared 4 months after the trauma and completely regressed before the epileptic seizures a extradural hematoma appeared 4 months after the TBI and spontanouse regressif before seisure .

Clinical cases

On 12 May 2020, we received Mr TT, aged 30 years, victim of an MVA motorcyclist not wearing a helmet with initial loss of consciousness, a GCS of 10/15 with agitation without any focal signs. A CT scan was performed urgently, showing a right frontal contusion (figure 1), with no indication for surgery.

He is managed as an inpatient and at D21 the patient is discharged from hospital with continued care at home with a GCS at 14/15 for 2 weeks and discharged to home care.

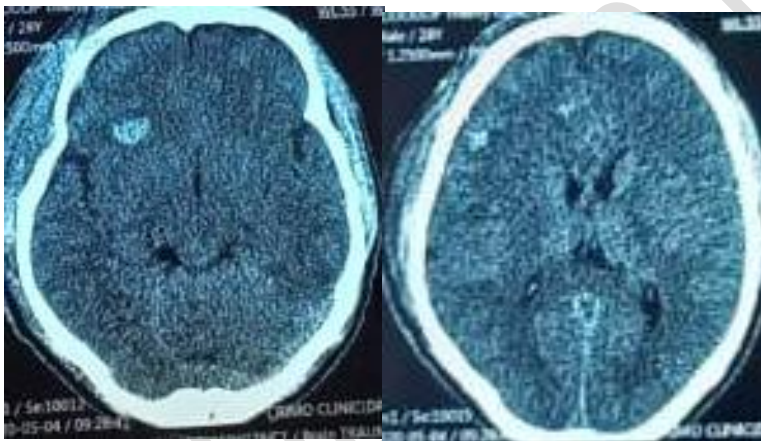


Plate 1. CT scan showing right frontal hemorrhagic contusion

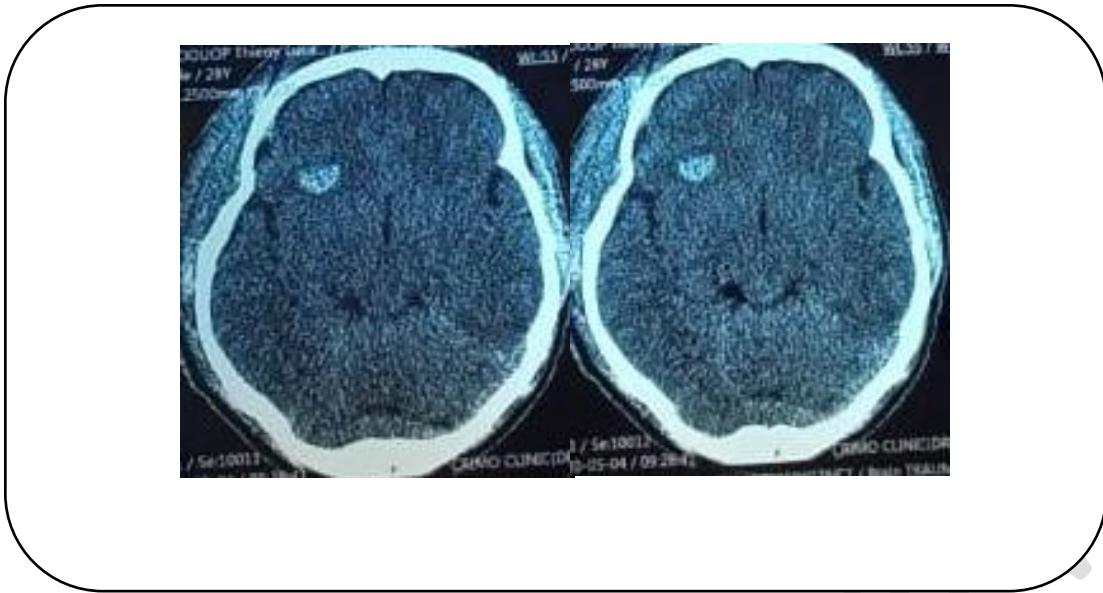


Plate 2. CT scan showing left frontal hemorrhagic contusion

He was seen in D40 post-surgery for evaluation, with memory impairment during recovery of his autonomy with GCS 15/15, the control brain CT scan shows a reappearance of the confusional haemorrhage with a right frontal hypodensity (fig 2)

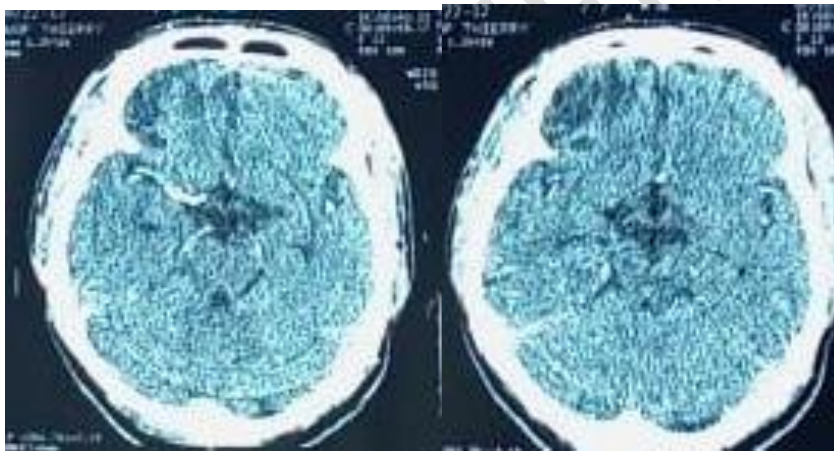


Fig 2 J 40 CT Inject and my inject, showing right frontal hypodensity

At D77 the patient was seen in consultation with right frontal headaches, more accentuated in the morning on awakening, without vomiting or motor deficits and without any signs of focalization. The control brain CT scan is requested showing a hyper dense biconcave image with effect, very suggestive of sub-acute HED, the patient declares to have had no other head trauma since the one in May 2020 above

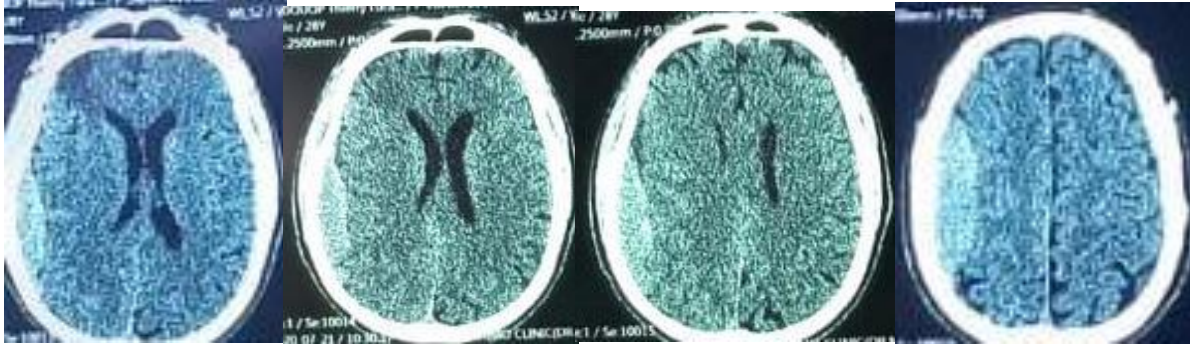

Fig 3 J77 Cerebral CT showing sub-acute HED with mass effect on the right lateral ventricle

Two years and three months after the trauma, the patient, a passenger on a bus, during a night journey from Douala to Bafoussam, found himself in the District Hospital of Dschang only in the morning, this hospital is located along the route of his journey. He has no memory of anything. According to telephone exchanges with the passenger who drove him in this hospital, he would have bought doubtful drugs on the bus and would have had 4 episodes of generalized tonic-clonic seizures with sphincter relaxation and ocular revulsion motivating the emergency hospitalization in this health structure at the end of his journey. The patient only remembers having collected his salary at the counter and went to the travel agency to pay for the Douala-Bafoussam ticket, but does not remember having paid for the travel ticket, but found the validated passenger ticket in his documents, and it is the presence of this travel ticket in his documents that attests to him having travelled; He thinks that he had received his salary on the same day, but does not remember the rest until the morning in this hospital where he was received in a state of agitation taken on the account of doubtful drug intoxication, but no drug dosage was made because of the tray.

The brain CT scan performed in emergency shows secular frontal hypodensity with complete resorption of the HED (fig 4), an EEG (fig 5) done the next day was normal.

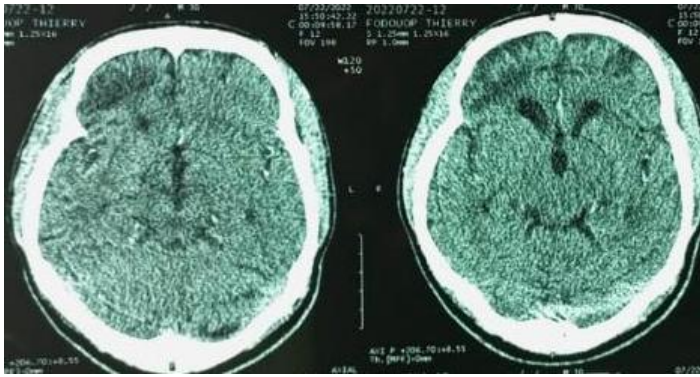


Fig 4: Control brain CT showing right frontal hypodensity without HED

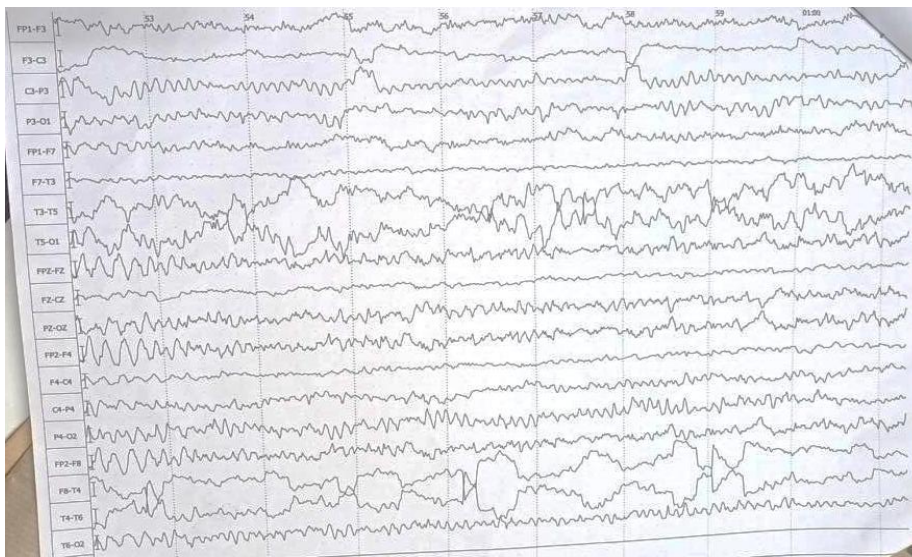


Fig. 5 NORMAL EEG

with ocular revulsion, sphincter relaxation, followed by drowsiness, lasting 5 minutes

EEG shows generalized epilepsy (fig:6), patient is put on disodium Valproate with cessation of seizures

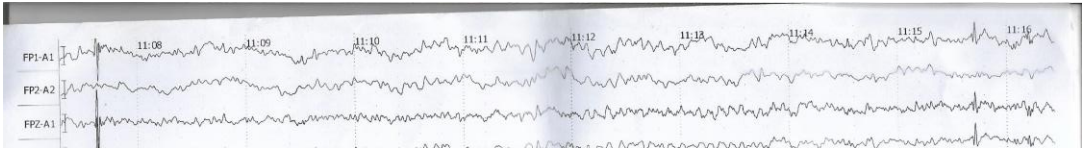
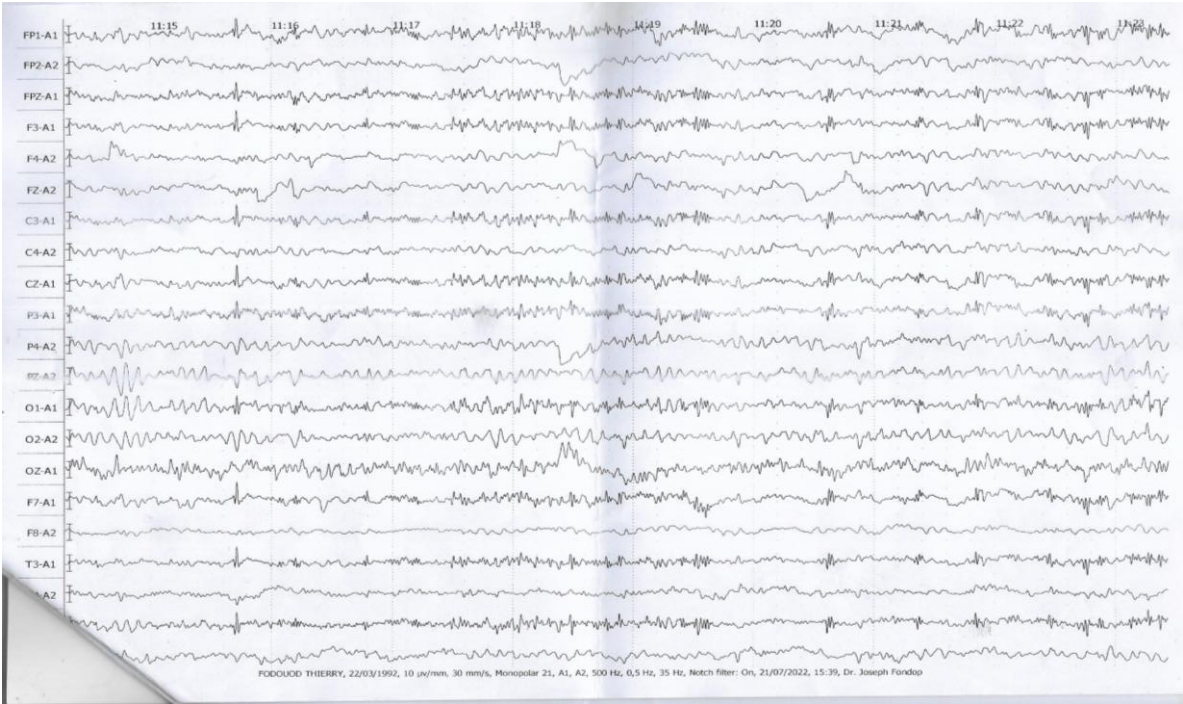


FIG 6: EEG showing a generalized seizure

DISCUSSION

“PTE is one of the most common and serious complications of TBI, leading to poor functional outcomes and a medical burden for survivors of TBI” (5, 9). “There is a lack of investigations on the clinical characteristics and latency of PTE” (9). Epilepsy is one of the most serious and distressing sequelae of CT. However, the first epileptic seizure can be delayed for several weeks or even years after the CT (10) . However, the first epileptic seizure can be delayed for several weeks or even years after the CT (10).

“The risk factors for PTE include **advanced age, penetrating injuries, injury severity** (e.g. neurosurgical procedure, intracranial hemorrhage, greater than 5 mm midline shift, duration of coma .24 hours, loss of consciousness .24 hours, prolonged length of post-traumatic amnesia), biparietal or multiple contusions, and frontal or temporal locations of the lesion In penetrating brain injury, a foreign body pierces the bony skull and passes into (and in some cases through) the substance of the brain. This leads to physical disruption of neurons, glial cells and fibre tracts Studies of the consequences of missile injuries to the head from World War I up through conflicts in the Middle East during the 1980s have shown a remarkably consistent pattern in terms of the development of epilepsy after this severe form of TBI. Studies of the consequences of missile injuries to the head from World War I up through conflicts in the Middle East during the 1980s have shown a remarkably consistent pattern in terms of the development of epilepsy after this severe form of TBI. The Vietnam Head Injury

Study, for example, found that incidence of PTE was 53% during the 15 years after the injury, with half still having seizures after 15 years” (26).

About 5% of patients with head injuries develop epilepsy, the incidence increasing with severity of injury. Attacks occur more often in the first week after trauma than subsequently, but they differ from late attacks both in character and in the factors affecting their incidence. These early attacks often have a focal onset, particularly when post-traumatic amnesia exceeds 24 hours or an intracranial haematoma is present; and 40% of patients have focal motor attacks only.

“Early seizures were seen in 4.5% of a cohort of 1000 unselected patients with head injury in Oxford” (22) and “were associated with skull fracture or intracranial haemorrhage” (5). “The incidence of early epilepsy is the same in older children and adults but is doubled in children under 5, indicating the susceptibility of the immature brain to seizures”(5). “Some studies suggested that epilepsy susceptibility after TBI increases with age, and might be associated with neuroinflammation, decreased neuronal metabolism, neuronal degeneration, and abnormal cerebral hemodynamics” (27). “Interestingly, epileptic discharges in juveniles were more frequent than in adults during the acute phase of TBI. A multicenter study reported that epileptic discharges were observed in 42.5% of TBI cases in children, and younger age was a significant risk factor for post-traumatic seizure and status epilepticus during the acute phase(38). The differences in the risk of epileptic seizures between adult and juvenile patients at different periods after TBI are related to the characteristics of brain development of patients of different ages: the cerebral cortex of juvenile patients is immature, the function of inhibiting nerve reflex is not established yet, and they are more sensitive to external injury

stimuli. Therefore, abnormal discharges of cerebral neurons are more likely to occur in the acute phase of TBI for juvenile patients, which presents as sub-clinical epileptic discharge or acute symptomatic seizures. At the same time, the young brain of juvenile patients is more malleable and adaptable than the aging brain, so it is less likely to form a chronic epileptic brain network after the acute phase of TBI".(9)

"The severity of TBI is an established etiological risk factor for PTE" (11, 13, 29,30) . "It was reported that patients who had more severe TBI may develop recurrent seizures within a shorter time interval and may have more frequent seizures, In terms of the distribution of PTE latency, we found that there was no difference between participants who had mild TBI and moderate TBI. PTE latency in participants that suffered severe TBI was related to their post-TBI treatments" (9). This observation is not only related to the brain damage caused by TBI, but also to the secondary brain damage caused by the operation itself. As seizures are mainly related to abnormal discharges of the cerebral cortical network, patients with severe TBI are more likely to have damage in the deep brain and even the brain stem rather than the cerebral cortex or subcortical, which might explain why they have a longer latency, While it has been reported that the high incidence of PTE may be related to multiple cranio cerebral injuries and lesion location (the temporal lobe)(31,32), we found that latency was not affected by single or multiple cranio cerebral injuries.

"Jamjoom et al note in their work on epilepsy and extradural haematomas that the risk of late epilepsy after an isolated extradural haematoma is small. Additional intradural abnormality substantially increases the risk of epilepsy" (33)

"Three factors increase the likelihood of late epilepsy. The incidence is 3000 in patients with an intracranial haematoma, 25%, in those with early epilepsy, and 15% in those with a depressed fracture. When none of these factors is present the incidence is only 1%, If a patient has either a haematoma or early epilepsy additional factors do not seem to increase the risk of

developing late epilepsy, but the incidence of epilepsy in patients with a depressed fracture varies from less than 4% to 60% and depends on four variables duration of post-traumatic amnesia; whether the dura is torn; the occurrence of early epilepsy; and the presence of focal signs” (34) ; Moreover, in the work of Adil et al, the first post-traumatic epileptic seizure occurs from the second after the trauma. Our patient had, a very long amnesia, hemorrhagic contusion, an extradural hematoma constituted and resorbed. These criteria confirm the posttraumatic etiology of his crisis(10).

- Physiology :

Epileptogenesis is thought to be initiated by specific types of cell loss and neuronal reorganization, which results not only in enhanced excitation, but also in decreased inhibition, predisposing to hypersynchronization. (35) “Brain injuries also lead to upregulation of proinflammatory cytokines and activated immune responses to further increase seizure susceptibility, promote neuronal excitability, and impair blood-brain barrier (BBB) integrity”.(36,37) “Early changes include the induction of immediate early genes and post-translational modifications of neurotransmitter receptor and ion channel/transporter proteins”.(38) Within days, neuronal death, initiation of an inflammatory

- cascade, and new gene transcription has been reported to occur(39). “Later (days to weeks) anatomic changes include axonal sprouting and dendritic modifications. For example, mossy fiber sprouting can be observed in chronic epileptic brain”.(40) “Over time, seizure threshold is lowered by a growing increase in excitability, and the risk of a seizure increases”.(25,41,42)

Antiepileptic treatment is often prescribed in cases of severe severe CT, especially in the neurosurgical setting (as is the case in most neurosurgical setting (as is the case in the

majority of our patients). It has been shown that with Phenytoin and Carbamazepine, there is a decrease in seizures in the first week but no in the first week but no significant protective effect was protective effect was observed between the 8th day and the end of the of the 2nd year ;Valproate and levetiracetam were also compared to phenytoin and no benefit was found. The Brain Trauma Foundation Guideline does

not make a recommendation (43). Prophylaxis for those who have not had seizures cannot be recommended without better classification of risk the prescription is what justified the non systematic prescription of antiepileptic drugs to our patient (5).the risk of post-traumatic epilepsy must be presented to the patient, presenting a potentially epileptogenic cranial trauma in order not to ignore the occurrence nor to delay the management of a pot traumatic seizure

Conclusion

Posttraumatic epilepsy is found more in male patients of average age as well as with patients with severe head trauma, all types of anatomical lesions of head trauma may be involved

The first seizures may occur several weeks, months or even years after the trauma. Antiepileptic prophylaxis does not prevent the occurrence of seizures.

Consent

As per international standard or university standard, patient(s) written consent has been collected and preserved by the author(s).

Ethical Approval:

As per international standard or university standard written ethical approval has been collected and preserved by the author(s).

REFERENCES

- 1 - Magiorkinis E, Sidiropoulou K, Diamantis A (2010) Hallmarks in the history of epilepsy: epilepsy in antiquity. *Epilepsy Behav* 17:103-108.
<https://doi.org/10.1016/j.yebeh.2009.10.023>
- 2 - Temkin O (1971) *Epilepsy in Ancient Medical Science. Falling Sick.* Johns Hopkins Press, Baltimore, pp 28-65
- 3 -. Gowers WR (1881) *Epilepsy and other chronic convulsive diseases.* Churchill, London
- 4- Horsley V (1886) Brain surgery. *Br Med J* 2:670-675
- 5-Surina Fordington¹ - Mark Manford² , A review of seizures and epilepsy following traumatic brain injury , *Journal of Neurology* (2020) 267:3105-3111 ,
<https://doi.org/10.1007/s00415-020-09926-w>
- 6- Hauser WA, Annegers JF, Kurland LT. Incidence of epilepsy and unprovoked seizures in Rochester, Minnesota: 1935-1984. *Epilepsia.* 1993;34(3):453-68.
- 7-. Scheffer IE, Berkovic S, Capovilla G, Connolly MB, French J, Guilhoto L, et al. ILAE classification of the epilepsies: Position paper of the ILAE Commission for Classification and

Terminology. *Epilepsia* [Internet]. 2017;58(4):512-21. Available from:
<http://www.ncbi.nlm.nih.gov/pubmed/28276062>

8- Chris G. Dulla¹ , - Asla Pitkänen² , Novel Approaches to Prevent Epileptogenesis After Traumatic Brain Injury Neurotherapeutics (2021) 18:1582-1601 ,
<https://doi.org/10.1007/s13311-021-01119-1>

9- Tingting Yu^{1,2}, Xiao Liu^{1,2}, Lei Sun^{1,2}, Jianping Wu^{1,2,3} and Qun Wang^{1,2,4*} Clinical characteristics of post-traumatic epilepsy and the factors affecting the latency of PTE , *BMC Neurology* (2021) 21:301

10- Adil Essanhaji¹, Najib Kissani², Bouchaib Kadiri ; Post-traumatic epilepsy in severe head trauma, retrospective analysis of a series of 40 cases in Marrakech Morocco ; *North African and Middle East Epilepsy Journal*, Volume 4 - Number 1 - January - February - 2015

11- Annegres JF, Hauser WA, Coan SP, Rocca WA. A population-based study of seizures after traumatic brain injuries. *N Engl J Med*. 1988;338:20-4.

12-. Karlander M, Ljungqvist J, Zelano J. Post- traumatic epilepsy in adults: a nationwide register- based study. *J Neurol Neurosurg Psychiatry*. 2021;9:617-21.

13-. Lowenstein DH. Epilepsy after head injury: an overview. *Epilepsia*. 2009;50(Suppl 2):4-9. <https://doi.org/10.1111/j.1528-1167.2008.02004.x>.

14- Christensen J. The epidemiology of posttraumatic epilepsy. *Semin Neurol*.2015;35(3): 218-22. <https://doi.org/10.1055/s-0035-15529237-1> Jennett WB (1961) Late epilepsy after blunt head injuries. A clinical study based on 282 cases of traumatic epilepsy. *J R Coll Surg Engl* 29:370-384

. 15- Englander J, Bushnik T, Duong TT, Cifu DX, Zafonte R, Wright J, et al. Analyzing risk factors for late posttraumatic seizures: a prospective, multicenter investigation. *Arch Phys Med Rehabil.* 2003;84(3):365-73. <https://doi.org/10.1053/apmr.2003.50022>.

16- **Fatima Anwer , Federico Oliveri , Fotios Kakargias , Priyanka Panday , Ana P. Arcia Franchini , Beshoy Iskander , Pousette Hamid ,** Post-Traumatic Seizures: A Deep-Dive Into Pathogenesis , *Cureus* 13(4),2021 :e14395. DOI 10.7759/cureus.14395

17- Fatima Anwer , Federico Oliveri , Fotios Kakargias , Priyanka Panday , Ana P. Arcia Franchini , Beshoy Iskander , Pousette Hamid Post-Traumatic Seizures: A Deep-Dive into Pathogenesis , 2021 *Cureus* 13(4): e14395. DOI 10.7759/cureus.14395

18-. Koenig JB, Dulla CG. Dysregulated glucose metabolism as an atherapeutic target to reduce post-traumatic epilepsy. *Front Cell Neurosci.* 2018;12(October):1–19.

19-. Sharma S, Tiarks G, Haight J, Bassuk AG. Neuropathophysiological Mechanisms and Treatment Strategies for Post-traumatic Epilepsy. *Front Mol Neurosci.* 2021;14(February).-

20-Dudek FE. Epileptogenesis: a new twist on the balance of excitation and inhibition. *Epilepsy curr* 2009; 9, 6:174-6

21 - Parmontree P, Tunthanathip T, Doungnern T, Rojpitbulstit M, Kulviwat W, Ratanalert S. Predictive risk factors for early seizures in traumatic brain injury. *J Neurosci Rural Pract* 2019;10(4):582-587

22- Jennett WB (1961) Late epilepsy after blunt head injuries. A clinical study based on 282 cases of traumatic epilepsy. *J R Coll Surg Engl* 29:370-384

23- Adesh Shrivastava, Md Moshiur Rahman ;: Luis Rafael Moscote-Salazar , Rajeev Ravish Keni , Manas Prakash, Amit Agrawal , Review of Literature on Post-traumatic Epilepsy in Extradural Hematoma Patients: A Case for Further Comprehensive Research, Indian Journal of Neurotrauma

24- Benardo LS. Prevention of epilepsy after head trauma: do we need new drugs or a new approach? *Epilepsia*. 2003;44(s10):27-33. <https://doi.org/10.1046/j.1528-1157.44.s10.2.x>.

25- Benardo LS. Prevention of epilepsy after head trauma: do we need new drugs or a new approach? *Epilepsia*. 2003;44(s10):27-33. <https://doi.org/10.1046/j.1528-1157.44.s10.2.x>.

26-Cory D. Lamar, M.D., Robin A. Hurley, M.D., Jared A. Rowland, Ph.D., Katherine H. Taber, Ph.D , Post-Traumatic Epilepsy: Review of Risks, Pathophysiology, and Potential Biomarkers , *Neuropsychiatry Clin Neurosci* 26:2, Spring 2014

27- van Vliet EA, Ndoe-Ekane XE, Lehto LJ, Gorter JA, Andrade P, Aronica E, et al. Long-lasting blood-brain barrier dysfunction and neuroinflammation after traumatic brain injury. *Neurobiol Dis*. 2020;145:105080. <https://doi.org/10.1016/j.nbd.2020.105080>.

28-Arndt DH, Lerner JT, Matsumoto JH, Madikians A, Yudovin S, Valino H, et al. Subclinical early posttraumatic seizures detected by continuous EEG monitoring in a consecutive pediatric cohort. *Epilepsia*. 2013;54(10):1780–8. <https://doi.org/10.1111/epi.12369>

29-Christensen J, Pedersen MG, Pedersen CB, Sidenius P, Olsen J, Vestergaard

M. Long-term risk of epilepsy after traumatic brain injury in children anyoung adults: a population-based cohort study. *Lancet.* 2009;373(9669):1105–10. [https://doi.org/10.1016/S0140-6736\(09\)60214-2](https://doi.org/10.1016/S0140-6736(09)60214-2).

30- Xu T, Yu X, Ou S, Liu X, Yuan J, Huang H, et al. Risk factors for posttraumatic epilepsy: a systematic review and meta-analysis. *Epilepsy Behav.* 2017;67:1-6. <https://doi.org/10.1016/j.yebeh.2016.10.026>.

31-Englander J, Bushnik T, Duong TT, Cifu DX, Zafonte R, Wright J, et al. Analyzing risk factors for late posttraumatic seizures: a prospective, multicenter investigation. *Arch Phys Med Rehabil.* 2003;84(3):365-73. <https://doi.org/10.1053/apmr.2003.50022>.

32-Tubi MA, Lutkenhoff E, Blanco MB, McArthur D, Villablanca P, Ellingson B, et al. Early seizures and temporal lobe trauma predict post-traumatic epilepsy: a longitudinal study. *Neurobiol Dis.* 2019;123:115-21. <https://doi.org/10.1016/j.nbd.2018.05.014>

33-A B Jamjoom, N Kane, D Sandeman, B Cummins, Epilepsy related to traumatic extradural haematomas, *bmj* volume 302 23 february 1991

34-Post traumatic epilepsy, *British medical journal*, 6132, P 229, 22 july 1978

35-Engel JJ Jr, Wilson C, Bragin A: Advances in understanding the process of epileptogenesis based on patient material: what can the patient tell us? *Epilepsia* 2003; 44(Suppl 12):60-71

36- Vezzani A, Friedman A, Dingledine RJ: The role of inflammation in epileptogenesis. *Neuropharmacology* 2013; 69:16-24

37-Xu D, Miller SD, Koh S: Immune mechanisms in epileptogenesis. *Front Cell Neurosci* 2013; 7:195

38-McNamara JO, Huang YZ, Leonard AS. Molecular signaling mechanisms underlying epileptogenesis. *Sci STKE* 2006; 2006:re12Vol. 18 No. 1/2021

39- Vezzani A, Granata T: Brain inflammation in epilepsy: experimental and clinical evidence. *Epilepsia* 2005; 46:1724-1743

40- Dudek FE, Sutula TP: Epileptogenesis in the dentate gyrus:a critical perspective. *Prog Brain Res* 2007; 163:755-773

41-Scharfman HE: The neurobiology of epilepsy. *Curr Neurol Neurosci Rep* 2007; 7:348-354

42-Victoria M. Golub and Doodipala Samba Reddy , Post-Traumatic Epilepsy and Comorbidities: Advanced Models, Molecular Mechanisms, Biomarkers, and Novel Therapeutic Interventions , *Pharmacol Rev* 74:387-438, April 2022

43- Carney N, Totten AM, O'Reilly C et al (2016) Guidelines forthe management of severe traumatic brain injury, Fourth Edition.Neurosurgery.
<https://doi.org/10.1227/neu.0000000000001432>