

Case report

Mallory Weiss tear - An uncommon cause of upper G.I bleeding in a cardiac patient with successful dual intervention

ABSTRACT

Introduction: Primary Percutaneous Coronary Intervention (PPCI) with stenting, especially with Drug eluting stents (DES), is the most widely accepted strategy globally for patients presented with STEMI, which necessitates a long duration of Dual antiplatelet therapy (DAPT) to prevent stent thrombosis. Potent P2Y12 inhibitors for DAPT are preferred in view of their superior protection against thrombosis but at the expense of increased bleeding risks. Early therapeutic intervention in the event of acute GI bleed has beneficial outcome while on active cardiac intervention.

Case presentation: A 67-year-old patient, who underwent PPCI with DES stent, incidentally developed Mallory-Weiss (MW) tear, which manifested as severe hematemesis when loaded with DAPT consisting of Aspirin and Ticagrelor. The therapy was withheld until the clipping of the tear was done. Single antiplatelet therapy (SAPT) with Aspirin was reinstated after a day and DAPT with Aspirin plus Clopidogrel after a week.

Conclusion: A careful assessment of the risks and benefits of acute coronary interventions need to consider complications and timely interventions thus individualizing and curating the DAPT as deemed necessary.

Keywords: Primary Percutaneous Coronary Intervention (PPCI), Dual Antiplatelet Therapy (DAPT), Upper gastrointestinal bleeding, Mallory-Weiss tear.

1. INTRODUCTION

Primary Percutaneous Coronary Intervention (PPCI) with stenting is an established procedure of choice in patients presented with STEMI [1].

Drug Eluting stents are preferred over Bare metal stents as they are known to mitigate the risks of stent restenosis but necessitates the use of Dual Antiplatelet Therapy (DAPT) for a longer period to prevent any life threatening risks. American heart association (AHA) recommends DAPT with Aspirin and a P2Y12 inhibitor (Clopidogrel, Ticagrelor or Prasugrel) following coronary stenting for at least one year and European Society of Cardiology (ESC) for 6 to 12 months in stable patients to reduce MACE or stent thrombosis [2]. In Acute Coronary Syndrome (ACS), both AHA & ESC recommend at least 12 months of DAPT. A shorter duration (less than 12 months) of DAPT can be considered in patients who are at high bleeding risks or low ischemic events and beyond 12 months in patients with low bleeding risks [3].

The incidence of GI bleeding was noted as 3.0% with DAPT and 0.3% with Single Antiplatelet Therapy (SAPT), but DAPT offers superior protection against stent thrombosis [4]. The risk of GI bleeding with third-generation P2Y12 inhibitors was higher than Clopidogrel (RR 1.28, 95% CI 1.13-1.46). Further, the subgroup analysis showed higher risk for GIB with Prasugrel (RR 1.40, 95% CI 1.10-1.77) than Ticagrelor (RR 1.15, 95% CI 0.94-1.39) [5].

We present a case of severe acute upper gastrointestinal bleeding immediately post PPCI and the challenges faced in its management due to the need for DAPT versus morbidity risks with the DAPT.

2. CASE PRESENTATION

A 67 year- old male chronic smoker and a known case of type 2 Diabetes Mellitus and Hypertension for more than 15 years was presented with chief complaints of heaviness in chest associated with back pain, sweating, SOB, giddiness and vomiting. It was sudden in onset and progressive at rest.

His vitals were: B.P- 127/64 mm Hg, PR- 57 beats/min, RR-20 beats/min and the laboratory findings were: Hb- 14.6, RBC- 4.59, WBC- 17,050. ECG was done, which showed STE in precordial leads (Fig.1). He was diagnosed as Anterior wall STEMI, WP- 3 &½ hours and was advised for PPCI.

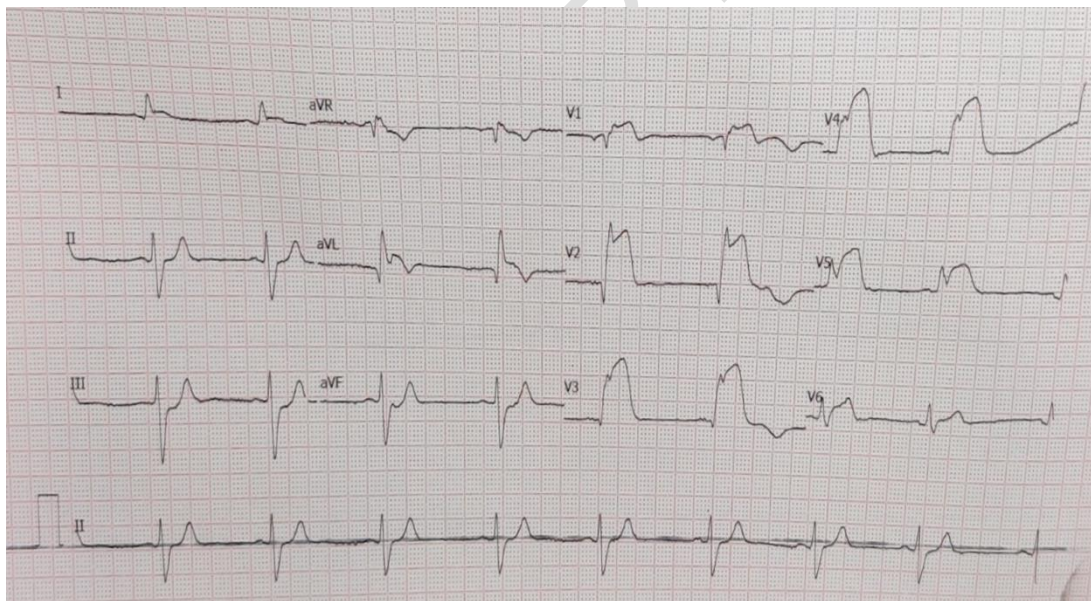


Figure 1 - STE in Precordial leads

CAG was performed through right radial approach on the same day, which revealed SVD mid LAD 100% thrombotic TO after large D1. Primary PTCA with Drug Eluting stent to mid LAD was done. The procedure was uneventful. He was loaded with Aspirin - 350 mg, OD and Ticagrelor -180 mg, OD. TIMI III flow was achieved after the angioplasty. The patient was comfortable and ECG showed regression of STE by >80%. After the procedure, the patient started having multiple episodes of vomiting and retching and antiemetics were given.

In the morning, on the day following the procedure, the patient was sweating with chest discomfort. Serial ECGs were performed, but no fresh notable changes in ECG were observed. Check angio was also done in view of the persistent chest discomfort, which revealed that the stent was patent and all the branches too were patent with TIMI III flow. Patient was shifted back to the ICU for observation. His Hemoglobin dropped from 12 gm% to 9.4 gm%. 4 units of PRBC were transfused due to considerable loss of blood volume. An hour later on the same day, the patient had an episode of massive hematemesis with hypotension. An emergency upper GI endoscopy was done immediately, which showed a long mucosal tear at the lower esophageal mucosal just below the GE junction suggestive of a Mallory-Weiss tear (Fig.2). Endoscopic Sclerotherapy and clipping of the bleeding ulcer with metal clips done (Fig. 3) and hemostasis restored.

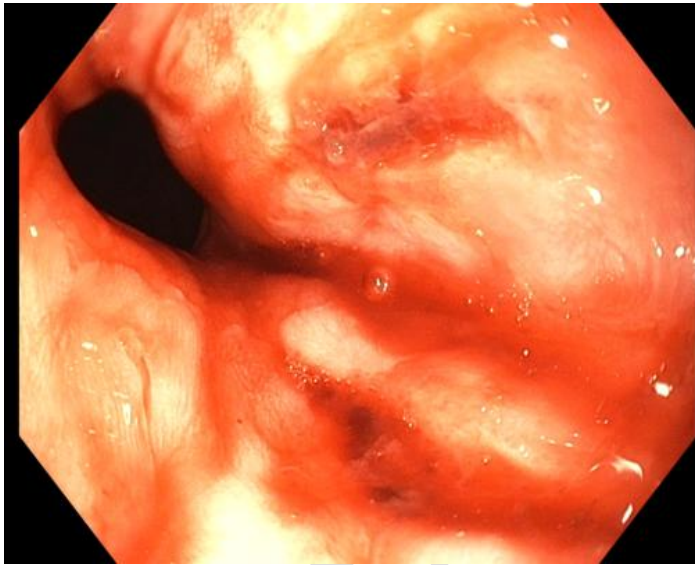


Fig. 2. Endoscopy revealing Mallory-Weiss tear.

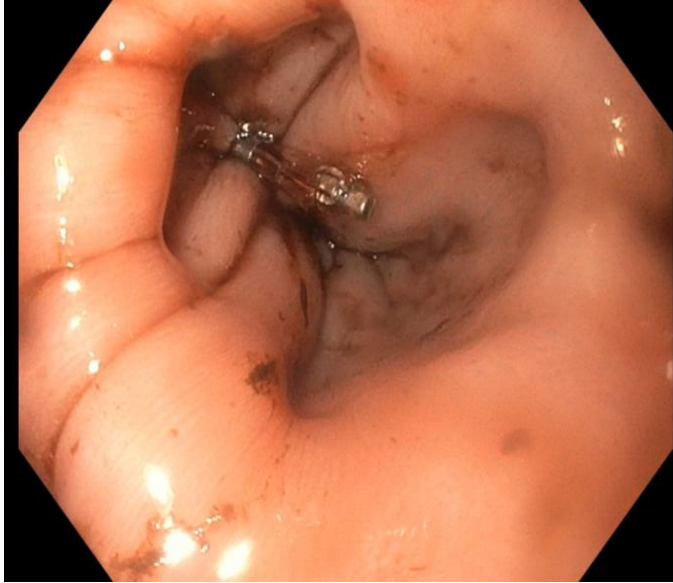


Fig.3 Clip at the site of bleed

He was also given vasopressor-Noradrenalin, which was gradually weaned off once BP was stabilized. DAPT was withheld for 24 hours. Aspirin was reinitiated after 24 hours, as there was no fresh GI bleed. The patient was discharged in a stable condition after 5 days. At the time of discharge, DAPT was initiated with de-escalation from Ticagrelor to Clopidogrel- 75 mg once daily alongside Aspirin.

Upon follow up, after a week, the patient was seen asymptomatic. Gastrointestinal endoscopy showed a healed lower esophageal mucosal tear and there was no fresh oozing. Clopidogrel dose was increased to full dose (75mg twice daily). Proton pump inhibitor-Esomeprazole 40 mg BD was advised for two weeks followed by a decrease in frequency to OD thereafter.

He is on regular follow up and is doing better till date (28 months) with noticeable improvement in his quality of life with neither further complaints of GI bleed nor recurrence of ACS.

3. DISCUSSION

DAPT remains standard of care to prevent stent occlusion due to thrombosis. This case highlights the dual intervention with intention to prevent progression of cardiac disease and at the same time control of unexpected upper gastrointestinal bleeding. ESC recommends risk stratification tools like DAPT Score (Table 1), for assessing optimal duration of DAPT with a trade-off between ischemic events and bleeding risks [6].

Table 1. Variables used in the calculation of DAPT Score [6].

Variables		Points
Age	≥ 75 years	-2
	65 to < 75 years	-1
	< 65 years	0
Smoking		+1
Diabetes Mellitus		+1
MI at presentation		+1
Prior PCI or prior MI		+1
Paclitaxel-eluting stent		+1
Vein graft stent		+2
Stent diameter < 3mm		+1
CHF or LVEF < 30%		+2
Clinical decision: High score of ≥ 2 → long DAPT (30 months) Low score of < 2 → standard DAPT (12 months).		

Myocardial Infarction (MI), Percutaneous coronary intervention (PCI), Congestive heart failure (CHF) and Left ventricular ejection fraction (LVEF).

With the increasing use of DAPT, the number of patients exposed to the risk from GI injury and bleeding is also rising. The extent of adverse GI events associated with the use of DAPT appears to be strongly associated with the dose and duration of the therapy. Aspirin remains the cornerstone in all the antiplatelet regimens, however the choice of second antiplatelet drug varies from case to case. For patients undergoing PCI, in addition to aspirin a P2Y12 inhibitor is used as second antiplatelet drug. Clopidogrel was the P2Y12 agent of choice for years, however due to increase in ischemic CV event rates due to stent thrombosis as a consequence of clopidogrel resistance, it lost favor in the last decade to newer P2Y12 inhibitors - Ticagrelor and Prasugrel. These newer agents are usually chosen over clopidogrel due to their higher potency in causing platelets inhibition. But this higher potential as an antiplatelet also comes with a trade off a higher risk of bleeding. Amongst the two, Prasugrel carries a higher risk of GI bleed than does Ticagrelor [5].

Within 30 days of the initiation of the dual antiplatelet therapy, the risk of bleeding was noted to range from 1.3% in the normal population to as high as 12% in the high risk population [7,8]. Regular use of aspirin is associated with high risk of GI bleed as they inhibit the synthesis of protective prostaglandins in GI mucosa. The extent of injury is strongly linked to the dose and duration of the aspirin use. Evidence suggests that aspirin can cause the new mucosal lesions or can aggravate the pre-existing ones and the relative risk of UGIB is much

higher (four -to six fold) at higher doses of aspirin [9]. Further, the use of enteric-coated or buffered formulations of aspirin also appears to fail in reducing UGIB risks associated with its use.

Clopidogrel, a P2Y₁₂ inhibitor, does not appear to form any new lesions but can cause the pre-existing ones to bleed in patients with underlying mucosal defects or scarring [7]. In the CAPRIE trial, it was evident that GI hemorrhage (0.52% vs. 0.72%, $P < .05$) was significantly low with Clopidogrel than with aspirin [10]. Randomized controlled trials conducted in patients with acute coronary syndrome, the combination regimen of Clopidogrel and aspirin appear to increase the relative risk of GI hemorrhage by 50% [11]. In the CURE study involving regimen of Clopidogrel (75mg) and high dose of aspirin (>200mg) vs Clopidogrel (75mg) and low-dose aspirin (≤ 100 mg) the risk of GI hemorrhage was significantly higher in the former combination with high-dose aspirin (3% vs. 4.9%, $P = .0009$) [12].

In this case, the presentation of DAPT related bleed is quite uncommon, which is a Mallory Weiss tear whose incidence in routine UGI bleed is 8-15 % [13,14,15]. The pathogenesis of Mallory-Weiss syndrome is yet to be understood completely. It is characterized by longitudinal mucosal lacerations that are caused by massive forceful episodes of vomiting, retching, coughing or straining, which lead to an increase in intra abdominal pressure. This increased abdominal pressure propels the contents of the stomach back to the esophagus and causes tears. Bleeding results when lower esophageal venous or arterial plexus are involved in the tear. It has been noted in case series that 40 to 80 percent of Mallory-Weiss syndrome patients are heavy alcohol users who experience vomiting or retching after too much of alcohol intake [15,16]. In patients who underwent PPCI, factors such as use of intraoperative contrast agents or stress that could induce postoperative vomiting by increasing intra abdominal pressure can further amplify the risk of MWS [17].

Rawla P reported in his article that MWS accounts for 1-15 % of UGIB in adults in the United States [18]. Kenneth Mallory and Soma Weiss were the first to describe the syndrome in 1929. Highest incidence is seen in men, especially in the age group of 40 to 60 years. It is usually manifested as hematemesis and melena, and the diagnosis is confirmed with endoscopy [18,19]. It often heals spontaneously within 48-72 hours after arresting the bleed. If intervened on time, reduces the chance of rebleed and thus reduces morbidity. In this case because of underlying cardiac issue the expected mortality is likely high hence intervention is indicated.

In case of any UGIB, two scoring systems, Rockall score (RS) and Blatchford score (GBS), are recommended to help clinicians stratify patients to high-risk and low risk subgroups. RS predicts mortality using pre endoscopic and endoscopic finding, while GBS predicts need for blood transfusion using basic clinical and laboratory data. A high score is associated with high risk of rebleeding, needing an intervention and vice versa [20].

Antunes in his review article suggested a stepwise approach to be adopted in patients presenting with upper GI bleed [21]. However, in case of a Mallory Weiss tear the precipitating factors could be violent with constant retching or coughing, Patients with any visible signs of ulcers or active bleed needing transfusion have to be first made hemodynamically stable for any active intervention both cardiac and endoscopy. Risk stratification is done using the available scoring systems followed by endoscopic findings within 24 hours to confirm the diagnosis. Any ongoing antiplatelet therapy ideally has to be

interrupted until the bleeding ceases [21]. Endoscopic clipping to the tear is the ideal intervention to stop bleeding. SAPT was reinstated with Aspirin initially followed by DAPT- the management of dual critical issues is a real challenge and affirms the multispecialty approach.

4. CONCLUSION

Mitigating the UGIB complications after PCI is a challenging task for the cardiologist and calls for interdisciplinary approach. The dual intervention is a must to navigate through and alleviate the complications of both coronary and gastrointestinal bleeding. A critical evaluation of the bleeding risks versus risks for ischemic events is needed for moving forward in patients undergoing PCI with DES as it necessitates by default the DAPT. Striking a perfect balance with the duration and combination of DAPT is the need of the hour, anchoring the very fact that any ongoing antiplatelet therapy can further worsen the unforeseen GI bleeding encountered during or post the surgery. Curating the DAPT judiciously is indeed a challenge to the cardiologist and gastroenterologist as both stent thrombosis and severe UGIB can be seen as wielding a double-edged sword.

CONSENT

As per the international standard or university standard, patients' written consent has been collected and preserved by the author(s).

ETHICAL APPROVAL

As per the international standard or university standard, patients' written consent has been collected and preserved by the author(s).

REFERENCES

1. Ohman EM. The Evolving Post-PCI Antithrombotic Therapies. *N Engl J Med* [Internet]. 2021;385:1712-1714.
2. Magnani G, Valgimigli M. Dual Antiplatelet Therapy After Drug-eluting Stent Implantation. *Interv Cardiol*. 2016;11(1):51–53. doi: 10.15420/icr.2015:17:2
3. Howard TM, Khot UN. Dual antiplatelet therapy after percutaneous intervention: Personalize the duration. *Cleve Clin J Med*. 2021;88(6):325-332. doi:<https://doi.org/10.3949/ccjm.88a.20113>
4. Bittl JA, Laine L. Gastrointestinal Injury Caused by Aspirin or Clopidogrel Monotherapy Versus Dual Antiplatelet Therapy. *J Am Coll Cardiol*. 2022; 79(2):129-131.
5. Chan-Guo G, Chen L, Chan EW, Cheung KS, Isshiki T, Wong ICK, et al. Systematic review with meta-analysis: the risk of gastrointestinal bleeding in patients taking third-

generation P2Y₁₂ inhibitors compared with clopidogrel. *Aliment Pharmacol Ther.* 2019;49(1):7-19. <https://doi.org/10.1111/apt.15059>

6. Leonardi S, Bueno H, Ingo A, Hassager C, Bonnefoy E, Lettino M. Optimised care of elderly patients with acute coronary syndrome. *Eur. Heart J. Acute Cardiovas. Care.* 2018;7:1-9. Doi:10.1177/2048872618761621.

7. Ng FH, Wong SY, Chang CM, Chen WH, Kng C, Lanas AI, Wong BC. High incidence of clopidogrel-associated gastrointestinal bleeding in patients with previous peptic ulcer disease. *Aliment Pharmacol Ther.* 2003;18(4):443–9

8. Yusuf S, Zhao F, Mehta SR, Chrolavicius S, Tognoni G, Fox KK. Effects of clopidogrel in addition to aspirin in patients with acute coronary syndromes without ST-segment elevation. *N Engl J Med.* 2001;345:494–502.

9. Patrono C, Bachmann F, Baigent C, Bode C, De Caterina R, Charbonnier B, et al. European Society of Cardiology. Expert consensus document on the use of antiplatelet agents. The task force on the use of antiplatelet agents in patients with atherosclerotic cardiovascular disease of the European Society of Cardiology. *Eur Heart J.* 2004;25(2):166–81.

10. CAPRIE Investigators. A randomised, blinded, trial of clopidogrel versus aspirin in patients at risk of ischaemic events (CAPRIE). CAPRIE Steering Committee. *Lancet* 1996;348(9038):1329–39.

11. Eikelboom JW, Hirsh J. Bleeding and management of bleeding. *Eur Heart J.* 2006;8(Suppl G):G38–45

12. Peters RJ, Mehta SR, Fox KA, Zhao F, Lewis BS, Kopecky SL, et al. Clopidogrel in Unstable angina to prevent Recurrent Events (CURE) Trial Investigators. Effects of aspirin dose when used alone or in combination with clopidogrel in patients with acute coronary syndromes: observations from the Clopidogrel in Unstable angina to prevent Recurrent Events (CURE) study. *Circulation* 2003;108(14):1682–7

13. Weaver DH, Maxwell JG, Castleton KB. Mallory-Weiss syndrome. *Am J Surg.* 1969; 118:887.

14. Watts HD, Admirand WH. Mallory-Weiss syndrome. A reappraisal. *JAMA* 1974; 230:1674.

15. Michel L, Serrano A, Malt RA. Mallory-Weiss syndrome. Evolution of diagnostic and therapeutic patterns over two decades. *Ann Surg* 1980; 192:716.

16. Dagradi AE, Broderick JT, Juler G, et al. The Mallory-Weiss syndrome and lesion. A study of 30 cases. *Am J Dig Dis* 1966; 11:710.

17. Zhang Y, Liu H, Liu X. Salvage treatment for severe upper gastrointestinal bleeding caused by Mallory-Weiss syndrome and myocardial depression after acute myocardial infarction. *Heliyon.* 2022 Nov 14;8(11):e11638. doi: 10.1016/j.heliyon.2022.e11638. PMID: 36406730; PMCID: PMC9668565.

18. Rawla P, Devasahayam J. Mallory-Weiss Syndrome [Updated 2021 Dec 12]. In: *StatPearls.* Treasure Island (FL): StatPearls Publishing; 2022.

19. Hussein MS, Alfaraj FA, Alshabwi AD, Altheyab AA, Alhasan KT, Alghamdi OM, et al. Evaluation and Management of Mallory – Weiss Syndrome: A Review. J. Pharm. Res. Int. [Internet]. 2021 Dec. 20 [cited 2023 Feb. 18];33(60A):788-94. Available from: <https://journalipri.com/index.php/JPRI/article/view/5214>

20. Custovic N, Husic-Selimovic A, Srsen N, Prohic D. Comparison of Glasgow-Blatchford Score and Rockall Score in Patients with Upper Gastrointestinal bleeding. Med Arch. 2020;74(4): 270-274. Doi: 10.5455/medarh.2020.74.270-274

21. Antunes C, Copelin II EL. Upper Gastrointestinal Bleeding. [Updated 2021 Jul 21]. In: StatPearls. Treasure Island (FL): StatPearls Publishing; 2022.

UNDER PEER REVIEW