

Cow Urine Extract of *Nicotiana tabacum* Leaf Portends Hepatotoxicity in Male Wistar Rats

ABSTRACT

Aims: The toxicological effects of single and repeated doses of aqueous extract (AE) and cow urine extract (CUE) of *Nicotiana tabacum* leaf on the liver and kidney function indices of male Wistar rats were investigated.

Study design: Thirty-five male rats were randomized into seven groups (n=5). The control group received 0.5 mL of distilled water, groups A and B received 8 mg/kg body weight (BW) of CUE and AE respectively, once daily; groups C and D received 16 mg/kg BW of CUE and AE respectively, thrice a day (TD); groups E and F received 32 mg/kg BW of CUE and AE respectively, TD. The administration was oral and lasted for 28 days.

Place and Duration of Study: The study was carried out at Summit University, Offa, Nigeria between June 2019 and August 2019.

Methodology: Thirty-five male rats were randomized into seven groups (n=5). The control group received 0.5 mL of distilled water, groups A and B received 8 mg/kg body weight (BW) of CUE and AE respectively, once daily; groups C and D received 16 mg/kg BW of CUE and AE respectively, thrice a day (TD); groups E and F received 32 mg/kg BW of CUE and AE respectively, TD.

Results: The result revealed no significant difference in the activities of ALP, and GGT but a significant increase in the ACP, ALT, and AST activities in both tissues and serum. Furthermore, there was a significant decrease in albumin concentration of rats in all the groups except group B when compared with the control rats. Liver and kidney histology revealed minimal lymphocytic infiltration with no sign of medium-term systemic damage.

Conclusion: The study suggests no nephrotoxicity of AE and CUE at all doses administered but probable hepatotoxicity at higher and repeated doses of both extracts except at the single dose of 8 mg/kg BW of AE.

Keywords: Nigerian Youth; cow urine; hepatotoxicity; Nicotiana tabacum, "Adimenu"

1. INTRODUCTION

Tobacco (*Nicotiana tabacum*), an annual plant with an average height of 1 to 2 meters, is cultivated in many countries of the world, [1], including Nigeria where it is abundant [2]. Traditionally, *Nicotiana tabacum* is used as an antidote for reptile and insect bites, pain management, neuralgia, gout, hair growth enhancement, treating ringworm, ulcers, and wounds and as a respiratory stimulant [3]. Chemical compounds such as sesquiterpene, alkaloids, lignans, flavonoids, phenolics, tannins, steroids, terpenoids, cardiac glycosides, essential oils, saponins, quinines, polypeptides, phenylpropanoids, chromanones, biphenyls, and isocoumarins have been obtained from the leaves of *Nicotiana tabacum*. The plant has been reported to possess antioxidant, antimicrobial, antiparasitic, analgesic, antidiabetic, antifertility, anti-aphthous, cytotoxic, and neuropharmacological activities [3]. With the exception of the seeds, all other parts of *Nicotiana tabacum* contain nicotine with the leaves having the most concentration [4]. The plant is cultivated primarily for use in the manufacture of nicotine-containing products such as cigarettes [5]. Nicotine which is the main active principle in the plant has been reported to be the most common overused compound in the world [4]. Nigeria, the country with the highest population in Africa has one of the leading tobacco markets in Africa, with over 18 billion cigarettes sold annually costing Nigerians over US\$ 931 million (6-7). The metabolism of nicotine occurs majorly in the liver [8-9], involving two important steps namely; oxidation of an iminium ion catalyzed by the human liver

microsome cytochrome P450 (P450, CYP) 2A6-catalyzed 5' and the oxidation of the iminium ion to cotinine [9]. This makes liver highly vulnerable to drug-induced toxicity [10].

The kidney plays an important role in homeostasis and removal of xenobiotics and metabolites from the body. These xenobiotics and their metabolites are eliminated majorly in the urine [11]. Nicotine has been reported to increase oxidative stress in kidneys, thus leading to alteration in the overall functioning of the kidney; prolonged exposure poses the risk of development of chronic kidney diseases which further worsen the effects of coexisting morbidities such as hypertension, obesity-associated renal disease, renal transplant status, or the harmful effect of various anticancer agents [12].

Cow urine is an important component of ancient Ayurvedic medicines that has been implicated in the management of various diseases. It is made up of 95% water, 2.5% urea, and a mix of minerals, salts, hormones, and enzymes (2.5%) [13]. It contains bioactive components such as phenols, amino acids, volatile and non-volatile substances and chemical components such as ammonia, nitrogen, magnesium, potassium, allantoin, creatinine and sulfate among others [14]. [15] reported that the GC-MS fingerprints of cow urine extract of *Nicotiana tabacum* contain α -nicotine, methyl palmitate, and methyl elaidate; and that the administration of the extract caused liver damage, renal impairment, and increased serum triglyceride level in rats. These varieties of compounds in cow urine make it widely employed as a therapeutic or additive substance in many ethno-medicinal traditions, and contemporary science has also demonstrated its therapeutic ability to manage various diseases including diabetes, high blood pressure, asthma, psoriasis, eczema, heart attack, artery blockage, fits, cancer, AIDS, piles, and prostate cancer [16]. However, there are reports of associated toxic effects such as renal impairment [15] when used in preparation of concoction. Previous studies revealed that cow urine extract of *Nicotiana tabacum* leaf induced oxidative stress, caused anemia, and impaired heart functionality in rats [17].

Locally, "Adimenu" or "Grade 1" is prepared by extracting *Nicotiana tabacum* leaf in cow urine; the regular volume consumed is about 5 mL. However, some addicted users consume this volume twice or thrice at once and at times more than once daily for acclaimed medicinal purposes without known scientific evidence(s). Therefore, the need to imitate the way "Adimenu or Grade 1" (*Nicotiana tabacum* leaf extract) is consumed locally so as to evaluate the safety and/or toxicity of its aqueous and cow urine extracts necessitated this study.

2. MATERIAL AND METHODS

2.1 Plant Material and Authentication

The dried leaf of *Nicotiana tabacum* was purchased in November 2019 from Ganmo market (8.4190°N, 4.6086°E), Kwara State, Nigeria. The plant was authenticated at the Herbarium Unit of Plant Biology, University of Ilorin and the voucher number UIL/002/11011 was assigned. The plant name, *Nicotiana tabacum* L. was verified (data supplied on 2012-03-26) on the online plant data base (<http://theplantlist.org/tpl1.1/search?q=Nicotiana+tabacum+>).

2.2 Experimental Animals

Thirty-five Wistar rats weighing 150.50 ± 8.20 g were obtained and housed in the clean and conducive Animal House of the Department of Chemical Sciences, Summit University Offa, Kwara State, Nigeria.

2.3 Assay Kits and Equipment

Assay kits for alkaline phosphatase, acid phosphatase, alanine aminotransferase, aspartate aminotransferase, gamma-glutamyl transferase, bilirubin, albumin, urea, uric acid, creatinine, sodium, potassium, chloride, and bicarbonate were products of Randox Laboratories Ltd., Co-Antrim, UK. Other chemicals and reagents used were of analytical grade. Freeze dryer was a product of Labconco, Kansas City, Missouri, USA.

2.4 Preparation of Aqueous and Cow Urine Extracts of *Nicotiana tabacum* leaves

Freshly collected cow urine (2L) and distilled water (750 mL) were boiled and allowed to cool, thereafter the dried leaf of *Nicotiana tabacum* (200 g and 100 g) was soaked in the solvents respectively for 24 hours at 25°C. The extracts were filtered using Whatman no 1 filter paper and the filtrate freeze-dried (Labconco Freeze Drier, Model 64132, Kansas City, Missouri, USA) to a percentage yield of 42.38% and 34.9% respectively. The extracts were reconstituted in distilled water to give the desired doses of 8, 16, 32 mg/kg body weight.

2.5 Animal Grouping and Extract Administration

Male Wister rats weighing 150.50 ± 8.20 g were kept in well-ventilated cages with free access to feed pellets and tap water. Thirty-five animals were assigned into 7 groups (A, B, C, D, E, F, and Control) of 5 rats each (Table 1).

Table 1. Animal Grouping and Extract Administration

Groups	Dosage (ml)
Control	0.5 mL of distilled water
A	8 mg/kg body weight of cow urine extract of <i>Nicotiana tabacum</i> leaf once daily
B	8 mg/kg body weight of aqueous extract of <i>Nicotiana tabacum</i> leaf once daily
C	16 mg/kg body weight of cow urine extract of <i>Nicotiana tabacum</i> leaf thrice daily
D	16 mg/kg body weight of aqueous extract of <i>Nicotiana tabacum</i> leaf thrice daily
E	32 mg/kg body weight of cow urine extract of <i>Nicotiana tabacum</i> leaf thrice daily
F	32 mg/kg body weight of aqueous extract of <i>Nicotiana tabacum</i> leaf thrice daily

2.6 Preparation of Serum and Tissue Supernatant

The procedure described by [18] was adopted for the preparation of serum. The animals were sacrificed under diethyl ether anesthesia by simply cutting the jugular vein; the blood was collected into plain sample tubes and left at 25°C for 30 minutes to form clots before being centrifuged at 1282 x g for 5 minutes. After centrifugation, the sera were collected with a Pasteur pipette into a clean sample bottle and labeled. The liver and the kidney were also removed, defatted, blotted with tissue paper, and weighed. The organs were homogenized separately in ice-cold 0.1M sucrose solution (1:4 w/v) using a Uniscope Laboratory Centrifuge (Model SM800B, Surgifriend Medicals, Essex, England). The homogenates were centrifuged for 10 minutes at 1789 x g to obtain supernatants, which together with the serum, were stored in a freezer at 4°C not later than 72 hours of preparation for the biochemical assays.

2.7 Determination of Biochemical Parameters and Histological Examination

The activities of alkaline and acid phosphatases, alanine and aspartate aminotransferases, and gamma-glutamyl transferase were determined using the methods described by Wright *et al.* [19], Reitman and Frankel [20], and [21] respectively. Bilirubin concentration was determined using the method described by Jendrassik and Grof [22], albumin concentration as described by Dumas *et al.* [23], urea concentration as described by Veniamin and Vakirtzi-Lemonias [24], uric acid concentration as described by Burtis *et al.*

[25], creatinine concentration as described by Bartels *et al.* [26], and serum electrolytes (Na, K, Ca, Cl and HCO₃) as described by Tietz [27]. Histology was done following the method described by Drury and Wallington [28].

2.8 Data Analysis

Data were expressed as the mean \pm SD of five determinations. Data were analyzed using a one-way analysis of variance followed by *Turkey's* post-hoc test for multiple comparisons. Statistical significance was set at 95% confidence interval ($p < 0.05$) and graph Pad Statistical Package version 6.0 was used for the statistical analyses.

3. RESULTS

The activity of ALP and ACP of the rats administered aqueous and cow urine extracts of *Nicotiana tabacum* leaf for 28 days is presented in Table 2. There was no significant ($P < .05$) difference in the ALP activity of the liver, kidney, and serum of rats administered single and repeated doses of aqueous and cow urine extract of *Nicotiana tabacum* leaf when compared with the control whereas administration of single and repeated doses of aqueous and cow urine extracts of *Nicotiana tabacum* leaf produced significant ($P < .05$) increase in ACP activity in the tissues when compared with the 0.5 ml distilled water administered control rats.

The activities of ALT, AST, and GGT of rats administered aqueous and cow urine extract of *Nicotiana tabacum* leaf for 28 days is shown in Table 3. Administration of the extracts produced a significant ($P < .05$) increase in the ALT and AST activities of all the tissues whereas the GGT activity in all the tissues was not significantly ($P > .05$) different from the control animals.

The serum biochemical indices of rats administered single and repeated doses of aqueous and cow urine extracts of *Nicotiana tabacum* leaf revealed a significant ($P < .05$) decrease in albumin concentration of all the groups except the group administered single dose of 8mg of the aqueous extract while other parameters such as total and direct bilirubin (TB and DB), urea, uric acid, and creatinine (Table 4), and serum electrolytes (Table 5) were not significantly ($P > .05$) different from the control rats.

Table 2: Activities of some membrane marker enzymes of rats administered aqueous and cow urine extracts of *Nicotiana tabacum* leaf

Groups	ALP (nM/min/mg protein)			ACP (nM/min/mg protein)		
	Liver	Kidney	Serum	Liver	Kidney	Serum
Control	54.09 ± 6.98 ^a	24.09 ± 2.32 ^a	12.39 ± 3.51 ^a	39.36 ± 1.62 ^a	34.79 ± 1.37 ^a	14.21 ± 1.41 ^a
A	57.10 ± 8.35 ^a	23.05 ± 3.79 ^a	11.82 ± 1.44 ^a	53.06 ± 8.14 ^b	52.88 ± 8.60 ^c	22.18 ± 2.50 ^b
B	54.00 ± 8.57 ^a	26.54 ± 4.99 ^a	11.30 ± 1.11 ^a	43.79 ± 4.36 ^a	39.64 ± 1.84 ^b	22.14 ± 1.21 ^b
C	57.98 ± 7.90 ^a	23.68 ± 1.53 ^a	11.20 ± 1.72 ^a	68.48 ± 7.53 ^b	51.67 ± 4.68 ^c	19.90 ± 1.95 ^b
D	60.93 ± 6.91 ^a	23.67 ± 2.98 ^a	11.63 ± 2.15 ^a	65.07 ± 4.61 ^b	42.15 ± 5.00 ^c	19.94 ± 2.25 ^b
E	51.57 ± 8.95 ^a	26.48 ± 1.90 ^a	11.41 ± 1.15 ^a	62.15 ± 2.90 ^b	37.52 ± 1.12 ^b	22.58 ± 1.89 ^b
F	58.04 ± 5.11 ^a	21.51 ± 4.28 ^a	12.69 ± 1.67 ^a	57.49 ± 8.43 ^b	70.73 ± 7.42 ^d	20.13 ± 1.10 ^b

Values are means of five replicates ± SD;

Values with different superscripts across the rows are significantly (P < 0.05) different from others

Table 3. Activities of some marker enzymes of rats administered aqueous and cow urine extracts of *Nicotiana tabacum* leaf

Groups	ALT (nM/min/mg protein)			AST (nM/min/mg protein)			GGT (U/L)		
	Liver	Kidney	Serum	Liver	Kidney	Serum	Liver	Kidney	Serum
Control	44.75 ± 2.20 ^a	30.50 ± 0.25 ^a	19.68 ± 0.50 ^a	62.66 ± 2.84 ^a	44.24 ± 8.68 ^a	21.87 ± 2.41 ^a	125.82 ± 8.44 ^a	112.07 ± 8.73 ^a	3.03 ± 0.25 ^a
A	50.38 ± 2.08 ^b	40.29 ± 2.32 ^b	27.06 ± 6.39 ^b	89.47 ± 5.02 ^b	71.35 ± 7.51 ^c	27.35 ± 1.38 ^b	141.03 ± 21.38 ^a	129.05 ± 18.63 ^a	4.03 ± 0.90 ^a
B	62.42 ± 5.69 ^c	45.91 ± 4.27 ^b	26.08 ± 5.48 ^b	88.51 ± 11.34 ^b	84.22 ± 6.74 ^b	26.60 ± 1.25 ^b	118.25 ± 6.49 ^a	137.63 ± 46.40 ^a	3.78 ± 1.07 ^a
C	62.64 ± 2.77 ^c	41.64 ± 5.82 ^b	26.68 ± 3.92 ^b	85.44 ± 15.92 ^b	69.27 ± 9.24 ^c	27.35 ± 2.33 ^b	123.84 ± 14.21 ^a	99.25 ± 24.53 ^a	3.65 ± 0.57 ^a
D	56.19 ± 2.53 ^b	35.97 ± 0.83 ^b	25.40 ± 3.71 ^b	95.27 ± 13.76 ^b	89.88 ± 7.56 ^b	26.89 ± 1.34 ^b	113.92 ± 10.15 ^a	144.99 ± 28.46 ^a	3.81 ± 1.41 ^a
E	51.52 ± 6.71 ^b	39.74 ± 2.12 ^b	29.50 ± 5.26 ^b	70.79 ± 6.95 ^b	90.36 ± 8.53 ^b	28.41 ± 3.25 ^b	128.66 ± 8.26 ^a	154.51 ± 33.25 ^a	4.92 ± 1.51 ^a
F	60.54 ± 2.00 ^c	35.34 ± 4.58 ^b	27.42 ± 1.31 ^b	89.30 ± 13.13 ^b	89.72 ± 2.97 ^b	25.78 ± 3.74 ^b	139.08 ± 15.16 ^a	149.04 ± 42.32 ^a	4.45 ± 0.47 ^a

Values are means of five replicates ± SD

Values with different superscripts across the rows are significantly (P < 0.05) different from others

Table 4. Some functional indices of rats administered aqueous and cow urine extracts of *Nicotiana tabacum* leaf

Group/ Parameters	Control	A	B	C	D	E	F
TB (mg/dL)	57.78 ± 2.90 ^a	60.21 ± 4.08 ^a	57.97 ± 1.36 ^a	54.58 ± 1.57 ^a	61.88 ± 5.36 ^a	66.52 ± 3.28 ^a	67.83 ± 2.80 ^a
DB (mg/dL)	31.11 ± 1.11 ^a	28.83 ± 2.50 ^a	34.15 ± 2.23 ^a	30.50 ± 6.02 ^a	28.82 ± 5.00 ^a	28.39 ± 1.41 ^a	29.58 ± 3.12 ^a

Albumin (g/dL)	84.16 ± 7.45 ^a	65.24 ± 10.17 ^b	91.37 ± 4.88 ^a	42.73 ± 4.75 ^c	44.77 ± 3.35 ^c	62.48 ± 4.93 ^b	58.90 ± 4.85 ^b
Urea (mg/dL)	104.83 ± 18.68 ^a	82.06 ± 22.13 ^a	108.80 ± 6.75 ^a	103.93 ± 3.75 ^a	99.59 ± 5.50 ^a	103.72 ± 8.66 ^a	101.66 ± 6.99 ^a
Uric Acid (mg/dL)	0.46 ± 0.07 ^a	0.57 ± 0.08 ^a	0.42 ± 0.04 ^a	0.50 ± 0.07 ^a	0.51 ± 0.01 ^a	0.43 ± 0.04 ^a	0.55 ± 0.06 ^a
Creatinine (mg/dL)	7.73 ± 0.67 ^a	7.79 ± 1.36 ^a	6.74 ± 1.40 ^a	5.99 ± 1.43 ^a	6.00 ± 0.49 ^a	6.81 ± 1.49 ^a	5.74 ± 1.74 ^a

Values are means of five replicates ± SD

Values with different superscripts across the rows are significantly different (P<0.05) from others

Table 5. Serum electrolytes of rats administered aqueous and cow urine extracts of *Nicotiana tabacum* leaf

Group	Na (mmol/L)	K (mmol/L)	Ca (mmol/L)	Cl (mmol/L)	HCO ₃ (mmol/L)
Control	13.29 ± 4.15 ^a	22.57 ± 5.18 ^a	58.24 ± 3.96 ^a	36.95 ± 7.20 ^a	28.84 ± 4.76 ^a
A	16.57 ± 1.02 ^a	24.48 ± 4.37 ^a	62.08 ± 4.67 ^a	36.58 ± 5.05 ^a	27.34 ± 1.26 ^a
B	15.02 ± 4.39 ^a	51.11 ± 4.20 ^a	58.90 ± 5.12 ^a	42.29 ± 6.05 ^a	28.92 ± 2.12 ^a
C	16.64 ± 2.23 ^a	34.53 ± 1.06 ^a	55.10 ± 2.26 ^a	34.13 ± 3.80 ^a	29.96 ± 3.58 ^a
D	15.00 ± 4.71 ^a	27.12 ± 3.13 ^a	59.89 ± 4.50 ^a	48.33 ± 6.22 ^a	28.24 ± 4.00 ^a
E	16.19 ± 4.12 ^a	25.64 ± 2.50 ^a	55.61 ± 1.91 ^a	39.04 ± 2.57 ^a	29.40 ± 0.99 ^a
F	15.80 ± 1.05 ^a	27.31 ± 2.49 ^a	58.11 ± 5.49 ^a	31.69 ± 2.80 ^a	31.95 ± 2.26 ^a

Values are means of five replicates ± SD

Values with different superscripts across the rows are significantly different (P < 0.05) from others

Administration of doses of aqueous and cow urine extracts of *Nicotiana tabacum* leaf showed preserved architecture composed of normal glomeruli, tubules, and interstitium with no features of acute or chronic injury (Plate 1). Administration of doses of cow urine extract of *Nicotiana tabacum* leaf showed preserved architecture composed of cords of normal hepatocytes with glycogen accumulation. The portal tracts showed mild to minimal lymphocytic infiltration with no features of chronic damage. The portal tracts of normal liver cells show minimal lymphocytic infiltration and no sign of chronic damage (Plate 2).

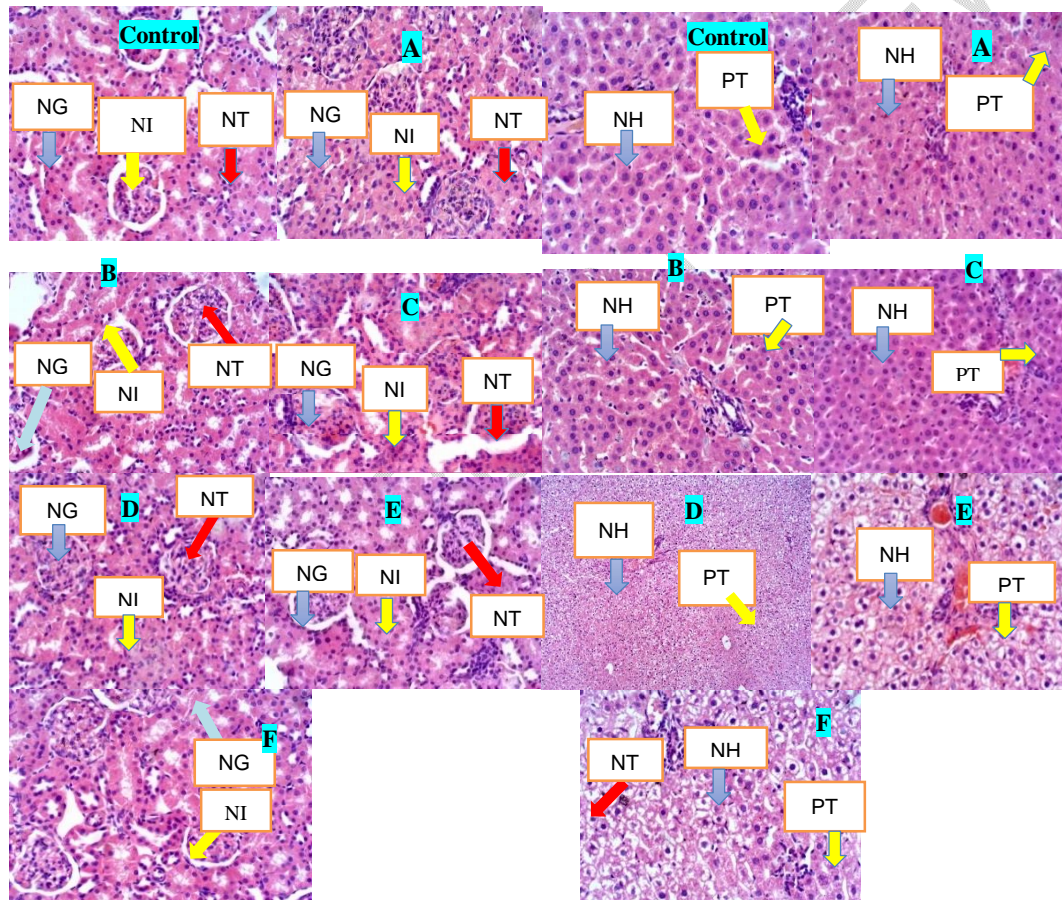


Plate 1: Cross section of the kidney of rats administered aqueous and cow urine extract of *Nicotiana tabacum* leaf for 28 days (Magnification: x400; H & E).

NG = Normal Glomerulus; NT = Normal Tubules; NI = Normal Interstitium

Plate 2: Cross section of the Liver of rats administered aqueous and cow urine extract of *Nicotiana tabacum* leaf for 28 days (Magnification: x400 x400; H & E).

NH = Normal Hepatocyte; PT = Normal Tubules

4. DISCUSSION

Owing to the various reasons for the continuous use of herbal medicines for health care [29] patients in some instances become addicted to some herbal medications/concoctions, and notable among such is the extracts of *Nicotiana tabacum* leaf popularly called "adimenu" [15]. The chief constituent of *Nicotiana tabacum* is nicotine which has been implicated in several risk factors for various diseases.

The determination of the activities of various enzymes in the tissue and serum is a significant part of toxicological investigation and a pointer to possible tissue damage [30]. Alkaline phosphatase (ALP) and Acid Phosphatase (ACP) are commonly used as marker enzymes of membrane integrity [31]. ALP is a ubiquitous enzyme widely distributed in various tissues. It is released into the blood during conditions such as obstructive jaundice or certain bone disorders or during hepatobiliary [32]. Acid Phosphatase in the blood indicates lysosomal metabolism disorder, bone diseases or prostrate carcinoma [33]. The non-significant difference in the ALP activity of rats administered aqueous and cow urine extracts of *Nicotiana tabacum* leaf is an indication that administration of the extracts did not alter the membrane integrity. The increase in the activity of ACP in the tissues and sera of all the animals in the test groups except the liver of the rats administered 8 mg/kg b.w. (single dose) aqueous extract of *Nicotiana tabacum* leaf suggests a likelihood of induced synthesis of ACP or probably an increased hydrolytic and clearance function of the lysosome thereby making it susceptible to damage.

Alanine aminotransferase (ALT) and Aspartate aminotransferase (AST) are found in tissues where they both catalyze transamination reactions. They are routinely used as markers of liver pathological conditions resulting from drug toxicity or infections [34] with ALT being more sensitive than AST [35]. The increase in the activity of ALT and AST in both tissues with concomitant increase in the serum of rats administered doses of aqueous and cow urine extract of *Nicotiana tabacum* leaf suggests in situ increase in the synthesis of these enzymes probably due to the increased detoxification process in the liver leading to an increased excretory role of the kidney. This result pointed to the detoxifying functionality of the liver that might be responsible for the protection of vital tissues against early damages that may ensue from detoxification processes.

Gamma glutamyl transferase (GGT) is a sensitive cholestasis damage marker and also involved in the metabolism of xenobiotics particularly at phase II. The non-significant difference in the activity of GGT in the tissues and sera is an indication that the extract might have been fully detoxified by the phase I enzymes of xenobiotic metabolism.

The concentration of bilirubin and albumin in the serum is a well-known index to determine the secretory and synthetic functioning of the liver and can be used to ascertain types of liver damage [36]. The direct and total bilirubin concentrations which are produced as by-products of breakdown of heme in the liver showed levels that were not significantly altered in the serum when compared with the control. This suggests that the extract neither caused an increase in bilirubin production nor affected the clearance of bilirubin from the blood. The decreased albumin concentrations in all the groups except the group administered 8 mg/kg b.w. (single dose) aqueous extract of *Nicotiana tabacum* leaf is an indication of reduced synthetic, secretory, and excretory functions of the hepatocytes prompted by the administration of the extracts of *Nicotiana tabacum* leaf.

The kidney is an organ responsible for the removal of waste and maintenance of water, pH, electrolyte [37]. Serum urea, uric acid, creatinine, and electrolytes are indices of renal excretory function [1]. The non-significant difference in the concentration of these parameters implied that the extract had no effect on the kidney's synthetic and elimination functions.

The liver of the cow urine extract of the *N. tabacum* leaf administered groups showed preserved architecture composed of cords of normal hepatocytes with glycogen accumulation. Glycogen accumulation has been reported to lead to hepatomegaly or glycogen accumulation.

5. CONCLUSION

This study reveals that the aqueous and cow urine extracts of *Nicotiana tabacum* showed no nephrotoxicity. However, all the groups demonstrated potential hepatotoxicity except the groups administered 8 mg/kg bwt of aqueous extract of *Nicotiana tabacum*. This suggests that low and single daily doses of *Nicotiana tabacum* could be safe for consumers while repeated consumption of both aqueous and cow urine extracts might not be.

CONSENT

Not Applicable

ETHICAL APPROVAL

This study was carried out in compliance with the standard principle of laboratory animal care. Ethical approval was obtained from the Summit University Ethical Review Committee with approval number SUERC/CONAS/2020/003.

REFERENCES

1. Akomolafe OR, Imafidon CE, Olukiran OS, Oladele AA, Akanji BO. Sub-acute administration of lower doses of nicotine caused sex-dependent improvement of renal function in Wistar rats. *Toxicology Report*. 2017;4:535-542. <https://www.sciencedirect.com/science/article/pii/S2214750017300689>
2. Ileke KD, Ogunbite OC, Oyeniyi E, Adeshina JM. *Nicotiana tabacum*: A prospective mosquitocide in the management of *Anopheles gambiae* (Giles). *International Journal of Mosquito Research*. 2015; 2(4): 19-23
3. Al-Snafi AE. Pharmacological and toxicological effects of *Nicotiana tabacum*. *World Journal of Advanced Pharmaceutical and Medical Research*. 2022;03(01), 006–018 <https://doi.org/10.53346/wjapmr.2022.3.1.0034>
4. Sanjeev A, Kapgate SM. Tobacco (*Nicotiana tabacum*) - A Systemic Review. *Int J Ayu Pharm Chem*. 2021;15(1):130 ISSN 2350-0204
5. Lewis RS. *Nicotiana tabacum* L.: Tobacco. In: Novak J., Blüthner WD. (eds) *Medicinal, Aromatic and Stimulant Plants. Handbook of Plant Breeding*. 2020;12. Springer, Cham. https://doi.org/10.1007/978-3-030-38792-1_9
6. World Health Organization. WHO global report on trends in tobacco smoking 2000–2025. Geneva: World Health Organization; 2015. Available from: <https://www.who.int/tobacco/publications/surveillance/reportontrendstobaccosmoking/en/>. Accessed 12 December 2022.
7. Ake A. Nigeria: Tobacco Consumption Contributes 12% Deaths From Heart Diseases - NHF. THISDAY. 2018 17 May 2018.
8. Benowitz NL, St Helen G, Dempsey DA, Jacob P, Tyndale RF. Disposition

kinetics and metabolism of nicotine and cotinine in African American smokers: impact of CYP2A6 genetic variation and enzymatic activity. *Pharmacogenet Genomics*. 2016;26(7):340-50. doi: 10.1097/FPC.0000000000000222. PMID: 27035242; PMCID: PMC4892970.

9. Murphy SE. Biochemistry of nicotine metabolism and its relevance to lung cancer. *J Biol Chem*. 2021;296:100722. doi: 10.1016/j.jbc.2021.100722. PMID: 33932402; PMCID: PMC8167289.

10. Ozougwu JC . Physiology of the liver. *International Journal of Research in Pharmacy and Biosciences*. 2017; 4(8):13-24.

11. Yang X, Han L. *Drug Transporters in Drug Disposition, Effects and Toxicity*. 2019;1141 ISBN : 978-981-13-7646-7

12. Arany I, Hall S, Reed DK, Reed CT, Dixit M. Nicotine Enhances High-Fat Diet-Induced Oxidative Stress in the Kidney. *Nicotine Tob Res*. 2016;18(7):1628-34.

13. Sharathchandra K, Anitha DG, Soumya S, Sridhar KR. (Bioactive Potential of Cow Urine from two Indigenous Cattle Breeds of Southern India. *DISCOVERY*. 2022;58(317):428–440.

14. Sharma K, kaur S. Kumar N. Cow urine prominence to humanity. *Journal of Pharmacognosy and Phytochemistry*. 2020; 9(1):459-465

15. Sulaiman FA, Nafiu MO, Yusuf BO, Muritala HF, Adeyemi SB, Omar SA, ... Adeyemi OS. The GC-MS fingerprints of *Nicotiana tabacum* L. Extract and propensity for renal impairment and modulation of serum triglycerides in Wistar rats. *Journal of Pharmacy and Pharmacognosy Research*. 2020; 8(3):191-200.

16. Manjramkar AJ, Deshmukh VV, Waghmare RN, Vaidya MS. Assessment of Antimicrobial Properties of Cow Urine Distillates. Article in *International Journal of Current Microbiology and Applied Sciences*. 2019;8(8):2556–2565. <https://doi.org/10.20546/ijcmas.2019.808.297>

17. Yusuf, BO, Salawu MO, Ganiyu AI, Naifu MO, Lukman HY, Moronfolu IA, Olakunle OS, Abdulattah LB, Aiwinnilomo AM, Ibrahim RB, Lawal BB, Okeme U, Oloyede HOB. Cardio-haematological and oxidative assaults in Wistar rats: the roles of *Nicotiana tabacum* leaf extracts. *Res. J. Phytochem*. 2022;16(2): 82-87. <https://doi.org/10.17311/rjphyto.2022.XX.XX>

18. Yakubu MT, Akanji, MA, Oladiji AT. Aphrodisiac potentials of the aqueous extract of *Fadogia agrestis* (Schweinf. Ex Hiern) stem in male albino rats. *Asian Journal of Andrology*. 2005;7(4): 399–404. <https://doi.org/10.1111/j.1745-7262.2005.00052.x>

19. Wright PJ, Leathwood PD, Enzymes in rat urine: Alkaline phosphatase. *Enzymologia*. 1972; 42:317-327.

20. Reitman A, Frankel S. Colorimetric method for the determination of serum glutamic oxaloacetic and glutamic pyruvic transaminases. *American Journal of Clinical Pathology*. 1957;28:56.

21. Szasz G. A Kinetic Photometric Method for Serum γ -Glutamyl Transpeptidase. *Clinical Chemistry*. 1969;15(2):124–136. <https://doi.org/10.1093/CLINCHEM/15.2.124>

22. Jendrassik L, Groff P. Colorimetric method for measurement of Bilirubin. *Biochem. J*. 1938;297: 81.

23. Dumas BT, Watson WA, Biggs HG. (n.d.). *N. Clinica Chimica Acta*. 1971;31(1):87-96.

24. Veniamin MP, Vakirtzi-Lemonias C. Chemical Basis of the Carbamidodiacetyl

- Micromethod for Estimation of Urea, Citrulline, and Carbamyl Derivatives. *Clinical Chemistry*, 1970;16(1):3–6. <https://doi.org/10.1093/CLINCHEM/16.1.3>
25. Burtis CA, Ashwood ER, DE B. *Tietz Textbook of Clinical Chemistry and Molecular Diagnostics* (5th ed.). 3251 Riverport Lane, St. Louis, Missouri 63043: Elsevier Saunders;1999.
26. Bartels H, Bohmer M, Heierli C. Serum creatinine determination without protein precipitation. *International Journal of Clinical Chemistry*. 1972;37:193–197.
27. Tietz, N. W. *Clinical guides to laboratory tests*. 3rd edn. W. B. Saunders Company; Philadelphia. 1995; 554-556
28. Drury RAB, Wallington EA. In: *Carleton's Histological Techniques* (4th edn). New York: Oxford University Press;1980
29. Mensah MLK, Komlaga G, Forkuo AD, Firempong C, Anning AK, Dickson RA. Toxicity and safety implications of herbal medicines used in Africa. *Herbal Medicine*2019;5, 63-118. <https://dx.doi.org/10.5572/intechopen.72437>
30. Akanji MA, Ngaha EO. Effect of Repeated Administration of Berenil on Urinary Enzyme Excretion with Corresponding Tissue Pattern in Rats. *Pharmacology & Toxicology*. 1989;64(3),272–275. <https://doi.org/10.1111/J.1600-0773.1989.TB00645.X>
31. Akanji MA, Olagoke OA, Oloyede OB. Effect of chronic consumption of metabisulphite on the integrity of the rat kidney cellular system. *Toxicology*. 1993;81:173–179. [https://doi.org/10.1016/0300-483X\(93\)90010-P](https://doi.org/10.1016/0300-483X(93)90010-P)
32. Singh A, Bhat TK, Sharma OP. Clinical biochemistry of hepatotoxicity. *Journal of Clinical Toxicology*. 2011;S4 (1): 1-19.
33. Bull H, Murray PG, Thomas D, Fraser AM, Nelson PN. Acid phosphatases. *Journal of Clinical Pathology: Molecular Pathology*. 2002;55: 65-72.
34. Nelson DL, Cox MM. *Lerniger's Principle of Biochemistry*, 7th edition, New York, W. H. Freeman and Company.2017.
35. Ojiako OA, Nwanjo HU. Is Vernonia amygdalina hepatotoxic or hepatoprotective? Response from biochemical and toxicity studies in rats. *African Journal of Biotechnology*. 2006;5(18):1648-1651. <https://doi.org/10.5897/ajb06.206>
36. Yakubu MT, Bilbis LS, Lawal M, Akanji M A. Effect of repeated administration of sildenafil citrate on selected enzyme activities of liver and kidney of male albino rats. *Nigerian Journal of Pure and Applied Science*. 2003;18, 395-400.
37. Vasudevan D, Vaidyanathan K (2018). Kidney function test. *Textbook of Biochemistry*, Chapter-25, 333-344. https://doi:10.5005/jp/books/13014_26