

Original Research Article

Chemical and biological evaluation of bakeries produced from golden berries

Abstract

This investigation was performed with the purpose of researching the influence of pizza containing dried golden berry fruits (DGBF) at different doses against carbon tetrachloride - induced hepatotoxicity in rats. The study shows phenols content of golden berry. 25 male rats were used in the biological investigation. Rats were divided into five groups (5 rats in group) the investigation was 12 weeks. The first group (negative group) was given a basal diet and the second group (G2, G3, G4, and G5) was injected intramuscularly with carbon tetrachloride 2 ml/kg BW (50% v/v in liquid paraffin) weekly to induce hepatotoxicity. After the injury, group G3, G4 and G5 fed on 50% basal diet supplemented with 50% pizza containing 5, 10 and 15% DGBF. Findings indicate that DGBF had a high antioxidant activity, total phenol, flavonoids, ascorbic acid and carotenoids content. Rats fed 50% pizza containing (5, 10, and 15%) DGBF had a lower serum total cholesterol, LDL cholesterol, triglyceride, urea, uric acid, creatinine, GOT, GPT, MDA and SOD compared to rats fed simply the basal diet (positive control). The DGBF was added to the pizza with different proportions, and its sensory properties were evaluated, and all proportions were proper to the panelists, compared to the control. The findings of this work suggest that golden berries could be used to treat and prevent hepatotoxicity patients.

Key words: Golden berry - phenolic Compounds- carbon tetrachloride – pizza- hepatotoxicity

1. Introduction

Numerous edible food crops, such as tomatillos, goldenberries, and groundcherries, are found in the Physalis genus of the Solanaceae family. Because consumers are becoming more intrigued by new fruits and veggies and have a growing understanding of the health advantages of consuming a varied diet, More interest has been given to these Physalis members. This

attention led to the conduct of many preliminary investigations on these *Physalis* plants to assess their nutritious and chemical profiles related to health advantages. The findings presented that these plants comprise a wide range of important vitamins and minerals, particularly K and ascorbic acid, which support the immune system and is also recognized for their antioxidant activity. In addition to their nutritional value, these plants comprise withanolides, a family of steroidal lactones famed for their anticancer and anti-inflammatory activities [1]. *Physalis* species withanolide extract has been shown in several investigations to be cytotoxic to cancer cells [1].

The amazing fruit Golden Berries (*Physalis peruviana* L.), furthermore well-known as Harankash in Egypt, has a wide range of culinary and therapeutic uses. According to Puente et al., [2], the occurrence of a number of specific phytosterols, (β -sitosterol, stigmasterol, and campesterol) which are present in large amounts in oils derived from the fruit of *P. peruviana* L. and exhibit antihypercholesterolemic and antioxidant effects, lowers blood cholesterol levels. Furthermore, high quantities of polyphenols like vitamins C and A contribute to the antioxidant activity associated with this finding. Lastly, the Egyptian GB (*P. peruviana* L.) has great potential as a functional food due to its high quality and quantity of nutrients and probiotics. The reduction of lipid accumulation, The redox balance of trace elements in obese rats, and the amelioration of iron overload in adipose tissues were all improved by GB feeding [3]. In addition, the value of GB as a natural iron chelator is now more widely acknowledged. Additionally, it reduces oxidative stress, enhancing the hemoglobin spin state in blood, which has an impact on how well it performs and restores hemoglobin's conformational structure and macromolecular function [3].

Goldenberries can be eaten raw in salads or processed into desserts like candy, cakes, jams, juices, pomace, raisins, and other pastries ([4].

The occurrence of metabolite degradation mechanisms during the fruit maturation process altered the nutritional content of the fruit, making it intriguing to assess metabolites in relation to the fruit ripening stage. [5].

The nutritional value of *Physalis peruviana* and its byproducts, makes them candidates for use in phytomedicine, the beauty industry, and the

preparation of functional foods. *Physalis peruviana* is a yellow-orange fruit with a juicy berry known as goldenberry or cape gooseberry[6].

The fruit of *Physalis peruviana* is extremely nutritious and delicious, and it contains nutraceutical properties including anti-inflammatory [7]; antimicrobial [8], and anticancer[9]. Its principal bioactive constituents are vitamins, physalins, carotenoids, and flavonoids [10]. Many fruits and vegetables have yellow, orange, or red coloring because of carotenoids. Due to their antioxidant and vitamin A content, they are crucial to the diet [11].

The health benefits associated with *Physalis Peruvian* consumption are mostly attributable to its nutritional composition. Berries are abundant in a variety of biological components, including carotene, vitamins B, C, E, and K, phytosterols, and essential minerals like iron and polyunsaturated fatty acids [12].

Liver illnesses continue to be one of the most important health issues in the world, but there are few choices for prevention and treatment [13]. It is generally known that oxidative stress, pathogenesis and inflammation are the causes of liver ailment, and that a viable therapeutic approach for the treatment and prevention of liver illnesses involves postponing and delaying the chain reactions of the oxidation, and inflammatory processes [14,15]. One of the many effects of carbon tetrachloride (CCl₄) poisoning is the generation of reactive oxygen species (ROS), such as superoxide and hydroxyl radicals, which are crucial in the development of liver disease.. [16,17]. It is argued that trichloromethyl, a byproduct of CCl₄'s primary metabolism, starts the biochemical reactions that lead to oxidative stress, which is the main reason for many pathological illnesses, including cancer, hypertension, diabetes mellitus, kidney and liver damage, and even mortality [17,18].

Oxidative stress is a primary inducer of apoptosis in a variety of acute and chronic liver injuries, as well as in hepatic fibrosis, according to clinical and experimental findings [19]. The depletion of antioxidant status and the exacerbation of lipid peroxidation are associated with hepatic fibrosis induced by CCl₄[17,20]. Accordingly, a promising and successful treatment approach for avoiding or postponing the development of hepatic fibrosis is presented by the use of antioxidants and their interactions in the diet, which has caught the

attention of investigators [21,22]. Given the aforementioned, the current study's objectives were to examine the effects of using dried golden berry fruit in the making of pizza and to fortify various pizza proportions with their functional qualities. Additionally, albino rat models with experimentally induced hepatitis were used to investigate the therapeutic potential of the fortified pizza as a functional food.

2 Materials and Methods

Materials

2.1 Golden berry collection

Healthy mature golden berries (*Physalis peruviana*) were obtained from a commercial market in Mansoura city, Egypt. The golden berries were peeled from their calyx, cleaned under running water, dried in the oven until a constant weight was reached, and then ground into powder using an electric grinder. The fruits were stored in the refrigerator for further use.

Preparation of blends:

Different mixtures were formed by partially adding wheat flour with dried golden berries fruits (DGBF) in levels of 5, 10, 15, and 20% to produce experimental pizza blends.

Preparation of Pizza:

The straight-dough technique was used to make examples of pizza. according to the method outlined by de Delahaye et al. [23] with some modifications, the following ingredients were used to make the control pizza dough: 100 g wheat flour 72% extraction, 14g corn oil, 1g salt, 2g sugar, 2g instant active dry yeast, water, diced green pepper, diced tomato, a small quantity of tomato paste, shredded mozzarella cheese, diced pickled olive and sliced pastrami were sprinkled on the top of pizza. The effect of adding 5, 10 and 15% DGBF with wheat flour on pizza besides, to control, and quality was studied.

The ingredients for the pizza dough were blended in a mixing bowl until they reached their maximum development. The resulting dough's were let to rest for 20 min at 30±2°C (first proofing), and then they were divided into 150g pieces, hand-rounded, and placed in pans for a 60-min final proofing period at 30±2°C and 80–85 % relative humidity in a fermentation cabinet. then baked for 10–15 min at 210–220°C in an electrically heated oven with steam provided throughout baking. Next, Pizza samples were taken out of the metal pan after

baking, cooled at room temperature, and then packed in plastic bags to inhibit moisture until analysis.

Sensory characteristics of pizza:

The sensory characteristics of pizza were assessed by a panelists of twenty staff- members from the Special Food and Nutrition Department, Food Technology Research Institute, Agricultural Research Center, Giza, Egypt. The defrosted pizza was used to make elaborate pizza samples. Color, taste, odor, texture (expressed by hardness and chewing action), and general appearance of the crust were the sensory characteristics that were assessed according to **the** method outlined by [23].

Determination of total phenol content (TPC)

The Folin-Ciocalteu method [24] was used to determine the TPC of the extracts. The absorbance was converted to milligrams of gallic acid equivalent per gram of dry material (**mg GAE/g**) using a gallic acid standard curve.

Determination of total flavonoid content (TFC)

The TFC was determined using a colorimetric procedure with the aluminum chloride technique as **outlined** by [25]. The results were calculated using quercetin as the reference substance and represented as milligrams of quercetin equivalent per gram of dry material (**mg QE/g**).

Determination of antioxidant activity

The DPPH radical scavenging activity method, as suggested by [26], was used to assess the free radical scavenging ability of DGBF.

Determination of vitamin C (Ascorbic acid):

HPLC was employed to measure ascorbic acid according to the producer outlined by [27].

Determination of carotenoids:

According to the **procedure** described by [28], carotene was measured by HPLC.

Diet of experiment rats

From the experimental animal house of the Food Technology Research Institute, Agric, Res., Center, Giza, Egypt, 25 mature male albino rats weighing between (180-186) were obtained. The animals were housed under inspection in a clean, well-ventilated cage for ten days **before the** experiment.

They were given a standard diet and free access to water. The quantity of fat, protein, carbohydrates, minerals, and vitamins in the basal diet complied with the rats' recommended dietary allowances. The basal diet was comprised of 10 % sucrose, 20 % protein (casein), 5 % corn oil, 2% choline chloride, 3.5% salt mixture, 5% fibers (cellulose), and 1% vitamins mixture, corn starch made up of remaining material entirely[29].

Experimental design

The research was carried out in Animal House in Food Technology. Research Institute, Agric, Res., Center, Giza, Egypt. After the adaptation period, 25 rats were divided into two main groups, the first group (n = 5 rats) was not injected with CCl₄ negative control(G₁) rats fed on the basal diet. The rats of the second group main (n= 20 rats) were subcutaneously injected with 2 ml/kg of weight rat of CCL₄ diluted with liquid paraffin (1:1 v:v) weekly during the experiment period to induce hepatotoxicity according to Li et al.,[30] rats of the second group main divided to four groups positive control (G₂) rats fed on the basal diet, G₃, G₄ and G₅ rats fed on the pizza containing with 5, 10 and 15% of DGBF.

Group (1): normal rats fed on a basal diet control negative(-ve) group.

Group (2): Hepatotoxicity rats kept a positive control (+ ve) group and fed on a basal diet.

Group (3): Hepatotoxicity rats were fed on pizza containing 5% dried golden berry fruits

Group (4): Hepatotoxicity rats were fed on pizza containing 10% dried golden berry fruits

Group (5): Hepatotoxicity rats were fed on pizza containing 15% dried golden berry fruits

G₁ and G₂ were fed on a 100% basal diet without any addition, meanwhile, G₃, G₄, and G₅ were fed on 50% pizza containing different proportions of dried golden berry+50% basal diet.

At the end of the experiment (12 weeks) each animal was anesthetized with ethyl ether. The blood collects from the vein plexus eye and is put in a dry clean centrifuged for 10 min at 3000 rpm to separate the serum, which was kept frozen at -20 °C in clean dry plastic until analyzed.

2.2.8 Biochemical Analyses:

Biochemical analysis:-

Cholesterol (CHL), low density lipoprotein (LDL), high density lipoprotein (HDL), triglyceride (TG), serum alanine amino-transferase (ALT), serum aspartate amino-transferase (AST) albumin (ALB), urea, creatinine, uric acid,

malondialdehyde (MDA) and super oxide dismutase (SOD) purchased from SPINREACT Co, SPAIN 2022.

Analysis of antioxidant indicators and oxidative stress

10 ml of phosphate buffer (pH 7.4) and 1g of rat liver were blended, and the mixture was rotated for 15 minutes at 4 °C and 10,000 rpm. Analysis of the proteins and enzymes was done using the supernatant, which was gathered. Thiobarbituric acid and lipid peroxide can react in the catabolite of MDA to produce a red compound with a maximum absorption peak of 532 nm [31]. Using a previously tested method, superoxide dismutase (SOD) activity was assessed in tissue homogenates [32]. At 15-second intervals for 1 minute, variations in absorbance at 480 nm were observed. In parallel, a control reaction without the enzyme and with all other components was investigated. The test method's definition of one unit of enzyme activity was 50% of epinephrine's antioxidant activity is suppressed. Determined reduced glutathione levels using the method that was described [33]. Immediately after the combination developed a yellow hue, its absorbance was assessed using a "spectrophotometer at 420 nm."

Histopathological examinations:

For histopathological analysis, liver samples from each group were taken. Specimens were preserved in 10% (v/v) neutral buffered formalin. Hematoxylin and eosin was used to prepare sections that were 4-6 µm thickness and examined histopathologically using light microscopy according to [34].

Statistical evaluation

The acquired data were statistically evaluated using One-Way Analysis of Variance (One Way ANOVA) in SPSS 26.

RESULTS AND DISCUSSION

Sensory analysis of pizza

Table 1 shows the sensory characteristics of pizza produced from blends containing wheat flour and (DGBF). The sensory qualities of blended pizza were impacted by the dried golden berry fruits and wheat flour adding

significantly ($p \leq 0.05$). The addition of DGBF decreased the crust color value to 18.10–14.00 respectively in compared to the control (19.30). Furthermore addition of DGBF decreased the odor value to 18.70–15.00 respectively in compared to the control (19.00). Similarly. Supplementing WF with DGBF significantly ($P \leq 0.05$) decreased taste value to 17.50–15.70 respectively in compared to the control (18.50). Also, the supplement of WF with DGBF blends significantly ($P \leq 0.05$) decreased the texture score of the pizza from 18.50 in control to 17.40–14 in blended breadsticks respectively. Also, the supplement of WF with DGBF blends significantly ($P \leq 0.05$) decreased the general appearance score of the pizza from 19.50 in control to 18.30–15.20 in blended pizza respectively. Adding WF with DGBF significantly ($P \leq 0.05$) decreased the overall acceptance value to 90.00–73.90 compared to the control (94.80). These findings match those described by [35] found that when increasing cape golden berry at extents 5, 10, 15 and 20% the overall acceptability, odor, taste, and color were decreased in breadsticks.

Table 1. Sensory properties of pizza

Blends	Crust color (20)	Odor (20)	Taste (20)	Texture (20)	General appearance (20)	Overall acceptability (20)
Control	19.30 ^a	19.00 ^a	18.50 ^a	18.50 ^a	19.50 ^a	94.80 ^a
Pizza with 05% DGBF	18.10 ^b	18.70 ^b	17.50 ^b	17.40 ^b	18.30 ^b	90.00 ^b
Pizza with 10% DGBF	17.00 ^c	17.00 ^c	17.00 ^c	16.00 ^c	17.50 ^c	84.50 ^c
Pizza with 15% DGBF	16.50 ^d	16.10 ^d	16.20 ^d	15.10 ^d	16.10 ^d	80.00 ^d
Pizza with 20% DGBF	14.00 ^e	15.00 ^e	15.70 ^e	14.00 ^e	15.20 ^e	73.90 ^e

Mean values with different superscripts within the same column are significantly different ($p \leq 0.05$)

phytochemicals composition in DGBF

Table 2 displays the total phenolic, flavonoid, DPPH inhibition percentage, ascorbic acid, and carotenoids present in the DGBF. The Total Flavonoids' compounds is computed as mg quercetin equivalent (RE)/g of dried extract, and the Total phenol compound is determined as mg GAE/g of plant extract [35] showed that DGBF contains flavonoid, total phenolic, ascorbic acid and carotenoids. The percentage of DPPH radical scavenging activity used to describe the results ranged from 28 to 90% for all varieties of golden berries [36]

Table2. Total phenolic , flavonoid, % DPPH Inhibition, ascorbic acid and carotenoids composition in DGBF.

Components	Dried golden berry fruits
Total phenol (mg GAE/ g of dried extract)	140
Total Flvaonoids (mg GAE/g of dried extract)	51.70
% DPPH Inhibition	75.34
Ascorbic acid (mg/100g)	150
Carotenoids (_mg/100g)	1350

Phenolic Compounds of DGBF

Polyphenolic compounds of DGBF were recorded in Table 3. The results indicated that DGBF contains fifteen phenolic compounds. rutin, kampferol, quercetin, chlorogenic acid, and catechin was a major phenolic compound in DGBF. These findings are in a harmony with [37] showed that golden berries are rich in phenolic acids like ferulic, chlorogenic, gallic, caffeic, and p-coumaric acids, flavonoids like quercetin, myricetin, rutin, kaempferol, catechins , and epicatechin biologically active constituents that lower the risk of certain ailments and promote health benefits like anti-hepatotoxic properties, and anti-inflammatory activity. Therefore, numerous researchers have focused on the utilization of antioxidants and their interactions in the diet as a feasible and efficient treatment strategy for avoiding or postponing the development of hepatic fibrosis [22].

Table 3. phenols content of DGBF.

Phenolic compounds	(mg/100g)
Rutin	95.00
Kampferol	55.26
Quercetin	30.48
chlorogenic acid	17.00
Catechin	10.52
Ferulic acid	7.51
Gallic acid	3.64
Protocatchoic	2.20
P-Coumaric acid	2.89
Vanillic acid	1.45
Epi-catachin	2.46
Benzoic acid	1.30
Cinnamic acid	3.27
Salicylic acid	2.25

Effect of DGBF on Body Weight, Final Body Weight and Body Weight Gain (%), of Normal and hepatic Rats.

Data in Table 4 showed that, the mean values of initial body weight of all rat groups after adaptation ranged between 180 to 186 g. At the end of the experiment (12 weeks), the final body weight of hepatic control rats (G2) was lower than the normal control (G1). While hepatic rats that fed on basal diet supplements with DGBF (G3, G4, and G5) have higher final body weight compared to hepatic control rats (G2). According to [38], ascorbic acid, which is present in high concentrations in *P. peruviana* L. fruit, is essential for a number of processes in the human body, including the generation of neurotransmitters, tissue maintenance, immune system responses, growth, and hormones.

Table 4. Effect of feeding on pizza with DGBF on initial and final weight and bodyweight gain in rats.

Groups	Diets	Initial weight(g) (M±SD)	Final weight (g) (M±SD)	Body weight gain	
				g	%
G1	Negative control (BD)	183.33 ^{ab} ±1.55	215.00 ^a ±1.64	31.66 ^a ±1.52	14.71 ^a ±1.75
G2	Positive control (BD)	181.33 ^b ±2.51	196.67 ^c ±2.51	15.66 ^b ±1.52	7.78 ^b ±1.50
G3	Pizza with 5 % DGBF	180.00 ^b ±1.51	204.33 ^b ±1.52	24.33 ^b ±2.51	11.91 ^b ±2.40
G4	Pizza with 10% DGBF	184.33 ^{ab} ±2.51	214.33 ^a ±.577	29.33 ^a ±2.64	13.68 ^a ±2.00
G5	Pizza with 15% DGBF	186.00 ^a ±1.55	218.33 ^a ±1.15	32.33 ^a ±1.70	14.80 ^a ±0.96

Means ±SD (n = 5) with the same letter (in column) are not significantly different (P ≤ 0.05).
BD= Basal Diet DGBF=Dried golden berry flour

Impacts of DGBF on lipid parameters

The lipid parameters of hepatic rats that consumed the DGBF supplement is presented in Table 5. In this investigation, hepatic rats had markedly higher plasma levels of TG, TC, and LDL than the healthy control group (p<0.05). Table 6 shows that DGBF supplementation dramatically decreased the

amount of HDL in the liver-damaged rats and considerably increased the levels of TC, TG, and LDL when compared to the healthy control group. In comparison to rats with hepatic rats, DGBF supplementation groups significantly increased HDL ($p < 0.05$). Additionally, when compared to the healthy control group, the hepatic group's levels of TG, TC, and LDL cholesterol were considerably higher ($p < 0.05$). TG, TC, and LDL levels were significantly decreased in the DGBF group at low and high doses ($p < 0.05$), while HDL levels are rising. These results are similar to [39] In comparison to obese rats, golden berry supplementation groups markedly increased HDL ($p < 0.05$). Low or high doses of golden berries significantly decreased LDL levels ($p < 0.05$).

Table 5. Influence of feeding on pizza with DGBF on serum lipids parameter

Groups	Total cholesterol (mg/dl) (M±SD)	Triglyceride (mg/dl) (M±SD)	HDL (mg/dl) (M±SD)	LDL (mg/dl) (M±SD)	VLDL (mg/dl) (M±SD)
G1	97.66 ^e ±3.00	118.33 ^c ±2.64	56.00 ^{ab} ±1.52	16.00 ^e ±2.75	23.67 ^c ±0.51
G2	174.33 ^a ±2.51	151.67 ^a ±2.51	29.33 ^c ±1.52	114.33 ^a ±1.50	30.33 ^{ab} ±0.50
G3	169.33 ^b ±2.51	150.00 ^a ±1.52	50.67 ^b ±2.51	88.67 ^b ±2.40	30.00 ^{ab} ±0.30
G4	154.33 ^c ±2.51	146.67 ^{ab} ±0.57	54.33 ^{ab} ±2.64	71.00 ^c ±2.00	29.33 ^{ab} ±0.12
G5	141.33 ^d ±2.00	133.33 ^{bc} ±1.15	58.00 ^a ±1.00	56.33 ^d ±1.96	26.67 ^{bc} ±0.23

Means ±SD ($n = 5$) with the same letter (in column) are not significantly different ($P \leq 0.05$).

Effect of feeding on pizza with DGBF on kidney functions.

The values in Table 6 illustrated the effect of supplemented diets pizza with DGBF on kidney function; urea, uric acid, and creatinine. CCl₄, not only affects the kidney weight but also the kidney functions as implied by the increment of plasma creatinine, urea, and uric acid in the positive control group which is markedly higher compared to the normal control group. The rats fed pizza with DGBF (5, 10, and 15%) groups had significantly decreased the plasma levels of uric acid, urea and creatinine. The best results of plasma

creatinine levels of treated groups were found in the group feed on pizza containing 15% of DGBF. The golden berry was formally highly prized by Arab physicians as a medical herb for treating kidney disease and diseases of the urinary passage. Today, it is applied in homeopathy for the same purpose. According to [40], animals fed with different *physalisperuviana* doses demonstrated a significant decreasing effect ($p < 0.05$) in the increased levels of blood markers such as creatinine and urea indicating the protection against kidney cell damage.

Table 6. Effect of feeding on pizza with DGBF on kidney functions

Group	Diets	Urea (mg/dl)	Uric acid (mg/dl)	Creatinine (mg/dl)
G1	Negative control (BD)	33.33 ^e ±0.16	2.68 ^e ±0.13	0.78 ^d ±0.05
G2	Positive control(BD)	67.67 ^a ±1.45	6.36 ^a ±0.16	1.88 ^a ±0.12
G3	Pizza with 5% DGBF	60.33 ^b ±1.68	5.58 ^b ±0.12	1.36 ^b ±0.08
G4	Pizza with 10% DGBF	52.67 ^c ±1.72	4.69 ^c ±0.51	1.14 ^c ±0.04
G5	Pizza with 15% DGBF	43.67 ^d ±1.12	3.89 ^d ±0.67	0.93 ^d ±0.02

Means ±SD ($n = 5$) with the same letter (in column) are not significantly different ($P \leq 0.05$).
BD= Basal Diet DGBF=Dried golden berry flour

Effect of feeding pizza with DGBF on liver functions of rats:

The results in Table 7 displayed the influence of supplemented diets with pizza containing DGBF on liver function. It is noticed that CCl₄ injection led to a significant decrease in GOT, GPT, albumin, and bilirubin ratio of the positive control group compared to the normal control group. Rats groups feeding in pizza containing DGBF proportions (5, 10, and 15 %) decreased significantly the liver function levels while increasing total protein. The best results in the level of liver function were found in the rat groups fed pizza containing 15% of DGBF.

According to [40], *physalisperuviana* has an anti-hepatotoxic impact on the entire ripe fruit. The high levels of serum parameters such as GPT and GOT in animals treated with or fed *physalisperuviana* preparations significantly decreased ($p < 0.05$), indicating that the animals were protected against hepatic cell injury. The antioxidant properties of *Physalisperuviana* may be the cause of its potential hepatoprotective effects. The same author also claimed that *physalisperuviana* contains a variety of substances, including withanolides, 28-hydroxywithanolide, quercetin, kaempferol, di- and tri-glycosides. These substances have potential antioxidant properties that guard against oxidative damage to hepatocytes and liver microsomes. According to studies, *physalisperuviana* contains phenols and flavonoids. Flavonoids are referred to as free-radical scavengers and are strong antioxidants against free radicals. One of the pathways for hepatoprotective effects is reported to involve antioxidant activity. These results were nearly with [41]

Table 7. Effect of feeding with DGBF on liver functions of rats:

Groups	GOT (AST) (IU/L)	GPT (ALT) (IU/L)	Albumin (mg/dl)	Total protein (g/dl)	Bilirubin (mg/dl)
G1	25.32 ^d ±1.68	33.65 ^e ±1.56	3.77 ^c ±0.35	6.43 ^a ±0.24	0.28 ^e ±0.24
G2	51.67 ^a ±1.84	55.34 ^a ±2.08	7.63 ^a ±0.53	4.33 ^d ±0.49	0.64 ^a ±0.35
G3	41.65 ^b ±1.61	43.32 ^b ±1.35	5.70 ^b ±0.48	4.38 ^e ±1.86	0.54 ^b ±0.34
G4	38.35 ^b ±1.96	42.00 ^c ±1.92	5.17 ^b ±0.43	5.33 ^c ±0.32	0.46 ^c ±0.14
G5	32.00 ^c ±1.72	39.35 ^d ±1.75	4.03 ^c ±0.64	5.83 ^b ±0.26	0.40 ^d ±0.27

Means ±SD ($n = 5$) with the same letter (in column) are not significantly different ($P \leq 0.05$).

Effect of pizza with DGBF supplementation on the liver's antioxidant and oxidative stress parameters in rats.

The antioxidant enzymes and oxidative stress parameters in the liver of rats given pizza containing DGBF are shown in Table 8 in compared to the control group, both negative and positive. Reactive oxygen species are calculated by comparing the amount of MDA in the liver to control rats. Rats with the hepatic disease have significantly increased lipid peroxidation in the liver ($p > 0.05$).

Supplementing with golden berries reduced lipid peroxidation in hepatic rats ($p > 0.05$). Reduced glutathione (GSH) and SOD are cellular antioxidants that are present naturally and help lower oxidative stress. Table 5 illustrates SOD activity was significantly higher in the hepatic rats' livers than in the control group in this study ($p < 0.05$). In contrast, hepatic rats' livers have significantly less GSH than normal rats' livers. Rats receiving supplements of dried golden berries significantly ($p < 0.05$) increased SOD activity and GSH levels in the hepatic rats groups. These findings harmony with [39] Supplementing with golden berries significantly ($p < 0.05$) improved SOD activity and GSH levels in obese individuals.

Iron was released from the heme group of myoglobin as part of the mechanism that caused oxidative stress. Superoxides and other high-activity oxides, such as hydrogen peroxide and oxygen molecules, are produced by iron, and they cause oxidative stress, lipid peroxidation, and cellular death. According to [12], *physalis peruviana* L. significantly increased SOD levels when compared to other groups. The antioxidant enzyme superoxide dismutase in the body has been demonstrated to be activated by golden berry components. Golden berries "have the highest antioxidant and anti-inflammatory concentration of any food," according to researchers. Additionally, the crucial antioxidant enzyme superoxide dismutase (SOD) is activated more by substances found in golden berries

Table 8. Antioxidant and oxidative stress parameter in the liver of rats:

Group	Diets	MDA (nmol/g wet tissue)	SOD (U/mg protein)	GSH (mg/g wet tissue)
G1	Negative control (BD)	80.10 ^e ±2.16	18.34 ^d ±1.13	128.38 ^a ±3.65
G2	Positive control(BD)	153.11 ^a ±3.45	39.00 ^a ±2.16	80.68 ^e ±2.16
G3	Pizza with 5% DGBF	122.77 ^b ±3.68	27.35 ^b ±1.12	98.56 ^d ±3.48
G4	Pizza with 10% DGBF	96.67 ^c ±1.72	19.69 ^c ±1.51	110.14 ^c ±3.04
G5	Pizza with 15% DGBF	77.47 ^d ±2.12	15.33 ^e ±0.67	116.43 ^b ±3.32

Means ±SD ($n = 5$) with the same letter (in column) are not significantly different ($P \leq 0.05$).

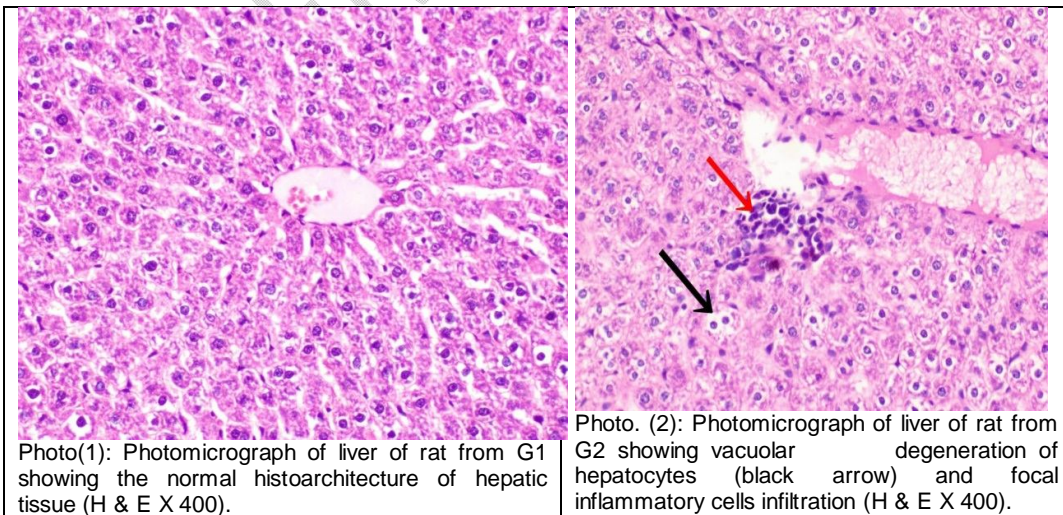
BD= Basal Diet DGBF=Dried golden berry flour

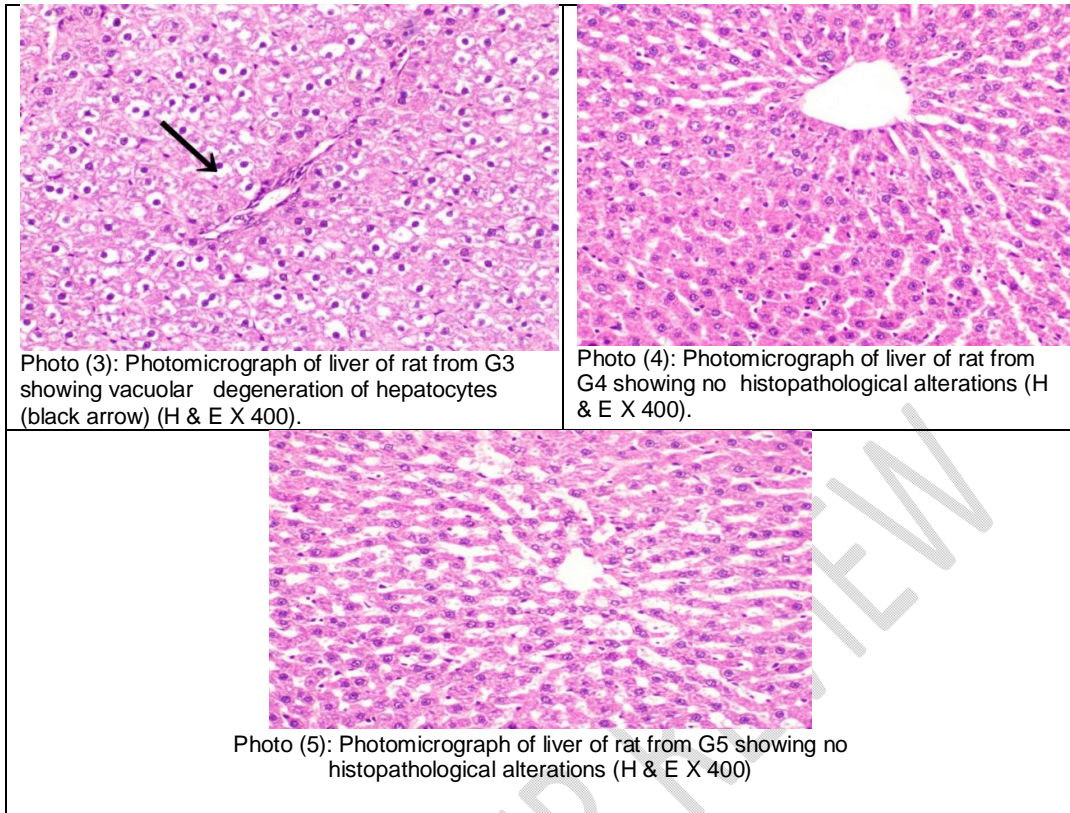
Histopathological changes in liver

Microscopic investigation of liver rat Photo(1): Photomicrograph of liver of rat from G1 revealing the normal histoarchitecture of hepatic tissue (H & E X 400). Also, Photo. (2): Photomicrograph of the liver of rat from G2 viewing vacuolar degeneration of hepatocytes (black arrow) and focal inflammatory cells infiltration. Photo (3): Photomicrograph of the liver of rat from G3 presenting vacuolar degeneration of hepatocytes (black arrow). Photo (4): Photomicrograph of the liver of rat from G4 displaying no histopathological alterations. Photo (5): Photomicrograph of the liver of rat from G5 screening no histopathological alterations (H & E X 400)

According to [35,42], biochemical data showed that CCl₄ caused significant histological alterations in hepatic tissue. Also, the strong antioxidant content of goldenberries may also help to reduce the morphological alterations in the liver. The CCl₄ free radicals produced by the Cytochrome P450 enzyme system could be eliminated by these compounds. By giving unsaturated lipids in the membrane a competitive substrate and/or by speeding up the healing process of a damaged cell membrane, oxidative damage to tissues was reduced.

Histopathological changes in liver





Conclusion:

Supplementation of pizza with DGBF at doses of 5,10, and 15% markedly enhanced lipid parameters, liver and kidney functions of hepatotoxicity rats. These findings may be related to DGBF substances with hepatoprotective, antilipidemic, anti-diabetic, and antioxidant properties, such as phenolic compounds, flavonoids, carotenoids, and ascorbic acid. Consequently, Pizza containing DGBF may be used to treat hepatotoxicity patients and avoid complications from diabetes, such as obesity.

REFERENCES

1. Shenstone E, Lippman Z, Van Eck J. A review of nutritional properties and health benefits of *Physalis* species. *Plant Foods Hum Nutr.* 2020; 75(3), 316-325.
2. Puente LA, Pinto-Muñoz CA, Castro ES, Cortés M. *Physalis peruviana* Linnaeus, the multiple properties of a highly functional fruit: A review. *Food Res Int.* 2011;44:1733-40.
3. Moussa SAA, Ibrahim FAA, Elbaset MA, Aziz SW, Abdellatif N, Attia A, El Toumy SA, Salib JY, Bashandy SAE. Efficacy of goldenberry extract in chelated iron overload induced by obesity: Novel safety concept for the

treatment of iron overloads diseases. J App Biol Biotech. 2022;10(4):92-100. DOI: [10.7324/JABB.2022.100413](https://doi.org/10.7324/JABB.2022.100413)

4. Sharoba MA, Ramadan MF. Rheological behavior and physicochemical characteristics of goldenberry (*Physalis peruviana*) juice as affected by enzymatic treatment. J Food Process Pres. 2011; 35: 201-219. DOI: [10.1111/j.1745-4549.2009.00471.x](https://doi.org/10.1111/j.1745-4549.2009.00471.x).

5. Etzbach L, Pfeiffer A, Weber F, Schieber A. Characterization of carotenoid profiles in goldenberry (*Physalis peruviana* L.) fruits at various ripening stages and in different plant tissues by HPLC-DADAPCI-MSn. Food Chem, 2018; 245: 508-517.

DOI: [10.1016/j.foodchem.2017.10.120](https://doi.org/10.1016/j.foodchem.2017.10.120).

6. Nocetti, D, Núñez H, Puente L, Espinosa A, Romero F. Composition and biological effects of goldenberry byproducts: an overview. J Sci Food Agric. 2020;100(2): 4335-4346. DOI: <https://doi.org/10.1002/jsfa.10386>

7. Dong B, An L, Yang X, Zhang X, Zhang J, Tuerhong M, Guo Y. Withanolides from *Physalis peruviana* showing nitric oxide inhibitory effects and affinities with iNOS. Bio org Chem. 2019;87: 585-593. DOI: <https://doi.org/10.1016/j.bioorg.2019.03.051>

8. El-Beltagi H S, Mohamed H I, Safwat G, Gamal M, Megahed BM H. Chemical composition and biological activity of *Physalis peruviana* L. Gesunde Pflanzen. 2019;71(2):113-122. DOI: <https://doi.org/10.1007/s10343-019-00456-8>

9. Ballesteros-Vivas D, Alvarez-Rivera G, León C, Morantes S J, Ibáñez, E., Parada-Alfonso, F, Valdés, A. Anti-proliferative bioactivity against HT-29 colon cancer cells of a withanolides-rich extract from golden berry (*Physalis peruviana* L.) calyx investigated by Foodomics. J. Funct. Foods. 2019;63: 103567. DOI: <https://doi.org/10.1016/j.jff.2019.103567>

10. Carrillo-Perdomo E, Aller A, Cruz-Quintana S M, Giampieri F, Alvarez-Suarez J M. Andean berries from Ecuador: a review on botany, agronomy, chemistry and health potential. J. Berry Res. 2015;5(2): 49-69. DOI: <https://doi.org/10.3233/JBR-140093>

11. Saini RK, Nile S H, Park S W. Carotenoids from fruits and vegetables: chemistry, analysis, occurrence, bioavailability and biological activities. Int. Food Res. J. 2015; 76(Part 3): 735-750. DOI: <https://doi.org/10.1016/j.foodres.2015.07.047>

12. Ali O, Yassen E, Temraz A. Study the Biological and Biochemical Effects of Some Dried Fruits on Acute Renal Failure in Rats. Egypt. J. Nutr. Health. 2019; 14: 59-75.

<https://doi.org/10.21608/ejnh.2019.104056>

13. Asrani S K, Devarbhavi H, Eaton J, Kamath P S. Burden of liver diseases in the world. *J. Hepatol.* 2019; 70(1):151-171.
14. Al-Olayan E M, El-Khadragy M F, Aref A M, Othman M S, Kassab R B, Abdel Moneim A E. The potential protective effect of *Physalisperuviana* L. against carbon tetrachloride-induced hepatotoxicity in rats is mediated by suppression of oxidative stress and downregulation of MMP-9 expression. *Oxid. Med. Cell. Longev.* 2014; 381413.
15. Hikal AH, Abd El-Fatta H M, El-Sheik N M, Refaie A A. Comparative study of marjoram (*Origanum majorana* L.) and silymarin (*Silybum marianum* L.) extract against carbon tetrachloride induced hepatic injury. *World J Pharm Pharm Sci.* 2018; 7(8): 1969-1992.
16. Arauz J, Rivera-Espinoza Y, Shibayama M, Favari L, Flores-Beltrán, R E. and Muriel P. Nicotinic acid prevents experimental liver fibrosis by attenuating the prooxidant process. *Int. Immunopharmacol.* 2015;28(1): 244-251.
17. Ramos-Tovar E, Muriel P. Molecular mechanisms that link oxidative stress, inflammation, and fibrosis in the liver. *Antioxidants.* 2020;9(12): 1279.
18. Casas-Grajales S, Reyes-Gordillo K, Cerda-García-Rojas C M, Tsutsumi V, Lakshman, M R, Muriel P. Rebaudioside A administration prevents experimental liver fibrosis: an in vivo and in vitro study of the mechanisms of action involved. *J Appl Toxicol.* 2019;39(8): 1118-1131.
19. Chen Z, Tian R, She Z, Cai J, Li H. Role of oxidative stress in the pathogenesis of nonalcoholic fatty liver disease. *Free Radical Biology and Medicine*, 2020;152: 116-141.
20. Fu Y, Zheng S, Lin J, Ryerse J, Chen A. Curcumin protects the rat liver from CCl₄-caused injury and fibrogenesis by attenuating oxidative stress and suppressing inflammation. *Mol. Pharmacol.* 2008;73(2): 399-409.
21. Deng G, Wang J., Zhang Q, He H, Wu F, Feng T, Hattori, M. Hepatoprotective effects of phloridzin on hepatic fibrosis induced by carbon tetrachloride against oxidative stress-triggered damage and fibrosis in rats. *Biol. Pharm. Bull.* 2012;35(7): 1118-1125.
22. Thuy T T V, Hai H, Kawada N. Role of oxidative and nitrosative stress in hepatic fibrosis. In *Liver pathophysiology*. 2017;(pp. 213-224). Academic Press.
23. de Delahaye E P, Jiménez P, Pérez E. Effect of enrichment with high content dietary fiber stabilized rice bran flour on chemical and functional properties of storage frozen pizzas. *J. Food Eng.* 2005; 68(1): 1-7.

24. Agbor GA, Vinson AJ, Donnelly PE. Folin-Ciocalteu Reagent for Polyphenolic Assay. *Int. j. food sci. nutr. diet.* 2014; 3: 147–56. <https://doi.org/10.19070/2326-3350-1400028>.
25. Ouadi Y E, Bendaif H, Mrabti H N, Elmsellem H, Kadmi Y, Shariati M A, Bouyanzer A. Antioxidant activity of phenols and flavonoids contents of aqueous extract of Pelargonium graveolens organ in the North-East Morocco. *Microbiol. Biotechnol. Food Sci.* 2021; 1218-1220 <https://doi.org/10.15414/jmbfs.2017.6.5.1218-1220>.
26. Abdel-Razek A G, Badr A N, Shehata MG. Characterization of olive oil by-products: Antioxidant activity, its ability to reduce aflatoxigenic fungi hazard and its aflatoxins. *Annu. Res. Rev. Biol.* 2017; 1-14
27. Shimada Y, Ko S. Quantitative Determination of Ascorbic Acid in Vegetables by High Performance Liquid Chromatography. *Chugokugakuen J.* 2006; 5: 13-16.
28. Khalil A, Varanani FR. Carotiniod extraction and analysis by reversed phase HPLC system. *Sarhad J. Agric.* 1996; 105 (67): 15-21.
29. Reeves PG, Nielson FH, Fahmy GC. Reports of the American Institute of Nutrition, Adhoc Willing Committee on Reformulation of the AIN 93, Rodent diet. *J. Nutr.* 1993; 123: 1939-1951.
30. Li R, Xu L, Liang T, Li Y, Zhang S, Duan X. Puerarin mediates hepatoprotection against CCL4 -induced hepatic fibrosis rats through attenuation of inflammation response and amelioration of metabolic function. State University Press. 2013; 39-63.
31. Kei S. Serum lipid peroxide in cerebrovascular disorders determined by a new colorimetric method. *Clin Chim Acta*, 1978; 90: 37– 43; [doi:10.1016/0009-8981\(78\)90081-5](https://doi.org/10.1016/0009-8981(78)90081-5)
32. Nishikimi M, Appaji Rao N, Yagi K. The occurrence of superoxide anion in the reaction of reduced phenazine methosulfate and molecular oxygen. *Biochem Biophys Res Commun.* 1972; 46: 849–54; [doi:10.1016/S0006-291X\(72\)80218-3](https://doi.org/10.1016/S0006-291X(72)80218-3).
33. Beutler E, Duron O, Kelly BM. Improved method for the determination of blood glutathione. *J Lab Clin Med* . 1963; 61: 882–8.
34. Bancroft JD, Steven A, Turner DR. Theory and Practice of Histological Techniques. 129s Churchill Livingstone. New York, London, Edinburgh, Madrid, Melbourne, San Francisco, Tokyo. 1996.
35. Abd El-Gwad A E. Chemical, Technological and Biological Studies On Some Functional foods. Ph. D. Thesis, Food Indus. Dept., Fact. Agric. Mansoura Univ., Egypt. 2019.

36. González-Mendoza D, Grimaldo-Juárez O, Soto-Ortiz R, Escoboza-García F, Hernández J F S. Evaluation of total phenolics, anthocyanins and antioxidant capacity in purple tomatillo (*Physalisixocarpa*) genotypes. *Afr. J. Biotechnol.* 2010;9(32): 5173-5176. <https://doi.org/10.4314/ajb.v9i32>
37. Ezzat SM, Abdallah HM, Yassen NN, Radwan RA, Mostafa ES, Salama MM, Salem MA. Phenolics from *Physalisperuviana* fruits ameliorate streptozotocin-induced diabetes and diabetic nephropathy in rats via induction of autophagy and apoptosis regression. *Biomed. Pharmacother.* 2021;142: 111948.
38. Hassanien M F R. *Physalisperuviana*: A Rich Source of Bioactive Phytochemicals for Functional Foods and Pharmaceuticals Food Reviews International. 2011; 27 (3): 259-27.
39. Sherif A, Abdelmottaleb M, Fatma A A. and Ibrahim M A. Goldenberry (*Physalisperuviana*) alleviates hepatic oxidative stress and metabolic syndrome in obese rats, *J. Appl. Pharm. Sci.* 2022: 001-013.
40. Taj D, Khan H, Sultana V, Ara J, Ehteshamul-Haque S. Biotechnology and Drug Development Laboratory. *Pak. J. Pharm. Sci.* 2014; 27(3):491-494.
41. Naumova N, Nechaeva T, Savenkov O, Fotev Y. Yield and fruit properties of husk tomato (*Physalisphyladelphica*) cultivars grown in the open field in the South of West Siberia. *Horticulturae*. 2019; 5 (19): 1-12.
42. El-Ghany A, Sedki AG, Bakr A E. Nutraceutical Effects of Some Medical Fruits against Carbon Tetrachloride Induced Hepatotoxicity in Rats. *Middle East J. Appl. Sci.* 2014, 4(4): 1100-1109.