Alacrimia revealing triple A syndrome:

a case report

Abstract :

Introduction :allgrove's syndrome is a rare hereditary disease associating alacrimia, achalasia and Addison's disease. Neurological signs are observed in a third of the cases. We report the observation of a 10-year-old child with congenital alacrimia in the context of Allgrove syndrome.

Patients and methods: We report the case of a 10-year-old patient with triple A syndrome,.

Results: The ophthalmological examination revealed a superficial punctate keratitis with an altered Schirmer's test. The somatic examination found a perioral melanoderma, with amyotrophy of the leg and hollow foot. The explorations performed showed an Addison's syndrome in both children associated with achalasia.

Discussion:Congenital alacrimia is the most frequently reported sign, it concerns the basic lacrimal secretion and often also the reflex secretion. Adrenocortical insufficiency is manifested during the first decade of life by severe hypoglycemic crises. Achalasia is revealed between 6 months and 15 years of age by vomiting and dysphagia.

Conclusion: In front of any alacrimia of the child or the young adult must evoke a syndrome of Allgrove. A careful search for adrenal insufficiency, achalasia and associated neurological signs is necessary and allows to watch out for complications that could put at risk the vital prognosis.

key words: alacrimia, triple A syndrome, pediatric population,

INTRODUCTION:

Allgrove syndrome or triple syndrome A is a rare hereditary multisystemic disease associating alacrimia, achalasia and adrenocortical insufficiency not responding to adreno corticotropic hormone. Neurological signs are observed in one third of cases. This polymalformative syndrome is transmitted in an autosomal recessive fashion [1] .

The most probable pathogenic hypothesis of Allgrove syndrome is the degeneration of cholinergic neurons of the autonomic nervous system.The therapeutic management is symptomatic.

The objective is to recall and describe the clinical presentation and to know how to evoke the syndrome in time in order to avoid the sometimes fatal complications

CLINICAL CASE :

We report the case of a 10 years old patient, the third of four siblings, from a consanguineous marriage, who consulted for congenital alacrimia. His antecedents were phonological delay, with the notion of intermittent dysphagia. His prenatal and perinatal history was without particularity. Her 2 month old brother died following vomiting (acute dehydration) with a notion of alacrimia.

The ophthalmological examination found a corrected visual acuity of 10/10 in both eyes, to the double eversion of the eyelids, we note absence of the palpebral part of the lacrimal gland bilaterally. The slit lamp examination showed conjunctival hyperemia, presence of superficial punctate keratitis(figure 1)

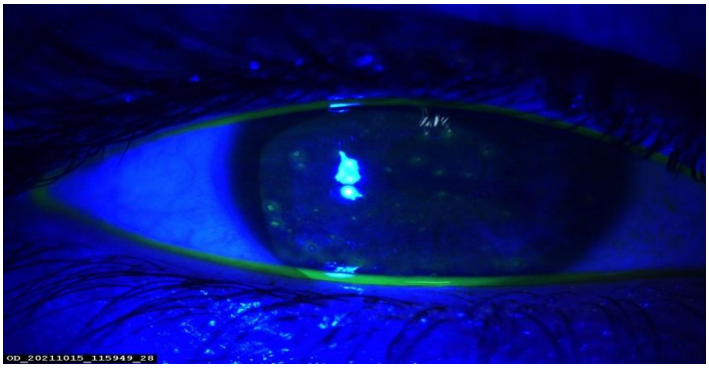

Figure 1 : superficial punctate keratitis

The Schirmer's test is altered; showed a wetting of 1mm and 2mm respectively in the right and left eyes(figure 2). the BUT for both eyes is 2 seconds. Fundus examination was normal in both eyes.

Figure 2:altered shirmer test, wetting of 1mm in the right eye and 2mm in the left eye

The clinical examination revealed a delay in staturo-weight (-3DS), melanoderma especially in the perioral region(figure 3), with amyotrophy of the leg ,hands and hollow foot(figure 4).

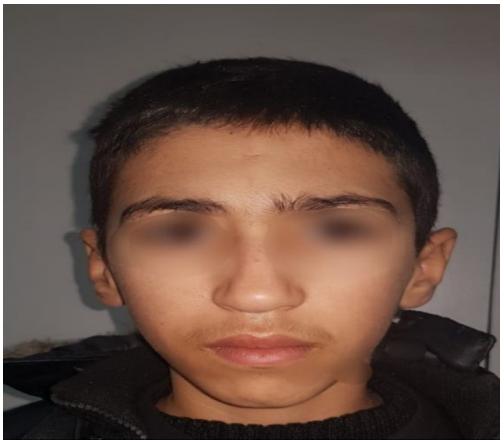

Figure 3: Perioral melanoderma **Figures 4** : amyotrophy of the lower extremities

A biological check-up was requested revealing an iron-deficient microcytic hypochromic anemia, a collapsed 8H cortisol level, an elevated ACTH level. Adrenal CT scan showed bilateral adrenal atrophy.

In view of the presence of alacrimia as shown by the Schirmer's test as well as the presence of dysphagia and adrenal insufficiency in the biological work-up, the diagnosis of triple A syndrome was retained.

A genetic study was made, revealing a mutation, type substitution of the gene AAAS on the chromosome 12.

The patient was hospitalized in the pediatric ward for further treatment; a barium esophagastroduodenal transit(figure 5) showed a bird's beak aspect of the esophageal junction, and esophageal manometry revealed an aperistalsis of the body of the esophagus.

The esogastroduodenal fibroscopy showed a narrowing of the lower esophagus, which was easily crossed without reflux or signs of esophagitis**.**

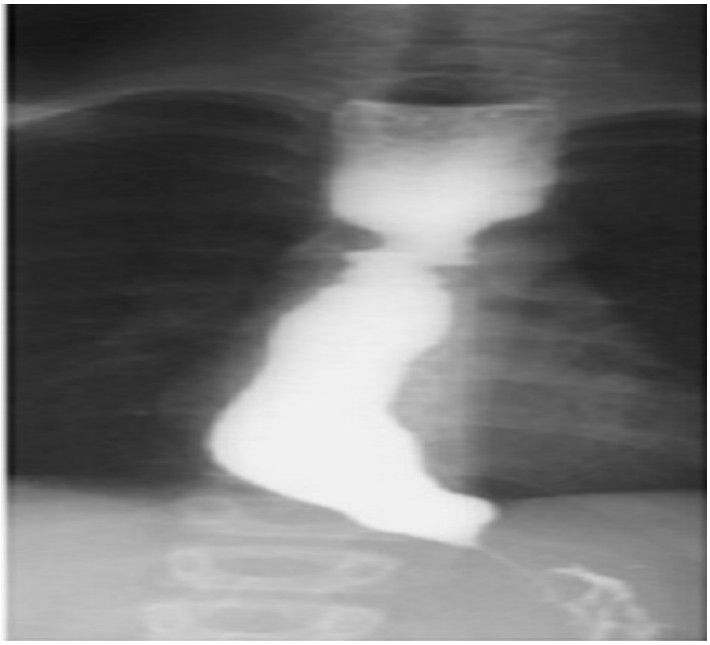

Figure 5: Esogastroduodenal transit with regular narrowing of the lower esophagus

The patient underwent endoscopic dilatation: Heller cardiomyotomy with simple postoperative procedures. Frequent ocular lubrication with topical tear substitutes was administered three times a day. With a substitution treatment based on hydrocortisone in one morning dose or in two doses, associated with fludrocortisone.

Discussion :

Allgrove syndrome is a rare condition whose prevalence may be underestimated. It should be considered in any patient presenting with any of the triad of abnormalities.

Alacrimia is the first and most consistent sign of this syndrome [2] Other features, such as cardiac achalasia or insensitivity to ACTH may present over a variable period of time [3].

Triple A syndrome is the consequence of a genetic mutation (substitution, deletion, inversion....) of the AAAS gene (Achalasia - Addisonianism - Alacrimia Syndrome). This AAAS gene codes for a protein, the exact role of this protein in Triple A syndrome is not yet known. However, researchers believe that it may have a regulatory role on the receptors of the hormone produced by the adrenal glands, cortisol, and a degenerative role on the nervous system [4].

The main ophthalmological manifestations in triple A syndrome include alacrimia with atrophy of the lacrimal glands and absence of lacrimation, keratoconjunctivitis, pupillary abnormalities including slow pupillary movement, accommodation disorders, amblyopia [5].

The processes of accommodation, miosis and lacrimation (basal and reflex) are under parasympathetic and cholinergic control, which explains why the disorders observed in patients with triple A syndrome are the result of a dysfunction of the autonomic system probably related to central involvement[6].

Other symptoms may be present; microcephaly related to the recurrence of hypoglycemic crises, mental retardation, hyperpigmentation, hyperkeratosis, cracking of the palms of the hands and soles of the feet.

Respiratory manifestations are present in 40% of adults with achalasia and adults with achalasia and in about 46% of children[7]. Respiratory clinical signs are non-specific; chronic cough, severe asthma that is difficult to control, recurrent bronchitis or pneumonia [8-9].

The treatment of Allgrove syndrome is symptomatic, based on substitution by artificial tears in case of alacrimia, by glucocorticoids associated with fludrocortisone in case of mineralocorticoid insufficiency. Achalasia is treated by esophageal dilatation or Heller cardiomyotomy

CONCLUSION

Triple A syndrome is a neuroendocrine disease with a significant diagnostic erraticity. A great heterogeneity of clinical pictures intervenes, making the approach difficult within this disease. In front of any alacrimia of the child or the young adult must evoke a syndrome of Allgrove. A careful research of an adrenal insufficiency of achalasia and associated neurological signs is essential and makes it possible to look out for complications being able to put at stake the vital prognosis.

Authors' contributions

This work was carried out in collaboration Between both authors. Both authors read and approved the final manuscript

COMPETING INTERESTS

Authors have declared that no competing interests exist

CONSENT

As per international standard or university standard, patient(s) written consent has been collected and preserved by the author(s)

ETHICAL APPROVAL

As per international standard or university standard written ethical approval has been collected and preserved by the author(s

REFERENCES

[1] : Clinical and genetic characterization of a Chinese patient with triple A syndrome and novel compound heterozygous mutations in the AAAS gene. Yang H, Zhang H, Lu L, Wang O, Xing X, Zhang M, Lu Z. J Pediatr Endocrinol Metab. 2013;26(3-4):389-91.

[2] : Moore PS, Couch RM, Perry YS, Shuckett EP, Winter JS. Syndrome d'Allgrove: Un syndrome autosomique récessif d'insensibilité à l'ACTH, d'achalasie et d'alacrime Clin Endocrinol (Oxf). 1991;34:107–14

[3] : Pedreira CC, Zacharin MR. Syndrome d'Allgrove : lorsqu'un trouble pédiatrique reconnaissable survient à l'âge adulte MJA. 2004;180:74–5

[4] : Djemai M, Abada-Bendib M, Masmoudi AN, Azzôug , Chentli M. Syndrome d'Allgrove : revue de 3 familles. *Revue Neurologique.* avril 2007 ; 163 (4):112.

[5] : Mullaney P, et al. Kératoconjonctivite sèche associée à une achalasie du cardia, une insuffisance corticosurrénalienne et une dégénérescence des glandes lacrymales : la kératoconjonctivite sèche secondaire à une dégénérescence des glandes lacrymales peut être parallèle à des modifications dégénératives de la fonction œsophagienne et corticosurrénalienne. *Ophtalmologie.* 1998 ; 105 (4):643–50.

[6] Kimber J, McLean BN, Prevett M, Hammans SR. Syndrome d'Allgrove ou 4 « A » : un syndrome autosomique récessif provoquant une maladie neurologique multisystémique. *J Neurol Neurosurg Psychiatrie.* 2003 mai ; 74 (5):654–7.

[7] Sinan H, Tatum RP, Soares VR, et al. Prevalence of respiratory symptoms in patients with achalasia. Dis Esophagus 2011;24: 224–8.

[8] Mehdi NF, Weinberger M, Abu-Hasan MN. Achalasia: unusual cause of chronic cough in children. Cough 2008;4:6.

[9] Azizkhan RG, Tapper D, Eraklis A. Achalasia in childhood: a 20- year experience. J Pediatr Surg 1980;15:452–6.