

## Case study

### **A rare bisalbuminemia etiology: Cholestatic hepatitis case report**

#### **Abstract**

Bisalbuminemias consist in a qualitative modification of the albumin pattern aspects, characterized by a duplication of the albumin fraction on the electrophoretic trace of the serum proteins. The prevalence of bisalbuminemia is about 0,03 to 1/1000. They can be inherited or acquired. We report a case of bisalbuminemia admitted at the hepato-gastroenterology Department of HMIMV RABAT.

This is 52 years old patient, operated for cerebral glioblastoma treated by radio-chemotherapy who consist in Temozolomide, presented cholestatic jaundice two weeks after oral chemotherapy. Electrophoresis serum protein use a capillary electrophoresis system (Capillaries, Sebia) reveals a hypoproteinemia and duplication of the albumin fraction.

Bisalbuminemias is a qualitative abnormality of the albumin pattern, diagnosed by electrophoretic trace of the serum proteins. It can be inherited or acquired but globally without pathological effects. The acquired etiology are several whose cholestatic hepatitis induced by drug can be evoked pending a more thorough study.

Keywords: Bisalbuminemia, capillary electrophoresis, cholestatic hepatitis

#### **INTRODUCTION**

Bisalbuminemia corresponds to a qualitative modification of the albumin trace characterized by a split peak [1] during plasma protein electrophoresis (PPE); this definition is then based on the realization of an EPP which can be classic or capillary whose resolution is better allowing to increase the prevalence of this electrophoretic aspect. The prevalence is of the order of 0.03 to 1 per thousand. They can be acquired or inherited. [2] We report a case of bisalbuminemia collected in our gastroenterology department of the military instruction hospital Mohammed V RABAT.

## OBSERVATION

### Patient Information:

This is a 52-year-old patient, operated for cerebral glioblastoma under radio-chemotherapy based on Temozolomide without any notion of hepatopathy, neoplasia, or taking beta-lactams, presenting with cholestatic jaundice beginning two weeks after taking Temozolomide.

### Physical examination:

The clinical examination found cutaneous and mucosal jaundice with memory and memory disorders falling within the framework of the post-operative consequences of surgery for his tumor.

### Biological data:

Biological examinations showed icteric cholestasis (alkaline phosphatase:  $60 \times N$ , gamma-GT:  $86 \times N$ , total bilirubin: 289 mg/L, direct bilirubin 221 mg/L), hepatic cytolysis (ALT:  $25 \times N$ , AST:  $11 \times N$ ).

CRP was 4.2 mg/L. Renal function and ionogram were normal, serum protein at 52 g/L (64–83), serum albumin at 31 g/L (no: 30–45) and prothrombin level at 82%. The blood count was normal. Lipasemia was normal.

The hepatotropic and non-hepatotropic viral serologies were negative, the autoimmune assessment (antinuclear auto-antibodies, anti-mitochondria, anti-smooth muscle and anti-liver antibodies) was normal. (Table 1). Abdominal ultrasound was normal.

Serum protein electrophoresis (EPP) performed by capillary electrophoresis (Capillarys, Sebia) reveals a proteinemia at 47g/L (64-83 g/L) and a doubling of the albumin fraction (Figure 1).

## Discussion

Bisalbuminemia corresponds to a qualitative modification of the albumin trace characterized by a split peak[1] during plasma protein electrophoresis (PPE); this definition is then based on the realization of an (EPP) which can be classic or capillary. [2]

The prevalence is of the order of 0.03 to 1 per thousand. They can be acquired or inherited. [2]

Serum protein electrophoresis is a technique that separates serum proteins according to their electrophoretic mobility into six migration zones: albumin, alpha-1 globulins, alpha-2 globulins, beta-1 globulins, beta-2 globulins, gamma

globulins under standardized conditions of ionic strength, pH, duration and intensity of the applied current. [2]

It should be noted that bisalbuminemia is more frequently encountered with the development of capillary electrophoresis, because this technique offers better resolution. [2]

Bisalbuminemia is revealed by a doubling of the albumin peak showing a qualitative anomaly which has no pathological repercussions. However, it can lead to a modification of the bioavailability of certain drugs or a different affinity to certain hormones, [3] metal ions, fatty acids which therefore see their concentration increased in the blood [4]. Hyperthyroidism in familial dysalbuminemia hyperthyroxinemia is one of these manifestations [5].

Bisalbuminemia can be acquired or hereditary. We speak of an acquired origin [2] when albumin is produced normally but structural modifications of part of the circulating albumin either by subtraction or by addition of material [4] lead to a modification of its electrophoretic characteristics.

There are three main acquired causes: Treatment with antibiotics with a  $\beta$ -lactam nucleus in renal failure or at high doses. In this case, the  $\beta$ -lactam rings attach themselves to the basic groups of proteins, which increases the attraction albumin on electrophoresis. The peak generally appears between the third and eighth day of antibiotic therapy and disappears within a few days to a few weeks after stopping treatment [4].

In particular, our patient was not taking  $\beta$ -lactam.

The presence of a pancreatic-peritoneal fistula, causing limited proteolysis of albumin by pancreatic enzymes, chymotrypsin and carboxypeptidases A and B. As a result, the fractions having been proteolyzed and those not proteolyzed of albumin produce two distinct narrow peaks [6]. In our patient, the lipasemia was normal, which excludes a possible pancreatitis.

During myeloma, the presence of a monoclonal immunoglobulin, especially of the IG A type, which binds to part of the circulating albumin and leads to a modification of its migration into electrophoresis [4].

Some authors report cases of bisalbuminemia in the course of certain pathologies such as Alzheimer's disease and during nephrotic syndrome with a pathophysiology that remains unknown. [4]

Analytical interference with alpha-fetoprotein in very high concentration due to their electrophoretic migration very close to the albumin zone is possible [7] but in this case it is rather an analytical error than a real one. bisalbuminemia.

No cases of bisalbuminemia acquired while taking temozolomide have been reported in the literature.

The diagnosis of genetic bisalbuminemia is first made by confirmation of the electrophoretic appearance superimposable on later tracings (permanent character)

and a family survey aimed at diagnosing this anomaly in several members of the same family [8].

Hereditary bisalbuminemia is due to an autosomal dominant monofactorial mutation of the albumin gene [4,9] with 125 variants identified to date, resulting in electrophoresis by two peaks of comparable concentration [3]. Gene sequencing may be requested for diagnostic confirmation and in the context of epidemiological and anthropological studies. [2]

Our patient had a previous plasma protein electrophoresis which is completely normal, thus eliminating a hereditary origin.

Thus, in front of this table, we can attribute this acquired bisalbuminemia to cholestatic hepatitis of drug origin. No similar case was reported in our bibliographic research.

## Conclusion

Bisalbuminemia is a qualitative anomaly of albumin detected during electrophoresis of plasma proteins which can be acquired or hereditary, generally without pathological repercussions. The latter have many etiologies including cholestatic hepatitis of drug origin can be evoked pending more in-depth studies.

## REFERENCES

1. Kelly TN, Gu D, Chen J, Huang JF, Chen JC, Duan X *et al.* Cigarette smoking and risk of stroke in the Chinese adult population. *Stroke*. 2008;39(6):1688-1693.
2. Fatima Zahra Hajoui, Asmaa Biaz, Lamyaa Zouiten, Samira Mechtani, Abdellah Dami, Sanaa Bouhsain, Zohra Ouzzif. Biochemistry service. A case of bisalbuminemia in a patient with digestive adenocarcinoma. A case of bisalbuminemia in a patient with digestive adenocarcinoma Mohamed V Military Instruction Hospital (HMIMV), Rabat, Morocco, Mohamed V Souissi University, Faculty of Medicine and Pharmacy Rabat, Morocco. *Ann Biol Clin* 2015;73(2):190-4.
3. Lefrèrea E, Dedomea C, Garcia-Hejla C, Ragota D, Chianeaa H, Delacourb S, Cremadesc P, Vesta. Bisalbuminemia: About a case Bisalbuminemia, A case report. 2018 French National Society of Internal Medicine (SNFMI). *REVMED*-5572
4. Bach-NgohouK, Schmitt S, Le Carrer D, Masson D, Denis M. Les dysalbumin mie. *Ann Biol Clin* 2005;63:127–34.
5. F El Boukhrissia, L Balouchb, K Mouddena, M Baaja, A. Hommadia, Y Bamoub. Bisalbuminemia occurring outside the usual situations. *REVMED*-5045 2015.

6. Avruskin TW, Juan CS, Weiss RE. Familial dysalbuminemic hyperthyroxinemia: A rare example of albumin polymorphism and its rapid molecular diagnosis JPediatr Endocrinol Metab 2002;15:801–7.

7. Desrame J, Delacour H, Bécbade D, Adem C, Raynaud JJ, Lecoules S, et al. Pancreatico-peritoneal fistula with bisalbuminemia. Med Press 2005;34:223–6.

8. Boujelbene A, Hellara I, Neffati F, Najjar MF. False bisalbuminemia and hyperalphafetoproteinemia. Gastroen Clin Biol 2010;34 636-8.

9. Chapuis Cellier C, Lombard C, Dimet I, Kolopp-Sarda MN. Serum protein electrophoresis in medical biology: interferences and confounding factors. RFL2018;499:47–58.

10. Rym Dabboubi, Yessine Amri, Chaima Sahli, Sondess Hadj Fredj, Leila Essaddam, Ala Zoghlami, Saida Ben Becher and Taieb Messaoud Inherited bisalbuminemia with growthhormone deficiency. <https://doi.org/10.1515/cclm-2018-1133>. Clin Chem Lab Med 2019.

**Table 1: Results of the patient's biological assessment.**

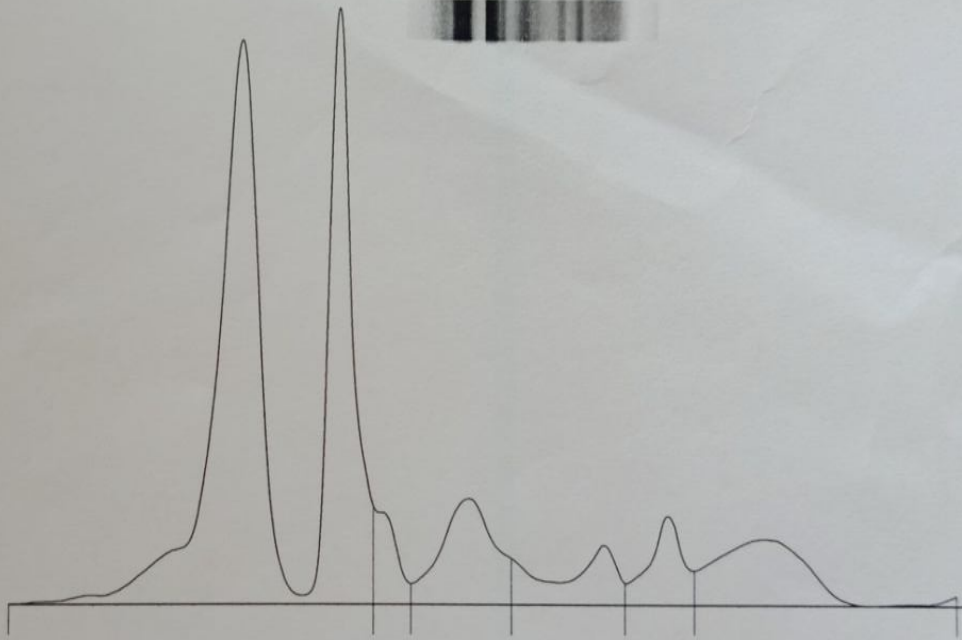
Examinations performed	Settings	Results
Hepatic check	AST (< 34 UI/L)	403
	ALT (< 40 UI/L)	1020
	PAL (32- 91U/L)	1131
	GGT (< 32 U/L)	2752
	Total bilirubin (3- 12 mg/L)	289
	Conjugated bilirubin (1- 5 mg/L)	221
Biochemistry	Sodium (135-145 mmol/L)	136
	potassium (3,7-5,3 mmol/L)	3,7
	Chloride ( 95-110 mmol/L)	98
	Calcium (90- 100 mg/L)	90
	Urea (0,15-38 g/L)	0,17
	Creatinine (6-13 mg/l)	7
	Albumin (30–45 g/L)	31
	Protidemia (64–83 g/L)	52
	Lipasemia (<160U/L)	25
Inflammatory assessment	CRP (1-7 mg/L)	4,2
	Ferritin (11-336 ng /mL)	50
CBC	Hemoglobin (12-16 g/dL)	13
	MCV (82-98 FL)	94
	MCHC (32-36 %)	35,4

	Platelets (150-450 G/L)	160
	White blood cells (4-10 G/L)	7,3
Hemostasis	TP (70-100%)	82
Hepatitis A serology	AC anti HVA	Negative
Hepatitis B serology	Ac anti-HBc	Negative
	Ag HBs	Negative
Hepatitis C serology	Ac anti-VHC	Negative
HSV1	AC type IgM and IgG	Negative
HSV2	AC type IgM and IgG	Negative
CMV	AC type IgM and IgG	Negative
EBV	AC type IgM and IgG	Negative
Immunological assessment	Antinuclear autoantibodies	Negative
	Antiliver kidney microsome antibody	Negative
	Anti-mitochondria antibodies	Negative
	Anti-smooth muscle antibody	Negative

**Figure 1:** Electrophoretic profile of the patient showing bisalbuminemia.

# Electrophorèse des protéines sériques

Electrophorèse capillaire



PT : **47** g/L

A/G : **1,95**

Nom	%	Normales %	g/L	Normales g/L
Albumine	<b>66,1</b>	55,8 - 66,1	<b>31,1</b>	40,2 - 47,6
Alpha 1	<b>3,4</b>	2,9 - 4,9	<b>1,6</b>	2,1 - 3,5
Alpha 2	<b>9,6</b>	7,1 - 11,8	<b>4,5</b>	5,1 - 8,5
Beta 1	<b>5,6</b>	4,7 - 7,2	<b>2,6</b>	3,4 - 5,2
Beta 2	<b>5,0</b>	3,2 - 6,5	<b>2,4</b>	2,3 - 4,7
Gamma	<b>10,3</b> <	11,1 - 18,8	<b>4,8</b>	8,0 - 13,5