

SEQUENCING & PHYLOGENETIC STUDY OF BOVINE PAPILLOMA VIRUS

ABSTRACT

The involvement of different genotypes of BPV was reported from different parts of the world. In this study a total of 5 BPV-1-positive PCR products were resequenced to determine the type of viral genome. The Delta papillomavirus sp. L1 generating genes showed the most similarity in a blast search (99.66 percent). Furthermore, multiple sequence alignment revealed 99% and 99.7% identity with Indian sequences KF055288.1 (IVRI, India) and HG918265.1 (IVRI, India) respectively. Phylogenetic analysis of partial sequences from the current study revealed that they are closely connected to MN977321.1 (Italy) and AB626705.1 (Japan), but are distantly related to KX907623.1 (China) and KY372394.1 (Turkey) sequences.

Keywords: BPV, Sequencing, cattle, histopathology, phylogeny

INTRODUCTION

Bovine papillomatosis has been identified in cattle (*Bos taurus*) in Europe, North America, Asia, and Oceania (Freitas *et al.*, 2004). In India bovine papilloma cases have been reported by a number of workers. The variety of BPV genotypes has been detected in cow herds and the primary types involved have been identified as BPV-1. In comparison to HPV genotype diversity the genotype diversity of BPV is significantly less documented. In the current study, 5 BPV-1 positive specimens (as determined by PCR) chosen as representative of BPV for geographical distribution were sequenced to confirm viral genome type. Using a BLAST search against non-redundant databases, these partial sequences revealed 147 (90.74%) reads as Delta papillomavirus. Using DNASTAR software, the current study's DNA sequences were compared with the published sequences available at the National Center for Biotechnology Information (NCBI, USA) (USA).

MATERIALS AND METHOD

All samples were collected as per standard sample collection procedure. This type of study does not require any ethical approval.

SAMPLING

For this study, twenty wart tissues were collected from cattle and buffalo of varying ages. The sample collection area includes villages in the Maharashtra districts of Satara and Pune. The samples were collected in sterile containers and transferred with ice packs to the laboratory, where they were maintained at - 20°C until further processing.

MOLECULAR DETECTION & SEQUENCING

The DNA purification kit was used to extract DNA from a wart tissue sample (head, shoulder, neck, and teat) from cattle of Pune and Satara district. The extracted DNA was used as a template. Amplification of extracted DNA was carried out by PCR targeting BPV-1 genes using published primers. For nucleotide sequencing, of BPV1 genotype total 5 purified PCR products from two different districts (Pune and Satara) were selected. Purified PCR products were sent for nucleotide sequencing. The obtained nucleotide sequences of BPV-1 genotype were subjected to BLAST analysis on the website of NCBI using BLAST tool (<http://www.ncbi.nlm.nih.gov/>). Amino acid sequences were constructed from obtained nucleotide sequence of BPV-1 genotype using protein analysis tool on the NCBI website. The obtained sequences were analyzed using DNASTAR (Lasergene, USA) software. Multiple sequence alignment of the sequences was carried out using Clustal W method in MegAlign (DNASTAR). Sequence obtained from Satara and Pune were subjected to establish their phylogenetic relationship with other sequences from NCBI data bank. Phylogenetic tree of the sequences was constructed in DNASTAR using neighbor-joining model and 1000 trials in bootstrap analysis.

Histopathology:

BPV suspected wart tissue were collected in 10 % formalin solution for histopathological examination. Paraffin embedding method was carried out as per method described by Chauhan, (1995). The staining procedure was carried out using routine Haematoxyline (H) and Eosin (E) method of staining. Stained slides with tissue sections were observed under the microscope for specific histopathological changes in wart tissues.

RESULTS AND DISCUSSION

BPV1 genotype sequencing

In the present study, a total of 5 BPV-1 positive specimens (as determined by PCR) which were selected as representative of BPV for geographical distribution, were sequenced to confirm viral genome type. The DNA sequences (250-297bp) of five samples were obtained after trimming the low-quality reads and removal of the overlapping sequence. These partial sequences were analyzed using a BLAST search against non-redundant databases, revealing 147 (90.74%), reads as Delta papillomavirus, (Fig.No.1). Sequence analysis was done by comparing DNA sequences of current study with the published sequences available at National Center for Biotechnology Information (NCBI, USA) using DNASTAR software (USA). Blast search showed the highest similarity (99.66 %) with the Delta papillomavirus spp. L1 encoding genes (Fig.No.2 and 3).

Multiple sequence alignment revealed 99% and 99.7% identity between all the sequences obtained in the current study and the submitted Indian sequences KF055288.1 (IVRI, India) and HG918265.1 (IVRI, India). Additionally, the sequences identity with KY372394.1 (Turkey), AB626705.1 (Japan), KX907623.1 (China), and MN977321.1 (Italy) are 95.5%, 99.3%, 99.3%, and 99.7%, respectively. Therefore, it may be said that, when compared to known sequences, the sequences obtained in the current study exhibit maximum sequence identity & minor sequence variation. Hamad et al. (2016) also reported 97 percent identity, confirming the presence of BPV-1. The result of the present study was in agreement with the earlier findings regarding BPV-1 as predominant genotype. Similar findings were reported by Timukaran *et al.*, (2017). They also reported high percentage sequence identity to the nucleotide sequence of BPV-1. Penget *et al.*, (2019) performed full-length genomic sequencing of all four isolated strains (JX180408, LA150909, HX160815, and BS160810) and all these four isolates were classified as BPV-1 and clustered into the Delta papillomavirus genera & belong to subtypes A. Shanshol and Ahmed (2021) indicated a greater prevalence (97%) of BPV-1 infection, this finding was consistent with previous national or worldwide investigations. The findings of this study are important from epidemiological point of view. Thus, it is essential to characterize genetically all the BPV occurring of different agro-climatic zones of India for effective diagnosis and control measures.

Phylogenetic study

Phylogenetic tree of the sequences was carried out using neighbor-joining model and 1000 trials in bootstrap analysis. Phylogenetic analysis revealed that BPV-2L1 sequences (SH1, 2, 3 and 5) of Maharashtra origin formed one cluster with minimum of 88.4% bootstrap support. SH4 sequence of current study falls in separate branch. Further the nucleotide sequences KF055288.1 (IVRI, India), HG918265.1 (IVRI, India), KY372394.1 (Turkey), AB626705.1 (Japan), KX907623.1 (China) and MN977321.1 (Italy) formed separate clad/ cluster. These two clusters (cluster of SH1, 2, 3 & 5 and cluster of remaining sequences) were separate and this relationship had 50.8% bootstrap support. Phylogenetic study of partial sequences of current study revealed close lineage with MN977321.1 (Italy) and AB626705.1 (Japan) whereas they are distantly related KX907623.1 (China) and KY372394.1 (Turkey) sequences, respectively (Fig. No.3). Similar findings were reported earlier by Timukaran *et al.* (2017). They reported the presence of BPV-1, with a 97% sequence identity to the BPV-1 sequences.

Histopathological Examination

Ten wart tissues were examined histopathologically. Six cases of papillomas and four cases of fibropapillomas were identified microscopically. Parakeratotic hyperkeratosis, Koilocytes, and squamous epithelial cell growth in papillomas (acanthosis) were noted. Another notable result was that the cytoplasm of koilocytes had an expanded, pale, vacuolated appearance. Squamous epithelial hyperplasia (acanthosis with papillary projections), multifocal to different hyperkeratosis, and proliferation of fibrous connective tissue in the dermis. The fibrous connective tissue proliferation was present in multiple directions interspersed with blood vessels and aggregates of lymphocytes and plasma cells. These cutaneous wart prevalence and pathology findings are generally in line with Tan et al. (2012). They reported similar histopathological changes such hyperkeratosis, irregular rete ridge formation, vacuolated cytoplasm, variable degrees of ballooning degeneration (koilocytes). In contrast to the findings of present research work Pangtyet. (2010) reported exophytic and cauliflower-like fibropapilloma in 13 biopsies & exophytic and dome-shaped fibropapilloma in 5 biopsies, occult and fibroblastic type papilloma 3 biopsies, cauliflower-like papilloma 3 biopsies, & endophytic fibropapilloma in 1 biopsy sample. The findings of this work was in agreement with Ozsoy et al. (2011) in their study they described the clinical, histopathological and immunohistochemical aspects of naturally occurring bovine cutaneous papillomatosis. A total of 82 Holstein cattle (9.5%), aged between 5 and 24 months, were diagnosed as cutaneous papilloma by clinical examination. The percentage of papilloma in male and female was 7.3% and 14.8% respectively. Histopathology of the wart tissue revealed various degrees of acanthosis and hyperkeratosis in all neoplasms (Fig.No.4). Histopathological findings of this research work are similar to those reported by Singh et. al, 2019, Yildirim et. al, 2022, Jangir and Somvanshi, 2021. They also reported fibropapilloma and papilloma with the characteristic pathological lesions such as hyperkeratinization, parakeratosis, keratohyalinization with koilocytes

CONCLUSIONS

The sequences from the current investigation had 99% and 99.7% identity with KF055288.1 (IVRI, India) and HG918265.1 (IVRI, India) sequences, respectively. Sequences of present investigation were 95.5 percent identical to KY372394.1 (Turkey), 99.3 percent identical to AB626705.1 (Japan), 99.3 percent identical to KX907623.1 (China), and 99.7 percent identical to MN977321.1 (Italy), BPV-1 L1 sequences from other nations. The partial sequences from the current study's phylogenetic analysis showed a close relationship with those from MN977321.1 (Italy) and AB626705.1 (Japan), although they are distantly linked to those from KX907623.1 (China) and KY372394.1 (Turkey). Using histological analysis of wart tissue, six cases of fibropapilloma and four cases of cutaneous papilloma

were observed.

Fig.1 Blast analysis of nucleotide sequence of BPV-1 field sample

Query Length 297

Other reports [Distance tree of results](#) [MSA viewer](#) ?

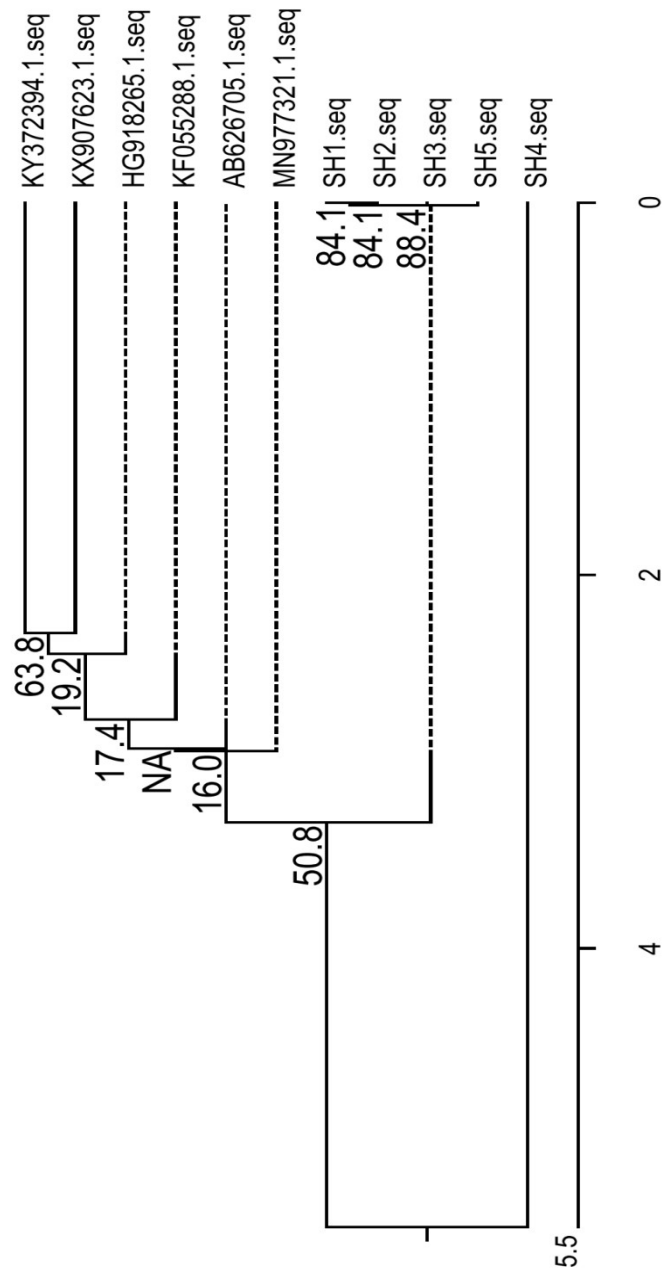
Descriptions		Graphic Summary		Alignments		Taxonomy	
Reports		Lineage		Organism		Taxonomy	
100 sequences selected ?							
Taxonomy		Number of hits		Number of Organisms		Description	
root		162		4			
. Papillomaviridae		161		3			
. . Deltapapillomavirus		147		2			
. . . Deltapapillomavirus sp.		5		1		Deltapapillomavirus sp. hits	
. . . Deltapapillomavirus 4		142		1		Deltapapillomavirus 4 hits	
. . Bovine papillomavirus		14		1		Bovine papillomavirus hits	
. unidentified cloning vector		1		1		unidentified cloning vector hits	

UNDER REVIEW

Fig. 2 Sequence identity and divergence of BPV-1 nucleotide sequenc

		Percent Identity												
		1	2	3	4	5	6	7	8	9	10	11		
Divergence	1	█	100.0	100.0	100.0	100.0	95.5	99.0	99.3	99.3	99.7	99.7	1	SH1.seq
	2	0.0	█	100.0	100.0	100.0	95.5	99.0	99.3	99.3	99.7	99.7	2	SH2.seq
	3	0.0	0.0	█	100.0	100.0	95.5	99.0	99.3	99.3	99.7	99.7	3	SH3.seq
	4	0.0	0.0	0.0	█	100.0	94.6	98.8	99.2	99.2	99.6	99.6	4	SH4.seq
	5	0.0	0.0	0.0	0.0	█	95.5	99.0	99.3	99.3	99.7	99.7	5	SH5.seq
	6	4.7	4.7	4.7	5.6	4.7	█	95.1	95.5	95.8	95.8	95.8	6	KY372394.1.seq
	7	1.0	1.0	1.0	1.2	1.0	5.1	█	99.0	99.0	99.3	99.3	7	KF055288.1.seq
	8	0.7	0.7	0.7	0.8	0.7	4.7	1.0	█	99.3	99.7	99.7	8	AB626705.1.seq
	9	0.7	0.7	0.7	0.8	0.7	4.3	1.0	0.7	█	99.7	99.7	9	KX907623.1.seq
	10	0.3	0.3	0.3	0.4	0.3	4.3	0.7	0.3	0.3	█	100.0	10	MN977321.1.seq
	11	0.3	0.3	0.3	0.4	0.3	4.3	0.7	0.3	0.3	0.0	█	11	HG918265.1.seq
	1	2	3	4	5	6	7	8	9	10	11			

UNDER PEER REVIEW



Nucleotide Substitutions (x100)
 Bootstrap Trials = 1000, seed = 111

Fig.3 Phylogenetic tree of BPV-1 nucleotide sequences

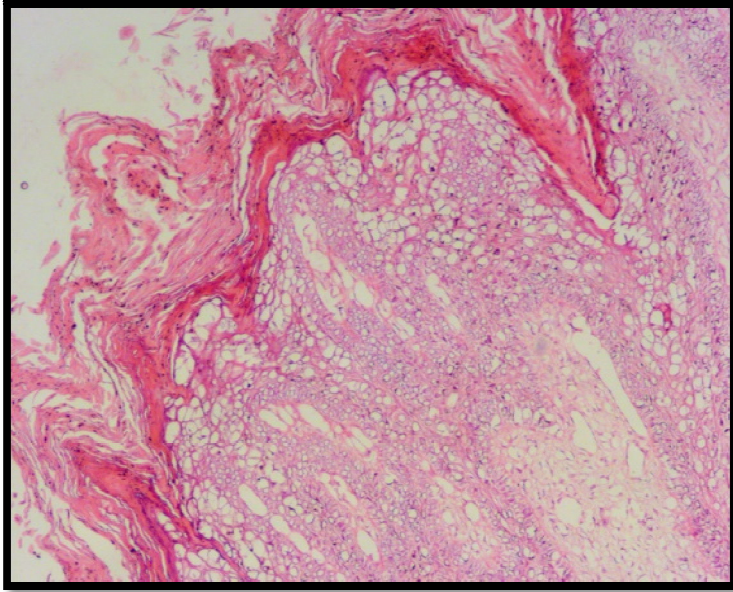


Fig.4 Severe acanthosis with parakeratotic hyperkeratosis, hydropic degeneration and vacuolation in squamous epithelium cells and papillary projection of dermis.

REFERENCES

- Chauhan H.V.S., (1995) *Veterinary Clinical and laboratory Diagnosis*. 3rd Edn, Jaypee Publishers, New Delhi.
- Freitas A. C. de., C. De. Carvalho, O. Brunner , Jr. E. H. Birgel , A. M .M.P. Dellalibera, F. J. Benesi, L. Gregory, W. Becak and R. De. C. S. dos Santos (2003) Viral DNA Sequences in Peripheral Blood and Vertical Transmission of the Virus a Discussion about BPV-1. *Brazilian J. of Micro.*, **34** (1) : 76-78
- Hamad, M. A., A. M. Al-Shammari, S. M. Odisho, and N. Y. Yaseen, (2016) Molecular and Phylogenetic analysis of Bovine Papillomavirus type 1: first report in Iraqi cattle, *Adv, Virology*, Vol. 2016, 1-7
- Ozsoy S. Y., Ozyildiz and M. Guzel (2011) Clinical, Pathological and Immuno histochemical Findings of Bovine Cutaneous Papillomatosis. *Ankara Univ, Vet. Fakderg.*, 58: 161-165.
- Timurkan, M. O., M. E. Alcigir (2017) Phylogenetic Analysis of a Partial L1 gene from Bovine Papillomavirus type 1 Isolated from naturally occurring Papilloma Cases in the Northwestern Region of Turkey. *J. Vet Res* 84: 1450.
- Jangir, Babu L., and Ramesh Somvanshi (2021). Pathological studies and detection of co-infection of bovine papilloma viruses in cattle cutaneous and teat warts. *Veterinarski arhiv* 91(6): 589-602.
- Pangty K., S. Singh, R. Goswami, G. Saikumar and R. Somvanshi (2010) Detection of BPV-1 and BPV-2 and Quantification of BPV-1 By Real-Time PCR in Cutaneous Warts in Cattle and Buffaloes. *Transbound Emerg. Dis.*, **57** (3): 185-196.
- Peng H., C. Wu, J. Li, C. Li, Z. Chen, Z. Pei and S. Feng (2019) Detection and Genomic Characterization of Bovine Papillomavirus Isolated from Chinese Native Cattle. *Transboundary and Emerging Diseases*, 66 (6): 2197-2203.
- Singh P, Jana C., Khulape Sagar A., Gautam S., Ramakrishnan M.A. (2019) Pathological investigation and molecular characterization of bovine papilloma virus-1 detected in cutaneous warts of cattle *Indian Journal of Vet. Path.*, 43 (2) 89-93

Shanshol, R. H. and J. A. Ahmed(2021). Pathological and Molecular study of BovinePapillomavirus BPV in Basrah Province/Iraq. Annals of R.S.C.B (25):11902-11917.

Yıldırım, Yakup, Mehmet Kale, ÖzlemÖzmen, Abdurrahman Anıl Çağırğan, SibelHasırcıoğlu, Ali Küçük, AyşegülUsta, and SevinçSökel(2022). "Phylogenetic analysis and searching bovine papillomaviruses in teat papillomatosis cases in cattle by performing histopathology, immunohistochemistry, and transmission electron microscopy." Microbial Pathogenesis 170: 105713.

UNDER PEER REVIEW