

## Original Research Article

# ASSESSMENT OF GINGIVAL ZENITH POSITION AND DISTANCE FROM VERTICAL BISECTING MIDLINE IN RIGHT AND LEFT MAXILLARY CENTRAL INCISORS

### ABSTRACT:

**Aims:** To assess the gingival zenith position and its distance from vertical bisecting midline in the maxillary right and left central incisors in Marathwada region.

**Material and method:** 60 participants were selected (34 male and 26 female), considering inclusion and exclusion criteria. 120 teeth were evaluated on diagnostic cast, gingival zenith position (GZP) and vertical bisecting midline (VBM) marked on each tooth. By using magnification loupes and digital vernier calipers, the distance between GZP and VBM was measured three times and average value was recorded. The GZP was recorded as mesial, distal or coinciding with VBM.

**Results:** Majority of right and left maxillary central incisors shows distal placement of GZP to the VBM and its mean distance from VBM was 0.87 mm. After statistical analysis, it was found that the *P* value for right and left central incisors was greater than 0.01, which was not statistically significant.

**Conclusion:** GZP is positioned 0.87mm from VBM and it is important in designing macroesthetics and microesthetics of teeth.

**Clinical significance:** These parameters are important during treatment planning of restoration in maxillary central incisors. Deviation from these parameter lead to unappealing and anaesthetic appearance.

**KEYWORDS:** *Gingival zenith position, Esthetic, Vertical bisecting line, Dental aesthetics, Maxilla.*

### INTRODUCTION:

Peace begins with the smile. Beautiful smile gives pleasure to the mind. It attracts positivity. Beautiful smile is created by considering some specific proportion of face, gingiva and teeth height, width and its symmetry. In that case, dentists are the ones who create a beautiful smile and make a person beautiful and happy [1]. Face is very important for every person and is considered as his social identity. And currently everyone gives prime importance to make it beautiful by adding beautiful smile.

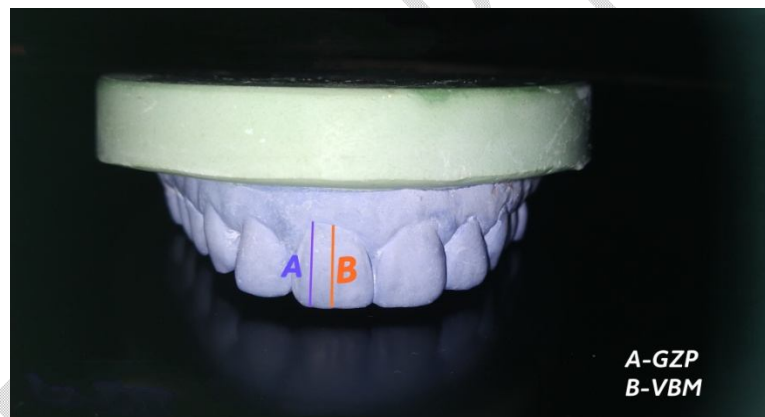
An esthetic smile is depends on white and pink esthetics .Teeth are considered under white and gingiva is under pink esthetics [1]. Gingival tissues surrounding the teeth play an important role in exhibiting a beautiful smile. And it should be considered in orthodontic, periodontal, restorative, and implant treatment planning [2]. The gingival health is considered as an important factor during treatment planning [2, 3].

Healthy gingiva is characterized by a knife- edged gingival margin, which is firmly attached to the tooth surface; cone shaped or pointed interdental papilla and presence of stippling on the gingiva [4]. Disruption of healthy gingival structure due to any reason leads to unpleasing smile [4]. Thus, every clinician should know the factors contributing the beautiful smile.

Gingival zenith position (GZP) is one of the factor considered during esthetic procedure. Gingival zenith (GZ) is the most apical aspect of free gingival margin [2]. The gingival zenith position is located from vertical bisecting midline (VBM) drawn through each maxillary anterior tooth. Gingival zenith position (GZP) is considered during orthodontic corrections, implant procedures, restorative procedures, and periodontal procedures. For diastema closure, consideration of gingival zenith position is very important to change the mesial-distal dimension of tooth [5]. GZP also help in correction of tooth angulations [6].

Aim of the present study was to assess the gingival zenith position and its distance from vertical bisecting midline in the maxillary right and left central incisors in Marathwada region.

**Figure 1**  
position and its  
vertical



gingival zenith  
distance from  
bisecting midline

#### **MATERIAL AND METHOD:**

This study was conducted in a private dental clinic in Aurangabad district. In this cross-sectional study, 60 healthy participants (34 males and 24 females) were randomly selected of the age group 18 – 25 years and informed consent was obtained from every participants. The inclusion criteria for this study was the participants who are willing to participates, periodontally healthy subjects were included. The exclusion criteria were restored maxillary anterior teeth, anterior crowding and spacing, history of orthodontic correction, incisal attrition, periodontal diseases like gingival recession, loss of interdental papilla, gingival overgrowth. The armamentarium used, alginate impression material and metal impression stock trays, magnification loupes, digital vernier calipers.

Alginate impression of maxillary arch were made and poured with stone and a diagnostic cast was obtained. On each cast vertically bisecting midline[VBM] and gingival zenith point [GZP] was marked. The

vertical bisecting midline [VBM] was marked by measuring tooth width at two reference points that is proximal incisal contact area position and the apical contact area position. The centre points were marked by dividing calculated mesiodistal width by half. These center points were joined by line extending from incisal aspect to gingival aspect of clinical crown. The highest point on the free gingival margin that is Gingival Zenith was marked and line extending through it was drawn. The gingival zenith position was evaluated and its medio-lateral distance from vertical bisecting midline was calculated for right and left central incisors. The measurements were recorded using digital vernier caliper. The measurements were recorded three times for each tooth and average value was recorded. All the data obtained was tabulated and statistical analysis was done.

## RESULT:

In the present study 60 subjects were randomly selected from patients coming to private dental clinic in aurangabad. Out of them 34 were male and 26 were female between the age group of 18 – 25. Total 120 maxillary central incisors were evaluated on the diagnostic cast.

Table 1 shows the position of GZP as mesial, distal or coinciding to VBM of total participants. The analysis by using vernier caliper and magnification loupe showed out of total 76.6% of right maxillary central incisors displayed GZP distal to the VBM, 20% displayed GZP mesial to VBM and 3.3% coinciding with VBM. Similarly, 73.3% of left maxillary central incisors displayed GZP distal to VBM, 23.3% mesial to VBM and 3.3% coinciding with VBM. So overall in the present study it was noticed that the central incisors predominantly showed the distal placement of GZP to the VBM.

Table 2 and 3 showed in case of male (34 males) 76.4% of right maxillary central incisors displayed GZP distal to VBM, 20.5% mesial to VBM and 2.9% coinciding with VBM. Similarly in left maxillary central incisors 73.5% displayed GZP distal to VBM, 23.5% mesial to VBM and 2.9% coinciding with VBM. And in case of female (26 females) for right maxillary central incisors 80.7% displayed GZP distal to VBM, 19.2% mesial to VBM and 3.8% coinciding with VBM. For left maxillary central incisors 73.07% GZP distal to VBM, 23.07% mesial to VBM and 3.8% was coinciding with VBM. By comparing it was noticed that in both gender the GZP predominantly present distal to VBM.

Table 4 shows the distance of GZP from VBM of clinical crown in maxillary central incisors. The mean distance of GZP from VBM if right and maxillary central incisors were 0.90 mm with standard deviation of 0.17 mm and for left maxillary central incisors were 0.84 mm with standard deviation of 0.17 mm.

In case of male the mean distance of GZP from VBM of right maxillary central incisors is 0.93 mm with standard deviation of 0.17 mm and for left maxillary central incisors it is 0.83 mm with standard deviation of 0.17 mm. And in case of female for right maxillary central incisors mean distance is 0.89 mm with standard deviation of 0.19 mm, for left maxillary central incisors it is 0.82 with standard deviation of 0.17 mm.

After the Statistical analysis, it was found that the *P* value for right and left central incisors was greater than 0.01, which was not statistically significant.

**TABLE 1 :The gingival zenith position in relation to the vertical bisecting midline in total subjects**

Tooth	n(Total)	Mesial	Distal	Coinciding
-------	----------	--------	--------	------------

		n	%	n	%	n	%
Right maxillary central incisor	60	12	20	46	76.6	2	3.3
Left maxillary central incisor	60	14	23.3	44	73.3	2	3.3

**Table 2 : The gingival zenith position in relation to the vertical bisecting midline in male**

Tooth	n(Total male)	Mesial		Distal		Coinciding	
		n	%	n	%	n	%
Right maxillary central incisor	34	7	20.5	26	76.4	1	2.9
Left maxillary central incisor	34	8	23.5	25	73.5	1	2.9

**Table 3: The gingival zenith position in relation to the vertical bisecting midline in female**

Tooth	n (Total female)	Mesial		Distal		Coinciding	
		n	%	n	%	n	%
Right maxillary central incisor	26	5	19.2	20	80.7	1	3.8
Left maxillary central incisor	26	6	23.07	19	73.07	1	3.8

**Table 4: The distance (mm) of the gingival zenith position from the vertical bisecting midline in total subjects**

Tooth	n(Total)	Mean distance (mm)	Standard deviation (mm)	Minimum (mm)	Maximum (mm)
Right maxillary central incisor	60	0.90 mm	0.17 mm	0 mm	1.08 mm
Left maxillary central incisor	60	0.84 mm	0.17 mm	0 mm	1 mm

## DISCUSSION:

Healthy gingiva is primary factor among the factors considered during esthetic treatment planning. And it is important to consider its morphology and contour [3, 7]. Gingival zenith position is an important factor in gingival morphology; [8], which lead to unpleasing smile and unhappy patient if not taken into consideration, while esthetic treatment planning. Gingival zenith position consideration is important in diastema closure, to determine the angulations of tooth and other esthetic procedures. [6, 7].

In the present study, 120 teeth were evaluated for deviation of GZP in maxillary central incisors. Mesial, distal deviation of GZP was seen. In addition, it is noticed that GZP and VBM was coinciding. However, the majority of the teeth show distal deviation of GZP to the VBM. This observation was similar to the result of Appukuttan et al. [4] study, which was conducted to access the GZP deviation from the VBM. Similar result obtained in the study of Aspalli S et al. [7], this result also comparable with the Goodlin R [9] study, in that also they observed the distal third placement of GZP for central incisors. In the study of Patil et al. [10], the GZP is not universally displaced towards the distal aspect. Opposite of that Magne and Belser U [3] reported universal distal deviation of GZP.

In this study, the average distance of GZP from VBM is 0.87 mm. This was similar to the results of study of Rufenachat CR. [11, 12], Zagar M et al. [13] Similar observation was also reported by shah et al. [14] in Indian population.

By comparing the GZP in male and female ,there is no significant difference found in right and left maxillary central incisors. Similar observation found in the study of Humagain M et al. [2] In the study of Abhay P et al. [15], they conclude distal deviation of GZP in central incisors more pronounced in female than in male.

GZP is important in treatment planning and rehabilitation of esthetic zone[4]. It determine the axial inclination of the tooth so it play important role while changing the mesial distal dimension of the tooth, diastema closure[7]. In the procedure of periodontal, orthodontic, restorative and implant GZP is important[2,15].

Limitation of the study was all anterior tooth should be taken into consideration and more subjects should be taken.

## CONCLUSION:

In the present study it was found that the distal deviation of GZP from VBM was predominant in maxillary central incisors. Mesial deviation was also found. Some incisors shows GZP was coinciding with VBM. It was also observed that the average distance of GZP from VBM was 0.87 mm. And there was no significant difference found in male and female regarding GZP and its distance VBM. We also highlights the importance of GZP in macroesthetics and microesthetics.

## COMPETING INTERESTS DISCLAIMER:

Authors have declared that they have no known competing financial interests OR non-financial interests OR personal relationships that could have appeared to influence the work reported in this paper.

## REFERENCES:

1. Pauer B, Mishra P, Banga P, Marawar PP. Gingival Zenith and its role in redefining esthetics: A clinical study. *J Indian Soc Periodontol* 2011; 15:135.
2. Humagain M, Rokaya D, Sri R, Dixit S, Kafle D. Gender based comparison of Gingival Zenith Esthetics. *Kathmandu Univ Med J* 2016; 54(2):148-52.
3. Magne P, Belser U. Bonded porcelain restoration in the anterior dentition. A biomimetic approach. *Carol Stream (IL): Quintessence*; 2002, pp. 58- 64.
4. Appukkuttan D, Cholan PK, Ashwin CR, Swapna S. Assessment of gingival zenith position and distance from vertical bisecting midline in the maxillary anterior dentition – An observational study. *J Orofac Sci* 2018; 10: 14-8.
5. Rothod Varsha J et al. 2017, Quantitative Evaluation of Deviation of gingival position in maxillary anterior Dentition. *Int J Recent Sci.* 8(4), pp. 16741 – 16744.
6. Bhuvaneshwaran M, Principles of smile design, *Journal of conservative Dentistry | Oct- Dec 2010, Vol 13, Issue 4:225-232.*
7. Aspalli S, Abraham S, Gaddale R, et al. Comparative evaluation of Gingival zenith Deviation from the Vertical Bisecting Midline and Apicocoronal Displacement of the Zenith of Lateral Incisor from Gingival Zenith Level: A cross-sectional study. *Int J Prosthodont Restor Dent* 2021; 119(2):88-92.
8. Singhal M, Singhal RA. CAD-CAM prosthodontic option and gingival zenith position for a rotated maxillary right central incisor: an evaluation. *Indian J Dent Res* 2012; 23(1):112-115. DOI: 10.4103/0970-9290.99053.
9. Goodlin R. Gingival aesthetics: a critical factor in smile design. *Oral Health and Dental practice* 2003; 93(4):1027 Charruel S, Perez C, Foti B. Parameters for gingival contour assessment. *J Periodontal* 2008; 79(5):7951801.
10. Patil AS, Ranganath V, Yerawadekar SA, et al. Pink esthetics; a study on significant gingival parameters. *J Contemp Dent Pract* 2020; 21(2):207-210. DOI: 10.5005/jp-journals-100124-2739.
11. Rufenacht CR. *Fundamentals of Esthetics*, Berlin: Quintessence; 2000.p.154
12. Rufenacht CR. *Fundamentals of Esthetic Integration*. Chicago, IL: Quintessence; 2000.p.154.
13. Zagar M, Knezovi ZD, Carek V. A quantitative evaluation of the distal displacement of the gingival zenith in the maxillary anterior teeth. *Coll Antropol* 2010; 34:225-8.
14. Shah D, Vaishnav K, Duseja S, Agrawal P. Relative position of gingival zenith in maxillary anterior teeth – A clinical appraisal. *Int J Health Biomed Res* 2014; 3:77-81.
15. Abhay P. Kolte, Rajashri A. Kolte, Charu Ahuja. Assessment of gingival zenith position and its level relative to age and gender in maxillary anterior teeth. *Quintessence Int* 2018; 49:761-768; doi: 10.3290/j.qi.a41009.

UNDER PEER REVIEW

UNDER PEER REVIEW