

Title : Lone atrial fibrillation during pregnancy in a young patient : about a case and literature review

Abstract :The period of pregnancy is a particular period during which several hormonal and physiological changes occur in the functioning of the pregnant woman causing many changes to the normal functioning of the body and especially the heart. with the appearance of arrhythmias and in particular AF which remains rare in pregnant women with a healthy heart. In this work we present a case of a 38-year-old woman, pregnant at 30 weeks who presents palpitations related to atrial fibrillation and the cardiological exploration objectified a healthy heart. The hemodynamic, hormonal and drug hypotheses are among the etiologies mentioned in this condition. During this paper, we have tried to review the different arguments posed in the literature and the means of suspicion and diagnosis.

Introduction

The period of pregnancy is a particular period during which several hormonal and physiological changes occur in the functioning of the pregnant woman causing many changes to the normal functioning of the body. The heart is not spared from these various changes which in some cases result in the occurrence of certain arrhythmias, in particular supraventricular arrhythmias. Generally, the occurrence of atrial fibrillation remains infrequent during pregnancy in young women. its occurrence may reflect either an exacerbation of an already present structural abnormality or an idiopathic one whose etiology remains undetermined even after careful investigation. The management of atrial fibrillation during pregnancy remains a priority and a diagnostic and therapeutic emergency, any delay of which can cause terrible consequences such as hemodynamic instability and heart failure.

We present a case of a young 38-year-old patient who presented with inaugural atrial fibrillation with a therapeutic challenge.

Case report

We report the case of Ms. K.B, a 38-year-old married woman and mother of 02 children, with no family history of ischemic or rhythmic heart disease who was admitted to the emergency department for treatment of palpitations. She is a patient followed for postpartum hypertension that occurred after her second pregnancy. She is not known to be diabetic or dyslipidemic. The patient had 5 pregnancies, 2 living children aged 5 and 3 years old , 2 abortions, and currently pregnant in 30 weeks of amenorrhea. She is on iron supplementation for the management of iron deficiency anemia that has been evolving for 07 months.

Her history goes back to 03 days before her admission by the occurrence of palpitations with the notion of atypical precordialgia without syncope or faintness motivating the patient to consulte in the emergency room. The examination on admission finds a patient well oriented in time and space supporting the supine position, still presenting the sensation of palpitations, discolored conjunctivae. her BP was 145/100 mmHg in both arms with a heart rate of 160 bpm. Her cardiovascular examination presented well perceived heart sounds with an irregular and rapid rhythm without other associated signs. her pleuropulmonary examination was normal. her gynecological examination was also normal.

Her ECG objectified tachycardia in atrial fibrillation with an average ventricular rate of 147 bpm without other repolarization disorders. Her assessment showed hypochromic microcytic anemia at 9d/dl, leukocytes at 5500/mm³, platelets at 176000/mm³, TP at 88%, K⁺ at 3.8 mmol/l, creatinine at 7mg/l, CRP at 8.7 mg/l .her hepatic, phosphocalcic, and lipid bloodwork were normal.

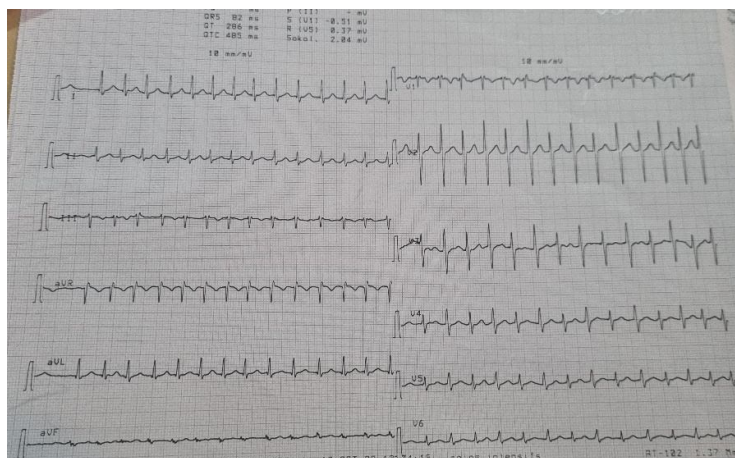


Figure 1 : Intensive care unit admission electrocardiogram

Transtoracic echocardiography showed a non-dilated, non-hypertrophied LV, with good global and segmental kinetics with an LVEF preserved at 63%. The RV is non-dilated with good systolic function, undilated atria, with Doppler : LV filling pressure were low and pulmonary systolic pressure at 33 mmhg.

The patient was initially put on anticoagulant treatment based on enoxaparine 0.7 cc2x/d, Bisoprolol 5 mg/d, and digoxin 0.25 mg 1 tab/d. the patient remained hemodynamically, respiratory and neurologically stable but without slowing down of the heart rate which, despite the treatment, remained around 140-150 bpm with a gradual drop in blood pressure. Given the patient's lack of improvement in terms of heart rate, with hemodynamic instability, the patient was shocked the day after her admission by an external electric shock initially at 50 joules then at 100 joules with resumption of a regular sinus rhythm after the 2nd shock under slight sedation without complication.

The post-ECV gynecological evaluation was normal with the presence of normal fetal activity and normal ultrasound as well. transtoracic echocardiography showed the same results observed before the external electric shock

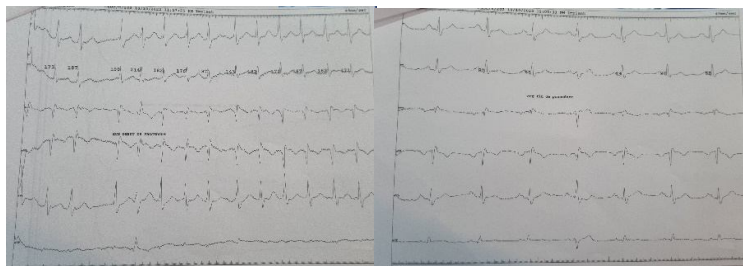


Figure 2 : electrocardiogram before and after external electric shock

The patient was put on curative anticoagulation 3 weeks after the shock with enoxaparin 0.7cc2/d and Bisoprolol 5mg /d with regular follow-up by the cardiologist and gynecologist.

Discussion

Atrial fibrillation remains the most frequent rhythm pathology. Its occurrence during pregnancy remains rare. If it occurs during pregnancy, AF generally occurs in patients with a prior heart condition. Isolated atrial fibrillation without associated cardiac pathology is rare. Indeed, the frequency of atrial fibrillation in pregnant women without associated cardiac pathology is of the order of 0.3% whereas it is of the order of 2.2% in the event of a prior cardiac condition with a risk of occurrence much higher in the 3rd trimester than in the 1st trimester.(1)

There is variability in terms of ethnicity with a clear predominance of the white race, which may presumed there is a genetic predisposition to the occurrence of FA during pregnancy.(2)

in pregnant patients with atrial fibrillation, the consequences can be serious. Atrial fibrillation is responsible for a rapid ventricular response with loss of atrial contraction which may be responsible for haemodynamic instability. Loss of atrial contraction responsible for 15-20% of ventricular filling and shortening of ventricular filling time due to rapid ventricular response may be responsible for maternal systemic hypoperfusion affecting fetal circulation in the interest of early detection of this arrhythmia(1)

Pregnancy is accompanied by a substantial decrease in peripheral vascular resistance due to vasodilation of the systemic vasculature.

Potential factors including direct effects of hormones on cardiac electrophysiology, autonomic tone, and hemodynamic perturbations, can provoke arrhythmias in pregnancy, labor, and delivery. A number of studies have demonstrated that AF, and in particular lone AF, have a substantial genetic component. Genome-wide association studies (GWAS) have indicated that common single-nucleotide polymorphisms (SNPs) have a role in the development of AF. Furthermore, rare variants in genes encoding cardiac gap junction proteins, signalling molecules, ion channels, and accessory subunits have been associated with lone AF in several recent genetic reports. Most of these reports show gain-of-function or loss-of-function mutations, leading to increased risk of lone AF.(3)

While most cases of atrial fibrillation in pregnancy are the result of an underlying cardiac arrhythmia or structural abnormality, there is a very small percentage of women who develop new-onset "lone" atrial fibrillation during their pregnancy.(4)

In evaluating new-onset "lone" atrial fibrillation in the pregnant woman, it is important to discern the etiology of the abnormality. The initial work-up should attempt to rule out cardiac conduction and structural abnormalities, as well as extracardiac etiologies such as pulmonary embolus, hyperthyroidism, electrolyte disturbances, and pharmacologic effects.(5)

This assessment should include an EKG, echocardiogram, serum electrolytes, thyroid studies, and urine drug screen. The EKG should reveal the diagnosis of atrial fibrillation as well as any other conduction abnormalities once the rate is controlled, and an echocardiogram will be able to evaluate any structural abnormalities that would predispose the patient to developing an arrhythmia.(5)

A thorough evaluation of medications as well as illicit drug use should be completed, as many pharmacologic agents are arrhythmogenic. If clinically indicated, an evaluation for pulmonary embolus should be completed using laboratory and radiologic evidence and therapy should be initiated(5) .All possible etiologies need exclusion for the diagnosis of lone AF.

Symptoms of palpitations, dizziness, and even syncope are an integral part of the symptoms that a pregnant woman may have during her pregnancy, however, these symptoms may be indicative of the pathology as in the case described by Murphy et al which the patient presented with palpitations on admission (6).

The management of isolated atrial fibrillation in pregnant women remains a therapeutic and managerial challenge. The management of the cardiovascular component and OBG must be concomitant and complementary. The initial supportive measures include left lateral position, 100% oxygen, and early intravenous access. Potential stimulants, such as smoking, caffeine, and alcohol should be eliminated. AF is mainly unprovoked, paroxysmal. Vagal nerve stimulation and Valsalva maneuvers are the first line treatments. (5)

In hemodynamically unstable patients, in patients who are not responding to pharmacologic therapy, or whenever the risk of ongoing atrial fibrillation is considered high for the mother or the fetus cardioversion up to 400 J can be performed safely at all stages of pregnancy and the consequent risk for foetal arrhythmias or preterm labour is low. The fetal heart rate should routinely be controlled after cardioversion. Cardioversion should generally be preceded by anticoagulation (7). In cases of atrial fibrillation occurring for longer than 48 hours, a transesophageal ECHO should be completed to evaluate atrial thrombus, and anticoagulation should be initiated prior to cardioversion (5)

ECV has been performed safely at all stages of pregnancy and is recommended whenever the risk of ongoing AF is considered high for the mother or the fetus. ECV could be performed in stable patients as well to avoid the potential adverse effects of drugs. The success rate of ECV in pregnant females is 93.2% after one or more attempts. (4) The factors affecting success of ECV include the type and length of the arrhythmia, cardioversion method, voltage, and type of energy. (4) Our patient was shocked by an external electric shock initially at 50 joules then at 100 joules with resumption of a regular sinus rhythm after the 2nd shock under slight sedation without complication

The introduction of anticoagulants depends on depending on the pregnancy trimester, such as low- and high-dose VKA use during the second and third trimesters, timing of low-molecular-weight heparin (LMWH) to unfractionated heparin (UFH) relative delivery. using LMWH at therapeutic doses in the first and last trimesters, and VKA with the usual INR targets or LMWH for the second trimester. Use of NOACs is prohibited during pregnancy. (7) warfarin should be avoided in women with and without surgical treatment of congenital heart because it crosses the placental barrier and is associated with the teratogenic embryopathy in the first trimester and fetal hemorrhage in the later stages of pregnancy. (8) **The American recommendations 2019 AHA/ACC/HRS and 2020 CCS/CHRS recommendation did not specify the type of anticoagulation used in pregnant women. (9)**

The initial goal should be to control the rate; however, in order to maintain consistent blood-flow to the patient's end organs including the placenta, sinus rhythm should be restored as soon as possible. (4)

Maternal*	Foetal
Arterial blood gases	Obstetric Ultrasound
12 lead electrocardiogram	Foetal Umbilical artery and Middle Cerebral artery doppler studies
Full blood count	Electronic foetal monitoring
C Reactive Protein	Serial Foetal Growth Scans
Renal function tests and Electrolytes	
Liver function tests	
Thyroid function tests	
Echocardiography	
High-sense Cardiac Troponin T	
Midstream Urine Analysis	
Chest X Ray	
Coagulation profile	

* Other investigations depend upon the maternal co-morbidities.
ECG = electrocardiogram.

MEDICINE

Figure : Investigations for maternal atrial fibrillation.(10)

Intravenous beta-blockers are recommended for acute rate control. Beta-1 selective blockers (e.g. metoprolol and bisoprolol) are generally safe and are recommended as the first choice(7). Beta-blockers are associated with fetal growth restriction; thus necessitating serial fetal growth monitoring in pregnancy (4). If beta-blockers fail, digoxin and verapamil should be considered for rate control. In haemodynamically stable patients without structural heart disease, i.v. ibutilide or flecainide may be considered for termination of AF but experience is limited. Flecainide, propafenone, or sotalol should be considered to prevent AF if atrioventricular nodal-blocking drugs fail(7). Amiodarone is not safe for the fetus as it may result in fetal thyroid toxicity (4). AF catheter ablation has no role during pregnancy.(7). **the American recommendations of 2014 and their focus published in 2019 did not specify specific care for pregnant women in their special population section(11).** Our patient was treated with digocin and bisoprolol at discharge with good evolution

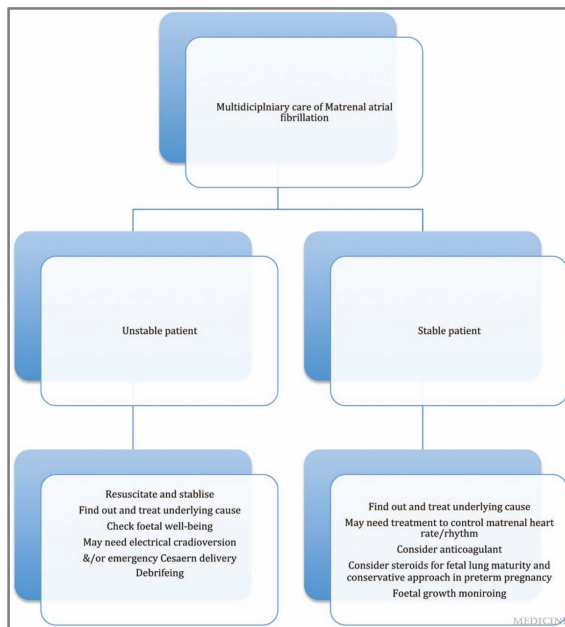


Figure : management of AF in a pregnant woman(10)

Conclusion : AF is a rare condition during pregnancy.the occurrence of isolated AF is even rarer.the occurrence of AF requires rapid, adequate and collegial management including the contribution of the cardiologist and the obstetrician for better management.

References

- (1) Ronpichai Chokesuwattanaskul, Charat Thongprayoon, Tarun Bathini, Oisin A. O'Corragain, Konika Sharma, Somchai Prechawat, Patompong Ungprasert, Kanramon Watthanasuntorn, Pavida Pachariyanon, Wisit Cheungpasitporn, Incidence of atrial fibrillation in pregnancy and clinical significance: A meta-analysis, *Advances in Medical Sciences*, Volume 64, Issue 2, 2019, Pages 415-422, ISSN 1896-1126, <https://doi.org/10.1016/j.advms.2019.07.003>.
- (2) Lee MS, Chen W, Zhang Z, Duan L, Ng A, Spencer HT, Kwan DM, Shen AY. Atrial Fibrillation and Atrial Flutter in Pregnant Women-A Population-Based Study. *J Am Heart Assoc*. 2016 Apr 13;5(4):e003182. doi: 10.1161/JAHA.115.003182. PMID: 27076563; PMCID: PMC4843529.
- (3) Andreassen L, Nielsen JB, Olesen MS. Genetic aspects of lone atrial fibrillation: what do we know? *Curr Pharm Des*. 2015;21(5):667-78. doi: 10.2174/1381612820666140825143610. PMID: 25175087.
- (4) Janjua, Nusrat Batool MBBS, MCPS, FCPS, MRCOGa,*; Birmani, Suhaib Akhtar MBBS, FCPS, MRCPIa; McDonagh, Thomas MD; Hameed, Abdul MBBS, MRCPI, MRCPS, MSc; McKernan, Matthew MB, ChB, MRCOG, PGDipd. New-onset lone maternal atrial fibrillation: A case report. *Medicine*: February 2020 - Volume 99 - Issue 7 - p e19156 doi: 10.1097/MD.00000000000019156
- (5) White S, Welch J, Brown LH. The Unexpected Pitter Patter: New-Onset Atrial Fibrillation in Pregnancy. *Case Reports in Emergency Medicine*. 2015;2015:318645
- (6) Murphy N, Sugrue D, McKenna P. Case report on the treatment of atrial fibrillation in a pregnant woman of 33 weeks' gestation. *Open J Obstetr Gynecol* 2014;04:8–9.
- (7) Gerhard Hindricks, Tatjana Potpara, Nikolaos Dagres, Elena Arbelo, Jeroen J Bax, Carina Blomström-Lundqvist, Giuseppe Boriani, Manuel Castella, Gheorghe-Andrei Dan, Polychronis E Dilaveris, Laurent Fauchier, Gerasimos Filippatos, Jonathan M Kalman, Mark La Meir, Deirdre A Lane, Jean-Pierre Lebeau, Maddalena Lettino, Gregory Y H Lip, Fausto J Pinto, G Neil Thomas, Marco Valgimigli, Isabelle C Van Gelder, Bart P Van Putte, Caroline L Watkins, ESC Scientific Document Group, 2020 ESC Guidelines for the diagnosis and management of atrial fibrillation developed in collaboration with the European Association for Cardio-Thoracic Surgery (EACTS): The Task Force for the diagnosis and management of atrial fibrillation of the European Society of Cardiology (ESC) Developed with the special contribution of the European Heart Rhythm Association (EHRA) of the ESC, *European Heart Journal*, Volume 42, Issue 5, 1 February 2021, Pages 373–498
- (8) Ramesh M. Gowda; Gopikrishna Pudukollu; Ijaz A. Khan; Sabrina L. Wilbur; Victor S. Navarro; Balendu C. Vasavada; Terrence J. Sacchi (2003). Lone atrial fibrillation during pregnancy. , 88(1), 0–124. doi:10.1016/s0167-5273(02)00360-1
- (9) Cheung CC, Nattel S, Macle L, Andrade JG. Management of Atrial Fibrillation in 2021: An Updated Comparison of the Current CCS/CHRS, ESC, and AHA/ACC/HRS Guidelines. *Can J Cardiol*. 2021 Oct;37(10):1607-1618. doi: 10.1016/j.cjca.2021.06.011. Epub 2021 Jun 26. PMID: 34186113.
- (10) Janjua, Nusrat Batool; Birmani, Suhaib Akhtar; McDonagh, Thomas; Hameed, Abdul; McKernan, Matthew *Medicine* 99(7):e19156, February 2020.

(11) 2019 AHA/ACC/HRS Focused Update of the 2014 AHA/ACC/HRS Guideline for the Management of Patients With Atrial Fibrillation: A Report of the American College of Cardiology/American Heart Association Task Force on Clinical Practice Guidelines and the Heart Rhythm Society in Collaboration With the Society of Thoracic Surgeons. Craig T. January, MD, PhD, FACC, Chair, L. Samuel Wann, MD, MACC, FAHA, Vice Chair, Hugh Calkins, MD, FACC, FAHA, FHRS, Lin Y. Chen, MD, MS, FACC, FAHA, FHRS, Joaquin E. Cigarroa, MD, FACC, Joseph C. Cleveland Jr, MD, FACC, Patrick T. Ellinor, MD, PhD, Michael D. Ezekowitz, MBChB, DPhil, FACC, FAHA, Michael E. Field, MD, FACC, FAHA, FHRS, Karen L. Furie, MD, MPH, FAHA, Paul A. Heidenreich, MD, FACC, FAHA, Katherine T. Murray, MD, FACC, FAHA, FHRS, Julie B. Shea, MS, RNCS, FHRS, Cynthia M. Tracy, MD, FAHA, Clyde W. Yancy, MD, MACC, FAHA