

## **Case study**

### **A case of Acute on chronic life threatening SVC stenosis managed by timely intervention**

**Short title: Timely management of SVC stenosis**

#### **ABSTRACT**

Superior Vena Cava (SVC) obstruction is a very well recognized condition described in many diseases like tumour or malignancies of middle mediastinum, clots in SVC, aortic aneurysm, thyroid disorders, infections like fungal and tuberculosis of lungs and rarely constrictive pericarditis. Clinical Presentation is usually chronic or sub-acute. Rarely, it can have acute presentation with symptoms of dyspnea and stridor. Diagnosis is usually made in view of underlying disease and presence of puffiness of face and engorged neck veins. Timely intervention especially in acute presentation is often lifesaving. We present a case of acute on chronic SVC obstruction in a patient of chronic kidney disease (CKD) related to HD (Haemodialysis) catheter induced obstruction of SVC. We had a patient who presented with stridor, orthopnea in a SVC syndrome setting in an emergency.

**Key Words:** Superior Vena Cava obstruction; Balloon dilation; Stenting

## **INTRODUCTION**

Superior vena cava (SVC) syndrome is a collection of clinical signs and symptoms resulting from either partial or complete obstruction of blood flow through the SVC. The incidence of SVC syndrome reported in the literature range from 1 in 650 to 1 in 3100 patients.(1) The SVC is part of the low-pressure venous system containing thin walls susceptible to damage by a variety of pathologic mechanisms. These mechanisms can be divided into three categories which are compromised vessel anatomy, impaired venous flow, and diminished vessel wall integrity. These mechanisms often coexist in patients presenting with SVC syndrome. Extrinsic compression and obstruction of the SVC by a mass in the mediastinum is the most common cause of SVC syndrome. A growing proportion of SVC syndromes are now associated with occlusive venous thrombus formation that compromises venous flow back to the heart. The increasing use of indwelling intravascular devices such as catheters and pacemakers and implantable cardioverter-defibrillator (ICD) leads have played a major role in this growth. Resultant venous wall inflammation, fibrosis, and eventual thrombus lead to stenosis of the vessel itself. The most common cause is thrombus formation or malignancy infiltration of the vessel wall. The superior vena cava is formed by the junction of the left and right innominate (brachiocephalic) veins and it carries de oxygenated blood from the head, neck, upper extremities, and torso back to the heart. Commonly, this syndrome is most commonly seen secondary to mediastinal malignancy for such as small cell bronchogenic carcinoma, non-Hodgkin's lymphoma followed by metastatic tumors. Although, other causes like post chemo-radiation, iatrogenic catheter induced also are frequent. Venous congestion produces sometimes a critical clinical scenario due to laryngeal oedema and cerebral congestion. The usual most common signs and symptoms include face or neck swelling, upper extremity swelling, dyspnea, cough, and dilated chest vein collaterals. We had a patient who presented with stridor, orthopnea in a SVC syndrome setting in an emergency.

## **CASE PRESENTATION**

A 73-year-old male presented with severe breathlessness and stridor. Patient was a known case of CKD on regular haemodialysis through right Internal jugular vein (IJV) HD catheter. On examination patient was found to be in distress due to difficult breathing with stridor. Face, neck and chest wall was seen puffed up. After initial evaluation patient underwent emergency lifesaving balloon dilatation followed by stenting of SVC through left IJV. Post procedure patient improved immediately with complete resolution of symptoms within 1 hour of procedure.

## **Diagnosis**

The diagnosis of SVC syndrome in our patient was obvious made largely based on a patient's history of chronic kidney disease and right IJV indwelling HD catheter. Physical findings were face/neck swelling, distended neck veins, cough, dyspnea, orthopnea, upper extremity swelling, distended chest and neck veins, and conjunctival suffusion. Along with that patient had stridor, hoarseness, dysphagia, pleural effusion, head plethora, headache, nausea, light headedness, syncope, change in vision, altered mental status, upper body edema, cyanosis, papilledema and was confused. Patient's vitals were unstable with thready pulse and low volume. Blood pressure was on lower side. Patient was orthopneic and was not able to lie down flat.

## **Treatment**

CT angiogram prior to taking the procedure showed occluded right and left sided IJV, brachiocephalic vein and no flow across SVC. There was indwelling Hemodialysis (HD) catheter on right IJV. Hence left IJV puncture was done under Doppler guidance. Peripheral angiogram showed occluded left IJV with no flow in brachiocephalic vein and SVC (Fig 1). The GAIA 3 014 wire was used to cross the stenosis from left IJV to SVC. The whole path was dilated with NC trek 4x15mm coronary balloon at high pressure (Fig 2). This was

followed by dilatation with ULTRAVERSE 7x40mm peripheral balloon at 12 atmosphere (Fig 3). Check angiogram showed fibrotic stricture at mid SVC with recoiling. Hence, SVS was stented using BARD ELUMINEXX 14X40mm self-expanding stent. Final shoot showed good flow from left IJV to SVC to right atria (RA) (Fig 4). Right perm catheter was removed and left IJV perm catheter was inserted as patient had bilateral thrombosed lower limb veins and no fistula available for dialysis.

### **Follow up**

Post procedure patient started improving immediately on cath lab table. He was shifted to ICU and his puffiness of face was reduced to minimal in 1 hr time. Vitals were stabilized and was able to lie flat with total disappearance of respiratory distress and stridor. Next day patient underwent routine HD through the left IJV HD catheter and was discharged following that. Timely skilled intervention saved a life with quick reduction in morbidity.

### **DISCUSSION**

SVC syndrome was first described by William Hunter in 1757 in a patient with a large syphilitic aortic aneurysm compressing the SVC. It occurs in approximately 15,000 persons in the United States each year.(1) SVC syndrome is the clinical manifestation of SVC obstruction and occurs through external compression, thrombosis or invasion of the vein. SVC syndrome is now almost exclusively (more than 90%) secondary to malignancy. The most common malignant cause is non-small cell lung cancer in approximately 50% of patients. HD catheters, inserted into the IJV, may lead to catheter-related thrombosis. Moreover, as compared to other central venous catheters (CVCs), it is believed that HD catheters may be associated with an increased risk of thrombosis-related complications. The mechanism underlying HD catheter associated thrombosis is poorly understood, however factors such as recurrent vascular access, platelet dysfunction, endothelial factors,

inflammation, and clotting abnormalities have been suggested.(2) Other HD thrombosis-related risk factors include catheter-related features (such as catheter caliber-to-vein), venipuncture-associated trauma (nowadays reduced with ultrasound guidance), and catheter position (i.e., higher risk if catheter tip is in the brachiocephalic vein or proximal SVC versus distal to SVC). Practice recommendations stated the catheter to vessel ratio (CVR) can assist clinicians in selecting the most appropriate-sized for device vessel, and catheter to vessel ratio CVR can increase from 33% to 45% of the vessel's diameter; this is supported by the fact that larger diameter catheters can increase thrombosis risk.(3, 4) There are several risk factors associated with catheter related thrombi; catheter placement can damage the endothelial wall, the catheter can be incorrectly placed, or it can also impede blood flow within a vein, causing blood stasis. These are components of Virchow's triad, and they are factors considered to contribute to thrombosis in iatrogenic SVCS.(5) In our case as well patient had HD catheter in right IJV over last 2 months.

Following a clinical diagnosis, supportive therapy and medical management are commonly initiated. This involves elevation of the patient's head as a simple maneuver with the goal of decreasing venous pressure. Further management is guided by the patient's underlying SVC syndrome etiology. For patients with thrombus related to an indwelling intravascular device, removal should be considered along with anticoagulation therapy and catheter-directed thrombolysis. Multidisciplinary treatment planning for those with obstruction due to malignancy is important as tumor type, and staging can help to guide appropriate chemotherapy or radiation therapy. Open surgical repair through bypass grafting with spiral saphenous vein, femoral vein, polytetrafluoroethylene (PTFE) graft, or Dacron graft have traditionally been considered to overcome SVC obstruction. With expanding treatment options for both benign and malignant etiology, endovascular therapy is now widely

considered the first-line treatment for SVC syndrome. Less invasive endovascular management can offer patients immediate relief of symptoms.

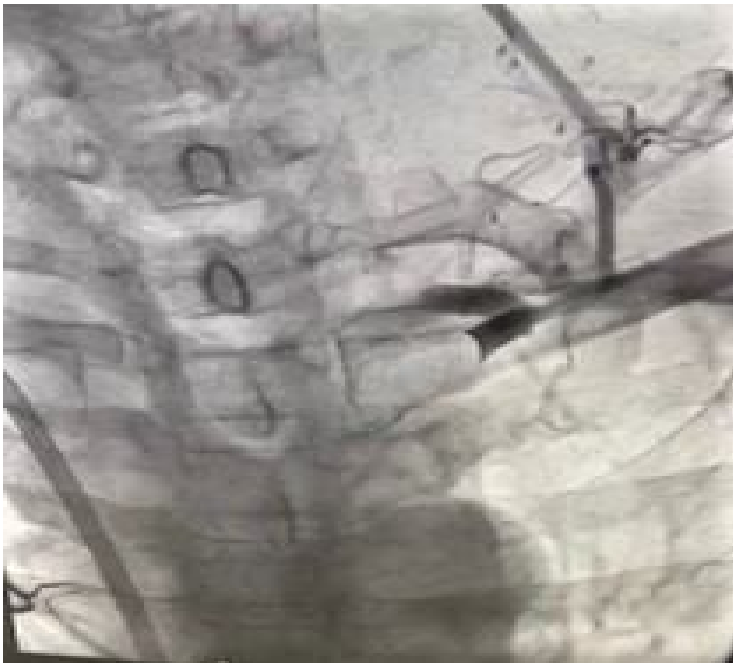In select cases, SVCS may be life threatening and requires emergent treatment. If laryngeal edema causing laryngeal constriction or cerebral edema is present, these medical emergencies require prompt management and rapid treatment of the underlying cause of SVCS may be indicated.(6-8) These clinical SVCS sequelae may cause long-term morbidity or mortality if left untreated, and empiric treatment with radiation, stenting, and/or chemotherapy may be indicated even before biopsy results become available.

Multiple scoring systems have been developed to assist practitioners in classifying the urgency of SVCS cases. In Yu et al.'s classification scheme, grade 4 SVCS indicates life-threatening disease due to one or more of the following: "significant cerebral edema (confusion, obtundation) or significant laryngeal edema (stridor) or significant hemodynamic compromise (syncope without precipitating factors, hypotension and renal insufficiency)." Although only 5 % of SVCS patients present with grade 4 disease, any of the aforementioned complications would be an indication for emergent venogram, stent placement, and thrombolytic therapy if indicated.(9) Patient in our case report also presented with grade 4 SVCS, hence was taken for emergency catheter intervention with excellent rewarding immediate result. (Fig 5)

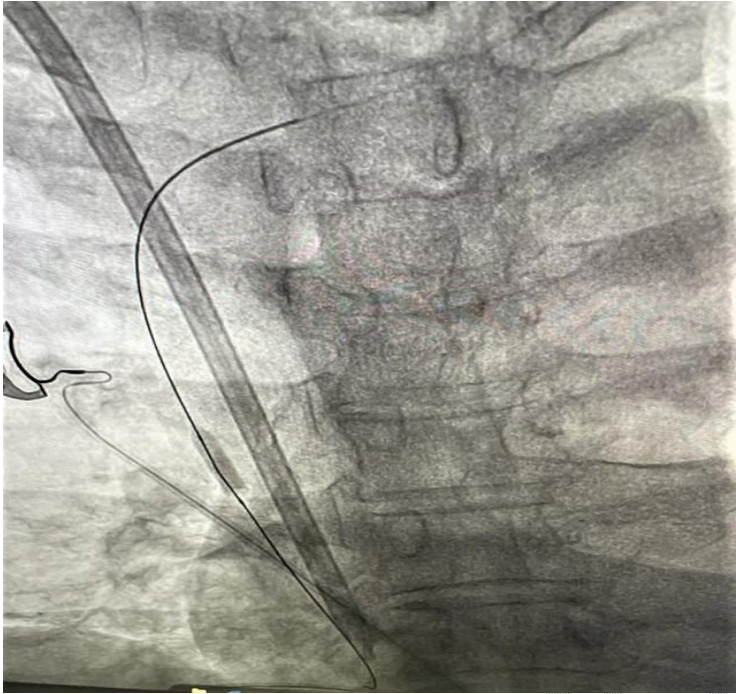
## REFERENCES

1. Higdon ML, Higdon JA. Treatment of oncologic emergencies. *American family physician*. 2006;74(11):1873-80.
2. Baldari D, Chiu S, Saliccioli L. Aortic pseudoaneurysm as a rare cause of superior vena cava syndrome: A case report. *Angiology*. 2006;57(3):363-6.
3. Szokol JW, Alspach D, Mehta MK, Parilla BV, Liptay MJ. Intermittent airway obstruction and superior vena cava syndrome in a patient with an undiagnosed mediastinal mass after cesarean delivery. *Anesthesia & Analgesia*. 2003;97(3):883-4.
4. Gaslin M, Seymour P, Willcox TO. Superior vena cava syndrome presenting as serous otitis media. *Otolaryngology-Head and Neck Surgery*. 2005;2(133):P243.
5. Guijarro Escribano J, Antón R, Colmenarejo Rubio A, Sáenz Cascos L, Sainz González F, Alguacil Rodríguez R. Superior vena cava syndrome with central venous catheter for chemotherapy treated successfully with fibrinolysis. *Clinical and Translational Oncology*. 2007;9(3):198-200.
6. Baker G, Barnes H. Superior vena cava syndrome: etiology, diagnosis, and treatment. *American Journal of Critical Care*. 1992;1(1):54-64.
7. Sofue K, Takeuchi Y, Arai Y, Sugimura K. Life-threatening cerebral edema caused by acute occlusion of a superior vena cava stent. *Cardiovascular and interventional radiology*. 2013;36(1):272-5.
8. Taguchi J, Kinoshita I, Akita H. Superior vena cava syndrome. *Gan to Kagaku ryoho Cancer & Chemotherapy*. 2011;38(4):518-23.
9. James BY, Wilson LD, Detterbeck FC. Superior vena cava syndrome—a proposed classification system and algorithm for management. *Journal of Thoracic Oncology*. 2008;3(8):811-4.

**Figure 1: Left Jugular Vein angiogram showing total occlusion of brachiocephalic & SVC**

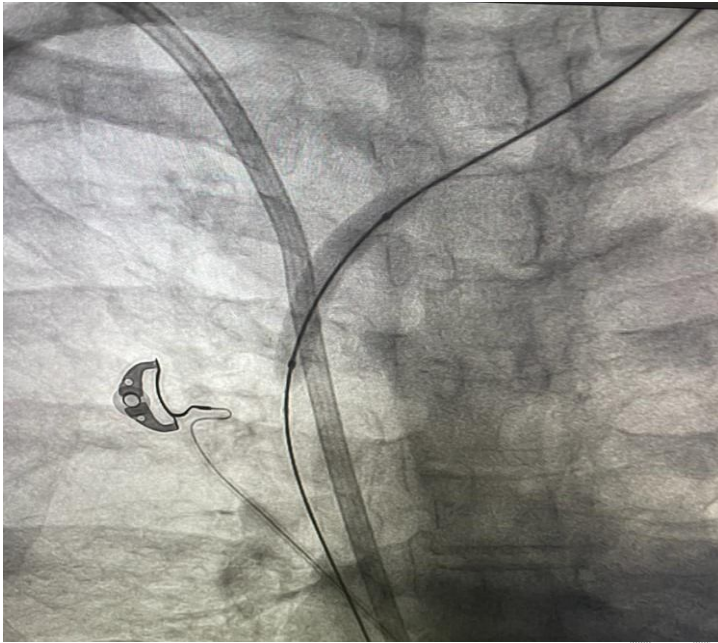


**Figure 2: Obstruction crossed with GAIA 3 wire and balloon dilatation with coronary balloon**



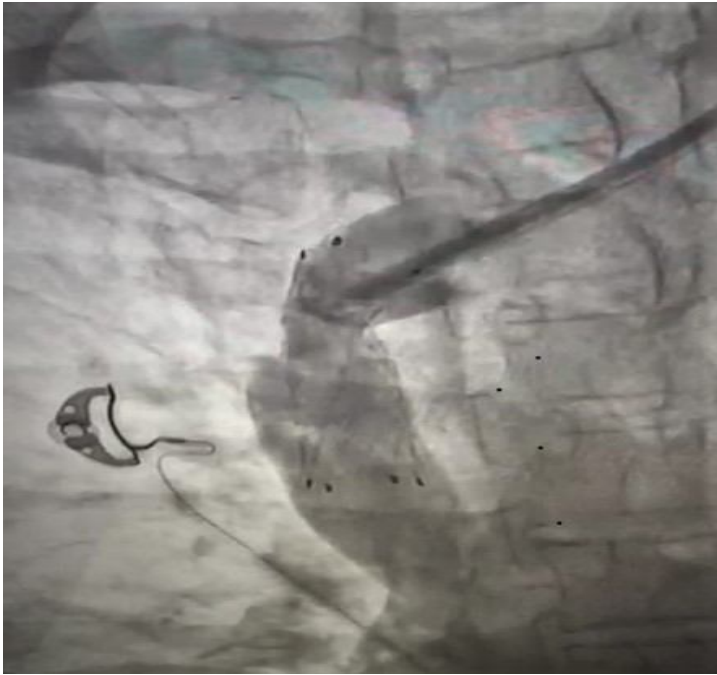
UNDER PEER REVIEW

**Figure 3: Obstruction dilated with peripheral balloon**



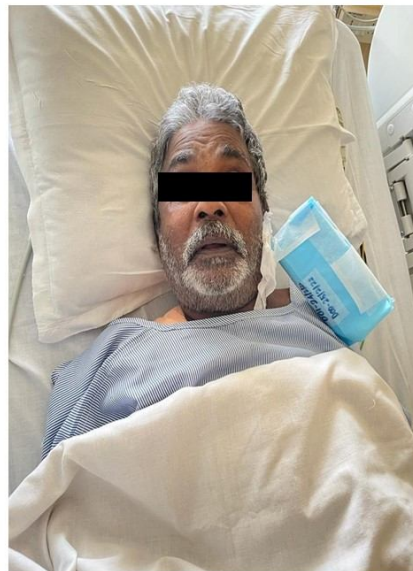
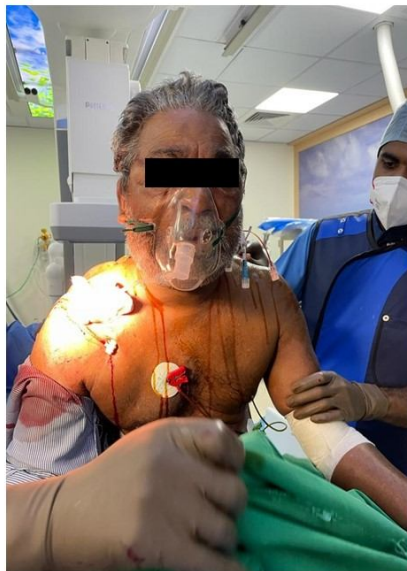UNDER PEER REVIEW

**Figure 4: Post Stenting SVC shows good flow**



UNDER PEER REVIEW

**Figure 5: Pre & Post Procedure Picture (Note: Marked reduction of Face & Neck swelling and reduced distress)**



UNDER PEER REVIEW