

ACUTE MESENTERIC ISCHEMIA AND INTESTINAL NECROSIS IN COVID-19 PATIENT: REPORT OF A CASE

ABSTRACT:

Aims: We present a case of acute intestinal necrosis due to multiple thrombosis in a female patient with confirmed SARS (Severe Acute Respiratory Syndrome)- Cov 19 infection.

Presentation of Case: A 69-year-old female patient was administered in Emergency Department in our hospital with symptoms of general weakness, loss of appetite and elevated body temperature up to 38°C which started three days before the admission, followed by abdominal distension with pain and confusion. After clinical examination and diagnostic investigations, an emergency laparotomy was performed, which showed discontinuous gangrenous changes in terminal ileum, two of which were already perforated, signs of diffuse stercoral peritonitis, spleen with changed morphology (whitish patches and uneven capsule). Resection of the terminal ileum with ileostomy and splenectomy were performed.

Discussion: Acute intestinal gangrene is a rarer, but devastating complication in patients with SARS Cov 19 infection. Its first symptoms cannot always be confirmed by diagnostic investigations, so great caution is required.

Conclusion: Life-threatening, extrapulmonary complications should be considered in Covid 19 confirmed patients.

Keywords: acute mesenteric ischemia, SARS-CoV-2, Covid 19 infection.

1. INTRODUCTION

SARS (Severe acute respiratory syndrome)-CoV-2 possesses the ability to penetrate inside its host cells via the interaction between its transmembrane glycoprotein, called protein S, and its functional receptor, angiotensin converting enzyme 2 (ACE2). In the respiratory tract, SARS-CoV-2 is thus able to infect alveolar epithelial cells and pulmonary endothelial cells. It results from intense local inflammation spreading to endothelial cells and causing endothelitis.

Until today we do not understand the mechanism of these complications during the disease, COVID-19. This is due either to diffuse endothelial inflammation secondary to viral infection of the endothelial cell or to an elevation of procoagulant factors (factor VIII, von Willebrand factor, fibrinogen) without forgetting the role of cytokines induced by the virus which causes coagulation and activation of fibrinolysis [1-3]. In addition to many circulating prothrombotic micro vesicles that supply platelets or monocytes as well as mediators released by activated neutrophils are also hypercoagulable factors.

While thrombosis is a well-known complication of coronavirus disease 2019 (COVID-19) infection, reports on intestinal necrosis due to intestinal ischemia caused by thrombosis are extremely rare but also occur [4]. Its initial symptoms might not be captured by CT scans, therefore caution is required. It is possible that a microthrombus occurring in the ileum vessel caused the intestinal necrosis.

We herein report a case of intestinal necrosis of terminal ileum due to multiple thrombosis in a COVID-19 patient.

2. PRESENTATION OF CASE

A 69-year-old female patient was brought to the Emergency Center due to diffuse abdominal pain and distension, elevated body temperature (up to 38°C), loss of appetite, general weakness and confusion. The complaints started 3 days before she called for an examination and the previous day due to the development of urine retention, a urinary catheter was placed. Obtained data on the patient's history shown some neurological conditions for which investigations were conducted at the Neurology Clinic in Skopje, North Macedonia looking for the reason of the appearance of moderate to severe flaccid quadriplegia three months ago. Available medical documentation shown that the patient was vaccinated with two doses of Sinovak vaccine (second dose received 5 months previously). The patient was also positive for SARS-Co 19 infection a month and a half ago when she had no symptoms related to the infection, rather she was tested due to the necessary hospitalization at the Department of Neurology to determine the causes of the neurological deficit, according to the instructions of the Ministry of Health. In this period of month and a half there is no negative PCR test for COVID 19 so is considered to be prolonged infection. Clinical examination revealed rigid abdominal wall, strong pain and peritoneal irritation. The patient was bradypsychic, bradylalic, with a dry and coated tongue, with concentrated urine, heart rate around 100/min, blood pressure 110/60 mm Hg. Laboratory findings shown leukocytosis (21.3), CRP (286.4), urea 34.6, creatinine 240, LDH (Lactate Dehydrogenase) 347, Hgb (hemoglobin) 8.6, Hct (hematocrit) 25.8, D-dimers 2300. Imaging investigations were performed. Abdominal CT showed pneumoperitoneum, mesenterial and intestinal oedema. Chest X-ray showed normal findings without elements of consolidation.

A quick antigen test for SARS-Co 19 infection was done, which was positive and then confirmed with PCR (polymerase chain reaction) testing.

We decide to perform urgent exploratory laparotomy according to the findings, from vital indications, with a high risk, which was accepted by the patient and her family with an appropriate signature.

The operation was performed in general anesthesia. Intraoperatively a large amount of free small intestinal content was found in the abdomen, with parietic intestines, signs of diffuse visceral and parietal peritonitis, discontinuous gangrenous changes of the ileum starting 20 cm proximal to the ileocecal valve, in a length of about 80 cm, with two holes from perforation (*Figure 1*).

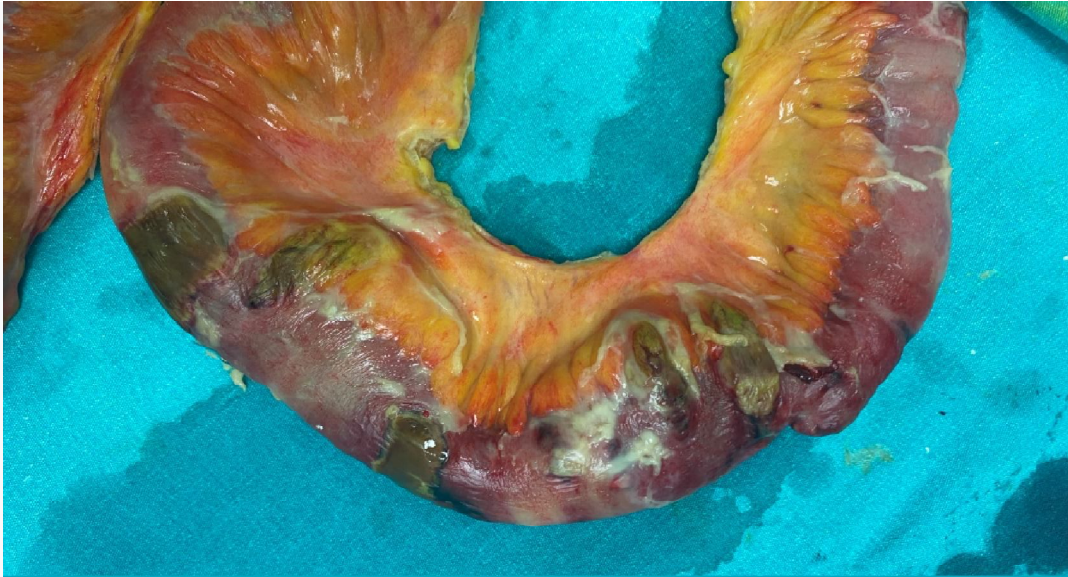


Figure 1. Appearance of the resected terminal ileum with discontinuous gangrenous changes

The spleen had also a changed morphology, with whitish patches and uneven capsule presented (*Figure 2*).

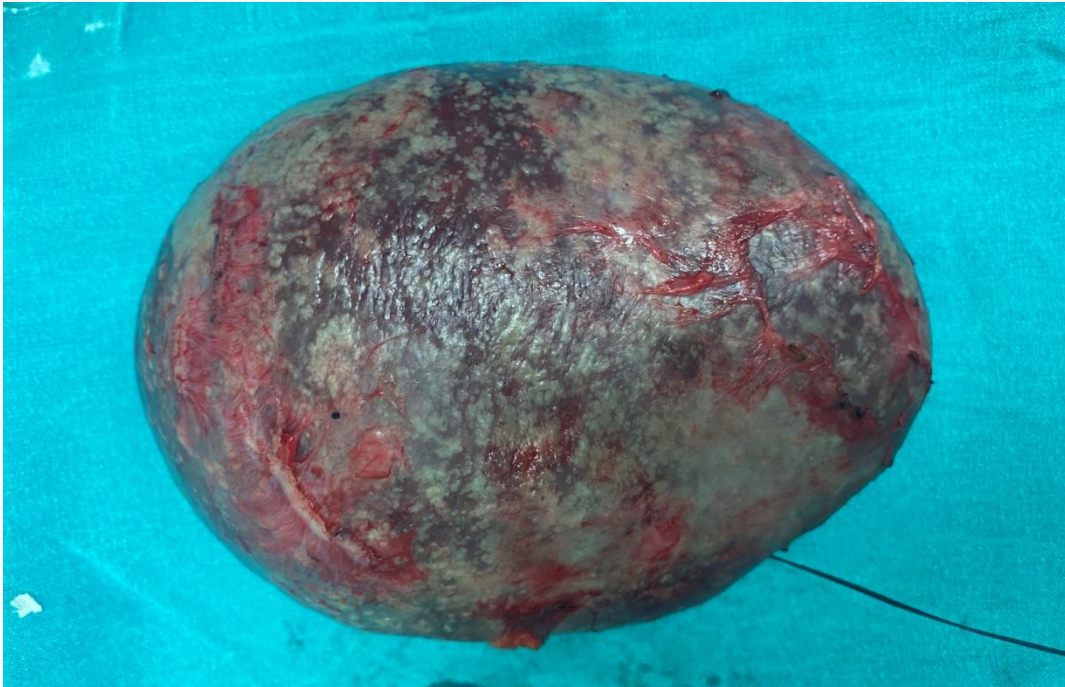


Figure 2. Appearance of the spleen (whitish patches and uneven capsule).

Resection of the ileum was performed, with splenectomy and creation of a terminal ileostomy. Extensive intraoperative lavage of the abdominal cavity was performed with double intraabdominal drainage, one of the recess of Douglas and other placed in the left subphrenic recess.

Postoperatively, the patient was placed in the COVID INTENSIVE UNIT for mechanical ventilation, antibiotic therapy, anticoagulant therapy (heparin pump 25000 IU/24h), infusion solutions, dopamine and norepinephrine stimulation. Unfortunately there was gradual deterioration of vital parameters, with oliguria to anuria, followed by rhythm disturbance, bradycardia, drop in saturation and asystole and consecutive death on the 6th postoperative day.

The pathohistological finding showed the existence of a transmural infarct on the intestinal wall with an abundant polymorphonuclear inflammatory infiltrate that affected the mesenteric fat tissue and formed multiple abscesses (*Figure 3 A*). On the intestinal serosa, there were signs of acute peritonitis in the organization and in part of the blood vessels there were fibrin thrombi. Part of the resected small intestine has only ulcer-erosive changes of the mucosa and submucosa, and a smaller part has preserved regular histoarchitectonics. The spleen has stagnant changes and signs of acute splenitis with formation of microabscesses (represented by a polymorphonuclear inflammatory infiltrate) (*Figure 3 B*). This histologic finding of acute splenitis in this patient is reflective of septic state.

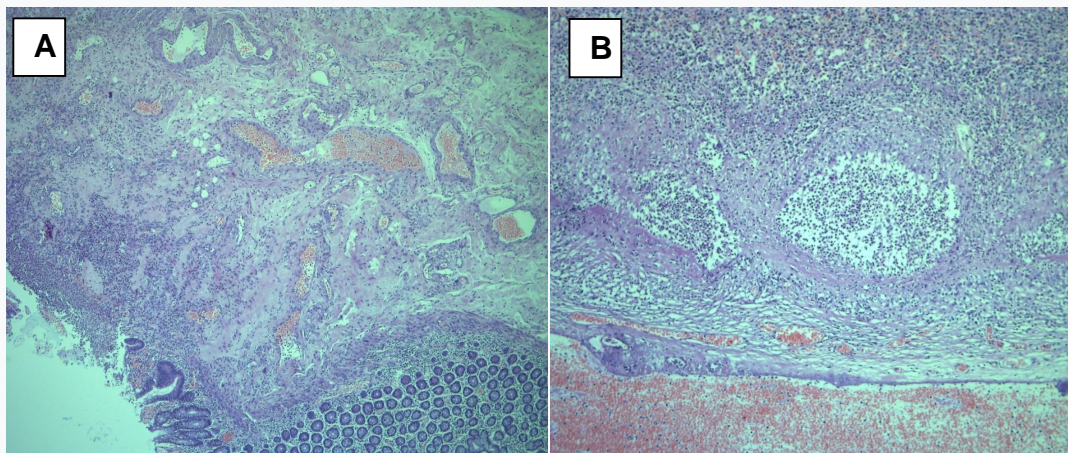


Figure 3. A. Small bowel – mucosal cleft ulceration with intramural vessel congestion and clot formation (H&E staining, x50) B. Spleen – congestion with subcapsular hematoma and microabscess formation (H&E staining, x100)

3. DISCUSSION

The COVID-19 pandemic is a fast-evolving situation, so reports of unique aspects of this infection are essential to aid clinicians in managing the condition. Thrombotic complications associated with COVID-19 have been described, with highest frequency in the lower limb arteries (71%), upper limb arteries (14%), cerebral arteries (10%) and visceral arteries (4%) [5, 6].

Complications from thrombosis can be fatal and require prophylaxis, early diagnosis, and therapeutic intervention. Small bowel ischemia was the most prevalent abdominal finding of all AMI in COVID-19 patients. The severity of AMI varies from mild, with transient superficial

changes in intestinal mucosa to severe form, producing transmural necrosis of the intestinal wall, potentially fatal in these patients [7]. Among these patients with AMI about 50% of them receiving conservative management died, highlighting high mortality without surgery [8]. We would like to report on a case with prolonged COVID-19 infection combined with microvascular thrombosis in terminal ileum, development of necrosis with perforation and peritonitis, which led to quick deterioration and lethal ending of the patient. In order to help to recognize and prevent these complications we would like to point out the need of quick diagnosis and treatment of such patients and avoid fatal outcome.

AMI (acute mesenteric ischemia) is a rare abdominal emergency that usually requires a wide intestinal resection [9]. A prompt diagnosis requires a high index of suspicion and is essential for successful treatment. The precise pathological mechanism leading to the complication of AMI in COVID-19 is not known. COVID-19-related hypercoagulability is likely a multifactorial-direct viral infection of the endothelial cell leading to diffuse endothelial inflammation, increased procoagulant factors like factor VIII, von Willebrand factor, fibrinogen, and high inflammatory state associated with the cytokine storm leading to coagulation and fibrinolysis activation. In our case, we believe that the microthrombus which occurred in the ileum vessel led to a shower embolism, which in turn caused intestinal necrosis in multiple areas of the ileum, as intestinal necrosis was localized in the terminal ileal region.

Additional explanations for the hypercoagulability may be the presence of large numbers of prothrombotic circulating microvesicles, which are cytoplasmic microparticles stemming from platelets or monocytes and neutrophil extracellular traps released from activated neutrophils that constitute a mixture of nucleic DNA, histones and nucleosomes [10]. Another possible mechanism includes direct bowel damage by the novel beta-coronavirus given expression of angiotensin-converting enzyme 2 on enterocytes of the small bowel, the target receptor for SARS-CoV-19.

In a report examining AMI of COVID-19 patients, small bowel ischemia (46.67%) was the most prevalent abdominal finding, followed by ischemic colitis (37.3%). Non-occlusive mesenteric ischemia (NOMI; 67.9%) indicating microvascular involvement was the most common pattern of bowel involvement. Approximately 50% of the patients receiving conservative/medical management died, highlighting high mortality without surgery [8,11, 12].

Delays in the diagnosis of AMI are common and associated with high rates of morbidity and mortality. Prompt diagnosis requires a high index of suspicion and early contrast CT imaging [13]. Treatment of this condition is focused on gastrointestinal decompression, fluid resuscitation, hemodynamic support, surgical resection of the necrotic bowel, and restoration of blood flow to the ischemic intestine. The diagnosis of an ischemic bowel should be one of the top differentials in critically ill patients when clinical symptoms are suggestive.

4. CONCLUSION

Complications from thrombosis can be fatal and require prophylaxis, early diagnosis, and therapeutic intervention. This report adds to the literature regarding the extrapulmonary complications of COVID-19 and in order to help with the future diagnosis and treatment of such patients.

Health care providers should have a high index of suspicion regarding life-threatening complications of COVID-19 so that timely intervention can be done.

CONSENT

Written informed consent was obtained from the patient for publication of this case report and accompanying images.

ETHICAL APPROVAL

As per international standard or university standard written ethical approval has been collected and preserved by the authors.

REFERENCES

1. A.H. Parry, A.H. Wani, M. Yaseen. Acute Mesenteric Ischemia in Severe Coronavirus-19 (COVID-19): Possible Mechanisms and Diagnostic Pathway. *AcadRadiol*, 2020; 27: 1190. doi: 10.1016/j.acra.2020.05.016
2. Z. Varga, A.J. Flammer, P. Steiger, M. Haberecker, R. Andermatt, A.S. Zinkernagel, et al. Endothelial cell infection and endotheliitis in COVID-19. *Lancet*, 2020; 395: 1417-1418.
3. M. Panigada, N. Bottino, P. Tagliabue, G. Grasselli, C. Novembrino, V. Chantarangkulet al. Hypercoagulability of COVID-19 patients in intensive care unit: A report of thromboelastography findings and other parameters of hemostasis. *J ThrombHaemost*, 18. 2020: 1738-1742 doi: 10.1111/jth.14850
4. Morioka H, Goto M, Tanaka H, Momose H, Fujino K, Hagiwara T, et al. Acute intestinal necrosis due to multiple thrombosis in COVID-19 patient. Report of a case. *Surg Case Rep*. 2022 Jul 19;8(1):136. doi: 10.1186/s40792-022-01495-6.
5. Guan W.J., Ni Z.Y., Hu Y. Clinical characteristics of coronavirus disease 2019 in China. *N. Engl. J. Med*. 2020;382:1708–1720. doi: 10.1056/NEJMoa2002032.
6. Yana E, Allan MC, Jeffrey S et al. Acute arterial thromboembolism in patients with COVID-19 in the New York City are. *Ann Vasc Surg*. 2021;70:290-4
7. N Schieda, N Fasih, W Shabana. Triphasic CT in the diagnosis of acute mesenteric ischaemia. *Eur Radiol*, 23 :2013; pp. 1891-1900, doi:10.1007/s00330-013-2797-y
8. Vineeta O, Avinash M, Aprateem M, et al. Mesenteric ischemia in patients with COVID-19: an updated systematic review of abdominal CT findings in 75 patients. *Abdom Radiol (NY)*. 2021;10:1–38.
9. Hajifathalian K., Krisko T., Mehta A. Gastrointestinal and hepatic manifestations of 2019 novel coronavirus disease in a large cohort of infected patients from New York: Clinical implications. *Gastroenterology*. 2020;159:1137–1140.e2. doi: 10.1053/j.gastro.2020.05.010.
10. Jean MC, Jerrold HL. COVID-19 and its implications for thrombosis and anticoagulation. *Blood*. 2020;135:2033–40.
11. Estevez-Cerda S.C., Saldaña-Rodríguez J.A., Alam-Gidi A.G., Riojas-Garza A., Rodarte-Shade M., Velazco-de la Garza J., et al. Severe bowel complications in SARS-CoV-2 patients receiving protocolized care. *Rev. Gastroenterol. Mex. Engl. Ed*. 2021;86:378–386. doi: 10.1016/j.rgmexen.2021.08.009.
12. Sevelia P., Rallabhandi S., Jahagirdar V., Kankanala S.R., Ginnaram A.R., Rama K. Acute Mesenteric Ischemia as an Early Complication of COVID-19. *Cureus*. 2021;13:e18082. doi: 10.7759/cureus.18082
13. Serban D., Socea B., Badiu C.D., Tudor C., Balasescu S.A., Dumitrescu D., et al. Acute surgical abdomen during the COVID 19 pandemic: Clinical and therapeutic challenges. *Exp. Ther. Med*. 2021;21:519. doi: 10.3892/etm.2021.9950