

Case report

Migrating Intrauterine Device Mimicking an Acute Appendicitis: a Case Report

ABSTRACT

The intrauterine device is the world's third most popular contraceptive method. However, it is not without risk. Indeed, serious complication can occur such as uterine perforation and migration to adjacent abdomino-pelvic structures. We report a case of a migration of intrauterine device mimicking an acute appendicitis which was removed under laparoscopy. Laparoscopy is the most common surgical procedure, and it is also considered the first recommended treatment.

Keywords: IUD; appendicitis; laparoscopy.

1. INTRODUCTION

According to data from the World Health Organization the intrauterine device is the third most used contraceptive method worldwide, **it has been shown to be a contraceptive method with a high efficacy rate and an adequate margin of safety** and widely used [1-5]. **"Among the infrequent but potentially serious complications** is has been associated with, there is uterine perforation which can cause lesion in adjacent organs" [6]. We report a case of a migration of intrauterine device mimicking an acute appendicitis which was removed under laparoscopy.

2. CASE PRESENTATION

A 52-year-old women, was admitted to the emergency department of our hospital with acute abdominal pain in the right iliac fossa with fever. **The patient's general condition was impaired. On physical examination she had abdominal guarding in the right iliac area and good hemodynamic status with normal blood pressure.** Laboratory studies found a biological inflammatory syndrome with hyperleukocytosis (15000/uL) and high C-reactive protein level (120 mg /L). In front of these clinico-biological signs we have suspect an acute appendicitis what imposed the realization of an abdomino-pelvic CT-scan which sowed an epiploic plastron containing a foreign body in the right iliac area (**Fig. 1**). The patient disclosed that she had received an insertion of an IUD 23 years ago.

An emergency surgery was planned under general **anesthesia** with laparoscopic approach, the IUD was removed from the large omentum (**Fig. 2, Fig. 3**), and there was no perforation in the uterus or the bowel.

The patient goes well and **she** was discharged 2 days after.

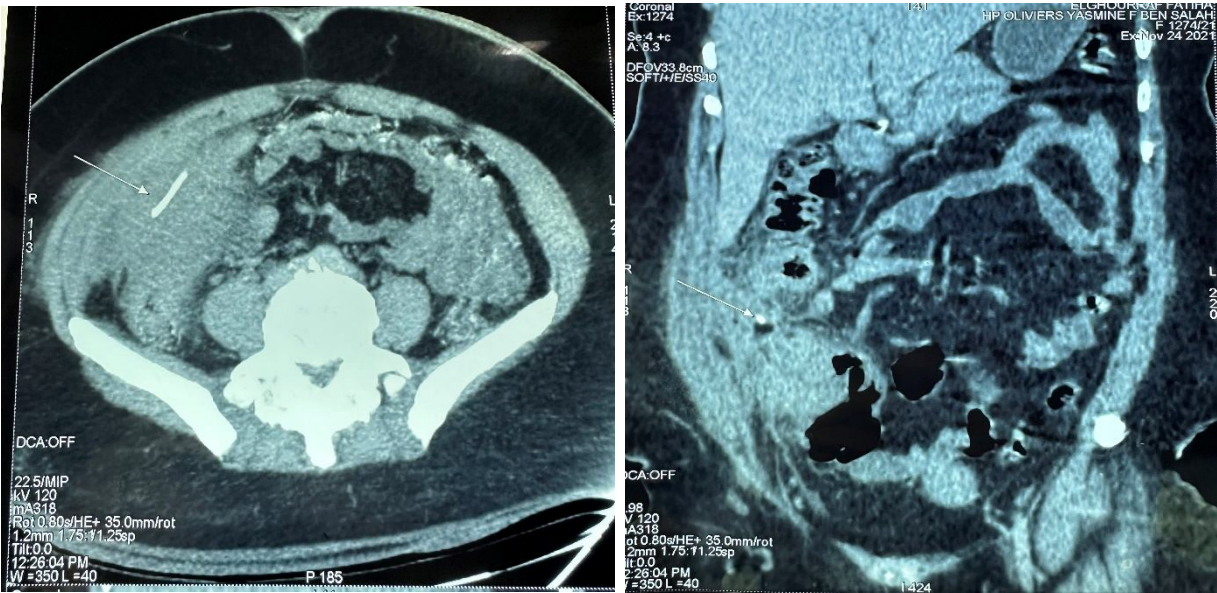


Fig. 1. CT-scan imaging showing the IUD in the right iliac area

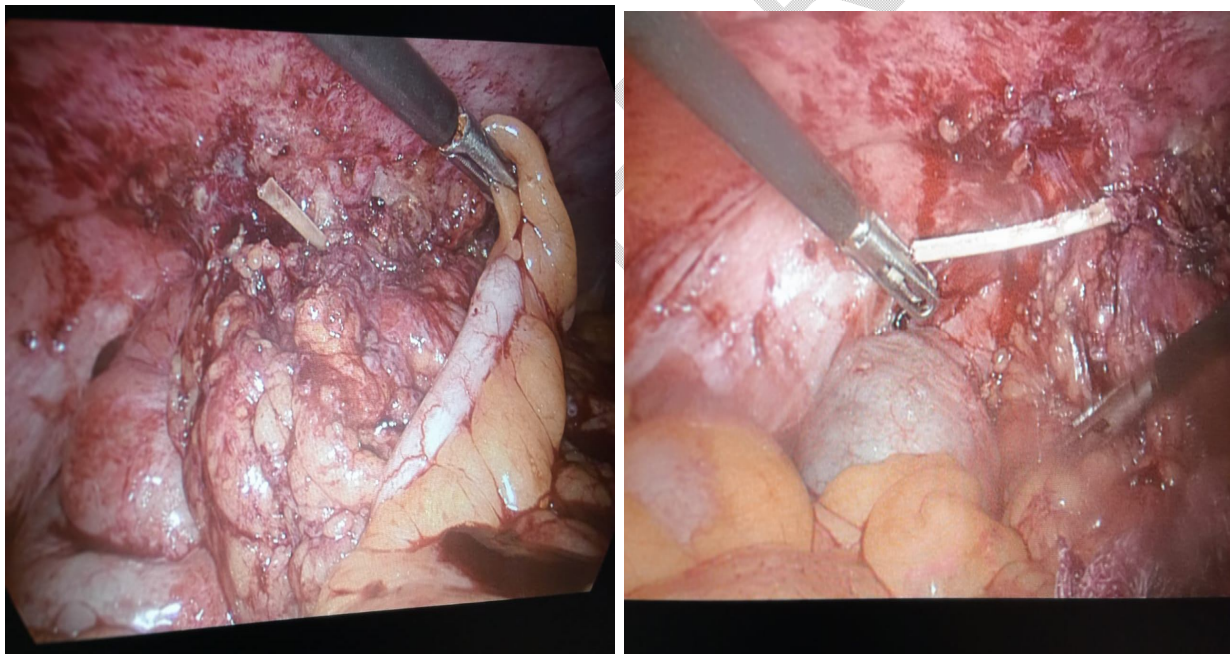


Fig. 2. Operatory imaging showing the removing of the IUD

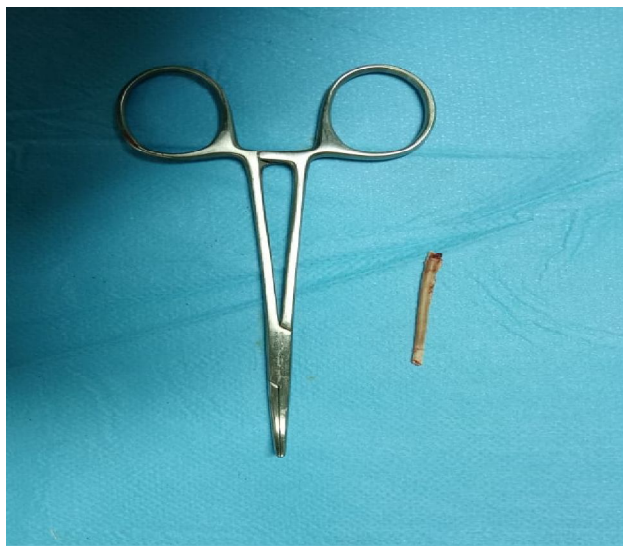

Fig. 3. The IUD after removing

3. DISCUSSION

"The intra-uterine device is a safe contraceptive method with a 99% of effectiveness and widely used worldwide" [7]. "However, it is not without risk. Indeed, serious complication can occur such as uterine perforation and migration to adjacent abdomino-pelvic structures" [8].

"The risk factors of the occurrence of uterine perforation by the IUD can be linked to the device itself such that its structure and components of the inserted tube. These risk factor may also be linked to the size, position, or the anatomical configuration of the uterus and the insertion period like post-partum and post-abortion" [9].

"Spontaneous perforation of the uterus by IUD is rare with a reported incidence of 0,001-0,05 %" [10]. "Severe intra-abdominal complication may ensue if an IUD is lost in the abdominal cavity and not removed. Intra-peritoneal IUD do not necessarily produce symptoms but may intrude neighboring viscera, such us the bladder or intestines" [11,12]. "An IUD related uterine perforation can remain undetected at the time of insertion and women can be asymptomatic for months or even years before the diagnosis of uterine perforation is made, therefore to determine the location of the device, a routine gynecologic examination should be scheduled 6 weeks after insertion as a proactive prevention method" [13].

"Most experts including the World Health Organization and the International federation for family Planning recommend the surgical removal of device once the migration is diagnosed before the occurrence of severe complications" [9] [14,15]. "The most frequent surgical procedure is laparoscopy which is also considered first treatment option. However, its success rate varies between 44 and 100%, depending on the presented complication and surgeon's expertise. Up to 25 % may have the necessity of conversion to laparotomy" [6] [16,17].

4. CONCLUSION

The migration of IUD may be asymptomatic for months or years, and it's may occur serious complication. The IUD must be retired as soon as the diagnosis of migration is confirmed. Laparoscopy is a surgical procedure that can be done on an elective basis and allows for the removal of devices and organ repair.

CONSENT

As per international standard or university standard, patient(s) written consent has been collected and preserved by the author(s).

ETHICAL APPROVAL

As per international standard or university standard written ethical approval has been collected and preserved by the author(s).

REFERENCES

1. United Nations, Contraceptive Use by Method 2019: Department of Economic and Social Affairs, Population Division. Data Booklet (ST/ESA/SER.A/435); 2019.
Available: https://www.un.org/development/desa/pd/sites/www.un.org.development.desa.pd/files/files/documents/2020/Jan/un_2019_contraceptiveusebymethod_databooklet.pdf.
2. Mosher WD, Jones J. Use of contraception in the United States: 1982-2008. *Vital Health Stat* 23. 2010;29:1-44.
3. United Nations, World Contraceptive Patterns 2013. Department of Economic and Social Affairs, Population Division (ST/ESA/SER.A/326); 2013.
4. Akpınar F, Nur Ozgur E, Yılmaz S, Ustaoglu O. Sigmoid colon migration of an intrauterine device. *Case Rep. Obstet. Gynecol.* 2014;14:3.
Available: <https://doi.org/10.1155/2014/207659>
5. Ekka NMP, Jha RK, Malua S, Bodra P, Murari K. Translocation of IUCD into Caecum Causing Acute Appendicitis. *International Journal of Medical and Dental Sciences.* 2015;4(1); 650–652.
6. Barnett C, Moehner S, Do Minh T, Heinemann K. Perforation risk and intra-uterine devices: results of the EURAS-IUD 5-year extension study. *Eur J Contracept Reprod Health Care.* 2007;22(6):424-428.
Available: <https://doi.org/10.1080/13625187.2017.1412427>
7. Ti AJ et al. Effectiveness and safety of extending intrauterine device duration: a systematic review. *Am J Obstet Gynecol.* 2020;223(1);24-35.
Available: <https://doi.org/10.1016/j.ajog.2020.01.014>
8. Zeino MY, Wietfeldt ED, Advani V, Ahad S, Younkin C, Hassan I. Laparoscopic removal of a copper intrauterine device from the sigmoid colon. *JSLS.* 2011;15(4); 568–570.
9. Nceboz Ü, Özçakir HT, Uyar Y, Çağlar H. Migration of an intrauterine contraceptive device to the sigmoid colon: a case report. *Eur. J. Contracept. Reprod. Health Care.* 2003;8(4);229–232.
10. Mulayim B, Mulayim S, Celik NY. A lost intrauterine device. Guess where we found it and how it happened? *Eur. J. Contracept. Reprod. Health Care.* 2006;11;47.
11. Atakan RH, Kaplan M, Ertrk E. Intravesical migration of intrauterine device resulting in stone formation. *Urology.* 2002;(60)5;911.
12. Mehrangiz ZB, Roghayeh AA, Shohreh AM. Migration of intrauterine device caused asymptomatic acute appendicitis: A case report. *Clin Case Rep.* 2021;9(5); e04283.
13. Harrison-Woolrych M, Ashton J, Coulter D. Uterine perforation on intrauterine device insertion: is the incidence higher than previously reported. *Contraception.* 2003;67(1);53-56.
Available: [https://doi.org/10.1016/S0010-7824\(02\)00417-1](https://doi.org/10.1016/S0010-7824(02)00417-1)

14. Mederos R, Humaran L, Minervini D. Surgical removal of an intrauterine device perforating the sigmoid colon: a case report. *Int. J. Surg.* 2008;6(6):60–62.
15. Adıyeke M, Sancı M, Karaca İ, Gökçü M, Töz E, Öcal E. Surgical management of intrauterine devices migrated towards intra-abdominal structures: 20-year experience of a tertiary center. *Clin. Exp. Obstet. Gynecol.* 2015;42(3):358–360.
16. Toumi O et al. Pelvic abscess complicating sigmoid colon perforation by migrating intrauterine device: a case report and review of the literature. *Int J Surg Case Rep.* 2018;42:60–63.
Available: / <https://doi.org/10.1016/j.ijscr.2017.10.038>
17. Mosley FR, Shahi N, Kurer MA. Elective surgical removal of migrated intrauterine contraceptive devices from within the peritoneal cavity: a comparison between open and laparoscopic removal. *JSLS.* 2012;16(2):236–241.
Available: / <https://doi.org/10.4293/108680812x13427982377265>

UNDER PEER REVIEW