

Case report

Inguinoscrotal Manifestations of Antenatal Bowel Perforation

Abstract

Aim:

Antenatal gastrointestinal perforation is a well recognised entity and is evident at birth with gastrointestinal obstruction by volvulus, atresia, intussusception, stenosis or inspissated meconium in 50% of cases. Exclusive inguinoscrotal presentation of this condition is rare and its different manifestations are highlighted.

Method:

A retrospective report of two infants with inguinoscrotal manifestations of antenatal gastrointestinal perforation. The first, a 2 month old with a tense unilateral inguinoscrotal hydrocoele and the second, a 2 day old premature child with a suspected incarcerated hernia, were investigated by plain abdominal X ray and ultrasound scan prior to surgical exploration. The excised hydrocoele sacs were submitted to histology.

Result:

Abdominal X ray and ultrasound scan revealed dense scrotal and scattered intra-abdominal calcification in the first case. No calcification was detectable in the latter case in which histology confirmed meconium laden macrophages in the wall of the encysted hydrocoele. Surgery was curative in both. In the absence of a family history, screening for cystic fibrosis mutation was negative for both.

Conclusion:

Antenatal gastrointestinal perforation may present in atypical fashion with principally inguinoscrotal signs. A high level of suspicion is necessary when calcification is noted in both the scrotum and abdomen although its absence in both sites does not exclude previous bowel perforation. Surgical management of the inguinoscrotal problems are sometimes necessary and histology of tissue may provide the only clue as to the diagnosis. In either event exclusion of cystic fibrosis is mandatory.

Introduction

Approximately half of all antenatal bowel perforations are associated with meconium peritonitis and gastrointestinal abnormality. The other half are asymptomatic with no demonstrable primary pathology. This provides fertile ground for theories to explain the phenomenon. Exclusive inguinoscrotal manifestation of in-utero bowel disruption is rare and interesting.

Case presentation

Case 1:

A 2 months old healthy infant, presented with a tense unilateral inguinoscrotal mass. Ultrasound demonstrated a communicating hydrocele with multiple echogenic foci suspended within the scrotal mass (fig1). An abdominal X-ray confirmed dense scrotal (fig 2) with concomitant subdiaphragmatic calcific flecks suggesting in utero bowel perforation and peritonitis.

Following 3 months of expectant treatment with no improvement, a repair of the tense hydrocele was performed via a right inguinal incision. Exploration revealed a meconium stained tunica vaginalis containing thick gelatinous material in which were suspended multiple calcific bodies. A patent processus vaginalis was ligated following comprehensive evacuation of the hydrocoele.

A screen for cystic fibrosis was negative and recovery was uncomplicated.

Case 2:

A premature child born at 35 weeks of gestation presented at 2 days of age with a suspected incarcerated inguinal hernia. He was afebrile on examination but with a tender, erythematous, irreducible swelling noted in the right iliac fossa. His abdomen was otherwise soft and non-tender with normal bowel sounds. External genitalia was normal with two well descended testicles.

With a tentative diagnosis of an incarcerated inguinal hernia, surgical exploration of the groin was undertaken and revealed a localised, non-communicating meconium hydrocoele of the spermatic cord. This was excised in its entirety and the patient made an uneventful recovery.

Histology of the hydrocoele confirmed acute and chronically inflamed granulation tissue in the wall with meconium-laden macrophages suggesting a history of undiagnosed in utero gut perforation with meconium peritonitis. Abdominal X-ray showed no evidence of calcification and screening for cystic fibrosis was negative.

Discussion:

In utero perforation and meconium peritonitis was first described by Morgagni in 1761.¹ With a frequency of 1 in 35 000 live births meconium peritonitis is a rare, sterile, in utero inflammation of the peritoneum². This arises due to the leakage of meconium through an intestinal perforation some time after the onset of gut peristalsis in the 5th month of gestation. In the 7th month of gestation, when evagination of the ventral abdominal wall occurs, meconium may also enter the patent processus vaginalis, inguinal canal and scrotum. As healing occurs, this free meconium undergoes calcification³. In cases of spontaneous resolution of meconium peritonitis, intra-peritoneal and scrotal calcification may be the only clue to an earlier, in utero perforation¹. Isolated thoracic and pelvic calcifications have also been described^{3,4}. Sometimes calcification is not radiographically visible though historically X-ray findings of calcification have been interpreted as being diagnostic of a prior or a healed perforation^{5,6}.

Fifty percent of cases of in utero perforation and meconium peritonitis are associated with gastrointestinal obstruction by volvulus, atresia, intussusception, stenosis or inspissated meconium in cystic fibrosis⁵. However, in the other half no primary pathology is demonstrated and various theories have been postulated to explain this phenomenon. These include, vascular insufficiency, alterations in mesenteric blood flow and abnormalities in gut mucosa and muscular wall⁷. In this context a benign course to meconium peritonitis is most likely.²

Occasionally this entity presents with a mass in the inguino-scrotal region comprising an encapsulated meconium collection which may be mistaken for a hernia or tumour^{1,5}. These masses are initially soft but harden with local tissue reaction and meconium calcification in the first weeks of life.⁸ In this scenario the differential diagnosis includes malignancy (teratoma, gonadoblastoma, leydig cell and other rare tumours), idiopathic testicular microlithiasis or haemorrhagic infarcts with organised intrascrotal haematoma^{7,9,10}. When abdominal and scrotal calcification are seen together on X ray or ultrasound, the differential diagnosis can be narrowed down to meconium peritonitis with meconium periorchitis.¹¹ However the absence of calcification, as evident in case 2 does not exclude an in utero perforation.

Meconium periorchitis usually follow a benign course and management is mainly expectant. Resorption of the hydrocoele and accompanying calcification maybe complete, avoiding surgical intervention.^{9,12,13} Despite this favourable outlook, surgery, as was our experience, is unavoidable in situations where there is difficulty in distinguishing an incarcerated hernia from an inflamed encysted hydrocoele of cord or for a tense, non resolving scrotal hydrocoele. The latter scenario also carries a risk of inducing morphological changes to the underlying testes consequent to sustained intrascrotal pressure.¹⁴ Surgery, to exclude malignancy, is rarely indicated.

The surgical approach, as we had experienced, is as for a standard hernia or hydrocoele repair and the presence of meconium staining is not an indication for more radical surgery. Biopsy of the wall is recommended for histological confirmation where there is strong clinical suspicion of meconium peritonitis in the absence of abdominal or scrotal calcification.

The incidence of cystic fibrosis is estimated to be 20% in meconium peritonitis and 4.5% in meconium periorchitis thus a chloride sweat test and DNA studies are mandatory in these cases.^{9,12,13}

In summary, antenatal bowel perforation may present exclusively as inguinoscrotal masses. In themselves they do not constitute an indication for surgery but scrotal exploration maybe necessary when there is concern over a possible hernia or when the hydrocoele progresses and fails to resolve. The surgical approach itself is as for a standard hydrocoele repair. Biopsy of the sac is mandatory to confirm clinical suspicion and to establish a definitive diagnosis.

UNDER PEER REVIEW

References

1. Forouhar F. Meconium Peritonitis: Pathology, Evolution and Diagnosis. *Am J Clin Pathol.*1982; 78: 208-213
2. Herschkowitz S., Mizrahi S., Sujov P. . Meconium Peritonitis: A Benign Course in a Premature Infant. *American Journal of Perinatology* 1990;7: 31-2
3. Dehner L, Scott D., Stocker J. Thomas. Meconium periorchitis: A Clinicopathologic Study of Four Cases with a Review of the Literature. *Hum Path* 1986;17: 807-812
4. Salman A.B, Karaoglanoglu N, Suma S. Abdominal, Scrotal and Thoracic Calcification Owing to Healed Meconium Peritonitis. *J Pediatr Surg.* 1999;34: 1415-1416
5. Ring K.S., Axelrod S.L., Burbige K.A., Hensle T.W. Meconium Hydrocoele: An Unusual Etiology of a Scrotal Mass in the Newborn. *J Urol* 1989;141: 1172-3
6. Thompson R.B., Rosen D.I., Gross D.M. Healed Meconium Peritonitis Presenting as an Inguinal Mass. *J Urol* 1973;110: 364-5
7. Heetderks DR, Verbrugge GP. Healed meconium peritonitis presenting as a scrotal mass in an infant. *J Pediatr Surg.* 1969; 4: 363-365
8. Berdon WE, Baker DH, Becker J, De Sanctis P. Scrotal masses in healed meconium peritonitis. *New Eng J Med.* 1967; 277:285-287
9. Burgoccon-Gibod L, Roucayrol AM. Meconium Periorchitis. *Ped Pathol.* 1992; 12:851-856.
10. Stokes III S., Flom S. Meconium Filled Hydrocoele Sacs as a Cause of Acute Scrotum in a Newborn. *J Urol.* 1997;158: 1960-1
11. Varkonyi I, Fliegel C, Rosslein R, Jenny P, Ohnacker H. Meconium periorchitis: case report and literature review. *Eur J Pediatr Surg.* 2000; 10:404-7
12. Friedman AP, Haller JO, Goodman JD. Sonography of scrotal masses in healed meconium peritonitis. *Urol Radiol.* 1983; 5:43-6
13. Tibboel D., Gaillard J.L.J., Molenaar J.C. The Importance of Mesenteric Vascular Insufficiency in Meconium Peritonitis. *Hum Path.* 1986;17: 411-416
14. Mahomed A, Stockdale E, Vaergese J, Youngson G. Abdominoscrotal hydrocoeles: Little place for conservatism. 1998; 13:186-188.

Fig 1 : Ultrasound scan demonstrating multiple calcific bodies suspended in the hydrocoele sac.

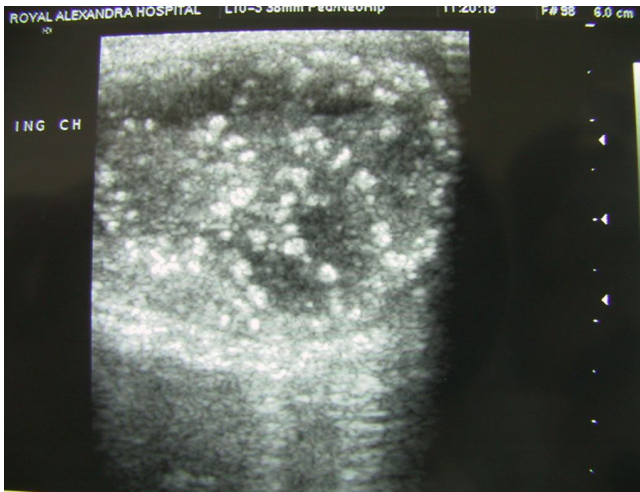


Fig 2 : Extensive right scrotal calcification visible on plain X ray. Some minimal flecks evident on left side as well.

