

RARE ASSOCIATION OF AN AGGRESSIVE GIANT CELL TUMOR WITH XERODERMA PIGMENTOSUM

ABSTRACT

Xeroderma pigmentosum (XP) is a genodermatosis that manifests as photo-induced skin and ocular alterations and skin cancers. An association with a giant cell tumor is a very rare entity. We report the case of a 17-year-old patient, followed since childhood for XP, who presented with a very aggressive giant cell tumor in the wrist for which he underwent amputation. A review of the literature of these rare lesions is presented and analyzed to see if this is an association or is a chance coincidence.

KEYWORDS : Xeroderma pigmentosum , giant cell tumour, Aggressive, Distal radius.

INTRODUCTION

Giant cell tumors (GCTs) are locally aggressive benign tumors that preferentially occur in the metaphyseal area of long bones [1]. They represent 5% to 10% of all primary bone tumors. They mainly affect young adults between 20 and 40 years of age. Their origin remains uncertain [2].

Xeroderma pigmentosum (XP) is a genodermatosis that manifests itself by photo-induced skin and eye changes and skin cancers. An association with a giant cell tumor is a very rare entity. We report a case of a 17 year old patient with an association of XP and GCT which would be the second case reported in the literature after that of REKHA et al [3]

CASE PRESENTATION

This is a 17 year old patient, right handed, without profession, followed for xeroderma pigmentosum since childhood, who consulted for a painful mass on the left wrist noted by the patient 2 months before.

The clinical examination revealed: tiny lenticular pigmented macules, with imprecise limits, spread over the skin and on the dorsal surface of the wrist; a shiny painful mass, hard and fixed in relation to the deep plane, circumferential, 8 cm in length (Fig. 1), with limited mobility of the wrist.), with limitation of wrist mobility without downstream vasculo-nerve, nor regional adenopathy. The standard radiological workup showed a lytic epiphyseal-metaphyseal image of the lower extremity of the radius, blowing out the cortical bone in places, breaking the external cortical bone with increased soft tissue density, classified as grade III according to the Campanacci classification (Fig. 2). Magnetic resonance imaging (MRI) revealed a large osteolytic mass, centered on the lower extremity of the radius, with irregular and heterogeneously enhanced contours, coming into contact with the radial and ulnar arteries and veins and infiltrating the digital arteries (Fig. 3). As part of the workup, a thoracic CT scan was performed, which did not reveal any other localization. The phosphocalcic assessment was normal. A biopsy of the mass performed dorsally confirmed the diagnosis of a malignant giant cell tumor. The evolution was marked by a budding ulceration with local extension invading the two pedicles (Fig. 4).

DISCUSSION:

Giant cell tumors are generally benign osteolytic lesions of relatively high frequency. They occur mainly in the epiphyses of the long bones of the limbs in 80% to 90% of cases [1]. Malignant GCTs is more common in men with a sex ratio at 3 [4]. Malignant GCTs are divided into primary and secondary forms. Primary malignant GCTs are those with sarcomatous components that are present de novo in conjunction with a giant cell tumour of the bone and are exceedingly rare. The term "dedifferentiated GCT" is also used to describe these tumours. Secondary malignant GCTs are high grade sarcomas occurring at sites of previously treated GCTs previously treated [5]

Xeroderma pigmentosum (XP) is an autosomal recessive condition characterized by poor nucleotide excision repair (NER) of DNA damage brought on by ultraviolet light (UV) and chemicals [6]. Patients who have elevated photosensitivity as well as typical cutaneous, ophthalmological, and neurological symptoms should have the diagnosis of XP suspected [7].

The mechanism that triggers the malignancy of this tumor in patients with XP is not clear, but uncontrolled cell proliferation is the final carcinogenic pathway [3]. Campanacci and al [8] proposed a radiographic classification, reflecting the aggressiveness of the lesion in three grades, of which grade III is a lesion with blurred boundaries, with extension into the soft tissues that is not limited by a bony shell, which corresponds to a locally aggressive tumor. An evolution towards a cutaneous complication is certain in this regard that could be avoided by a rapid medical management or even radiotherapy, followed by surgery.

The choice of treatment is based on the local aggressiveness of this tumor and the histological result. Monobloc resection is recommended for TCG grade III [9].

It has been shown in recent studies that patients with a normal allele and a common polymorphism in one of the four XP genes (XP-A, XP-C, ERCC2 or ERCC5) have an increased risk of skin and lung cancer as well as a poor response to chemotherapy [10].

Neyssa et al proved that the P53 protein mutation is involved in the pathogenesis of osteosarcoma [11].

CONCLUSION

The association of an aggressive giant cell tumor with xeroderma pigmentosum is very rare. There are no arguments to explain the occurrence of severe forms of GCT on a terrain of XP. Moreover, the small number of cases reported in the literature does not allow us to validate this hypothesis. However, this association could not be a simple coincidence, which solicits a new avenue of research.

Consent

As per international standard or university standard, parental(s) written consent has been collected and preserved by the author(s).

Ethical Approval:

As per international standard or university standard written ethical approval has been collected and preserved by the author(s).

REFERENCES

- [1] Sobti A, Agrawal P, Agarwala S, et al. Giant cell tumor of bone-an overview. *Archives of Bone and Joint Surgery* 2016; 4: 2.
- [2] Hosseinzadeh S, De Jesus O. Giant Cell Tumor. In: *StatPearls [Internet]*. StatPearls Publishing, 2022.
- [3] Rekha A, Rai DK. GIANT CELL TUMOUR OF THE TIBIA WITH XERODERMA PIGMENTOSUM. *Journal of Clinical and Diagnostic Research* 2007; 1: 529–532.
- [4] Murphey MD, Nomikos GC, Flemming DJ, et al. Imaging of giant cell tumor and giant cell reparative granuloma of bone: radiologic-pathologic correlation. *Radiographics* 2001; 21: 1283–1309.
- [5] Raskin KA, Schwab JH, Mankin HJ, et al. Giant cell tumor of bone. *JAAOS-Journal of the American Academy of Orthopaedic Surgeons* 2013; 21: 118–126.
- [6] Sidwell RU, Sandison A, Wing J, et al. A novel mutation in the XPA gene associated with unusually mild clinical features in a patient who developed a spindle cell melanoma. *British Journal of Dermatology* 2006; 155: 81–88.
- [7] Leung AK, Barankin B, Lam JM, et al. Xeroderma pigmentosum: An updated review. *Drugs in Context*; 11.
- [8] Campanacci M, Baldini N, Boriani S, et al. Giant-cell tumor of bone. *JBJS* 1987; 69: 106–114.
- [9] Cheng JC, Johnston JO. Giant cell tumor of bone: prognosis and treatment of pulmonary metastases. *Clinical Orthopaedics and Related Research (1976-2007)* 1997; 338: 205–214.
- [10] OTTAVIANI, Sébastien, FOREST, Anne, ESCAMPS, Vincent, et al. Osteosarcoma in a patient with xeroderma pigmentosum. *Joint bone spine*, 2009, vol. 76, no 1, p. 109-110.
- [11] Marina N, Gebhardt M, Teot L, et al. Biology and therapeutic advances for pediatric osteosarcoma. *The oncologist* 2004; 9: 422–441.

Conflict of Interest : The authors declare no relationship of interest.

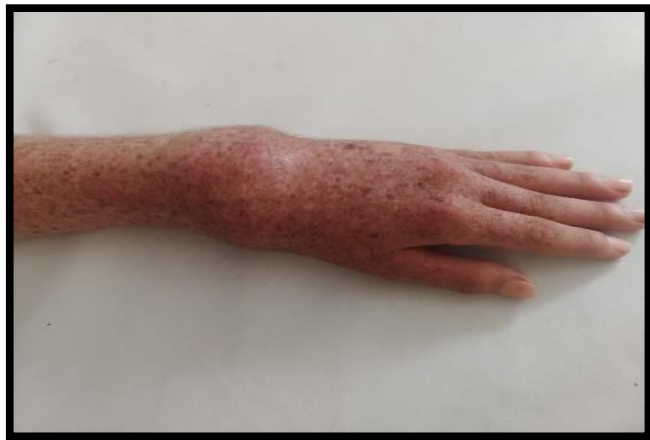

Fig. 1: Clinical appearance of the tumor mass on the wrist and polymorphic pigmented macules

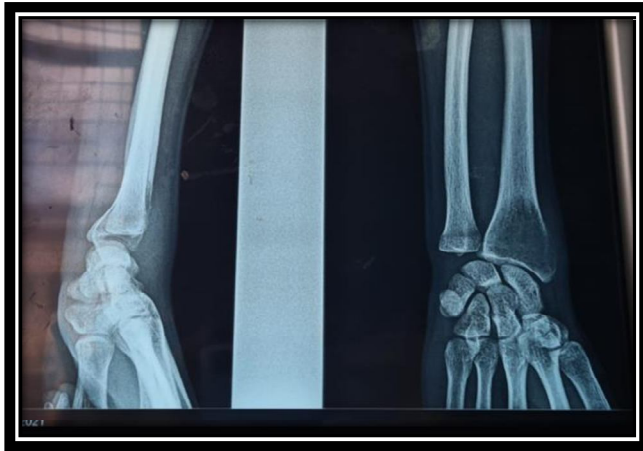


Fig. 2: Radiological aspect showing the epiphyseal/metaphyseal lytic image Grade III of Cappanacci

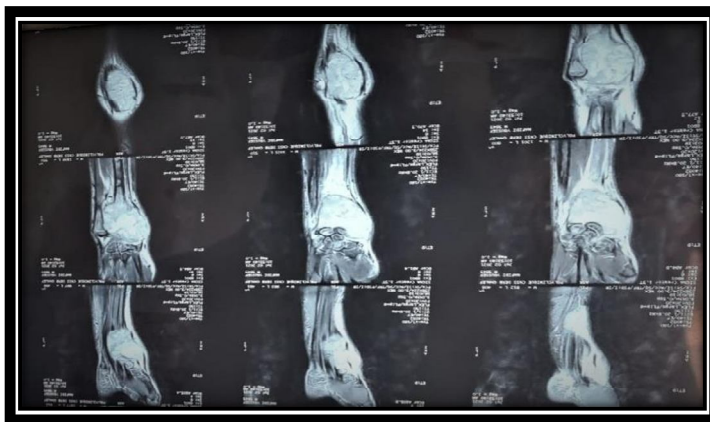

FIG 3: The MRI showing the extension of the tumor to the soft tissue of the wrist

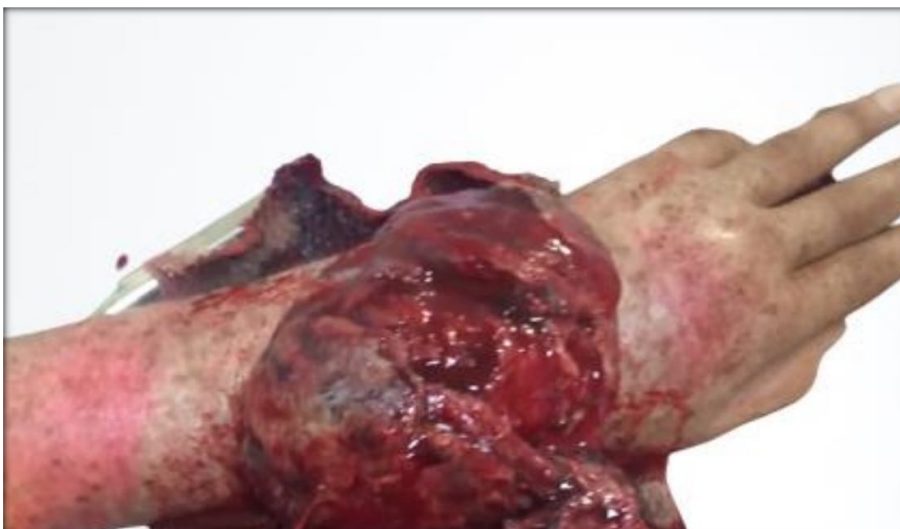

Fig. 4: Clinical appearance showing the aggressive evolution of the tumor after biopsy.

UNDER PEER REVIEW