

Case study

A case of extensive bowel gangrene due to tubercular mesenteric cyst

Abstract:

We report a case of 10 year old female weighing 20 kg with severe pain abdomen and abdominal distension for 3 days. Radiological investigation suggested bowel obstruction. Emergency exploratory laparotomy done with resection of gangrenous bowel segment containing mesenteric cyst with end jejunostomy. Histopathological report suggested it to be a tubercular mesenteric cyst, and patient started on anti-tuberculosis treatment.

Introduction:

Mesenteric cyst is a rare diagnosis with incidence around 1 per 140,000, most commonly occurring in adults with mean age of 45 years.¹ Approximately, one-third of the cases occur in children younger than 15 years, with mean age of 4.9 years. Mesenteric cyst was first described by Benevieni, a Florentine anatomist in 1507, arising from duodenal to sigmoid colon mesentery.² It is a rare cause of abdominal pain. The etiology of mesenteric cyst can be either arising from congenitally misplaced lymphatic tissue that has no efferent communication with the lymphatic system (chylolymphatic) or it may be derived from a diverticulum of the mesenteric border of the intestine that has become sequestered (enterogenous) or there may be blockage of the lymphatic system due to trauma, infection or neoplasm.³ Differential diagnosis can be serosanguinous cyst due to trauma, tuberculous abscess of the mesentery, hydatid cyst, ovarian cyst, tumours of mesentery. Knowledge of these lesions are important due to the various complications associated with suboptimal surgical management.

Case Report:

A 10 year old girl, native of Karimganj, presented to surgery casualty of Silchar Medical College and Hospital on 29.03.2022 with complaints of severe generalised pain abdomen and distension of abdomen for 3 days. It was associated with multiple episodes of vomiting. However, there was no history of hematemesis, melena, fever, cough, trauma, seizures. There was no significant past history as well as family history. On clinical examination, the patient was oriented to time, place and person, with BP- 90/60 mm hg, pulse rate – 112/min, no palor, icterus or cyanosis. However, features of dehydration was present with dry tongue, sunken eyes. Per abdominal examination revealed a distended, tense abdomen with generalised tenderness with decreased bowel sounds. Per rectal examination revealed a collapsed rectum. Laboratory tests were done and showed hemoglobin level of 9.8 g/dl, total leukocyte count 7510 cells/ cu mm, platelet count- 2.7

lakhs/ cu mm. Her renal function test was deranged with urea- 150 mg/dl, creatinine- 1.47mg/dl, sodium – 122 mmol/L and potassium- 5.80 mmol/L. Liver function test, amylase and lipase levels were within normal limits. Chest Radiograph was normal. Plain picture abdomen showed multiple air fluid level with no air under diaphragm. Ultrasound of the abdomen showed features of bowel obstruction.

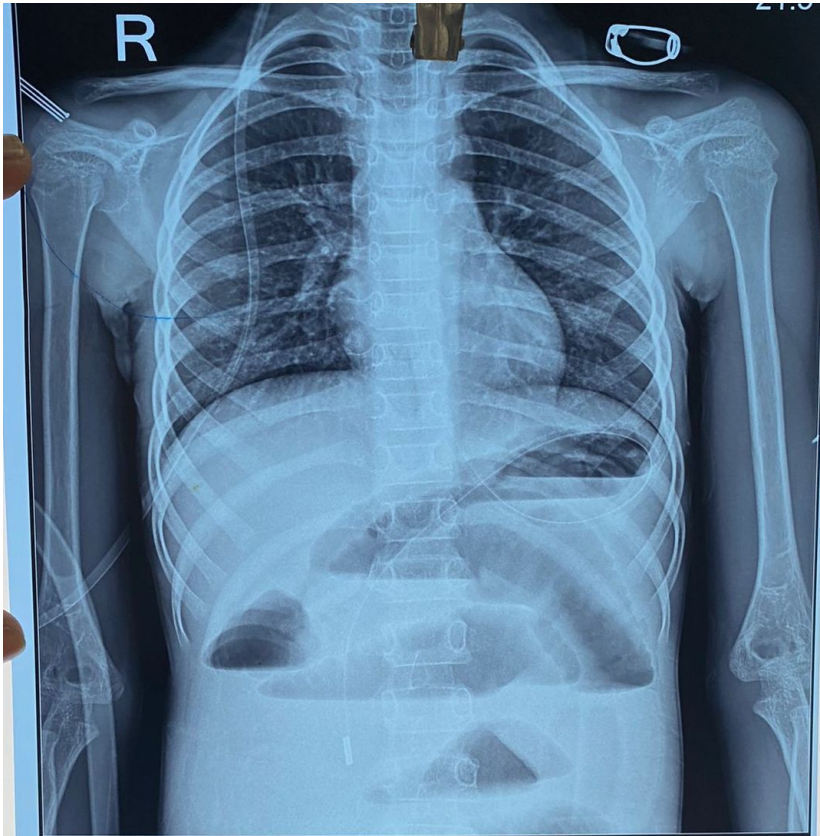


Fig 1- Radiograph showing multiple air fluid level.

As the condition of the patient deteriorated over time, CECT could not be planned and patient was prepared for emergency OT. Patient underwent Emergency exploratory laparotomy under GA on 30.03.2022, which revealed a large section of gangrenous bowel segment extending from distal jejunum to almost the end of ileo-caecal junction with torsion of the bowel segment around a mesenteric cyst of size 4cm* 4.5cm*3cm.

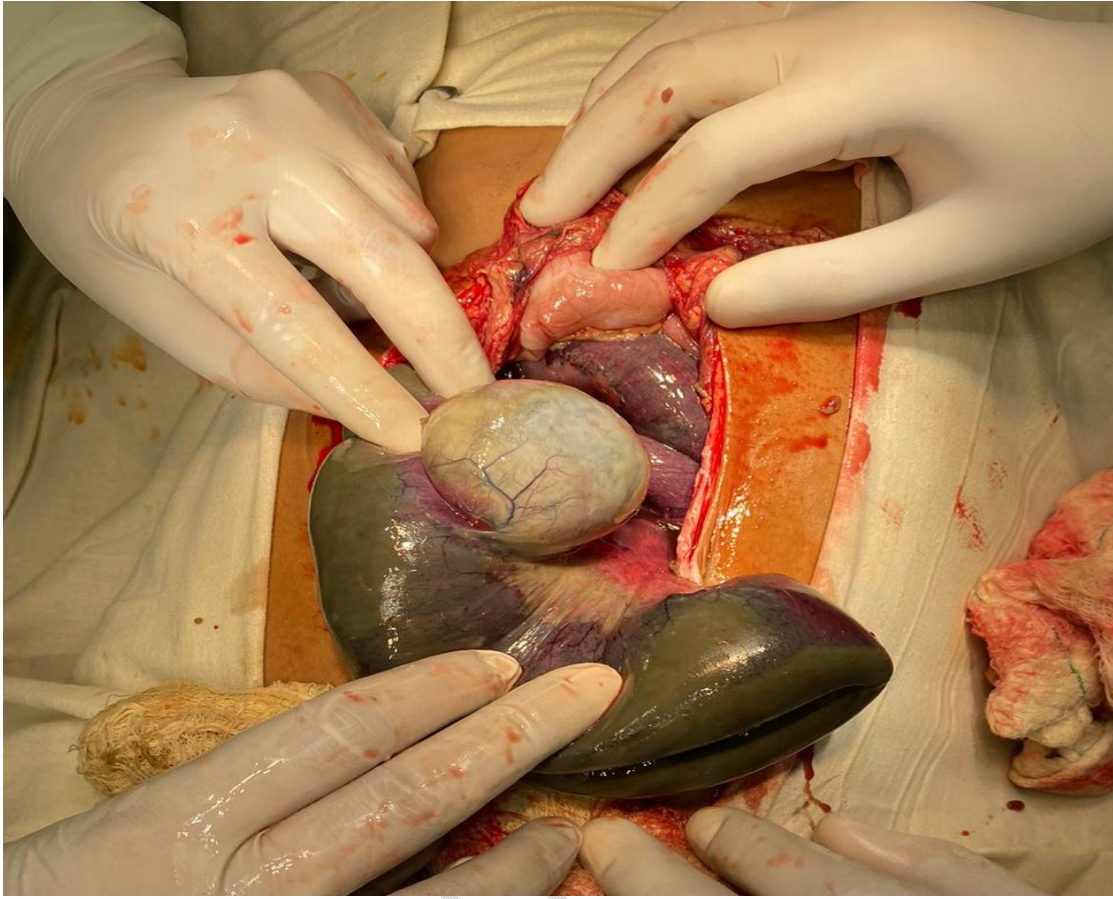


Fig 2 - Mesenteric Cyst with Gangrenous bowel segment on laparotomy.

UNDER P...

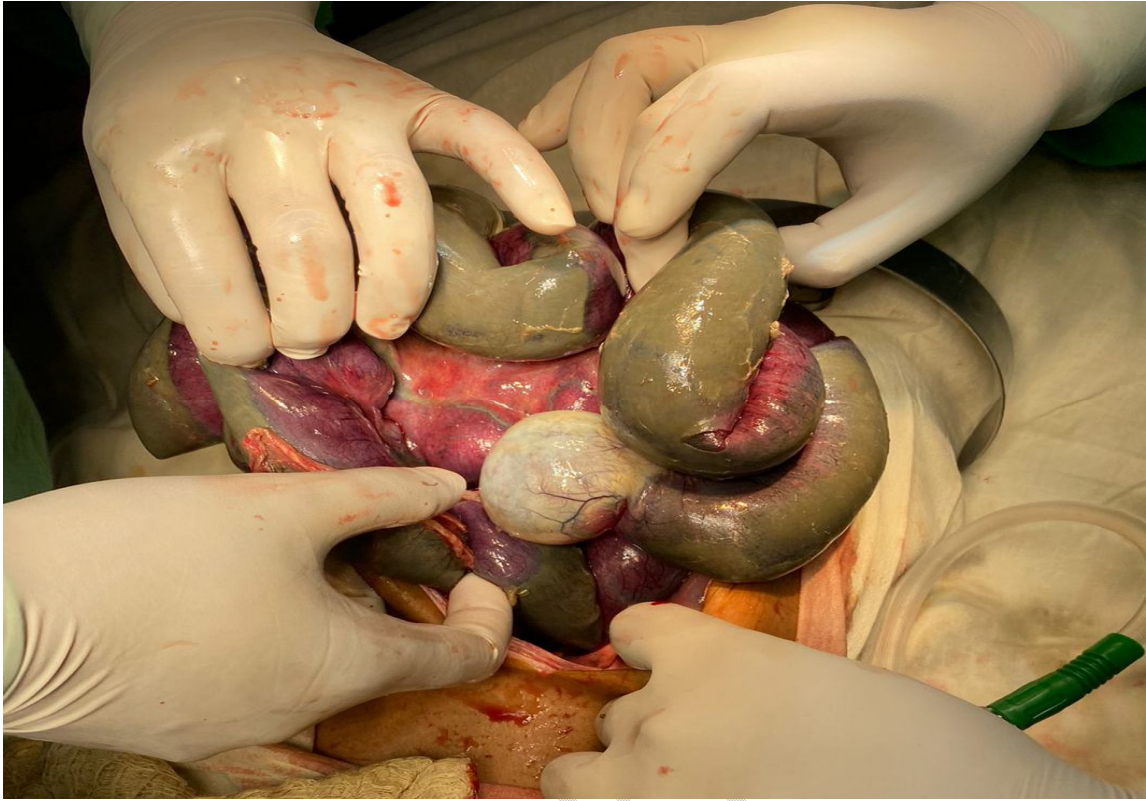


Fig 3- Torsion of bowel segment containing mesenteric cyst.

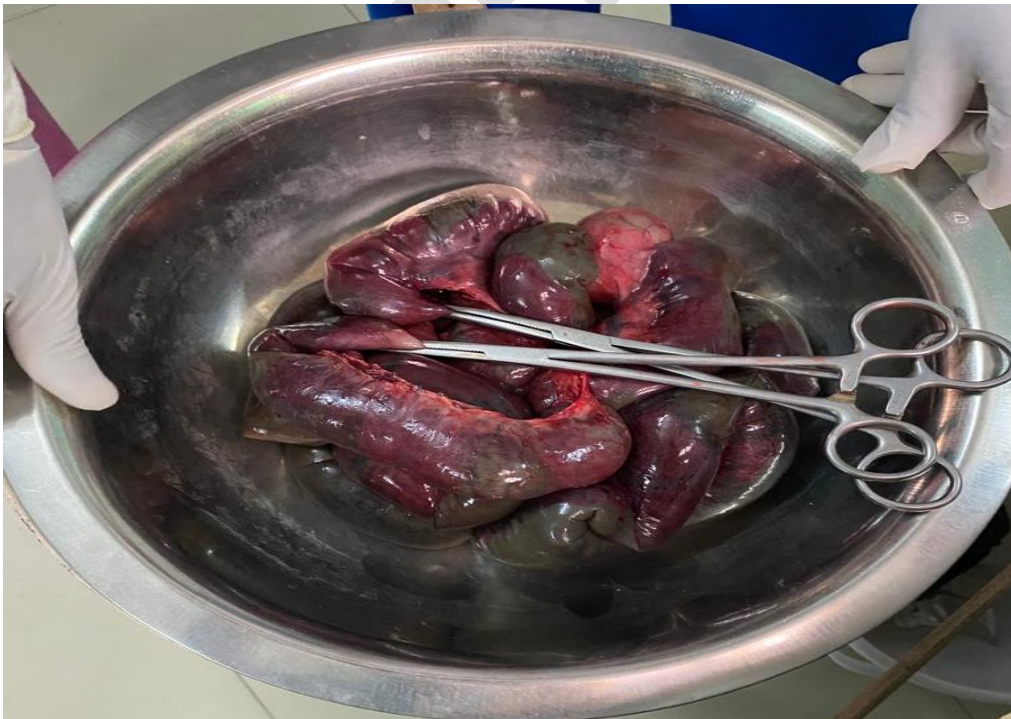

Fig 4- Resected portion of bowel with cyst.

Resection of the gangrenous bowel segment containing the mesenteric cyst was done (approximately 160 cm) with closure of the distal end of the left over terminal ileum (about 5cm from ileo-caecal junction) and an end jejunostomy was performed. PVC drain placed at the pelvic region and the abdomen was closed back. The patient received 1 unit of PRBC intra-operatively. The patient was shifted to paediatrics Intensive care unit and was kept on mechanical ventilation, on Dopamine, Dobutamine and Adrenaline as the patient was in shock. Patient was extubated on day 3 and jejunostomy was functional from 5th post-operative day. The patient was kept NPO for 5 days, and nasogastric tube was removed on 5th post-operative day, and was orally allowed. Drain was removed on 6th post-operative day. Dyselectrolytemia was present post-operatively, which eventually was corrected. Specimen of the resected portion of the bowel with cyst was sent for Histopathological examination. Gross examination showed glistening, grayish white cyst with prominent veins. Cut section showed caseous material with haemorrhagic fluid. Microscopically, cyst wall showed scattered epithelioid histiocytes, ill-defined granuloma with caseous necrosis. A diagnosis of tubercular mesenteric cyst was made and the patient is presently on anti-tubercular therapy.

UNDER PEER REVIEW

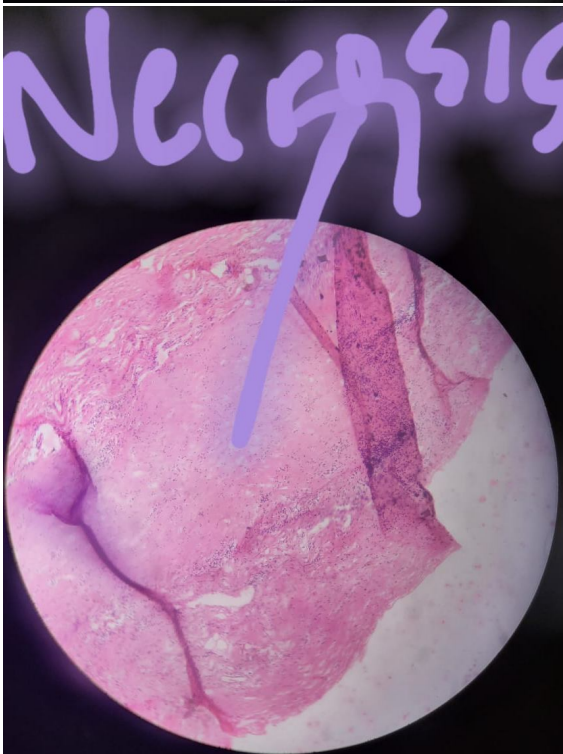
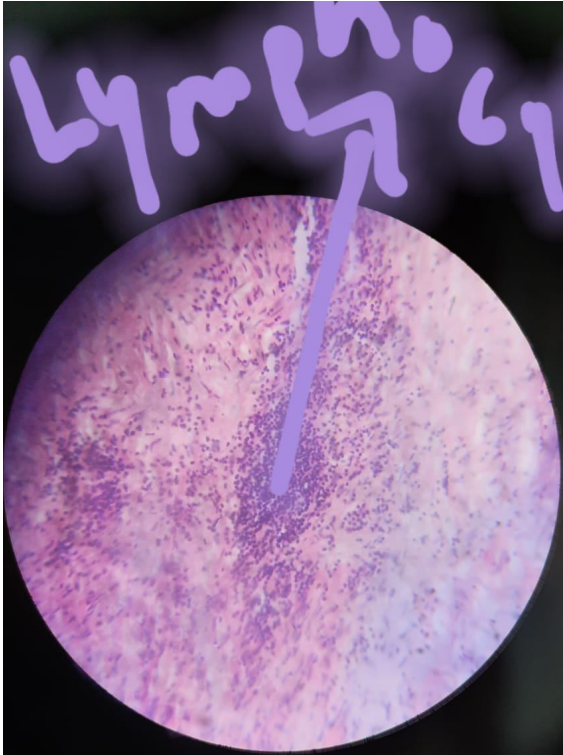


Fig 5- HPE showing lymphocytosis

Fig 6- HPE showing caseous necrosis

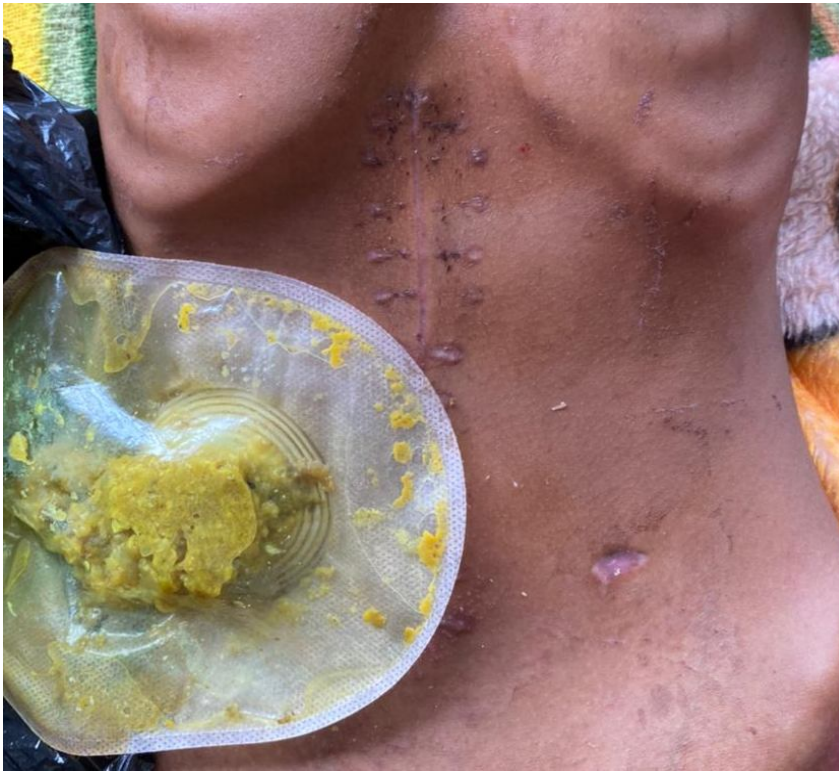

Fig 7- Present day status of abdominal site.

Discussion:

Mesenteric cysts are a rare surgical condition. Italian anatomist Benevanni first described this entity performing an autopsy in an 8-year-old boy in 1507, while Rokitansky published the first accurate description of a chylous mesenteric cyst in 1842 and Tillaux performed the first successful surgery for a cystic mass in the mesentery in 1880.

Mesenteric cyst may occur in the mesentery of either the small intestine (60%) or the colon (40%). They can be chylolymphatic, enterogenous, urogenital remnant, dermoid. Mesenteric cysts can be simple or multiple, unilocular or multilocular, and they may contain haemorrhagic, serous, chylous, or infected fluid. They can range in size from few millimetres to attaining huge size. Aetiology of mesenteric cyst is uncertain. The most accepted theory as proposed by Gross, is benign proliferation of ectopic lymphatics in the mesentery that lack communication with the remainder of the lymphatic system.⁴ They are often asymptomatic and found incidentally while patients are undergoing work-up or receiving treatment for other conditions, such as appendicitis, small bowel obstruction, or diverticulitis, although patients may present with lower abdominal pain and symptoms that are frequently associated with other abdominal conditions. The most common presentation is of a painless abdominal swelling with characteristic physical signs; there is a fluctuant swelling near the umbilicus, the swelling moves freely in a plane at right angles to the

attachment of the mesentery (Tillaux's sign), there is a zone of resonance around the cyst. Complications include torsion of the portion of mesentery containing the cyst, rupture and spillage of infective fluid, haemorrhage, infection, herniation of bowel into an abdominal defect.⁵

Mesenteric cyst should be evaluated with complete history, thorough clinical examination, radiological investigations (radiographs, ultrasound, Computed tomography) to reach a provisional diagnosis. The diagnosis is proven on laparotomy and has to be histologically confirmed. Treatment of choice for chylolymphatic cyst is enucleation since this type of cyst has its own blood supply. Enterogenous cyst has a common blood supply with the bowel, therefore, removal of the cyst entails resection of the related portion of intestine. Bowel resection may be required in case of gangrenous segments. If enucleation or resection is not possible because of its location deep within the root of mesentery, then partial excision with marsupialisation of the remaining cyst into the abdominal cavity can be done. However, if this procedure is done, then the cyst lining should be sclerosed with 10% glucose solution, diathermy, tincture of iodine to minimise recurrence. Once removed, mesenteric cysts rarely recur, and patients have an excellent prognosis. Malignant cysts occur in less than 3% of cases.

The advent of laparoscopic surgery has allowed resection of these cysts to be achieved without full laparotomy. Laparoscopic exploration is done using four ports after insufflation with Veress needle and excision of cyst is done using cautery scissors and blunt dissection. Endobags are then used to retrieve the cyst.

Conclusion:

In our case, the patient being 10 years of age, must have asymptomatic mesenteric cyst initially, complicated by torsion and severe abdominal pain. Patient presented to the emergency late, at a time where there was vascular compromise.

References:

1. KURTZ RJ, HEIMANN TM, BECK AR, HOLT J. Mesenteric and Retroperitoneal Cysts. *Ann Surg.* 1986 Jan;203(1):109–12.
2. Swartley WB. MESENTERIC CYSTS*. *Ann Surg.* 1927 Jun;85(6):886–96.
3. O'Brien MF, Winter DC, Lee G, Fitzgerald EJ, O'Sullivan GC. Mesenteric cysts — A series of six cases with a review of the literature. *Ir J Med Sci.* 1999 Oct;168(4):233–6.
4. Knowles CH. The peritoneum, omentum, mesentery and retroperitoneal space. In: Williams NS, O'Connell PR, McCaskie AW, editors. *Bailey and Love's short practice of surgery.* 27th ed. 2018. p. 1047–66.
5. Swartley WB. MESENTERIC CYSTS* OF PHILADELPHIA, PA. FROM THE DEPARTMENT OF SURGERY OF THE GERMANTOWN DISPENSARY AND HOSPITAL.

Ethical approval:

Not required

UNDER PEER REVIEW