

Inadvertent Gallbladder stenting during Endoscopic management of Choledocholithiasis detected during laparoscopic cholecystectomy: A Case Report

Abstract:

Endoscopic retrograde cholangiopancreatography (ERCP) is the standard management protocol for choledocholithiasis, which more often than not involves a placement of stent in the common bile duct. Here we present a case of inadvertent stenting of the cystic duct and gallbladder during ERCP for choledocholithiasis which was detected during laparoscopic cholecystectomy. A 38 year old lady presented with jaundice and right upper quadrant pain, diagnosed with choledocholithiasis, underwent ERCP with stenting and stone extraction. After 6 weeks, she underwent laparoscopic cholecystectomy, when it was noticed that the biliary stent was inadvertently placed into the cystic duct and gallbladder. The stent was removed laparoscopically through a rent in the gallbladder and cystic duct stump clipped. We report this case to enhance awareness amongst surgeons regarding the unintended location of a biliary stent.

Keywords: Gallbladder stenting, choledocholithiasis, cholecystectomy, ERCP

Introduction:

The prevalence of gall stones is quite high in the general population, being as high as 15%. Of these, 10-18% are found to have common bile duct (CBD) stones [1]. Most CBD stones are secondary having migrated from the gallbladder. A possibility of CBD stone must be excluded prior to laparoscopic cholecystectomy. Since the introduction of endoscopic retrograde cholangiopancreatography (ERCP) over 40 years ago, the ability to tackle CBD stones with minimal complications has improved [2]. Though complications such as pancreatitis, haemorrhage, viscous perforation exists following ERCP [3], yet those of stent migration, wrongful stenting into the cystic duct are quite rare. **Reference to be quoted**

Here we present a rare case of inadvertent biliary stenting of the cystic duct and gallbladder following ERCP for choledocholithiasis, which was detected during subsequent laparoscopic cholecystectomy.

Case Report:

A 38 year old lady presented with right upper abdominal pain and jaundice since 10 days with similar complaints in the past. On examination she was icteric, with normal vital signs. There was tenderness over the right hypochondrium with no features of peritonitis. **Initial evaluation** (What Evaluations?) and magnetic resonance cholangiopancreatography (MRCP) revealed cholelithiasis and choledocholithiasis with a distal CBD calculus of size 12 mm as showed in figure 1. She underwent ERCP with stone extraction and biliary stenting with no adverse events. Following the procedure patient was relieved of symptoms and discharged to follow up for cholecystectomy.

She was readmitted after 6 weeks with the plan for laparoscopic cholecystectomy. Repeat ultrasonography revealed contracted gallbladder with cholelithiasis and no CBD stones and stent in situ in the CBD. She underwent the standard 4 port laparoscopic cholecystectomy. Intraoperatively, there was minimal adhesions in the region of Calot's triangle as shown in figure 2. During Calot's dissection, the cystic duct was found rigid. It was observed that the biliary stent was present within the cystic duct and entering into the gallbladder. It was removed via a rent in the gallbladder as shown in figure 3, following which the cholecystectomy was completed. Postoperative period was uneventful and patient was discharged to follow up on post operative day 3.

Figure 1: MRCP showing CBD calculus

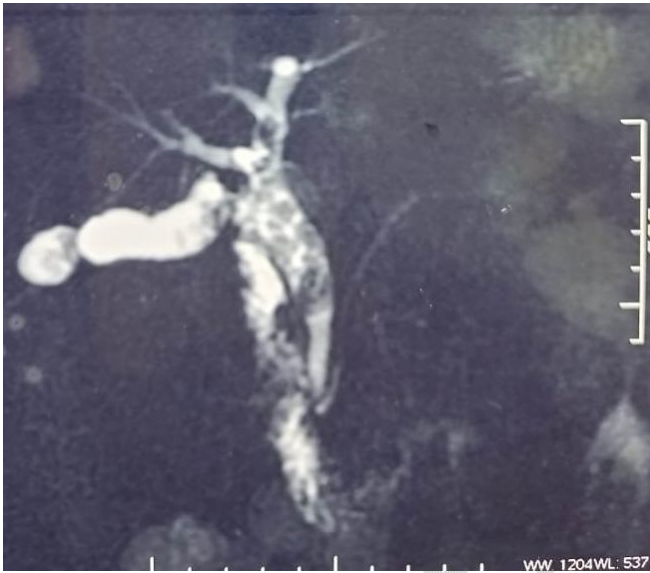
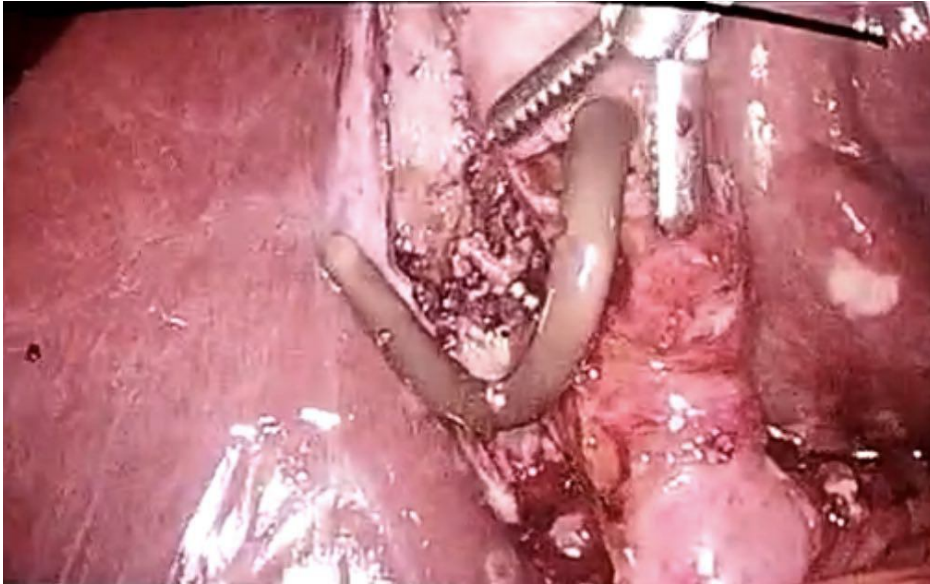


Figure 2: Intraoperative photograph showing adhesions in the region of Calot's triangle

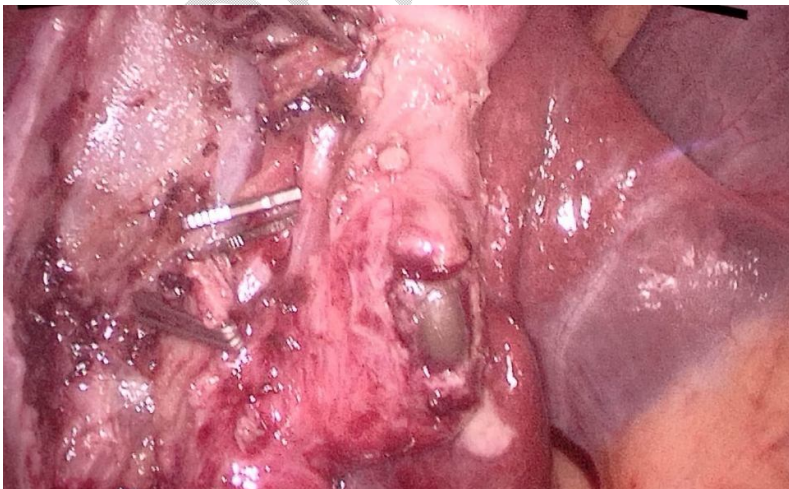

Figure 3: Intraoperative photograph showing the removal of the stent through the gallbladder



Discussion:

ERCP with biliary stenting is now the standard of care as the first line management for certain cases of choledocholithiasis. It involves either a sphincterotomy or balloon dilation of the common bile duct followed by sweeping of the stones [2]. A biliary stent is usually placed to prevent recurrence or stricture. Such patients after ERCP are candidates for laparoscopic cholecystectomy either within the first 48 hours or after 6 weeks, although there are varied guidelines [4]. With many documented complications of ERCP, some are rare and less understood [5]. Of these inadvertent biliary stenting into the cystic duct and gallbladder is one such complication **with none to very few cases reported. (References of few cases reportede must be quoted)**

Our case describes this complication of inadvertent biliary stenting into the cystic duct and gallbladder, which was later detected during laparoscopic cholecystectomy. Although this is not a fatal complication, it is important for the surgeon to be aware of such occurrences as it can pose trouble while ligating the cystic duct during cholecystectomy. Should a surgeon encounter such a finding intraoperatively, it is best tackled by stent extraction laparoscopically by a rent in the gallbladder, followed by completing the cholecystectomy as depicted in our case report. If identified preoperatively by means of any radiological investigation, a repeat ERCP and stenting may be tried to reposition the stent without any adverse consequences.

Conclusion:

Awareness among surgeons regarding the complication of inadvertent biliary stenting into the cystic duct and gallbladder is necessary to avoid intraoperative surgical surprises during interval laparoscopic cholecystectomy following ERCP for choledocholithiasis.

References:

1. Martin DJ, Vernon DR, Toouli J. Surgical versus endoscopic treatment of bile duct stones. *Cochrane Database Syst Rev* 2006; : CD003327
2. Al-Haddad M. ERCP for common bile duct stone extraction: Sphincterotomy, balloon dilation, or both?. *Saudi J Gastroenterol* 2015;21:181-2
3. Freeman ML, Nelson DB, Sherman S, Haber GB, Herman ME, Dorsher PJ, Moore JP, Fennerty MB, Ryan ME, Shaw MJ, Lande JD, Pheley AM. Complications of endoscopic biliary sphincterotomy. *N Engl J Med*. 1996 Sep 26;335(13):909-18. doi: 10.1056/NEJM199609263351301. PMID: 8782497
4. Friis C, Rothman JP, Burcharth J, Rosenberg J. Optimal Timing for Laparoscopic Cholecystectomy After Endoscopic Retrograde Cholangiopancreatography: A Systematic Review. *Scand J Surg*. 2018 Jun;107(2):99-106. doi: 10.1177/1457496917748224. Epub 2017 Dec 26. PMID: 29277136.
5. Talukdar R. Complications of ERCP. *Best Pract Res Clin Gastroenterol*. 2016 Oct;30(5):793-805. doi: 10.1016/j.bpg.2016.10.007. Epub 2016 Oct 27. PMID: 27931637.

Note:

- i. **Some recent references need to be quoted by the author.**
- ii. **References related to the case study needs to be reflected in the manuscript.**