

Original Research Article

Evaluation of Autologous Plasma Gel in Tear Trough Deformity

Abstract

Background: Plasma gel is a gelatinous substance made of proteins that have been gelled together and includes fibrin, which gives the formula more firmness and resistance than regular platelet-rich plasma. The aim of this work was to evaluate the safety and efficacy of autologous plasma gel injection in treatment of tear trough deformity.

Methods: This study was carried out on 10 female patients presented with tear trough deformity without prior cosmetic therapy or performed any facial surgery. [The participants](#) ~~Female patients were~~ received two sessions of autologous plasma gel injection at [2- week interval](#).

Results: There was statistically significant improvement (decrease) in Tear Trough Rating Scale after intervention compared to before intervention ($P=0.004$). Regarding patient satisfaction after treatment, [the all](#) patients showed various degree of satisfaction as follows: [there was any patient](#) very satisfied, 2 patients (20%) [were](#) satisfied, 4 patients (40%) [were](#) neutral, 3 patients (30%) [were](#) dissatisfied, and 1 patient (10%) [was](#) very dissatisfied.

Conclusions: The present study showed that plasma gel was safe and effective in the treatment of Tear Trough Deformity. Plasma gel give significantly better outcome as regard global improvement, complications and patient satisfaction.

Keywords: Autologous Plasma Gel, Tear Trough Deformity, Efficacy, Platelet Rich Plasma

Comment [BO1]: It will be good to add how the results were obtained in the methods, i.e. how you determined efficacy and safety

Comment [BO2]: Replace with "no patient was very satisfied"

Introduction:

A natural dip known as a tear trough (TT) extends inferolaterally from the medial canthus to the midpupillary line. There are many topographically distinct kinds of TT deformity because of the complex anatomies of the suborbital area and the multivariate anatomical aetiology of the condition ^[1]. Palpabromalar grooves (PMg), lower eyelid bags, anteromedial cheek deficit, cheek laxity, malar festoons, and lower eyelid laxity are all kinds of TT malformation ^[2].

TT deformity is a significant cosmetic issue that causes an undesirable, depressed, and worn-out expression that becomes worse with age ^[3]. An important phase that includes regaining youthful look is correcting TT malformation. Additionally, to assisting in maintaining a more youthful look, it will almost certainly have favourable effects on everyday activities ^[4, 5]. The TT deformity may be corrected using a variety of surgical and nonsurgical methods, but ~~regret~~regrettablyfully, most of these methods do not completely repair this deformity and some can make it worse ^[6].

One method for treating tear trough deformities and improving cosmetic results that ~~was~~ere previously only possible via surgery is facial soft tissue augmentation ^[7]. Bovine collagen and hyaluronic acid are two common injectable fillers. Despite having many benefits, these drugs ~~are expensive~~have a high price, and they pose a danger of inflammation leading to neurovascular damage, and ~~the risk~~chance of blindness ^[8].~~Due to these drawbacks, we~~So that promoted ~~us~~to conducted the current study to assess the safety and efficacy of polyactic acid thread injection and ~~autologus~~autologous plasma gel injection alone versus combination in tear trough deformity ^[9].

Plasma gel is a gelatinous substance made of proteins that have been gelled together and includes fibrin, which gives the formula more firmness and resistance than regular platelet-rich plasma^[10]. The activation of platelet-poor plasma by the addition of a clotting cascade

Comment [B03]: Did you utilize polyactic thread injection in this study? If so, it should be stated clearly in the methods

stimulator, such as calcium chloride, calcium gluconate, or thrombin, and/or the application of heat results in the formation of the plasma gel^[11].

The aim of this work was to evaluate the safety and efficacy of autologous plasma gel injection in treatment of tear trough deformity.

Patients and Methods:

This study was carried out on 10 female patients presented with tear trough deformity without prior cosmetic therapy or performed any facial surgery and aged from 25 to 55 years old. All patients presented at the were collected from Outpatient Clinic of Dermatology and Venereology Department, Tanta University Hospitals, from September 2019 to September 2020.

After receiving authorization from Tanta University's Ethical Committee, the research was carried out. The patients provided signed permission after being fully briefed.

Exclusion criteria were pregnancy, breast feeding, below 25 years or above 55 years, with chronic illness as hepatic insufficiency or hepatitis, chronic renal failure, cardiovascular diseases, thyroid disorders, or cancer, smokers, having a history of syncope during or just after venipuncture, maybe brought on by a nervousness of getting an injection or by an excessive vasovagal tone, history of keloid formation, having immunosuppression, receiving therapy that causes absolute or relative immunosuppression, having a thrombophilic or pro-coagulative disorders, with history of bleeding or clotting disorders or platelet count less than 100,000/ml, any infectious disease, using non-steroidal anti-inflammatory drugs, systemic corticosteroids, anticoagulants such as aspirin, warfarin, isotretinoin, with hemoglobin less than 12 mg/dl for females and 14, and with over-abundance of skin, requiring removal.

Female patients were received two sessions of autologous plasma gel injection at 2- week interval.

Comment [BO4]: Is there a reason for using only female patients? Also, the sample size is quite small. Any justification?

Comment [BO5]: Any reason for excluding patients <25 and >55 years?

Comment [BO6]: ???

All patients were subjected to complete medical history taking, full clinical examination, dermatological examination and clinical assessment.

Hirmand Classification System^[12]

Volume loss in Class I patients is restricted medially to the TT. Additionally, the central cheek may experience some flattening in these individuals. In addition to the medial orbital region, class II patients may show volume loss in the lateral orbital region. They may also have moderate volume insufficiency in the medial cheek and flatness of the central upper cheek. Patients in class III have a complete depression that extends from medial to lateral sides of the orbital rim, circumferentially.

Procedure of study

Lidocaine 5% topical anaesthetic cream was put to the TT after the photographs were taken, and it was left there for 15 minutes.

Preparation of plasma gel: Ten milliliter of each participant's ~~10 mL of~~ venous blood was drawn and placed in sterile tubes with anticoagulation (sodium citrate 1:10). HettichRotofix 32. A centrifuge (Tuttlingen, Germany) centrifuged the blood sample at 3000 rpm for 15 minutes, separating it into three layers: buffy coat, plasma supernatant, and RBCs at the bottom. For a two-part plasma sample, consisting of the top two thirds of PPP and the bottom one third of PRP, the plasma supernatant was centrifuged once more at 1500 rpm for an additional five minutes. To avoid mixing, it was carefully avoided to shake the tubes. First, gently aspirate the top two thirds (PPP) to prepare them for activation using calcium gluconate 10% at a ratio of 0.01 mL per 1 mL of PPP. It was then split into two 1.0 mL syringes, heated for at least one minute in a hot water bath between 60 and 100°C, and then refrigerated for at least one minute in a cold bath between 0 and 8°C. PPP was finally changed into a viscous gel.

Comment [B07]: Was this done under aseptic conditions?
What instrument was used in taking the photograph?

Comment [B08]: What is PPP?

Technique of injection of plasma gel: Under an occlusive covering for 15 minutes, a topical anaesthetic cream (5% Lidocaine) was administered superficially to the infraorbital area. The "serial puncture method" or the "push technique" was used to inject 1-2 mL of plasma gel suprapariosteally, 1 cm under the orbital rim, to correct the TT deformity. In order to enhance the gel's cushioning by native soft tissue, the injection plane was suprapariosteal. In order to protect the neurovascular bundle from harm, caution must be taken during injecting near the infraorbital foramen. In the "serial puncture method," a 1 mL insulin syringe was used to gently massage the TT to adapt to the morphology of the surrounding tissues after injecting a tiny amount of PPP gel suprapariosteally into the TT deformity of the infraorbital region. To avoid injecting near any obvious blood vessels, care was taken. Plasma gel was administered in the direction of the TT medially and at the reverse direction laterally in participants who complained of total hollowness beneath the eyes. The patients were told not to massage or apply prolonged pressure to the treated region for a week.

Comment [BO9]: It is important that the same method was used to administer the plasma gel, to reduce bias

Clinical assessment

Tear Trough Rating Scale (TTRS): A measure called the tear trough rating scale (TTRS) was used to determine how much the tear trough deformity has improved. It includes the following items, Trough depth (measured as the distance between the anterior lacrimal crest and the depth of the trough; 1 point is awarded for each millimetre of depth).

Comment [BO10]: Would be nice if the TTRS was presented in a tabular form rather than prose

Although hyperpigmentation and dyspigmentation do not directly affect the depth of the trough, they do provide the impression of depth: One score for no hyperpigmentation, two points for mild pigmentation, three points for moderate pigmentation, and four points for intense or severe hyperpigmentation.

Nasal fat pads/pockets prolapse was graded as: one point for mild, two points for Moderate, and three points for ~~S~~evere prolapse.

According to the Glogaus scale, rhytidosis of the skin of the lower eyelid was graded as mild, moderate, advanced, and severe; 1+ receives 1 point, and 4+ receives 4 points.

Global assessment for degree of improvement by three blinded dermatologist^[5]:

Standardized global images are subjected to digital image analysis to calculate the proportion of change using a four-point grading system as follow: 0= (No improvement (0-25%), 1= Fair improvement (25%-49%), 2=Good improvement (50%-75%), 3=Excellent improvement (>75%).

Skin texture and homogeneity: Using a five-point scale based on the percentage of alteration in the smoothness of the surface of skin and the homogeneity of its colour, the extent of improvement in the skin's uniformity and texture: Much worse if worsening is more than 25%, worse if the deterioration is less than 25%, somewhat improved if improvement is between 25% and 50%, and greatly improved if recovery is greater than 50%.

Statistical analysis

The SPSS v25 statistical analysis programme was used. For the same group, paired Student's t tests were used to compare quantitative data that were provided as mean and standard deviation (SD). Frequency and percentages (%) were used to illustrate qualitative variables. Significant results were defined as two tailed P values <0.05.

Results:

Table 1 shows age, clinical assessment by Hirmand classification before intervention, TTRS before and after intervention in patients.

Table 1: Age, clinical assessment by Hirmand classification before intervention, TTRS before and after intervention in patients

		Patients (n = 10)
Age (years)		34.60± 7.29
Hirmand classification	Class I	3(30.0%)
	Class II	4(40.0%)
	Class III	3(30.0%)
TTRS before		7.50± 2.17

TTRS after intervention	6.2± 1.97
--------------------------------	-----------

Data are presented as mean ± SD or frequency (%), TTRS: Tear Trough Rating Scale

There was statistically significant improvement (decrease) in Tear Trough Rating Scale after intervention compared to before intervention (P=0.004). Table 2

Table 2: Tear Trough Rating Scale (TTRS) before and after intervention in Patients

	TTRS beforeintervention	TTRS afterintervention	P-value
Group B	7.50± 2.17	6.2 ± 1.97	0.004*

Data are presented as mean ± SD or frequency (%), *: significant p value, TTRS: Tear Trough Rating Scale

Table 3 shows global improvement scale and skin texture and homogeneity in the studied patients.

Table 3: Global improvement scale and skin texture and homogeneity in the studied patients

Global improvement scale	Patients (n = 10)	
	No.	%
Excellent improvement (>75%)	0	0.0%
Good improvement (50-74%)	2	20.0%
Fair improvement (25 - 49%)	1	10.0%
No improvement (25%)	7	70.0%
Skin texture and homogeneity (%)		
Slightly improved	50.0%	
Improved	30.0%	
Greatly improved	20.0%	

Table 4 shows side effects in the studied patients.

Table 4: Side effects in the studied patients

Side effects		Patients (n = 10)	
		No.	%
Pain	No	1	10.0%
	Mild	9	90.0%
	Moderate	0	0.0%
Swelling	No	4	40.0%
	Minimal	0	0.0%
	Moderate	6	60.0%
Bruising	No	7	70.0%
	Yes	3	30.0%

Comment [BO11]: Kindly state in the methodology how these were elicited. What tool was used to determine pain, swelling and bruising?

Table 5 shows patient satisfaction.

Table 5: Patient satisfaction

Patient satisfaction	Patients (n = 10)	
	No.	%
Very satisfied	0	0.0%

Satisfied	2	20.0%
Neutral	4	40.0%
Dissatisfied	3	30.0%
Very dissatisfied	1	10.0%

39-years old female with TTD before treatment with plasma gel injection. And after 3 months from treatment, showing good improvement. Figure 1

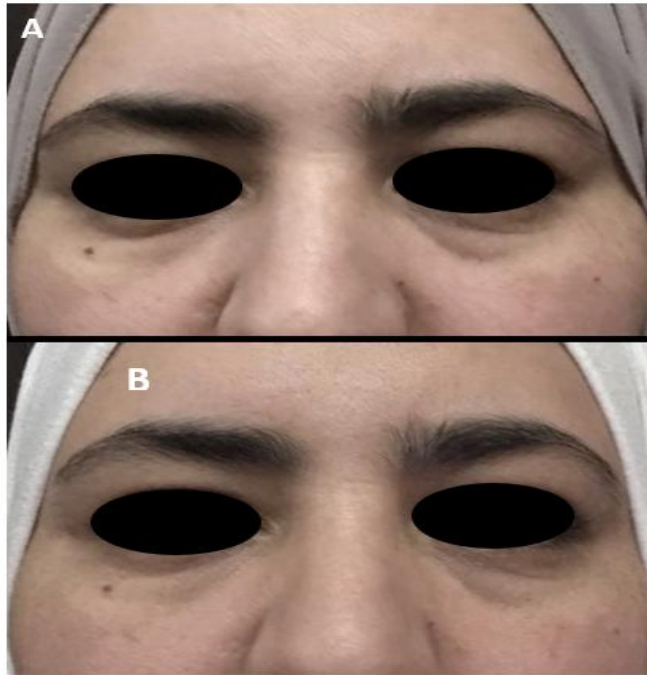

Figure 1: (A): Before treatment with plasma gel injection. (B): After 3 months from treatment, showing good improvement

46-years old female with TTD before treatment with plasma gel injection and after 3 months from treatment, showing fair improvement. Figure 2

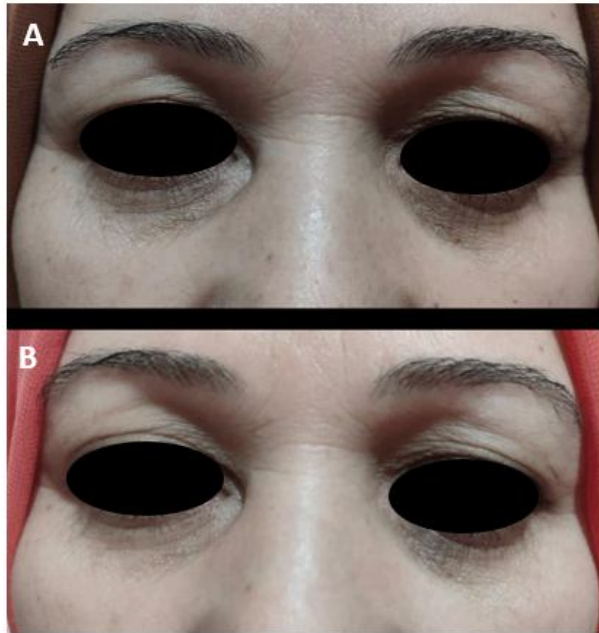


Figure 2: (A): Before treatment with plasma gel injection. (B): After 3 months from treatment, showing fair improvement

Discussion

Although the TT deformity is a significant aesthetic problem, its specific cause is still unknown. But a variety of variables, including gender, congenital or aging-related maxillary hypoplasia, flexibility of the periorbital retention ligaments, cutaneous elastosis, structural alterations in the superficial and/or deep fat compartments, and a particular genetic susceptibility have been reported^[13].

In the plasma gel group, the mean TTRS before and after intervention was 7.50 ± 2.17 and 6.2 ± 1.97 respectively. There was statistically significant improvement (decrease) in Tear Trough Rating Scale after intervention compared to before intervention in group (B) with p value was 0.004.

Neinaa et al^[14]'s study comparing the effectiveness of PRP gel vs platelet-poor plasma gel in infraorbital rejuvenation provides evidence for this. Injections of PPP gel in the right infraorbital area (Group A) and PRP in the left infraorbital region (Group B) were used to treat 68 females who had dark circles and/or TT deformity. They had three therapy sessions separated by two weeks, and they were monitored every month for three months. Both groups had substantial clinical improvements, as shown by a decrease in the extent of hyperpigmentation and the tear trough grading scale. Obviously, Group A showed more clinical and dermoscopic improvements than did Group B. Therefore, it can be said that PPP gel and PRP were both clinically successful treatments for improving the appearance of the infraorbital area. Additionally, PPP gel appears to be a much superior therapeutic approach than PRP.

This is consistent with the findings of Doghaim et al. ^[5], who assessed the PPP gel's effectiveness in face rejuvenation and discovered a considerable clinical improvement in TTD. However, they did not conduct a comparison investigation and used a limited sample size. The considerable reduction in tear trough deformity depth seen in this research, together with the significant improvement of TTRS, may be attributable to the influence of PDGF, which plays a key role in angiogenesis and collagen remodelling (84). Additionally, it boosts the generation of extracellular matrix components, especially hyaluronic acid, which improves skin tone and gives the appearance of more bright and healthy skin.

Regarding global improvement scale showed that 0% reported excellent improvement, 20% of cases reported good improvement while 10% of them respectively reported fair improvement.

In the present study, regarding skin texture and homogeneity, showed that the mean skin texture and homogeneity in group was 3.50 ± 0.71 . 60% of cases in group B showed slight improvement.

Regarding side-effects we found that mild complications were reported 90% of cases had mild pain, 60% cases had swelling, and 30% cases reported bruising.

Additionally, Neinaa et al. ^[14] showed that PRP and PPP gel adverse effects were minimal and transient in both treatment groups. Tolerable discomfort or pain at the site of injection, transient [edema](#), and ecchymosis were observed more often in group B (PRP) than in group A (PPP gel; with P value >0.001). Apart from local injection site responses like transient discomfort, erythema, and ecchymosis, which may be avoided with sufficient care, both PPP gel and PRP are autologous preparations and free of any major negative effects (such as hypersensitivity reaction or disease transmission).

Additionally, Doghaim et al. ^[5] reported that the observed negative impacts of plasma gel administration sessions were low and temporary in the form of burning sensation, mild pain, erythema, and edoema at the injection site that gradually resolved within a few hours. However, local bruises lasting a few days was noted by two females with facial wrinkles and six people with tear trough deformity. Local bruising was treated with topical anti-thrombotic and anti-edematous cream (Hemoclar) administered twice daily. No patient ever complained fibrosis, irregularity, brittleness, or lumpiness at the treated area.

Regarding patient satisfaction after treatment, all patients showed various degree of satisfaction as follows: there was any patient very satisfied, 2 patients (20%) satisfied, 4 patients (40%) neutral, 3 patients (30%) dissatisfied, and 1 patient (10%) very dissatisfied.

[There are some limitations in this study which future study needs to address. The first is the small sample size and the second is the short period of follow up. It is desirable to find out what the results would be like after 1, 2 or even 5 years.](#)

Conclusions:

The present study showed that plasma gel was safe and effective in the treatment of Tear Trough Deformity. Plasma gel give significantly better outcome as regard global improvement, complications and patient satisfaction.

References:

1. Bagci B. A New Technique for the Correction of Tear Trough Deformity via Filler Injections. *Plast Reconstr Surg Glob Open*. 2018;6:e1901.
2. Peng PH, Peng JH. Treating the tear trough: A new classification system, a 6-step evaluation procedure, hyaluronic acid injection algorithm, and treatment sequences. *J Cosmet Dermatol*. 2018;17:333-9.
3. Ravelli FN, Sandin J, Sakai FDP, Macedo AC, Curi VC, editors. Deep-fill of the tear trough with hyaluronic acid 2012.
4. Ganceviciene R, Liakou AI, Theodoridis A, Makrantonaki E, Zouboulis CC. Skin anti-aging strategies. *Dermatoendocrinol*. 2012;4:308-19.
5. Doghaim NN, El-Tatawy RA, Neinaa YME. Assessment of the efficacy and safety of platelet poor plasma gel as autologous dermal filler for facial rejuvenation. *J Cosmet Dermatol*. 2019.
6. Gawdat TI, Elsherif EAE, Alahmadawy YA, Mostafa YSE. Management of tear trough deformity with and without tear trough-orbicularis retaining ligament complex release in transconjunctival blepharoplasty: a comparative study. *Int J Ophthalmol*. 2019;12:89-93.
7. Carruthers J, Cohen SR, Joseph JH, Narins RS, Rubin M. The science and art of dermal fillers for soft-tissue augmentation. *J Drugs Dermatol*. 2009;8:335-50.
8. Requena L, Requena C, Christensen LH, Zimmermann US, Kutzner H, Cerroni L. Requena L, Requena C, Christensen L, Zimmermann US, Kutzner H, Cerroni L. Adverse

reactions to injectable soft tissue fillers. *J Am Acad Dermatol* 2011;64:1-34. *Journal of The American Academy of Dermatology*. 2011;64.

9. Wong CH, Mendelson B. Facial soft-tissue spaces and retaining ligaments of the midcheek: defining the premaxillary space. *Plast Reconstr Surg*. 2013;132:49-56.

10. Landray MJ, Haynes R, Hopewell JC, Parish S, Aung T, Tomson J, et al. Effects of extended-release niacin with laropiprant in high-risk patients. *N Engl J Med*. 2014;371:203-12.

11. Galindo-Moreno P, Ortiz G, Torrecillas-Martinez L, Fernández-Barbero J, O'Valle F, Wang H-L, et al. Composition of platelet-rich plasma gel: A Western blot analysis. 2016;422:42-50.

12. Hirmand H. Anatomy and nonsurgical correction of the tear trough deformity. *Plast Reconstr Surg*. 2010;125:699-708.

13. Cotofana S, Fratila AA, Schenck TL, Redka-Swoboda W, Zilinsky I, Pavicic T. The Anatomy of the Aging Face: A Review. *Facial Plast Surg*. 2016;32:253-60.

14. Neinaa YM, Hodeib AAE, Morquos MM, Elgarhy LH. Platelet-poor plasma gel vs platelet-rich plasma for infraorbital rejuvenation: A clinical and dermoscopic comparative study. *Dermatologic Therapy*. 2020;33.