

## Original Research Article

# Correlation Between Findings of visual field, Optical Coherence Tomography and Orbital Computerized Tomography in Thyroid Eye Disease with or without Dysthyroid Optic Neuropathy

### **Abstract:**

#### **Purpose:**

The aim of this study is to evaluate the findings of optical coherence tomography, visual field and orbital computerized tomography in thyroid eye disease, correlate the findings with the clinical data for early detection and anticipation of dysthyroid optic neuropathy.

#### **Setting and design:**

This is a comparative observational cross-sectional study that was conducted at the Outpatient Clinic of the Ophthalmology Department of Tanta University Hospital.

#### **Patients and methods:**

This study was carried out on 30 eyes of patients with TED and 15 eyes of age-matched normal subjects. Of the 30 eyes with thyroid associated orbitopathy (TAO) 15 eyes had DON (group 1: TED with DON) and 15 eyes didn't have DON (group 2: TED without DON) and the third group included normal (control) age and gender-matched individuals. For each patient we used OCT for measurement of PRNFL thickness, VF and orbital CT for measurement of amount of proptosis in the three groups.

#### **Results:**

The mean PRNFL thickness was significantly lower in group (1) patients compared to group (2) (p-value = 0.004) and higher in group (1) compared to group (3) (p-value < 0.001) but no statistically significant difference between group (2) and group (3) (p-value = 0.551).

Visual field MD was significantly lower in group (1) patients compared to group (2) (p-value = 0.002) and higher in group (1) compared to group (3) (p-value < 0.001) but no statistically significant difference between group (2) and group (3) (p-value = 0.777).

Amount of proptosis was significantly higher in group (1) compared to group (2). (p value < 0.001), and higher in group (1) compared to group (3). (p value < 0.001) but not statistically significant between group (2) and group (3). (p value = 0.265).

#### **Conclusion:**

Peri-papillary nerve fiber layer act as an auxiliary tool for the early diagnosis of DON, VF testing is considered as reliable indicator of DON  
Amount of proptosis not correlated with severity of DON.

#### **Keywords:**

dysthyroid optic neuropathy, thyroid eye disease, orbital computerized tomography, proptosis, visual field, optical coherence tomography

## **Introduction:**

Thyroid eye disease (TED) is the most common cause of unilateral and bilateral proptosis in adults, accounting for 85% of patients with bilateral proptosis and for 10% to 30% of patients with unilateral proptosis. TED is the most frequent cause of acquired diplopia unrelated to extraocular muscle palsy in adults. While the majority of patients with TED first present with systemic hyperthyroidism, 5% to 25% of patients present to an ophthalmologist before the diagnosis of systemic disease.<sup>1</sup>

Thyroid-associated orbitopathy (TAO) is an autoimmune condition of the orbit which is closely associated with Graves' hyperthyroidism, although either condition may exist without the other. It may antedate, coincide with or follow hyperthyroidism. Assessment of the frequency of the association depends on the method used for detecting TAO; with sensitive methods subclinical TAO can be demonstrated in 70% of patients with hyperthyroidism. The clinical features of the disorder vary from a mild grittiness of the eyes to severe diplopia, loss of vision and disfiguring proptosis.<sup>2</sup> Dysthyroid optic neuropathy (DON) is impairment of optic nerve function due to TAO. This potentially blinding complication occurs in up to 25% of patients with TAO. The most obvious pathological change within the orbit is the enlargement of extraocular muscles.<sup>3</sup>

Although the diagnosis of TAO and DON is based primarily on clinical signs from laboratory test results suggestive of thyroid dysfunction and autoimmunity, imaging studies, such as computed tomography (CT), magnetic resonance imaging (MRI) can also be extremely important in both the diagnosis and clinical or surgical follow-up.<sup>4</sup>

Optical coherence tomography (OCT) is non-invasive, interferometric imaging modality that enables in vivo imaging of the retina in cross-sections. Optical coherence tomography (OCT) has been used to evaluate the thickness of the retinal nerve fiber layer (RNFL) in the anticipation and monitoring of the DON.<sup>5</sup>

Visual field (VF) testing is an important diagnostic tool in the evaluation of patients with various pathologies affecting optic nerve and neuro-ophthalmological diseases. Both manual and automated perimetry have been used extensively for detecting and documenting VF changes secondary to TED-DON.<sup>6</sup>

CT scan, or computed tomography scan, is a medical imaging procedure that uses X-ray to produce cross-sectional (tomographic) images (virtual "slices") of specific areas of a scanned object. CT orbit can also be used to detect degree of extra ocular muscle enlargement and impingement on optic nerve in thyroid orbitopathy.<sup>7</sup>

The aim of this study is to evaluate the findings of optical coherence tomography, visual field and orbital computerized tomography in thyroid eye disease, correlate the findings with the clinical data for early detection and anticipation of dysthyroid optic neuropathy.

## **Patients and methods:**

This cross-sectional study was carried out on 30 eyes of patients with TED who attended ophthalmology outpatient clinic in Tanta University Eye Hospital and 15 eyes of age-matched normal subjects from August 2020 to October 2021. Of the 30 eyes with thyroid associated orbitopathy(TAO) 15 eyes had DON (group 1: TED with DON) and 15 eyes didn't have DON (group 2:TED without DON) and the third group included

normal (control) age and gender-matched individuals.

There is no risk to the participants of the study at all and ethical committee approval from Tanta University was obtained. Full counseling of the participants in this research about the nature of the study was obtained and informed consent was taken.

Patients with history of previous orbital trauma or history of previous orbital surgery were excluded

**Detailed medical and surgical history** was obtained from all the participants followed by a complete ophthalmological examination.

**Optical coherence tomography:** All the study participants underwent OCT imaging using the OCT spectralis (Heidelberg engineering, Heidelberg, Germany) -with use of mydriatic eye drops- with recording of nerve fiber layer thickness in the peripapillary zone. Using the 3.4 mm circular scan centered on the optic disc, the peripapillary retinal nerve fibre layer thickness was measured in the four quadrants and the average RNFL thickness was taken as the main parameter.

**Visual field testing:** Using Humphrey perimetry system with 24-2 strategy:

Standard automated perimetry: (SAP) examinations were obtained using the Humphrey Field Analyzer (Carl-Zeiss Meditec, Dublin, CA; SITA standard strategy, program 24-2).

"CARL ZEISS Humphrey 750i Field Analyzer / HFA II-I" A

visual field was defined as reliable when fixation losses and false-positive and false-negative rates were less than 20%. A visual field defect was defined as having three or more significant points  $P < 0.05$  with at least one of  $P < 0.01$  on the same side of the horizontal meridian in the pattern deviation plot and classified as outside normal limits in the glaucoma hemi field test. All participant underwent VF testing to determine MD and PSD. VF loss was expressed as MD from normal, we used VF mean deviation for analysis of VF affection. visual fields were ranked in order by worsening mean deviation as well as classified into the following categories: primarily inferior defect , primarily superior defect , central defect , scattered defect , enlarged blind spot , and total loss .

**Orbital computerized tomography:** CT was done at CT scanning unit at radiodiagnosis and medical imaging department Tanta university hospital .CT examinations were made in general elective (GE)optima 660(128 multidetector computed tomography MDCT) and a Toshiba aquilion one (320MDCT) with slice thickness of 1-5mm and sharp kernel reconstruction CT processing.

**Amount of proptosis:**

The axial image including the maximal thickness of the lens or intraocular lens implants and passing through the equators of the globes was used for these measurements.

Measurement of proptosis was based on the interzygomatic line which is drawn between the ventral zygomatic borders bilaterally. The distance between the apex of the globe and the interzygomatic line corresponds to the Hertel-index value in millimeters, and values  $\geq 22$ mm or asymmetry greater than 2mm are considered pathologic.

**Statistical analysis:**

Statistical presentation and analysis of the present study was conducted, using the mean, standard deviation, student t- test, Chi-square, Linear Correlation Coefficient and Analysis of variance [ANOVA] tests by (SPSS) software version 20.0. (IBM Corp, Armonk, New York, USA ). A p value less than 0.05 was considered statistically significant.

Unpaired Student T-test was used to compare between two groups in quantitative data.

Chi-square the hypothesis that the row and column variables are independent, without indicating strength or direction of the relationship. Pearson chi-square and likelihood-ratio chi-square.

Linear Correlation coefficient was used for detection of correlation between two quantitative variables in one group.

Analysis of variance [ANOVA] tests. According to the computer program SPSS for Windows. ANOVA test was used for comparison among different times in the same group in quantitative data. .

**Results:**

The mean visual field MD was (-5.451±6.169 db)in group (1), (-0.460±1.454 db)in group (2)and (0.447±0.164 db )in group (3). Visual field MD was significantly was significantly lower in group (1) compared to group (2). (p-value = 0.002) , significantly lower in group (1) compared to group(3).(p value <0.001) but not statistically significant group (2) and group (3) (p-value = 0.777). Table (1) ,figure(1)

Visual field defects in group (1) were primarily inferior in (73.33%) of eyes, primarily superior in (6.67%) of eyes and scattered field defects in (20.00%) of eyes.(table 2)

The mean PRNFL thickness was (86.000±17.578 µm) in group (1), (100.067±6.341µm) in group (2) and (104.333 ± 4.894 µm) in group (3). RNFL thickness was significantly lower in group (1) compared to group (2). (p-value = 0.004) , significantly lower in group (1) compared to group(3).(p value <0.001) but not statistically significant group (2) and group (3) (p-value = 0.551). (Table 3),figure (2)

The mean amount of proptosis was (24.833±2.200 mm)in group (1),(20.453±1.788 mm)in group (2),(19,487±0.609 mm)in group (3). Amount of proptosis was significantly higher in group (1)compared to group (2).(p value <0.001),and in group (1)compared to group (3).(p value<0.001) but no statistically significant difference between group (2) and group (3).(p value=0.265).(table 4) (figure 3)

**Table (1) shows the visual field MD (db)of groups included in the study**

VF MD	Groups			ANOVA		TUKEY'S Test		
	TED with DON	TED without DON	Control	F	P-value	Group 1 and 2	Group 1 and 3	Group 2 and 3
Range	(-20.23) - (-0.18)	(-5.17) - 1.01	0.1- 0.7	11.288	<0.001*	0.002*	<0.001*	0.777
Mean ±SD	-5.451 ± 6.169	-0.460 ± 1.454	0.447 ± 0.164					

VF MD:visual field mean deviation,TED with DON :thyroid eye disease with dysthyroid optic neuropathy

**Table (2) shows types of visual field defects in group (1)**

VF Defect Type		
	N	%
Inferior	11	73.33
Scattered	3	20.00
Superior	1	6.67
Total	15	100.00

**Table (3) :shows the PRNFL thickness (um) of groups included in the study**

PRNFL Thickness	Groups			ANOVA		TUKEY'S Test		
	TED with DON	TED without DON	Control	F	P-Value	Group 1and 2	Group 1 and 3	Group 2and 3
Range	60 – 111	88 - 110	98 - 115	11.098	<0.001*	0.004*	<0.001*	0.551
Mean ±SD	86.000 ± 17.578	100.067 ± 6.341	104.333 ± 4.894					

PRNFL:prepapillary retinal nerve fiber layer

**Table 4 : shows amount of proptosis(mm) in each group of the study**

Amount of Proptosis	Groups			ANOVA		TUKEY'S Test		
	TED with DON	TED without DON	Control	F	P-value	Group 1and 2	Group 1 and 3	Group 2and 3
Range	20.7 - 27.4	18.2 - 24.9	18.7 - 20.3	43.455	<0.001*	<0.001*	<0.001*	0.265
Mean ±SD	24.833 ± 2.200	20.453 ± 1.788	19.487 ± 0.609					

## Discussion:

Thyroid eye disease (TED), also known as Graves' orbitopathy or thyroid-associated orbitopathy, is an autoimmune and inflammatory disorder. The deposition of collagen and glycosaminoglycans in TED results in expansion of the extraocular muscle (EOM) and orbital fat.<sup>8</sup>

DON may present a wide range of symptoms and signs, its diagnosis depends on several clinical features including decreased visual acuity (VA), abnormal visual fields (VF), impaired color and brightness perception, delayed visually evoked potentials, afferent pupillary defects and edema or atrophy of the optic nerve head.<sup>9</sup>

In this study, we attempted to clarify a constellation of clinical and radiologic findings associated with DON to aid in the diagnosis of equivocal cases and develop a safe follow-up schedule for those at risk for developing DON.

In the present study, the mean PRNFL thickness was statistically significant between group (1) and group (2) (p-value = 0.004) and statistically significant group (1) and group (3) (p-value <0.001) but not statistically significant group (2) and group (3) (P-value = 0.551).

This coincides with Luo, et al.<sup>10</sup> study results showing that peripapillary nerve fiber layer act as an auxiliary tool for the early diagnosis of dysthyroid optic neuropathy, the PRNFL thickness was significantly lower in DON group compared to TED without DON patients (P-value=0.004)

In contrast to Wu, et al.<sup>4</sup>, who conduct a study on Forty-four TAO patients including 23 non-DON and 21 DON patients, and 38 healthy participants, there was no significant difference between DON and non-DON group .they found that ganglion cell atrophy and inflammatory oedema co-exist in DON patients.

In the current study, there were significant differences between group (1) and group (2) regarding mean deviation of visual field (P-value=0.002)

In agreement with our study, Mckeag, et al.<sup>11</sup> found that in eyes with DON , visual field was abnormal in 40 out of 56 tested (71%). In eyes without DON visual field was abnormal in two patients out of 16 tested (13%).

Moreover, Visual field defects in group (1) were primarily inferior in (73.33%) of eyes , primarily superior in (6.67%) of eyes and scattered field defects in (20.00%) of eyes , meaning that inferior field defect is the most common.

In agreement with these results, Choi, et al.<sup>12</sup> study included 78 visual fields in of 98 patients with DON , 52 (67%) were inferior defects. Indicating that inferior defect is the most typical TED-DON-associated visual field.

In the present study, amount of proptosis was statistically significant between-group (1) and group (2) (p-value <0.001) and statistically significant between group (1) and group (3) (p-value < 0.001) but not statistically significant between group (2) and group (3) (p-value = 0.265).

In agreement with these results, Guo, et al.<sup>13</sup>, One hundred and forty-five eyes of 75 patients with TED, of which 58 eyes with DON and 70 eyes of 35 healthy controls were included. Amount of proptosis was significantly higher in DON group compared to Don Group and healthy control (p-value<0.05).

This was consistent with Callahan, et al.,<sup>14</sup> . The results of their study indicated that patients with TED–CON had, on average, 1.4mm “greater” measurements on Hertel

exophthalmometry than non-compressive TED patients ( $p < 0.01$ ).

Contrary to these results, Kennerdell, et al.<sup>15</sup> concluded that Optic neuropathy in dysthyroid disease had no direct relation to the degree of exophthalmos. It seemed that the optic nerve could withstand a stretch type of injury in severe degrees of exophthalmos much better than a compression type of injury that occurred in dysthyroid optic neuropathy.

On the contrary of the current study, the study carried out by Metson, et al.<sup>16</sup>, who found that The degree of proptosis does not correlate with the overall severity of disease because patients with poor compliance of the orbital septum may not experience significant proptosis, but can have severe compression at the orbital apex and optic neuropathy.

### **Conclusion:**

Our study indicates that

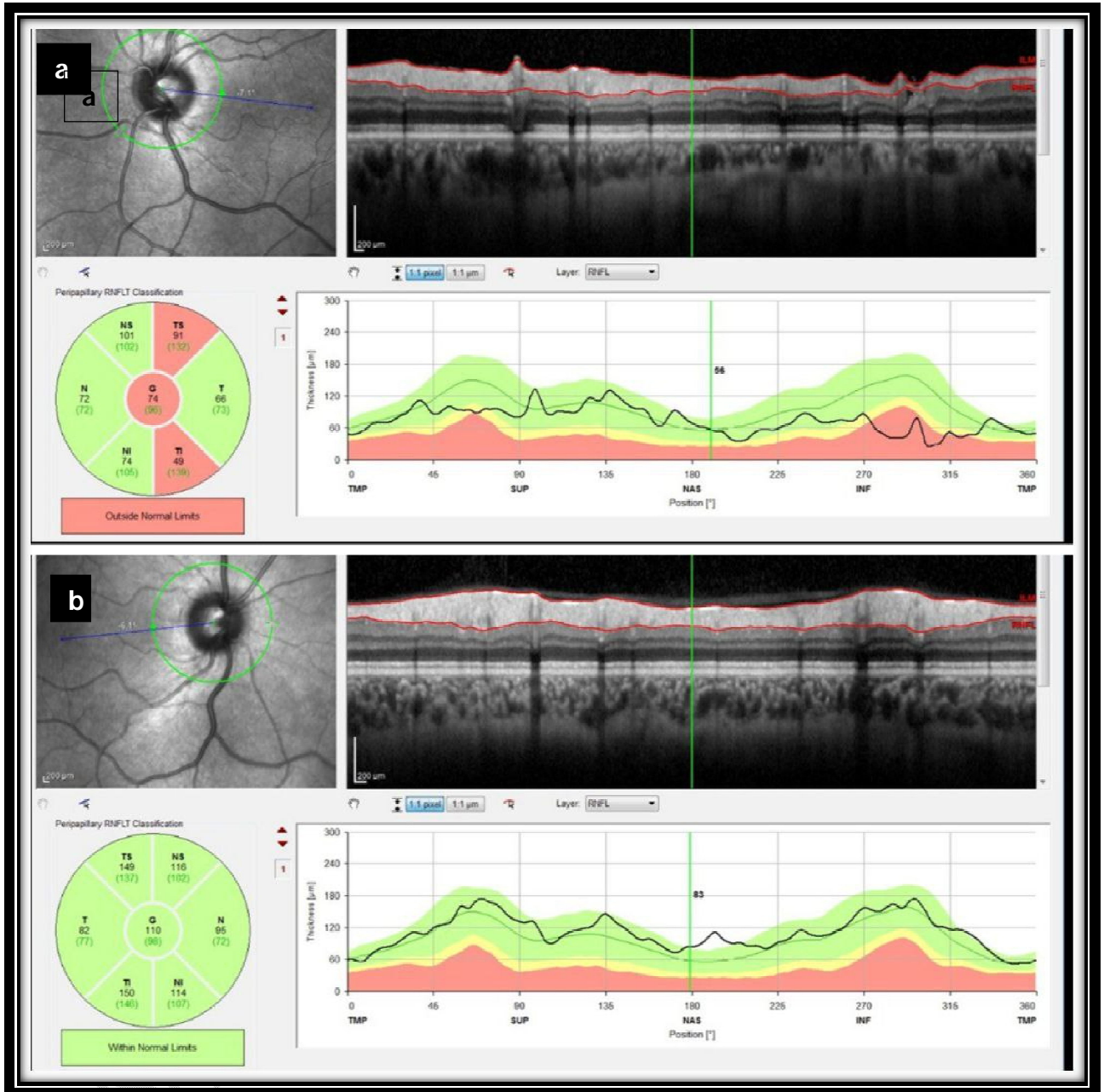
1. Peri-papillary nerve fiber layer act as an auxiliary tool for the early diagnosis of dysthyroid optic neuropathy
2. VF testing is considered as reliable indicator of DON and VF defects resulting from DON are most often inferiorly.
3. Amount of proptosis doesn't correlate with occurrence and severity of DON

### **References:**

1. *Gonçalves ACP, Gebrim EMMS, Monteiro MLR. Imaging studies for diagnosing Graves' orbitopathy and dysthyroid optic neuropathy. Clinics (Sao Paulo). 2012 Nov;67(11):1327–34.*
2. *3. Park K-A, Kim Y-D, In Woo K, et al. Optical coherence tomography measurements in compressive optic neuropathy associated with dysthyroid orbitopathy. Graefe's Arch Clin Exp Ophthalmol = Albr von Graefes Arch fur Klin und Exp Ophthalmol. 2016 Aug;254(8):1617–24.*
3. *Barrett L, Glatt HJ, Burde RM, et al. Optic nerve dysfunction in thyroid eye disease: CT. Radiology. 1988 May;167(2):503–7.*
4. *5. Wu Y, Tu Y, Wu C, et al. Reduced macular inner retinal thickness and microvascular density in the early stage of patients with dysthyroid optic neuropathy. Eye Vis (London, England). 2020;7:16.*
5. *Forte R, Bonavolontà P, Vassallo P. Evaluation of retinal nerve fiber layer with optic nerve tracking optical coherence tomography in thyroid-associated orbitopathy. Ophthalmol J Int d'ophtalmologie Int J Ophthalmol Zeitschrift fur Augenheilkd. 2010;224(2):116–21.*

6. Ferris JD, Dawson EL, Plowman N, et al. Radiotherapy in thyroid eye disease: the effect on the field of binocular single vision. *J AAPOS Off Publ Am Assoc Pediatr Ophthalmol Strabismus*. 2002 Apr;6(2):71–6.
7. Chaganti S, Mundy K, DeLisi MP, et al. Assessment of Orbital Computed Tomography (CT) Imaging Biomarkers in Patients with Thyroid Eye Disease. *J Digit Imaging*. 2019 Dec;32(6):987–94.
8. Trobe JD, Glaser JS, Laflamme P. Dysthyroid optic neuropathy: clinical profile and rationale for management. *Arch Ophthalmol*. 1978;96(7):1199–209.
9. Elyashiv S, Skaat A, Ben Simon G, et al. [Clinical characteristics of dysthyroid optic neuropathy]. *Harefuah*. 2015 Feb;154(2):98-102,137.
10. Luo L, Li D, Gao L, et al. Retinal nerve fiber layer and ganglion cell complex thickness as a diagnostic tool in early stage dysthyroid optic neuropathy. *Eur J Ophthalmol*. 2021;112067212110620.
11. McKeag D, Lane C, Lazarus JH, et al. Clinical features of dysthyroid optic neuropathy: A European Group on Graves' Orbitopathy (EUGOGO) survey. *Br J Ophthalmol*. 2007;91(4):455–8.
12. Choi CJ, Oropesa S, Callahan AB, et al. Patterns of visual field changes in thyroid eye disease. *Orbit*. 2017;36(4):201–7.
13. Guo J, Li X, Ma R, et al. The changes of retinal nerve fibre layer and ganglion cell layer with different severity of thyroid eye disease. *Eye*. 2022;36(1):129–34.
14. Callahan AB, Campbell AA, Oropesa S, et al. The Columbia Thyroid Eye Disease-Compressive Optic Neuropathy Diagnostic Formula. *Ophthal Plast Reconstr Surg*. 2018;34(4):S68–71.
15. Kennerdell JS, Rosenbaum AE, El-Hoshy MH. Apical optic nerve compression of dysthyroid optic neuropathy on computed tomography. *Arch Ophthalmol*. 1981;99(5):807–9.
16. Metson R, Pletcher SD. Endoscopic Orbital and Optic Nerve Decompression. *Otolaryngol Clin North Am*. 2006;39(3):551–61.

## FIGURES



*Figure 1: shows the peripapillary RNFL thickness of both eyes in case of TED. figure a :left eye (with DON) , The average peripapillary RNFL thickness was 74 μm with RNFL thickness outside normal limits in supero-temporal and infero-temporal sectors figure b :right eye (without DON), The average peripapillary RNFL thickness was 110 μm with RNFL within normal limits in all sectors.*

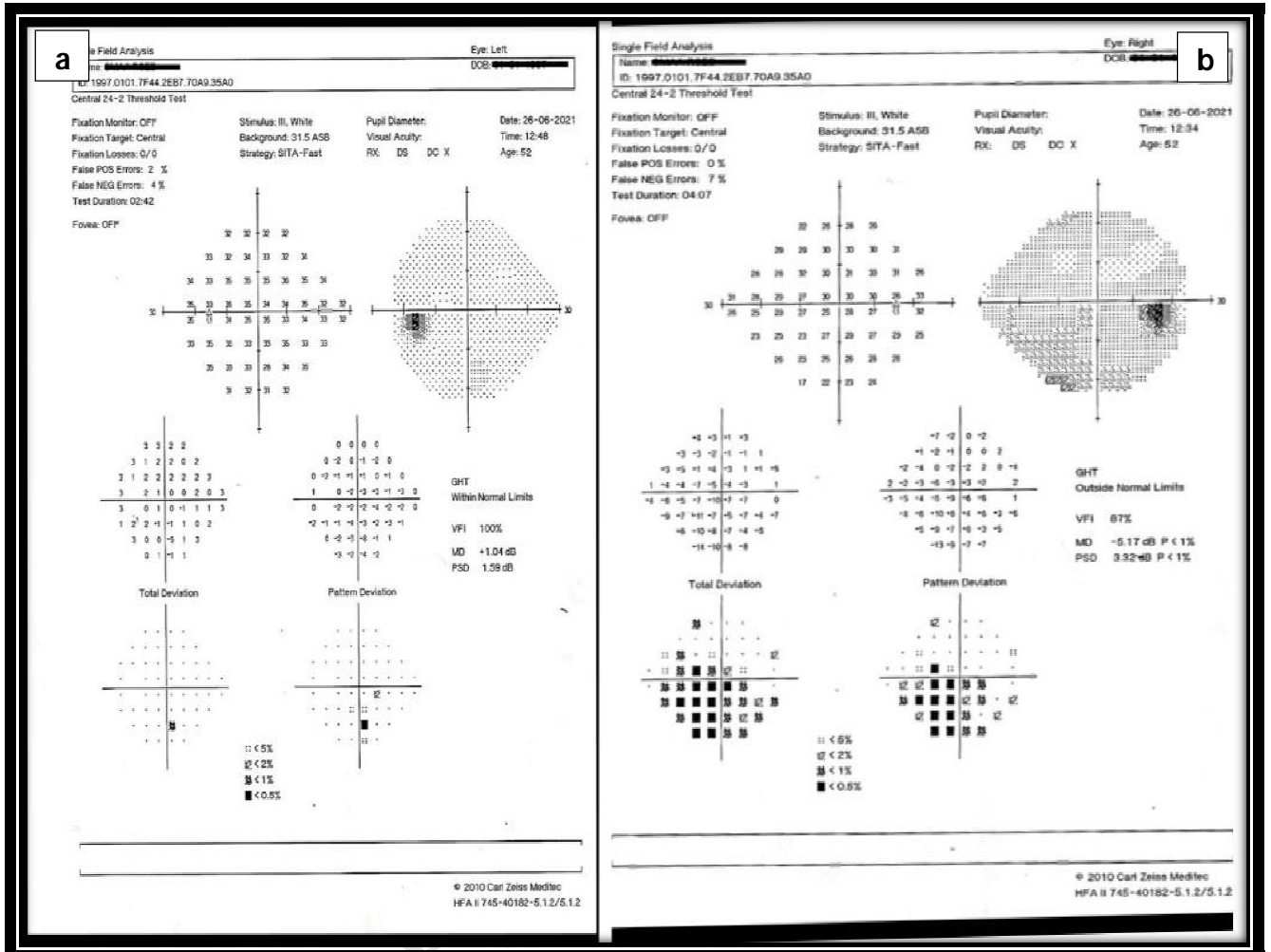
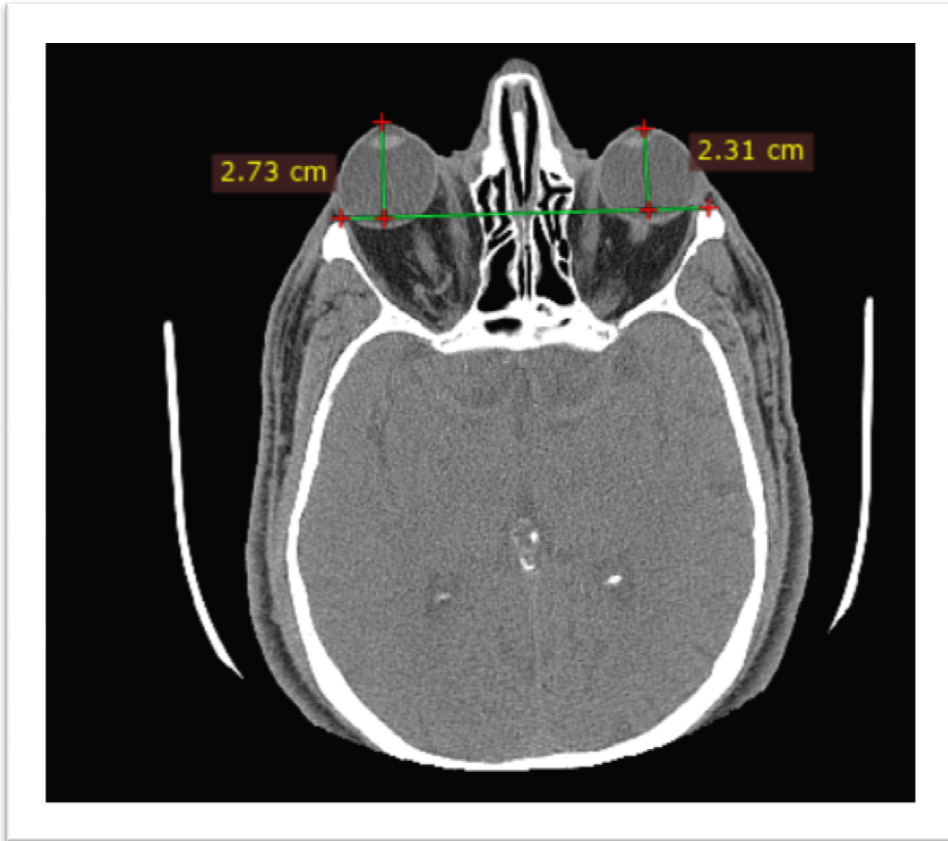

Figure 2: shows visual field changes and mean deviation of both eyes in case with TED.

figure a:left eye (without DON) , normal VF with VF MD 1.04 dB

figure b:right eye (with DON), lower arcuate scotoma with VF MD -5.17 Db



*Figure 3 :amount of proptosis in patient with TED,right eye:27.3mm,left eye :23.1mm*