

# The endocarditis of left atrial myxoma: A Case report

## **Abstract**

In this case report, a 37-year-old man with a history of lethargy, nocturnal sweats, and fever is diagnosed with an infected myxoma. His fever was 38 degrees. He was on broad-spectrum antibiotic treatment and had inflammatory markers and positive blood cultures. The transthoracic echocardiogram revealed a large mobile mass connected to the atrial septum, even though the mitral valve was unobstructed. He was given antibiotics for two weeks, or until his inflammatory signs returned to normal. A large atrial myxoma was surgically excised from the patient. It was an easy postoperative therapy.

**Keywords: endocarditis, myxoma, infection, surgery, antibiotic resistance**

## **Introduction:**

A cardiac myxoma (CM) is defined by the World Health Organization as a neoplasm formed of stellate to plump, cytologically bland mesenchymal cells embedded in a myxoid stroma. It is the most prevalent type of primary heart tumor. Fever, anemia, or increased inflammatory markers are common clinical manifestations; nevertheless, infection of these tumors is uncommon. The use of transthoracic echocardiography has boosted diagnosis.

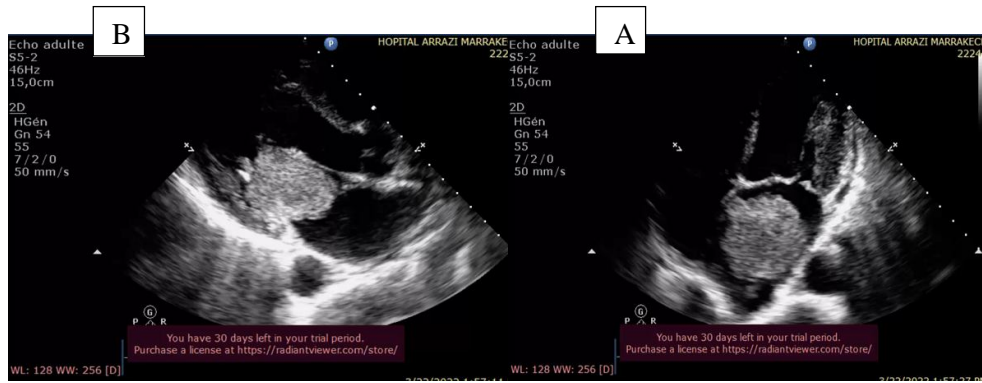
The most effective therapy is surgical excision, which has a success rate of more than 90%. We present a case of *Streptococcus metis*-infected myxoma. A review of the current literature is used to discuss and compare the diagnosis and therapy.

## **Case presentation**

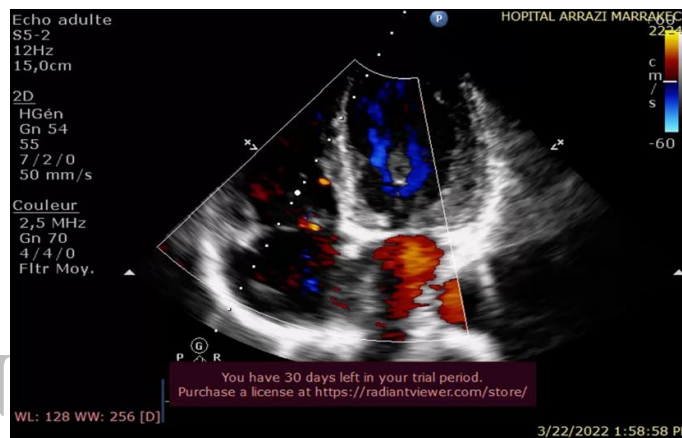
A 37-year-old man arrived with dyspnea, tiredness, malaise, and weight loss. He was hospitalized with a fever of 38°C and tachycardia. Biological tests revealed leukocytosis (16710 leukocytes/mL), an erythrocyte sedimentation rate (ESR) of 130 mm/h, and a procalcitonin level of 28 (for a normal of 0.5)

Echocardiography indicated a 5.6x4.1 cm pedunculated vegetative mass in the left atrium, heterogeneously dense and adhering to the interatrial septum, prolapsing into the left ventricle, with mild mitral regurgitation but no severe mitral valve blockage (Figure 1,2).

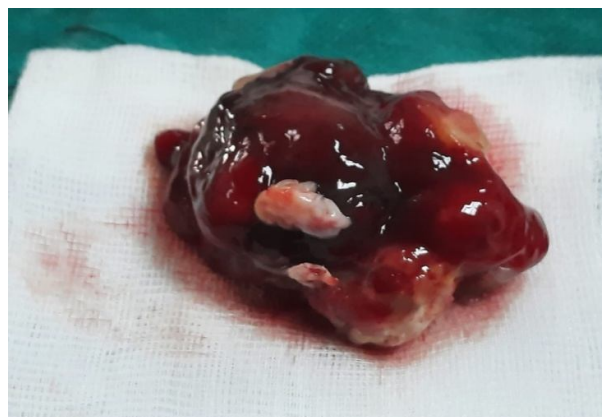The diagnosis of infective endocarditis on myxoma was suspected (Table), and antibiotic therapy with C3G and gentamicin was initiated, as well as blood cultures, which were positive for *Streptococcus Metis*. The patient was sent to cardiothoracic surgery. During surgery. The left atrium was examined during surgery, and a pedunculated gelatinous mass adhering to the atrial septum was resected (Fig. 3). The surgical course was unremarkable, his fever returned to normal, and echocardiogram revealed no residual mitral regurgitation. He was released from the hospital 10 days following the surgery.



**Figure 1: heterogeneous mass with pedicle attached to the interatrial septum(A). The mass has prolapsed through the mitral valve (B).**



**Figure 2: Myxoma of the left atrium causes moderate mitral regurgitation.**



**Figure 3: Myxoma of the heart constituted of friable, gelatinous tissue**

### **Discussion**

Myxomas are the most frequent type of primary cardiac tumor, with the majority developing in the atria (75% in the left atrium and 20% in the right atrium) [1]. Infection of a myxoma is rare [1-4], resulting in a clinical presentation comparable to infective endocarditis. Criteria for diagnosing infected myxoma have been established (Table 1).

## Tale 1: Criteria for diagnosis of infected atrial Myxoma

**TABLE. Criteria for the Diagnosis of Infected Atrial Myxoma**

Definitive	1. Myxoma documented by histology, and 2.a. Microorganisms observed in the sample, or 2.b. Positive blood cultures and evidence of inflammation in the sample
Probable	1. Myxoma documented by histology, and 2. Positive blood cultures and evidence of inflammation in the sample
Possible	1. Characteristic appearance on transthoracic or transesophageal echocardiography, and 2. Positive blood cultures

Taken from Horstkotte et al.<sup>8</sup>

Although cardiac myxomas often cause signs of infective endocarditis, they are rarely infected. In the literature, 51 cases of confirmed infected left atrial myxomas [2-18] have been reported, with the bacteria implicated being *Streptococcus viridans* (44%) and *Staphylococcus aureus* (15%) [12], with a microbiological spectrum comparable to that of native valve endocarditis. Bacteremia does not indicate that the myxoma is infected, since there have been cases of positive blood cultures in the absence of inflammation or infection in the tumors.

There are no distinct presentations of the clinical symptoms, making diagnosis challenging. Our patient, like the majority of other cases documented in the literature (94%, 48 of 51 individuals), was a fever. on the other hand, Fever is frequent in uninfected myxomas. They can cause an obstruction of the outflow.

In our case, there was no embolic sign, despite the fact that embolic complications have been described in 43% of cases in the literature (22 of 51 patients). However, the risk of embolic complications with uninfected myxoma is highly variable, ranging from 20 to 75%; however, once infected, the risk of cerebral and systemic embolism is much higher (88% of cases) than that of uninfected myxoma (33% of cases) because it is assumed that these vegetations are particularly unstable. On this topic, Revankar et al [13] compared clinical outcomes of uninfected myxomas to those of infected myxomas by comparing many case series. The authors discovered that embolic events caused by infected myxoma were not statistically greater than those caused by uninfected myxoma (45% versus 33%) [13].

Furthermore, the use of echocardiography has transformed the diagnosis of infected myxoma [6, 14]. In patients suspected of having an infected myxoma, echocardiography has become the gold standard for diagnosis and outcome evaluation. Echocardiography was used to diagnose 43 of the 51 previously reported instances. Tunick et al., on the other hand, observed the existence of a finger-like structure on the surface of a myxoma, indicating the presence of an infected myxoma [14], which was best revealed on gradient-enhanced cine-echo and gadolinium images.

Our patient was treated with antibiotics for two weeks before undergoing surgical excision. Furthermore, a study of the literature revealed that surgical excision was done in 44 of 51 patients (86% of cases), with a preference to continue routine antibiotic therapy for endocarditis for at least two weeks [16;17;18].

### **Conclusion:**

Infected myxoma is uncommon. When a patient with myxoma has a fever, blood cultures should be taken. Echocardiography should be done in individuals with unexplained fever, especially if early procedures are equivocal, to rule out lesions such as vegetation or myxoma, both of which may necessitate immediate surgical intervention.

### **Consent**

As per international standard or university standard, patient(s) written consent has been collected and preserved by the author(s).

### **Ethical Approval:**

As per international standard or university standard written ethical approval has been collected and preserved by the author(s).

### **References:**

[1] Reyne.n, K... *Cardiac myxomas. N Engl J Med*, 333 (1995), pp. 1610-7

[2] ten Berg JM, Elbers HRJ, Defauw JJAM, Plokker HWT. *Endocarditis on a left atrial myxoma. Eur Heart J* 1992;13:1592-3.4

[3] Revankar SG, Clark RA. *Infected cardiac myxoma: case report and literature review. Medicine* 1998;77:337-44.5

[4] Vogt PR, Jenni R, Turina MI. *Infected left atrial myxoma with concomitant mitral valve endocarditis. Eur J Cardiothorac Surg* 1996 10:71-3.6.

[5] Whitman MS, Rovito MA, Klions D, Tunkel AR. *Infected atrial myxoma: case report and review. Clin Infect Dis* 1994

[6] Malloch CL, Abbott JA, Rapaport E. *Left atrial myxoma with bacteremia. Am J Cardiol* 1970; 25: 353-8.

[7] Graham HV, von Hartitzsh B, Medina JR. *Infected atrial myxoma. Am J Cardiol* 1976; 25: 658-61.

[8] Rogers EW, Weyman AE, Noble RJ, Bruins SC. Left atrial myxoma infected with *Histoplasma capsulatum*. *Am J Med* 1978; 64: 683-90.

[9] Rajpal RS, Leibsohn JA, Liekweg WG et al. Infected left atrial myxoma with bacteremia simulating infective endocarditis. *Arch Intern Med* 1979; 139: 1176

[10] Quinn TJ, Codini MA, Harris AA. Infected cardiac myxoma. *Am J Cardiol* 1984; 53: 381-2.

[11] Frandsen TM, Prichard JG, Store SO *Streptococcus viridans* bacteremia associated with atrial myxoma. *Am Heart J* 1985; 110: 180-1.

[12] García-Quintana A, et al. *Infected Left Atrial Myxoma*, 2005

[13] Revankar S.G., Clark R.A. Infected cardiac myxoma. Case report and literature review. *Medicine*. 77, 337- 344, 1998.

[14] Tunick P.A., Fox A.C., Culliford A., Levy R., Kronzon I. The echocardiographic recognition of atrial myxoma vegetation. *Am. Heart J.* 119, 679-680, 1990.

[15] Puvaneswary M., Thomson D. Magnetic resonance imaging features of an infected right atrial myxoma. *Australas. Radiol.* 45, 501-503, 2001.

[16] Sebastiano Leone, Giuseppina dell'Aquila Sergio Giglio<sup>1</sup>, Mario Magliocca<sup>1</sup>, Patrizia Maio<sup>1</sup>, Francesco Saverio. Infected atrial myxoma: case report and literature review ,Italy . *Le Infezioni in Medicina*, n. 4, 256-261, 2007

[17] Horstkotte D, Follath F, Gutschik E, Lengyel M, Oto A, Pavie A, et al..

*Guía de Práctica Clínica sobre prevención, diagnóstico y tratamiento de la endocarditis infecciosa..*

*Rev Esp Cardiol*, 57 (2004), pp. 952-62

[18] Dekkers P, Elbers HR, Morshuis WJ, Jaarsma W.. Infected left atrial myxoma. *J Am Soc Echocardiogr*, 14 (2001), pp. 644-5

UNDER PEER REVIEW