

Case study

Triple X syndrome with congenital anomalies : a Rare case report

Abstract

Triple X syndrome is a relatively common chromosomal abnormality affecting 0.1% of live-born girls. Most of these girls have a normal phenotype and only a few cases have birth defects. The diagnosis of triple X syndrome may never be made because the clinical manifestations are not important to prompt the request for a karyotype. Prenatal diagnosis is often made before advanced maternal age. Parents of triple X children should be counseled regarding the significance of this syndrome and its prognosis. We report a case of triple X syndrome diagnosed in a five-day-old female newborn, with facial asymmetry, a palpebral coloboma and bilateral auricular appendages, the diagnosis was established by cytogenetic study on a constitutional karyotype which showed profile 47, XXX. Informed parental consent is required.

Keywords: palpebral coloboma; auricular appendages; newborn female; prenatal diagnosis; 47, XXX.

Introduction

" After the description of Down's anomaly as trisomy 21 (1); Klinefelter and Turner syndromes, the first case of trisomy X was published" (2). In 1959, Jacobs described the first case of an infertile woman with triple X syndrome.

"Triple X syndrome is a sex chromosomal abnormality that involves the presence of three sex chromosomes resulting in a 47, XXX karyotype" (3). "The anomaly occurs following a nondisjunction in meiosis I. About 90% of these cases are of maternal origin and 10% of paternal origin. The frequency of the 47, XXX phenotype diagnosed by genetic amniocentesis is estimated at 0.1% of female live births, which is approximately equivalent to its incidence in the neonatal population" (4). "Postnatal diagnosis is difficult because most of these cases have a normal phenotype and do not manifest as a structural abnormality. Only a few cases of karyotype 47, XXX have congenital malformations reported in the literature" (5). We report here a clinical case of triple X syndrome which was diagnosed in a newborn.

Case Presentation

A term female newborn baby of Moroccan origin was born vaginally to a mother with poor antenatal care, on a highway was brought to the Mohamed V military instruction hospital's maternity department in Rabat. The baby cried spontaneously at birth with an APGAR score of 10/10 at the 1st minute. The birth weight was 1950 grams (below 3rd percentile), body length 43 cm (below 3rd percentile) and head circumference 32 cm (below 3rd percentile). The estimated Dubowitz's score was 38 weeks of gestation approximately.

Maternal data showed mother was 43-year-old with gestation 2 and parity 1, had poorly controlled gestational diabetes and pregnancy induced hypertension on medication. Her first baby was premature and had died at home due to unknown cause. the father is at the age of 52, has no notable history. no notion of consanguinity of the parents.

On examination baby had an asymmetrical face, mouth slightly deviated towards the right side without hypoplasia, the eyelids appear asymmetrical with superior palpebral coloboma covering the right eye (figure 1) and a tubercle under the left nostril, the two ears completely formed with the presence of bilateral preauricular appendages in numbers of 3 to 4 on each side (Figure 2).

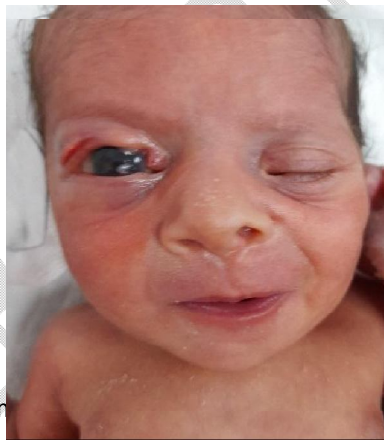

Figure 1: Asymmetry of the right eye

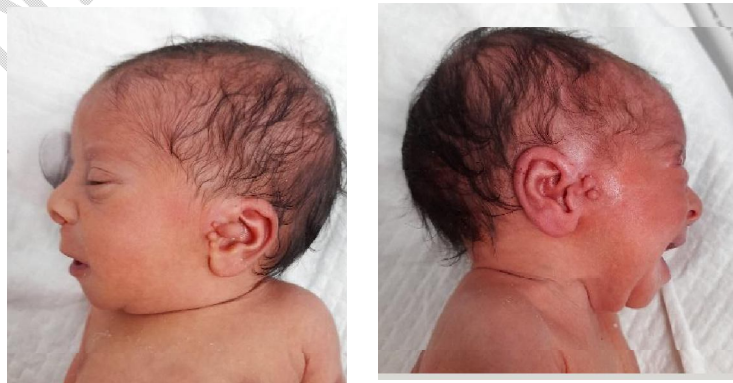

Figure 2: Bilateral preauricular skin tags

There was no palate, spine, limb anomalies. Baby had normal female genitalia. the cardiovascular and abdominal examination was normal. The evaluation of the function of vision could not be done. Routine blood investigation including infection markers was normal.

Chest X ray showed normal cardiac size, lung fields and Spine (Figure 3). TORCH profiles were negative. The Constitutional Karyotype showed the presence of an extra X chromosome in all the mitoses examined (Figure 4). So we concluded the diagnosis of Triple X syndrome.

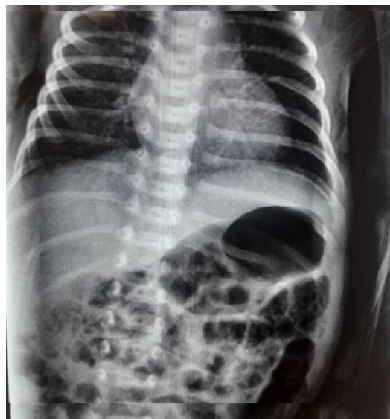

Figure 3: Standard X-ray of the spine. No anomalies found

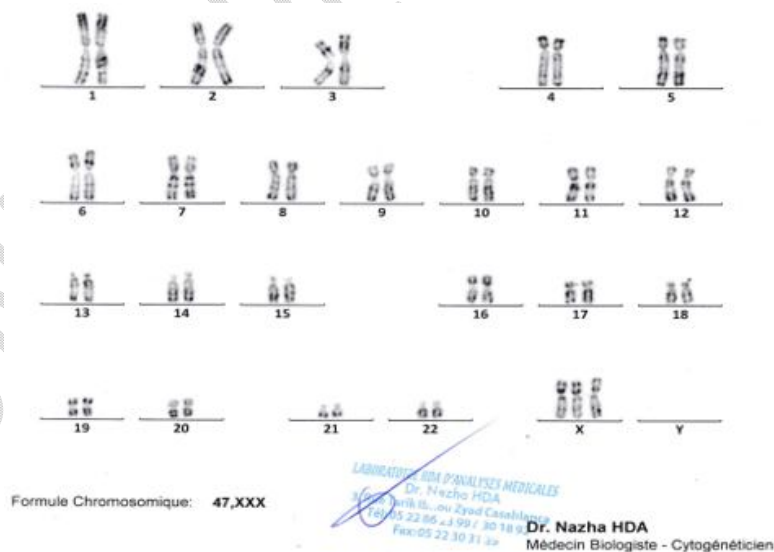


Figure 4: cytogenetic study of our patient showing profile 47, XXX

Discussion

"The first 47, triple X karyotype was described by Jacobs et al. in 1959 as the "super female", although in most cases those females with an extra X chromosome were identified

in hospitals for the mentally retarded" (3). "Cases of female infants with the 47, XXX phenotype are relatively common" (4). "Most of these infants have a normal phenotype. Only a few cases with trisomy X have congenital malformations reported in the literature" (5,6). Our case study arises from phenotypically normal parents, has facial dysmorphism with right upper palpebral coloboma and multiple preauricular tubercles. Generally, congenital ocular malformations of the coloboma type can be part of a hereditary polymalformative framework, for example: CHARGE, Goldenhar, Goltz syndromes, etc., or else can be linked to chromosomal abnormalities: trisomies 13, 18 and 8; triploidy; cat's eye, Turner's and Klinefelter's syndromes. It is very rare to find a congenital coloboma revealed by a triple X syndrome.

"This genetic anomaly is usually of sporadic origin, the X chromosomes in these patients fail to separate during cell division, by a process called non-disjunction. It derives mainly from nondisjunction maternal errors during meiosis I (63%) or II (17.4%). Only one of the three X chromosomes is activated and the other two are inactivated as Barr bodies. The variable phenotypic abnormalities mentioned above are thought to be linked to the overexpression of genes located on the extra X chromosomes that escape X inactivation" (5). "Advanced maternal age and aberrant recombination are risk factors for the syndrome" (7).

"There are few reports of the prenatal diagnosis of 47, XXX. The indication for cytogenetic studies in cases diagnosed before birth of 47, XXX are, usually either due to advanced maternal age or after detection of abnormal findings on prenatal fetal ultrasound such as oligohydramnios, fetal hydrops, intraoral mass, cleft lip and palate, postaxial polydactyly, syndactyly, bronchogenic cyst, dysplastic kidneys" (5,6). "The cases that were diagnosed after birth occurred following the detection of various congenital anomalies, mainly of the genitourinary system, such as ambiguous genitalia, ovarian dysgenesis, cloacal exstrophy, renal agenesis" (8), hence the importance of paying special attention to the urogenital tract at prenatal ultrasound to offer the possibility of early intervention after birth.

The majority of patients with triple X syndrome may go undetected and undiagnosed due to the normal phenotype, socially acceptable intelligence, normal sexual development and fertility even though they have other issues like low intelligence quotient and low cognitive functions. Only a few will have physical abnormalities. Their performance in school might not be at the level of their peer groups since there might be delayed language development, reading impairment, poor arithmetic performance, and poor verbal comprehension and reasoning. There may be chances of becoming socially isolated due to psychosocial adjustment issues (9,10).

People with triple X may have delayed puberty and/or early menopause; they could also have a reproductive problem (11, 12). Those with associated autoimmune thyroid disorders may experience pregnancy complications resulting in premature births and malformations (13).

Conclusion

Triple X syndrome is a syndrome has variable physical and behavioral phenotype. Despite its relatively high prevalence, many problems remain yet to be studied in physical and behavioral development up to old age.

The pediatrician and parents can observe and analyze the linguistic, neuromotor, learning and behavioral skills of the child during his development. Parents should therefore be advised. Early diagnosis can help the child to develop as close to normal during schooling and later in life.

Further studies are needed to establish evidence-based treatment and support protocols in physical treatments (endocrinological treatment, fertility problems and treatment of cases of EEG abnormalities in relation to behavior, etc.), support educational, psychiatric diagnosis and treatment; and psychological treatment, such as psychotherapy and family therapy.

Consent

As per international standard or university standard, parental(s) written consent has been collected and preserved by the author(s).

Ethical Approval:

As per international standard or university standard written ethical approval has been collected and preserved by the author(s).

References

1. Jagadeesh S, Jabeen G, Bhat L, Vasikarla M, Suresh A, Seshadri . S, et al. Triple X syndrome with rare phenotypic presentation. *Indian J Pediatr* 2008;75:629—31.
2. Liebezeit BU, Rohrer TR, Singer H, Doerr HG. Tall stature as presenting symptom in a girl with triple X syndrome. *J Pediatr Endocrinol Metab* 2003; 16:233-5.
3. KH Gustavson, Triple X syndrome deviation with mild symptoms. The majority goes undiagnosed, *Lakartidningen*, 96, 1999, 5646-5647.
4. Simpson JL, Elias S. Sex chromosomal polysomies (47, XXY; 47, XYY; 47, XXX), sex reversed (46, XX) males, and disorders of the male reproductive ducts. In: Simpson JL, Elias S, editors. *Genetics in obstetrics and gynecology*. Philadelphia: Saunders; 2003. p. 323—41.
5. Khoury-Cotlado F, Wehbeh AN, Fisher AJ, Bombard AT, Weiner Z. Prenatal diagnosis of 47, XXX. *Am J Obstet Gynecol* 2005;192:1469—71.
6. Duncan SLB. Embryology of the female genital tract: its genetic defects and congenital anomalies. In: Shaw RW, Soutter WP, Stanton SL, editors. *Section 1: Basic principles and investigations, Gynaecology*. 3rd ed. London: Churchill Livingstone, 2003; pp 1-19.
7. Rolle U, Linse B, Glasow S, Sandig KR, Richter T, Till H. Duodenal atresia in an infant with triple X syndrome: a new associated malformation in 47, triple X. *Birth Defects Res A Clin Mol Teratol* 2007;79:612—3.

8. Rosa RF, Dibi RP, Picetti Jdos S, Rosa RC, Zen PR, Graziadio, C. Amenorrhea and X chromosome abnormalities. *Rev Bras Ginecol Obstet* 2008;30:511—7.
9. Kaplan RM, Jaccuzo DP. *Psychological Testing: Principles , Application & Issues*. 7th ed. Belmont: California, Thomson Wadsworth, 2009.
10. Anjum Afshan, Triple X syndrome, *J Pak Med Assoc*, 62(4), 2012, 392-394.
11. Sattler JM. *Assessment of Academic Achievement*. In *Assessment of Children: Behavioral and Clinical Applications*. 4th ed. San Diego: Jerome M Sattler. Publisher Inc 2002.
12. BG Bender, RJ Harmon, MG Linden, B Bucher-bartelson, A Robinson, *Psychosocial Competence of unselected young adults with sex chromosome abnormalities*, *Am J Med Genet*, 88, 1999, 200-6.
13. R Goswami, D Goswami, M Kabra, N Gupta, S Dubey, *Prevalence of the triple X syndrome in phenotypically normal women with premature ovarian failure and its association with auto-immune thyroid disorders*, *FertilSteril*, 80, 2003, 1052-4

UNDER PEER REVIEW