

Case study

Triple X syndrome: a case report

Abstract

Triple X syndrome is a relatively common chromosomal abnormality affecting 0.1% of live-born girls. Most of these girls have a normal phenotype and only a few cases have birth defects. We report a case of triple X syndrome diagnosed in a five-day-old female newborn, with facial asymmetry, a palpebral coloboma and bilateral auricular appendages, the diagnosis was established by cytogenetic study on a constitutional karyotype which showed profile 47, XXX.

Keywords: palpebral coloboma; auricular appendages; newborn female, triple X syndrome; 47, XXX.

Introduction

After the description of Down's anomaly as trisomy 21 (1); Klinefelter and Turner syndromes, the first case of trisomy X was published (2). In 1959, Jacobs described the first case of an infertile woman with triple X syndrome.

Triple X syndrome is a sex chromosomal abnormality that involves the presence of three sex chromosomes resulting in a 47, XXX karyotype (3). The **digital anomaly** occurs following a nondisjunction in meiosis I. About 90% of these cases are of maternal origin and 10% of paternal origin. The frequency of the 47,XXX phenotype diagnosed by genetic amniocentesis is estimated at 0.1% of female live births, which is approximately equivalent to its incidence in the neonatal population (4). Postnatal diagnosis is difficult because most of these cases have a normal phenotype and do not manifest as a structural abnormality. Only a few cases of karyotype 47, XXX have congenital malformations reported in the literature (5). We report here a clinical case of triple X syndrome which was diagnosed in a newborn ~~during the neonatal period and we recall the clinical aspects and the particularities of this sex chromosome aneuploidy.~~

Case report

This is a newborn at 5 days of life, born at term, female, resulting from a poorly followed pregnancy, the delivery had taken place by highway on indication of gestational diabetes not follow-up and hypertension during pregnancy under treatment, in the maternity hospital of the Mohamed V military instruction hospital in Rabat. The baby cried spontaneously at birth with an APGAR score of 10/10 at the 1st minute. The birth weight was 1950 grams, body length 43 cm and head circumference 32 cm. The Dubowitz score was estimated at approximately 38-week amenorrhea.

Comment [CL1]: Diagnosis at birth and presence of congenital anomalies is rare in this syndrome. Generally they are normal at diagnosed during childhood due to developmental delay and learning problems. A good review of literature is in this article. Otter M, Schrandner-Stumpel CT, Curfs LM. Triple X syndrome: a review of the literature. Eur J Hum Genet. 2010 Mar;18(3):265-71. doi: 10.1038/ejhg.2009.109. Epub 2009 Jul 1. PMID: 19568271; PMCID: PMC2987225. is in this article.

Comment [CL2]: With congenital anomalies: A Rare case report

Comment [CL3]: What it means?

Comment [CL4]: delete

Comment [CL5]: Modify the sentence. A term female newborn baby was born vaginally to a mother with poor antenatal care, on a highway was brought to the Mohamed V military instruction hospital's maternity department in Rabat.

Comment [CL6]: The estimated Dubowitz's score was 38 weeks of gestation approximately.

The maternal history is summarized by a 43-year-old mother, gestation 2 and parity 1, with a history of prolonged rupture of membranes, poorly managed gestational diabetes and gravidic hypertension under treatment. This lady also had a history of neonatal death at home of a hypotrophic premature baby at 25 days of life for an undocumented cause.

Clinically the patient presents an asymmetrical face, mouth slightly deviated towards the right side without hypoplasia, the eyelids appear asymmetrical with superior palpebral coloboma covering the right eye (figure 1) and a tubercle under the left nostril, the two ears completely formed with the presence of bilateral preauricular appendages in numbers of 3 to 4 on each side (Figure 2).

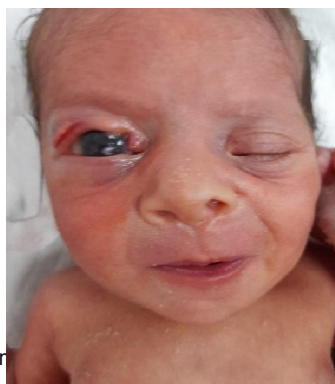

Figure 1: Asymmetry of the right eye

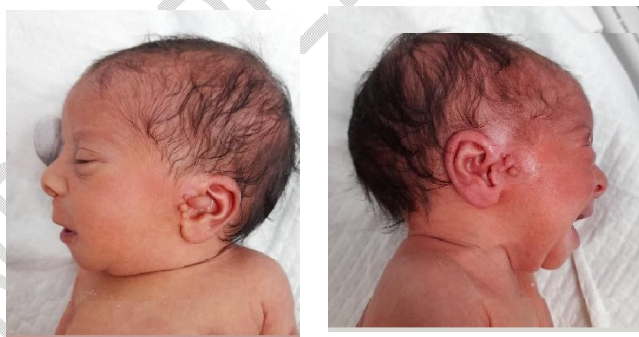

Figure 2: Bilateral preauricular tubers

On physical examination, the palate is intact, the eyeball appears normal, no abnormality in the spine, no orthopedic abnormality visible, the external genitalia of female types without particularities, the cardiovascular and abdominal examination is without particularity. The evaluation of the function of vision has not been concluded. Based on routine blood results, leukocytes 10,610/uL, hemoglobin 19 g/dL, platelets 189,000/uL, neutrophils 35%, lymphocytes 48.1%, monocytes 16%, therefore it was concluded that there was no sign of acute infection.

Comment [CL7]: Modify Maternal data showed mother was 43 year old with gestation 2 and parity 1, had poorly controlled gestational diabetes and pregnancy induced hypertension on medication. Her first baby was premature and had died at home due to unknown cause.

Comment [CL8]: Home death we cannot tell type of prematurity.

Comment [CL9]: On examination baby had

Comment [CL10]: Is it facial palsy or congenital absence of angular oris muscle?

Comment [CL11]: Skin tags

Comment [CL12]: There was no palate, spine, limb anomalies. Baby had normal female genitalia.

Comment [CL13]: Was normal

Comment [CL14]: Could not be done.

Comment [CL15]: Routine blood investigation including infection markers were normal.

The malformative assessment carried out showed that the heart is not enlarged, the lungs do not appear infiltrated and normal bronchovascular patterns, no abnormalities in the spine (Figure 3), the kidneys are of regular contours, the shadow of the liver and spleen did not appear enlarged and there was no mass syndrome or peritoneal effusion. TORCH profiles were negative. A constitutional karyotype was requested; in addition to support; showing the presence of an extra X chromosome in all the mitoses examined (Figure 4). So we concluded the diagnosis of Triple X syndrome.

- Comment [CL16]:** Chest X ray showed normal cardiac size, lung fields and Spine.
- Comment [CL17]:** No need as clinical examination of abdomen was normal.
- Comment [CL18]:** The Constitutional Karyotype showed

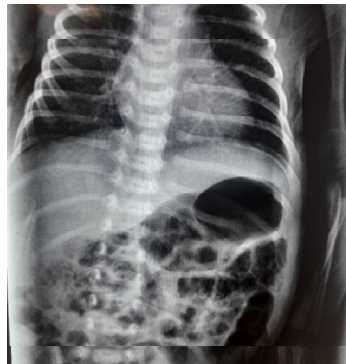

Figure 3: Standard X-ray of the spine. No anomalies found

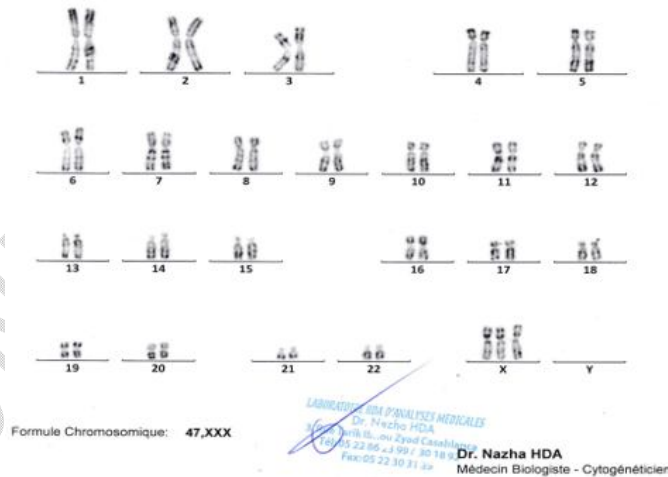


Figure 4: cytogenetic study of our patient showing profile 47, XXX

Discussion

The first 47, triple X karyotype was described by Jacobs et al. in 1959 as the "super female", although in most cases those females with an extra X chromosome were identified in hospitals for the mentally retarded (3). Cases of female infants with the 47, XXX phenotype are relatively common (4). Most of these infants have a normal phenotype. Only

- Comment [CL19]:** Modify as many are just repetitions

a few cases with trisomy X have congenital malformations reported in the literature (5,6). Our case study arises from phenotypically normal parents, has facial dysmorphism with right upper palpebral coloboma and multiple preauricular tubercles. Generally, congenital ocular malformations of the coloboma type can be part of a hereditary polymalformative framework, for example: CHARGE, Goldenhar, Goltz syndromes, etc., or else can be linked to chromosomal abnormalities: trisomies 13, 18 and 8; triploidy; cat's eye, Turner's and Klinefelter's syndromes. It is very rare to find a congenital coloboma revealed by a triple X syndrome.

This genetic anomaly is usually of sporadic origin, the X chromosomes in these patients fail to separate during cell division, by a process called non-disjunction. It derives mainly from nondisjunction maternal errors during meiosis I (63%) or II (17.4%). Only one of the three X chromosomes is activated and the other two are inactivated as Barr bodies. The variable phenotypic abnormalities mentioned above are thought to be linked to the overexpression of genes located on the extra X chromosomes that escape X inactivation (5). Advanced maternal age and aberrant recombination are risk factors for the syndrome (7).

There are few reports of the prenatal diagnosis of 47, XXX. The indication for cytogenetic studies in cases diagnosed before birth of 47, XXX are, usually either due to advanced maternal age or after detection of abnormal findings on prenatal fetal ultrasound such as oligohydramnios, fetal hydrops, intraoral mass, cleft lip and palate, postaxial polydactyly, syndactyly, bronchogenic cyst, dysplastic kidneys (5,6). The cases that were diagnosed after birth occurred following the detection of various congenital anomalies, mainly of the genitourinary system, such as ambiguous genitalia, ovarian dysgenesis, cloacal exstrophy, renal agenesis (8), hence the importance of paying special attention to the urogenital tract at prenatal ultrasound to offer the possibility of early intervention after birth.

The majority of patients with triple X syndrome may go undetected and undiagnosed due to the normal phenotype, socially acceptable intelligence, normal sexual development and fertility even though they have other issues like low intelligence quotient and low cognitive functions. Only a few will have physical abnormalities. Their performance in school might not be at the level of their peer groups since there might be delayed language development, reading impairment, poor arithmetic performance, and poor verbal comprehension and reasoning. There may be chances of becoming socially isolated due to psychosocial adjustment issues (9,10).

People with triple X may have delayed puberty and/or early menopause; they could also have a reproductive problem (11, 12). Those with associated autoimmune thyroid disorders may experience pregnancy complications resulting in premature births and malformations (13).

Conclusion

Triple X syndrome is a syndrome has variable physical and behavioral phenotype. Despite its relatively high prevalence, many problems remain yet to be studied in physical and behavioral development upto old age.

Comment [CL20]: Lot of repetition. Reduce it.

The pediatrician and parents can observe and analyze the linguistic, neuromotor, learning and behavioral skills of the child during his development. Parents should therefore be advised. Early diagnosis can help the child to develop as close to normal during schooling and later in life.

Further studies are needed to establish evidence-based treatment and support protocols in physical treatments (endocrinological treatment, fertility problems and treatment of cases of EEG abnormalities in relation to behavior, etc.), support educational, psychiatric diagnosis and treatment; and psychological treatment, such as psychotherapy and family therapy.

References

1. Lejeune J, Gautier M, Turpin R: Study of somatic chromosomes from 9 mongoloid children. *C R HebdSeancesAcadSci* 1959; 248: 1721–1722.
2. Jacobs PA, Baikie AG, Court Brown WM, MacGregor TN, Maclean N, Harnden DG: Evidence for the existence of the human 'super female'. *Lancet* 1959; 274: 423–425.
3. KH Gustavson, Triple X syndrome deviation with mild symptoms. The majority goes undiagnosed, *Lakartidningen*, 96, 1999, 5646-5647.
4. Simpson JL, Elias S. Sex chromosomal polysomies (47, XXY; 47, XYY; 47, XXX), sex reversed (46, XX) males, and disorders of the male reproductive ducts. In: Simpson JL, Elias S, editors. *Genetics in obstetrics and gynecology*. Philadelphia: Saunders; 2003. p. 323–41.
5. Khoury-Cotlado F, Wehbeh AN, Fisher AJ, Bombard AT, Weiner Z. Prenatal diagnosis of 47, XXX. *Am J ObstetGynecol* 2005;192:1469–71.
6. Lin HJ, Ndiforchu F, Patell S. Exstrophy of the cloaca in a 47, XXX child: review of genitourinary malformations in triple X patients. *Am J Med Genet* 1993;45:761–3.
7. Rolle U, Linse B, Glasow S, Sandig KR, Richter T, Till H. Duodenal atresia in an infant with triple X syndrome: a new associated malformation in 47, triple X. *Birth Defects Res A ClinMolTeratol* 2007;79:612–3.
8. Haddow JE, Palomaki GE, Knight GJ, Cunningham GC, Lustig LS, Boyd PA. Reducing the need for amniocentesis in women 35 years of age or older with serum markers for screening. *N Engl J Med* 1994;330:1114–8.
9. J Rovet, C Nestley, J Bailey, M Keenan, D Stewart, Intelligence and achievement in children with extra X aneuploidy: A longitudinal perspective, *Am J Med Genet*, 60, 1995, 356-63.
10. AnjumAfshan, Triple X syndrome, *J Pak Med Assoc*, 62(4), 2012, 392-394.
11. R Harmon, B Bender, M Linden, A Robinson, Transition from adolescence to early adulthood: Adaptation and psychiatric status of women with 47, XXX. *J Am Acad Child AdolescPsychiatry*, 37, 1998, 286-91.
12. BG Bender, RJ Harmon, MG Linden, B Bucher-bartelson, A Robinson, Psychosocial Competence of unselected young adults with sex chromosome abnormalities, *Am J Med Genet*, 88, 1999, 200-6.
13. R Goswami, D Goswami, M Kabra, N Gupta, S Dubey, Prevalence of the triple X syndrome in phenotypically normal women with premature ovarian failure and its association with auto-immune thyroid disorders, *FertilSteril*, 80, 2003, 1052-4.

Comment [CL21]: Check the punctuations of Vancouver style

Comment [CL22]: Check fullstop

Comment [CL23]: check

Comment [CL24]: check

Comment [CL25]: check

Comment [CL26]: check

Comment [CL27]: check

UNDER PEER REVIEW

