

Management challenges of Isolated duodenal trauma. A case report and literature review

Abstract

Duodenal trauma is uncommon but nowadays seen more frequently due to the increased accidents and violent events. We report a case of isolated duodenal injury following blunt abdominal trauma and highlight the challenges associated with its management. The diagnosis of the duodenal injury was early but associated with the hemodynamic instability of the patient. A short resuscitation was necessary before admitting the patient to the operating room. The patient underwent a surgical procedure which was the Jordan technique.

Keywords: Isolated duodenal Trauma, Diagnosis, Challenge management, Complications

Introduction

The management of duodenal trauma remains controversial. These injuries are relatively rare. Their management is made challenging by the retroperitoneal position of the duodenum and by its physiological function [1]. Mortality is not negligible, it is mainly increased by delay in the diagnosis, the frequency of associated lesions, and technical difficulties. There is no consensus on the surgical technique that ranges from primary suturing to complex resections depending on the severity of the lesions [2]. To try to answer these questions, this work proposes an analysis of a case coupled with that of the literature where the authors share their experience; reporting the different epidemiological, clinical, therapeutic, and prognostic characteristics of this rare injury.

Better not mention that case report can be used to answer these clinical questions, as this needs RCT.

Case report

A 60-year-old male patient with no notable history; consulted our emergency room four hours after a road accident for intense epigastric pain. There was no associated loss of consciousness. Clinical examination of the patient revealed hypotension of 80/50 mmHg, tachycardia of 115-120 beats per minute, and polypnea of 24 cycles per minute with permanent and invincible contraction of the rectus abdominal muscles.

Need more information on the mechanism of injury, explanation of the cause for hypotension. Since it is 4h, sepsis to cause hypotension is unlikely and there was no

A biological assessment was requested and returned without particularity. An abdominopelvic Computer Tomography(CT) scan was performed urgently without an oral contrast medium and it revealed the presence of pneumoperitoneum in the inter hepato-diaphragmatic space

and also in the Morisson space. This was associated with a peritoneal fluid effusion suggesting the perforation of a hollow organ (FIG1.). After short fluid resuscitation, the patient was admitted to the operating room. Under general anesthesia, a laparotomy with a mid-line incision was performed. Exploration found bilious liquid in the inter hepato-renal space and the right parietocolic space. Greenish spots of the transverse mesocolon with a grade III rupture of the second duodenal portion were discovered (FIG2). In this context, a surgical intervention by the Jordan technique was performed. The Pyloric exclusion was achieved through a gastrostomy, subsequently, the gastro-entero-anastomosis and duodenal primary repair were carried out associated with a wide drainage system. Recovery after the operation was uneventful and the patient was discharged from the hospital on the fifth postoperative day.

Discussion

The anatomy of the duodenum is unique and complex because of its close relationship to adjacent structures. Lying deep within the abdomen, the duodenum is well protected in the retroperitoneal space. Therefore, the isolated duodenal perforation is exceptional, found only in 0.6% of abdominal contusions. Duodenal trauma has low diagnostic accuracy before the operation, with the rate of definite diagnosis before the operation always below 10%. It is usually accompanied by other injuries due to the special and complicated anatomy of the duodenum. Duodenal trauma has a high incidence of missed diagnosis during operation which represents 20% of all cases [2]. The diagnostic accuracy of duodenum injury is low because it has no specific clinical signs and symptoms. The injury may not present with any sign of peritoneal irritation. If other abdominal organs are injured simultaneously, the diagnosis normally becomes more difficult. It has been shown that if the interval between injury and operation is longer than 24 hours, the injury would be considered severe. This is why early diagnosis is capital and the clinical signs detected should be particularly emphasized. However, surgeons need to know that the absence of clinical signs and symptoms does not exclude the possibility of a duodenal injury [3]. Our patient presented intense epigastric pain and permanent and invincible contraction of the rectus abdominal muscles and he consulted early. Abdominal plain films, ultrasound tests, and CT scans can also help in the diagnosis of duodenal injuries. Retroperitoneal air, free intraperitoneal air, or other signs such as obliteration of the psoas muscle shadow and scoliosis of the lumbar vertebrae can give a clue of the existence of an injury.

If you can explain the sensitivity and specificity of these signs, it will be more informative.

Under the circumstance of the absence of positive signs, air or water-soluble radiopaque contrast agent can be injected through a nasogastric tube just before the abdominal film is taken. If leakage happens, rupture of the duodenum can be confirmed [4]. The CT scan performed without oral contrast medium showed the presence of pneumoperitoneum in the inter hepato-diaphragmatic space and in a Morisson space; without highlighting the injured party. Laparoscopy also helps in the diagnosis of patients seen early and hemodynamically stable. Although routine laboratory tests are not helpful in the preoperative diagnosis of

duodenal rupture, some authors find that serum amylase is an important marker. Serum amylase is elevated in 50% of patients with duodenal or upper gastrointestinal injury [5]. In our case, the operative decision was based on clinical and radiological elements. Explorative laparotomy remains the ultimate diagnostic method if there is a high degree of suspicion of duodenal injury. The explorative procedures should be careful, comprehensive, accurate, and quick. The duodenum should be explored if such signs appear: free gas or fluid looking like bile with an undetermined origin, extraction of intestinal juice or fluid like bile from the retroperitoneum, hematoma, edema, ecchymosis or crepitus in the periduodenal region or root of mesentery and mesocolon. It requires careful detection for an accompanying injury to the pancreas as well as the bile duct and the ampulla, especially when the second portion of the duodenum is injured [2]. The principle of duodenal injury treatment is to take the overall situation into account and handle matters in order of importance and urgency. The literature has increasingly favored simple primary repair over complex strategies designed to divert and reduce the flow of secretions over the repair [6]. Options are limited for a patient presenting late with sepsis. Sometimes, "damage control surgery" in the form of polypropylene mesh laparostomy after duodenorrhaphy, tube gastrostomy, reverse tube duodenostomy, and a feeding jejunostomy can be performed. Salvage procedures like quick "damage control" with delayed definitive surgery, Foley catheter duodenostomy, and duodenal decompression by quadruple tube technique are sparingly reported [7]. Our patient underwent the Jordan technique, consisting of performing a pyloric exclusion via gastrostomy, a gastro-entero-anastomosis, and duodenal primary repair. Mobilization of the duodenum is known to reveal significant injury even in the absence of apparent signs of trauma to it. Thus, a case of complete transection of the duodenum at two places has been reported, one just beyond the pylorus and the other between the second and third part of the duodenum [8]. This report highlights the possibility of a duodenal injury occurring at multiple sites. We strongly suggest that in all major blunt trauma cases, even in the presence of obvious perforation on the duodenum, the duodenum should always be mobilized and evaluated for additional injury. During our exploration, the duodenal injury was unique, categorized as grade III according to the American Association for the Surgery of Trauma Organ Injury Scale (AASTOIS: American Association for the Surgery of Trauma Organ Injury Scale) [9]. Duodenal lesions are also associated with a high morbidity rate; complications are mainly represented by fistulas resulting from surgical repair failure due to suture line dehiscence and are occasionally represented by duodenal obstruction. In a review of 7 series [10], with a total of 341 patients, a morbidity rate of 22% was observed. Fifty-one (51) cases of an intra-abdominal abscess (15%), 21 of duodenal fistula (6%), 3 cases of duodenal obstruction (0.9%), and 2 cases of recurrent pancreatitis (0.5%) were reported. Fakhry et al. [11] a multicentre retrospective study comprising 318 patients with duodenal trauma recorded a morbidity rate of 27.1%. The location of the injury at the duodenal level has long been described as associated with high mortality. However, this would be largely due to the frequent association with other lesions within the abdomen. In a series of 2220 patients with isolated duodenal perforation, a fistula rate was 2.3% with tube decompression and 11.8% without. The mortality rate was 6.6%. This mortality is however higher when there is a

delay in managing the lesion [12]. The good prognosis with our patient could be explained by the fact that the lesion was isolated and the diagnosis was done early.

Conclusion

Isolated duodenal injury following blunt abdominal trauma is rare. The injury may not present with any sign of peritoneal irritation. Therefore, most general surgeons have a low index of suspicion and may not be experienced in handling such problems. There is no consensus regarding the surgical technique to be implemented. More complicated injuries need more sophisticated operation techniques and are followed by a high incidence of postoperative complications. This especially has to do with duodenal fistulas and the high mortality rate.

Please try more focused conclusion.

Figures

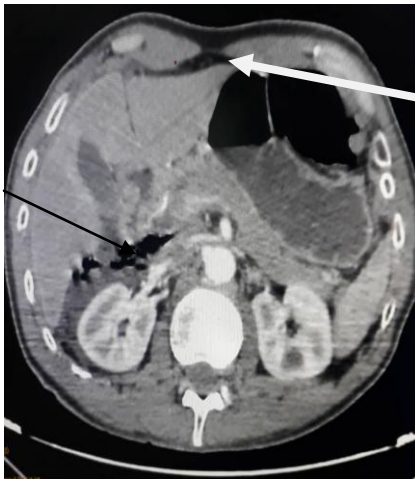

Fig 1 : Abdominal CT scan image showing pneumoperitoneum and a peritoneal fluid effusion.

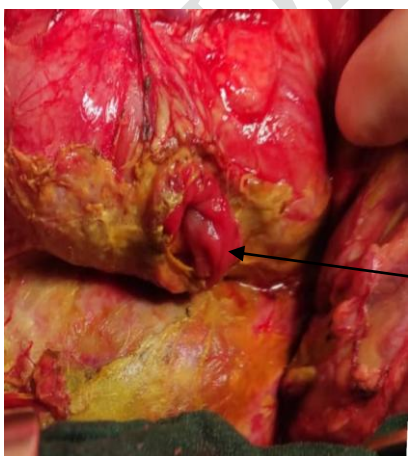


Fig 2 : Per-operative image showing a breach of the second duodenal portion.

Declarations

We certify that all possible efforts have been made to protect the identity of the patient mentioned in this Manuscript.

Consent

Not Applicable to this **Manuscript**

References

1. Fraga GP, Biazotto G, Villaca MP. Duodenal trauma: factors related to morbimortality. *Rev Col Bras Cir* 2008;35(2):94-102.
2. Siboni S, Benjamin E, Haltmeier T, Inaba K, Demetriades D. Isolated Blunt Duodenal Trauma: Simple repair, low mortality. *Am Surg*. 2015;81(10):961-4.
3. LeBedis CA, Anderson SW, Soto JA. CT imaging of blunt traumatic bowel and mesenteric injuries. *Radiol Clin North Am*. 2012;50(1):123-36.
4. D'Andrea KJ, Kunac A, Kinler RL, Staff I, Butler KL. Diagnosing blunt hollow viscus injury: is computed tomography the answer? *Am J Surg*. 2013;205(4):414-18.
5. Huang CL, Lee JY, Chang YT. Early laparoscopic repair for blunt duodenal perforation in an adolescent. *J Pediatr Surg*. 2012;47(5):E11-14.
6. Ordoñez C, García A, Parra MW. Complex penetrating duodenal injuries: Less is better. *J Trauma Acute Care Surg* 2014;76(5):1177-83.
7. Twelfth MM. Isolated duodenal rupture: primary repair without diversion; is it safe; Review of the literature. *BMJ Case Rep*. 2017;bcr-2016-215251.
8. Zelić M, Kunisek L, Petrosić N, Mendrila D, Depolo A, Uravić M. Double transection of complete duodenal circumference after blunt abdominal trauma without other intra-abdominal injuries. *Wien Klin Wochenschr*. 2010;122:54-6.
9. Moore EE, Cogbill TH, Malangoni MA, Jurkovich GJ, Champion HR, Gennarelli TA, et al. Organ injury scaling, I: pancreas, duodenum, small bowel, colon, and rectum. *J Trauma*. 1990;30(11):1427-9.
10. Girgin S, Gedik E, Yamur Y, Uysal E, Baç B. Management of duodenal injury: our experience and the value of tube duodenostomy. *Ulus Travma Acil Cerrahi Derg*. 2009;15:467-472.

11. Fakhry S, Watts D. Current diagnostic approaches lack sensitivity in the diagnosis of perforated blunt small bowel injury: analysis from 275,557 trauma admissions from the EAST Multi-Institutional HIV Trial. *J Trauma*. 2003;54:295-306.
12. Mingoli A, La Torre M, Brachini G, Costa G, Balducci G, Frezza B, et al. Hollow viscus injuries: predictors of outcome and role of diagnostic delay. *Ther Clin Risk Manag*. 2017;13:1069.

UNDER PEER REVIEW