

Original Research Article

Evaluation of effects of vitamin C supplementation in wound healing post dental implant surgery- A clinical study

ABSTRACT

AIM- The present study was conducted to assess the role of vitamin C in wound healing following dental implant surgery.

MATERIALS AND METHODS- 60 patients receiving dental implants were divided into two groups of 30 each. group A and group B. Group A included 30 patients who underwent dental implant surgery along with vitamin C supplementation, 500 mg twice a day post-surgery for 5 days and group B included 30 patients who underwent dental implant surgery alone. The Wound Healing Index, Wound Evaluation score and Visual Analog Scale were the following indices evaluated.

RESULTS - The results of the present study showed that there was a significant improvement in all indices in both group A and group B, but results in group A were statistically more significant than group B and indicating that maximum healing was seen in the first 7 days post-operative, thereafter, remaining more or less the same. In reference to vitamin C for pain relief, there was no statistically difference between the study groups.

CONCLUSION- using vitamin C supplementation post-operative healing following dental implant surgery in patients given vitamin C. However, vitamin C supplementation does not decrease the post operative pain associated with dental pain and anxiety.

Key words – dental implant, vitamin C, wound healing, pain, follow up, post operative

INTRODUCTION

Periodontitis is defined as “an inflammatory disease of the supporting tissues of the teeth caused by specific microorganisms or groups of specific microorganisms, resulting in progressive destruction of the periodontal ligament and alveolar bone with increased probing depth formation, recession or both.”¹

A major cause of tooth loss is periodontitis, which in its mild to severe forms affects 46% of the population, with other tooth loss etiologies including caries, trauma, genetic disorders, such as dentinogenesis imperfecta and developmental defects.²

Dental implants are the best treatment option for the rehabilitation of aesthetic and functional problems that result from tooth loss.³ Dental implants are designed to achieve primary mechanical stability and promote a strong bone-implant interaction over time through osseointegration.⁴ The process of wound healing follows dental implant surgery is an important factor that affects the clinical success and survival rate of dental implants.² Wound healing of an osseous wound around a dental implant is a sequentially and coordinated organized repair mechanism. A specific form of wound healing occurs around dental implants.

Wound healing after dental implant surgery is an important concern in dentistry.⁴⁽¹²⁾ Typical healing in dentistry refers to the periodontal tissue healing which occurs differently in periodontal procedures. Postsurgical wound healing monitoring is mainly performed by wound inspection after careful food and plaque debridement.¹³ In a healing bone wound, fibroblast-like osteogenic progenitor cells differentiate into osteoblasts and start to deposit woven bone that gradually grows towards the implant surface.

Healing of an implant wound is a complex process likely affected by multiple factors and individual variations. Umpteen studies have been done till date, validating the role of micro and macronutrients involved in the wound healing process. Arginine and glutamine, vitamin A, B, C, and D, zinc, and iron are essential for synthesis of collagen.⁵

Mohammad BM et al. (2016)⁶ showed that vitamin C could promote wound healing through a variety of mechanisms. Vitamin C protects the function of vascular

endothelium, increasing the expression of vascular endothelial growth factor, which promote cell division and secretion of matrix proteins. Vascular endothelial growth factor promotes angiogenesis which is also essential element for the regeneration of damaged tissues. Comprehending the importance of wound healing and anticipated role of vitamin C supplementation post implant surgery. This study was first to be undertaken to evaluate the role of additional vitamin C supplementation in wound healing post implant surgery.

MATERIALS AND METHODS

The present clinical study was conducted on 60 patients visiting the Department of Periodontology at Sri Guru Ram Das Institute of Dental Sciences and Research, Sri Amritsar. The research protocol was initially submitted to the institutional ethical committee. After approval, all patients were verbally informed, and a written consent was taken from all the participants before inclusion in the study. The study was conducted in agreement with principles embodied in the Helsinki Declaration of 1975, as revised in 2013.⁷

Selection criteria for the requirement of patients

Inclusion criteria included healthy adults aged 18-80 years, patients with missing teeth requiring dental implants, co-operative patients showing acceptable oral hygiene, patients willing to sign the informed consent and commitment to post treatment follow up visits.

Exclusion criteria included patients having any systemic disease influencing the periodontal health, alcoholics, smokers, tobacco chewers, drug addicts, pregnant women and lactating mothers, uncooperative patients.

Patients who fulfilled the inclusion and exclusion criteria were divided into two groups i.e., group A and group B. Group A included 30 patients who underwent dental implant surgery along with vitamin C supplementation, 500 mg twice a day post-surgery for 5 days and group B included 30 patients who underwent dental implant surgery alone.**(Figure1)**

Follow up were done at 7th, 14th and 21st day post-surgery.

The flow chart for the study design included exclusion, inclusion criteria, number of patients and indices used for the study. **(Flow chart)**

Assessment

Wound healing index (Landry, Turnbull and Howley)⁸ healing was estimated with a 5-level score index evaluated with the following 4 parameters: tissue color, response to palpation, granulation tissue and incision margin.

The wound evaluation scale (WES)⁹ addresses 6 clinical variables, each one with a 1/0 (not present/present) score for a maximum total score of 6: step-off borders, contour irregularities (puckering), wound margin separation greater than 2 mm, edge inversion (sinking, curling), inflammation (redness, discharge), and overall cosmetic appearance (well/not well). A score of 6/6 indicates optimal wound healing whereas a score of ≤ 5 indicates sub-optimal healing.

The Visual Analog Scale (VAS)¹⁰ was used to evaluate the subjective pain level experienced by the patient. The VAS consisted of a horizontal line of 10 cm (100 mm) long, anchored at the left end by the descriptor —no pain and at the right end by —unbearable pain. The patient was asked to mark the severity of the pain. The distance of this point, in centimeters, from the left end of the scale was recorded and used as the VAS score.

RESULTS

There were no clinical complications reported during follow up period and all dental implants were successfully osseointegrated. The post operative wound healing response and pain from representative patients in each group were recorded.

The value of wound healing index in group A 2.46 ± 1.07 at 7th day which increased to 3.76 ± 0.62 at 14th day and 4.46 ± 1.04 at 21st day. Whereas the value of wound healing index in group B was 3.06 ± 0.78 at 7th day which was increased to 3.86 ± 0.62 at 14th day and 3.93 ± 1.17 at 21st day given in **Table 1 and graph 3**.

On comparison of values wound healing index between group A and group B, the differences were found to be statistically significant ($p < 0.05$), at 7th day and non-significant ($p > 0.05$), at 14th and 21st day postoperatively.

The value of wound evaluation score in group A 1.56 ± 1.35 at 7th day which increased to 3.83 ± 1.11 at 14th day and 5.53 ± 0.57 at 21st day. Whereas the value of wound evaluation score in group B was 2.23 ± 1.59 at 7th day which was increased to 3.80 ± 1.09 at 14th day and 4.90 ± 0.54 at 21st day given in given in **Table 2 and graph 2.**

On comparison of values wound evaluation score between group A and group B, the differences were found to be statistically non-significant ($p > 0.05$) at 7th and 14th day and significant ($p < 0.05$) at 21st day postoperatively

The value of visual analog scale in group A was 4.66 ± 2.74 at 7th day which reduced to 2.43 ± 2.09 at 14th day and 1.10 ± 1.51 at 21st day. Whereas, the value of visual analog scale in group B was 5.16 ± 3.24 at 7th day which was reduced to 2.43 ± 2.41 at 14th day and which 0.66 ± 1.06 at 21st day given in **Table 3 and graph 1.**

On comparison of values visual analog scale between group A and group B, the differences were found to be statistically non-significant ($p > 0.05$), at 7th, 14th and 21st day postoperatively.

DISCUSSION

Vitamin C is a water-soluble vitamin, antioxidant, and essential co-factor for collagen biosynthesis, carnitine and catecholamine metabolism, and dietary iron absorption.¹⁴⁰ Vitamin C solution is necessary to cross-link collagen molecules to enhance tissue strength and it stimulates collagen genes to synthesize collagen in order to heal the wounds.¹¹

The primary outcome of this study was that postoperative administration of vitamin C improved the healing potential. In this study, a total of 110 dental implants were placed in 60 patients comprising 30 patients in each group. 45 dental implants were placed in maxilla and 65 dental implants placed in mandible.

Pain perception is a multifactorial phenomenon in which emotional experiences and sensory are involved; it is influenced greatly by the subject's expectation of pain which is associated with dental procedure.

Areej K et al. (2007)¹² conducted a study to assess the pain associated with dental implant surgery in 234 patients. Pain intensity was moderate or severe pain in a few

patients and majority of the patients had mild pain at all time points. Pain experienced by patients following the surgical placement of dental implants was generally mild and gradually decreased with time. Surgical difficulty, operator experience, female gender, and pain at earlier time-points were associated significantly with patient reports of pain.

Wong and Lytle et al. (1991)¹³ stated that implant insertion is one of the most stressful and anxiety-provoking procedures in dentistry. So, it is important that oral surgeons who perform these procedures are aware of the effect of anxiety on the patient's experience of pain.

Literature is brimming with studies, comparing that healing of oral wounds closely resembles as that of healing occur in other parts of body or connective tissue. Vitamin C protects the function of vascular endothelium, increasing the expression of vascular endothelial growth factor, which promotes cell division and secretion of matrix proteins. Vascular endothelial growth factor promotes angiogenesis, which is an essential element for the regeneration of damaged tissues.

In my study, 500 mg vitamin C was given in group A patients. Optimal dosage of vitamin C is necessary for collagen deposition and formation of dense granulation tissue. Less than 300mg of vitamin C has been shown to be associated with suboptimal effects accrued by the intake of vitamin C.

Healing process was significantly faster in group A patients but up till 7th day as indicated by wound healing scores was significant at 7th day and statistically non-significant at 14th and 21st day in both group A and group B.

But pertaining to day 14 or onwards, results were more or less same in 14th and 21st day in both the group A and B. This indicates that patients did not ensue any extra benefits of vitamin C supplementation. This shows that vitamin C played a significant role in healing upto till 7th day only.

Within the body repair and regeneration of tissue are influenced by vitamin C. Vitamin C is the synthesis of connective tissue, particularly collagen and provides tensile strength to new collagen formed which would otherwise be unable to stretch without tearing.

Soft tissue around dental implants plays a central role in esthetic outcomes. Healing of the peri-implant soft tissue occurs similarly to that of against of a tooth after surgical procedure. Epithelial and connective tissue contact to the implant or abutment surface is established within 1-2 weeks and further maturation follows up to at least 12 weeks. Careful surgical handling of the soft tissue when exposing the dental implant and placing the healing abutments helps the clinician to obtain the possible results, but even so there is loss of volumes of the tissues as they become weaker and more rigid after each procedure.

In implant dentistry soft tissue management requires an appropriate good esthetic finish. Without the good foundation of adequate blood supply and hard tissue support, satisfactory soft tissue results cannot be achieved. Attention is paid during the treatment planning step and the execution of the surgical procedures in implant placement for the preservation and recreation of the loss of alveolar bone is of critical importance.

In this study vitamin C was prescribed to 30 patients twice daily in the dosage of 500mg for 5 days post dental implant surgery. Also, the follow up period of this study was 21 days. Within the limits of present study, it can be concluded that larger sample size and increased duration of vitamin C intake could have been more scientifically productive as larger sample size can ensure inclusion of a more representative range of patients operating on a wider range of platform. A limited time span of 21 days follow-up might have been short in planning and delivering the end results. Longer follow-ups are helpful for the effective outcomes of the study. Further studies are needed to assess the optimal route of administration, time span and dosage of vitamin C needed to improve wound healing in patients undergoing dental implant surgery and the individual variations between patients and factors like patient lifestyle, diet and age may affect the outcome.

CONCLUSION

Vitamin C supplementation was ineffective in decreasing the postoperative pain associated with dental implant surgery, while vitamin C supplementation may play an important role in postsurgical wound healing, the individual variations between patients and factors like patients age, life style, medication and drug may affect the outcome.

In this study vitamin C was prescribed to 30 patients twice daily in the dosage of 500mg for 5 days post dental implant surgery. Also, the follow up period of this study was 21 days. Within the limits of present study, it can be concluded that larger sample size and increased duration of vitamin C intake could have been more scientifically productive as larger sample size can ensure inclusion of a more representative range of patients operating on a wider range of platform. A limited time span of 21 days follow-up might have been short in planning and delivering the end results. Longer follow-ups are helpful for the effective outcomes of the study. Further studies are needed to assess the optimal route of administration, time span and dosage of vitamin C needed to improve wound healing in patients undergoing dental implant surgery and the individual variations between patients and factors like patient lifestyle, diet and age may affect the outcome.

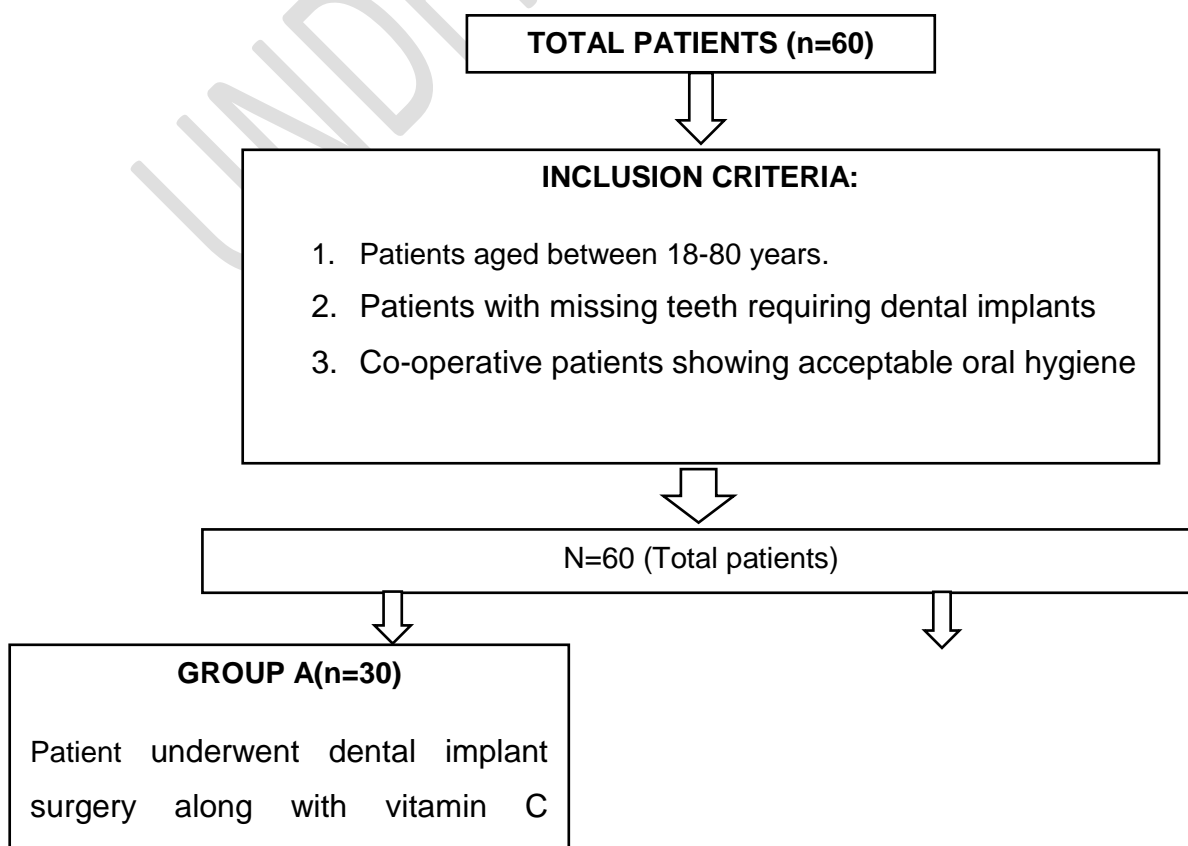
REFERENCES

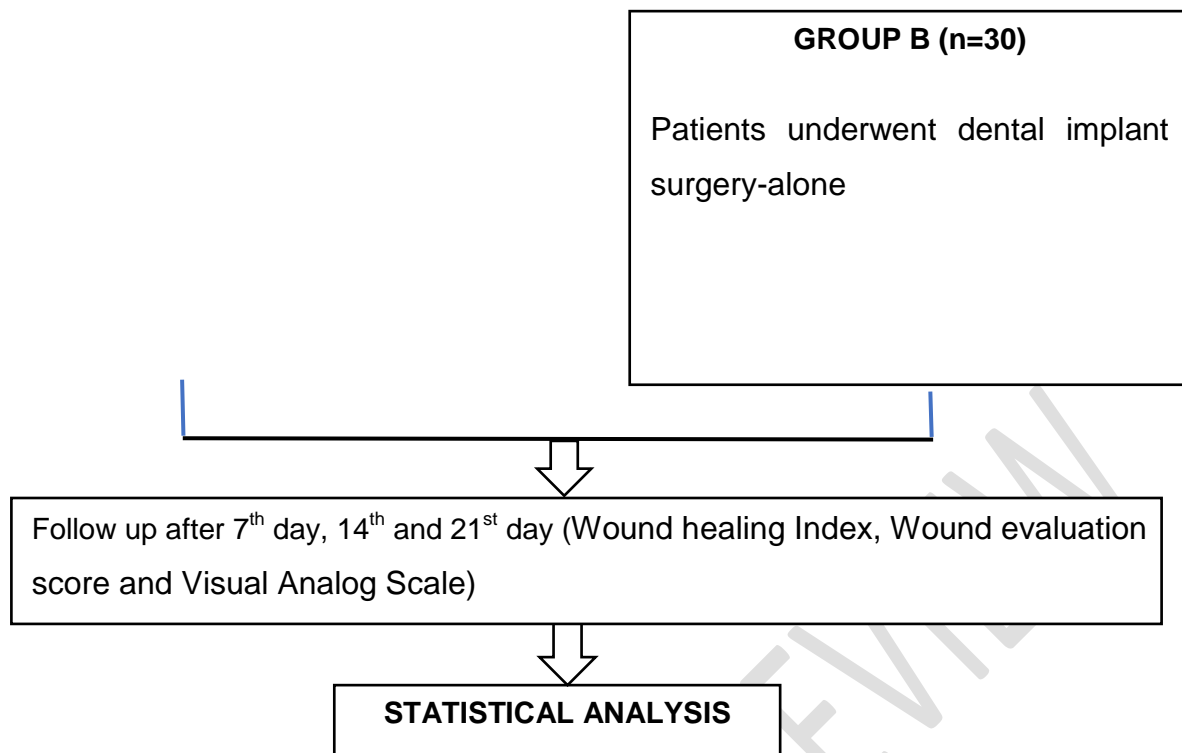
1. Hinrichs JE, Novak MJ Classification of diseases and condition affecting the periodontium. In: Newman MG, Takei HH, Klokkevold P, Carranza FA (eds).Carranza'sClinical Periodontology (eds) 11th ed. Missouri: WB Saunders; 2012.p.60-81.
2. Zohrabian VM, Sonick M, Hwang D, Abrahams JJ. Dental implants. Semin Ultrasound CT MR. 2015 Oct;36(5):415-26.
3. Li X, Tang L, Lin YF, Xie GF.Role of vitamin C in wound healing after dental implant surgery in patients treated with bone grafts and patients with chronic periodontitis.Clin Implant Dent Relat Res. 2018 Oct;20(5):793-8.
4. Gaviria L, Salcido JP, Guda T, Ong JL. Current trends in dental implants. J Korean Assoc Oral Maxillofac Surg. 2014 Apr;40(2):50-60.
5. Barchitta M, Maugeri A, Favara G, Magnano San Lio R, Evola G, et al. Nutrition and wound healing: An overview focusing on the beneficial effects of curcumin.Int J Mol Sci. 2019 Mar 5;20(5):1119.
6. Mohammed BM, Fisher BJ, Kraskauskas D, Ward S, Wayne JS, Brophy DF, et al.Vitamin C promotes wound healing through novel pleiotropic mechanisms.int Wound J. 2016 Aug;13(4):572-84.

7. World Medical Association. World medical association declaration of Helsinki: ethical principles of medical research involving human subjects. JAMA. 2013 Nov;310(20):2191-4.
8. Landry RG, Turnbull RS, Howley T. Effectiveness of benzydamyne HCl in the treatmentof periodontal post-surgical patients. Res Clin Forums, 1988;10:105-118.
9. Hollander JE, Singer AJ, Valentine S. Wound registry: development and validation. Ann Emerg Med. 1995 May;25(5):675-85.
10. McCormack HM, David JD, Sheather S. Clinical applications of visual analogue scales: a critical review. Psychol Med. 1988 Nov;18(4):1007-19.
11. Gadge H, Fernandes B, Priyadarshini HR, Grover S, Kumar J, Khiraiya N. Impact of Vitamin C on Wound Healing Following Dental Implantation. Ann Rom Soc Bio. 2021 May;5(25):2356-60.
12. Al-Khabbaz AK, Griffin TJ, Al-Shammari KF. Assessment of pain associated with the surgical placement of dental implants. J Periodontol. 2007 Feb;78(2):239-46.
13. Wong M, Lytle WR. A comparison of anxiety levels associated with root canal therapy and oral surgery treatment. J Endod. 1991 Sep;17(9):461-5.

FLOW CHART

STUDY DESIGN





TABLES

Time	Group A (n – 30) Mean + SD	Group B (n – 30) Mean + SD	Group A vs Group B P-value
AT DAY 7	2.46 ± 1.07	3.06 ± 0.78	0.016
AT DAY 14	3.76 ± 0.62	3.86 ± 0.62	0.539
AT DAY 21	4.46 ± 1.04	3.93 ± 1.17	0.068

Table: 1 Comparison of wound healing index between group a and group b at 7th, 14th and 21st day

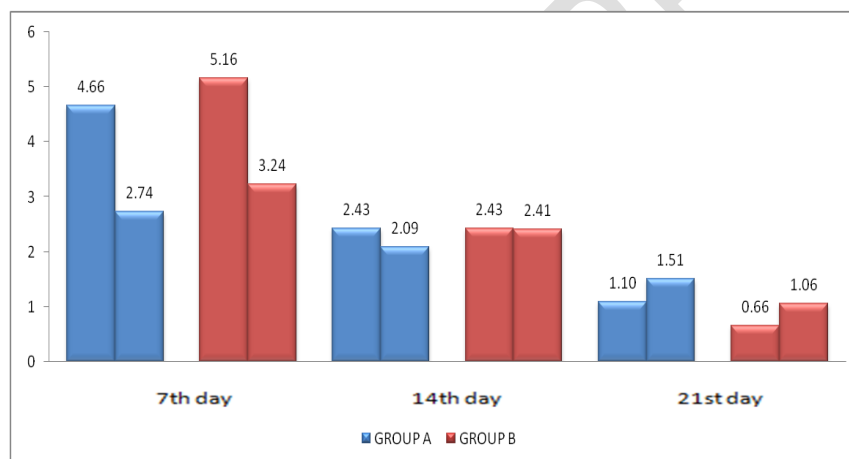
Time	Group A (n – 30) Mean + SD	Group B (n – 30) Mean + SD	Group A vs Group B P-value
AT DAY 7	2.46 ± 1.07	3.06 ± 0.78	0.016
AT DAY 14	3.76 ± 0.62	3.86 ± 0.62	0.539
AT DAY 21	4.46 ± 1.04	3.93 ± 1.17	0.068

Table: 2 Comparison of wound evaluation score between group A and group B at 7th, 14th and 21st day

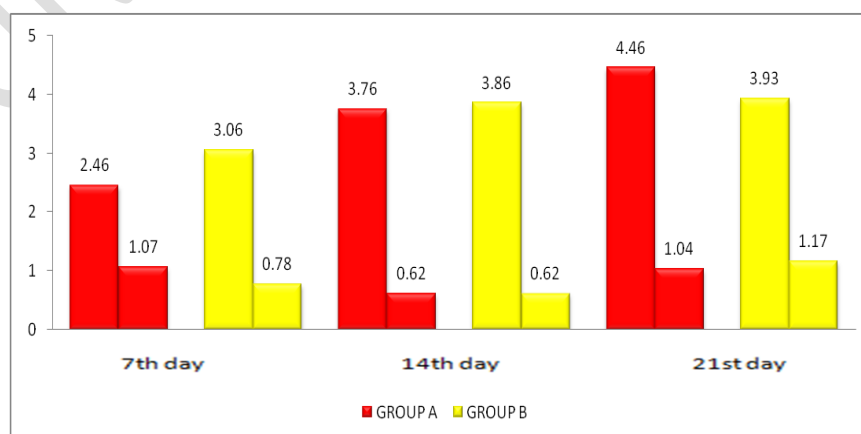
Time	Group A (n – 30) Mean + SD	Group B (n – 30) Mean + SD	Group A vs Group B P-value
AT DAY 7	4.66 ± 2.74	5.16 ± 3.24	0.522
AT DAY 14	2.43 ± 2.09	2.43 ± 2.41	1.000
AT DAY 21	1.10 ± 1.51	0.66 ± 1.06	0.025

Table:3 Comparison of visual analog scale between group A and group B at 7th, 14th and 21st day

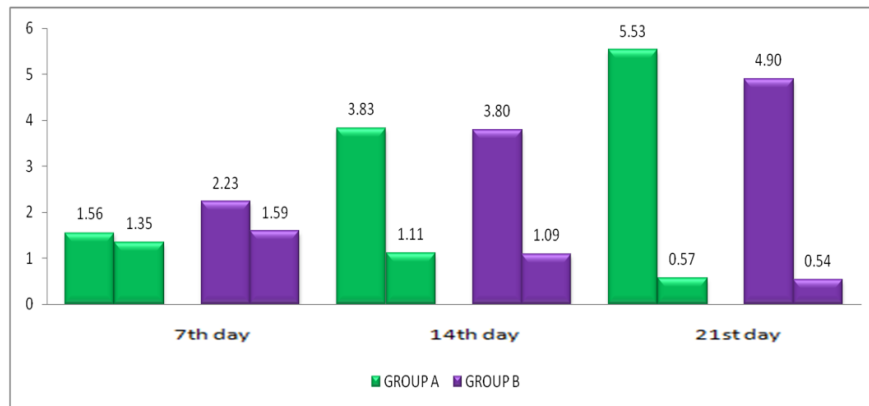
GRAPHS



Graph 1 COMPARISON OF VISUAL ANALOG SCALE BETWEEN GROUP A AND GROUP B AT 7TH, 14TH AND 21ST DAY



Graph 2 COMPARISON OF WOUND HEALING INDEX BETWEEN GROUP A AND GROUP B AT 7TH AND 21ST DAY



Graph 3 COMPARISON OF WOUND EVALUATION SCORE BETWEEN GROUP A AND GROUP B AT 7TH, 14TH AND 21ST DAY

UNDER PEER REVIEW