

## Case study

# Testicular Torsion: Case Report & Literature Review

## ABSTRACT

Acute Scrotal pain compromise 0.5% of all emergency department visits. Testicular torsion is a true urologic emergency, early diagnosing and treatment is crucial in salvaging the testis. Here we present to you a case of Acute testicular torsion in a young boy which proved that timing is key in saving the testis.

## 1. INTRODUCTION

Testicular torsion is a condition where the testicle twists around the spermatic cord, resulting in blood flow to the testicle being compromised. It affects 3.8 per 100,000 males younger than 18 years annually. It accounts for 10% to 15% of acute scrotal disease in children, and results in an orchiectomy rate of 42% in boys undergoing surgery for testicular torsion.

## 2. CASE REPORT

A 14 years old boy with no comorbidities came to Emergency Department with a complaint of Right testicular swelling for 2 days. Initially was started as abdominal pain at suprapubic region at 28/8/23 around 2 am. He didn't seek treatment to hospital till 29/8/2023 at 12.10pm after failed warm compression and worsening swelling with skin changes. Clinical Examination upon arrival finding was the Right scrotum swollen, warmth and tender upon palpation with absence of cremasteric reflex. Otherwise, Contralateral testes was Normal.

Blood investigation taken did not show sign of infection, White Cell was within normal range.

Urgent Ultrasonography was performed which shows absence of blood flow to the right testes and hence diagnosed as Right Testicular Torsion and proceeds with urgent referral to the Urology team.

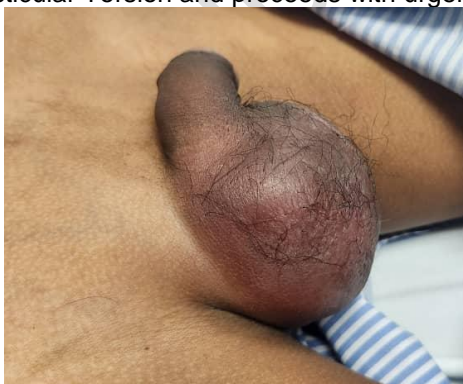

Figure 1 Clinical appearance of Scrotum at ED

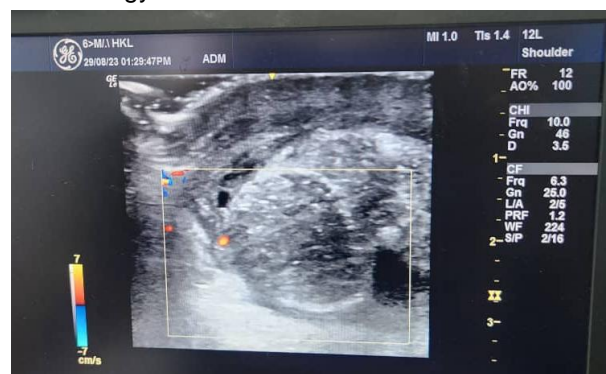


Figure 2 Doppler USG of Right Testis

During Scrotal Exploration on the same day, intraoperatively noted Bell Clapper Deformity on the Right testis and it was twisted twice clockwise and the right testis also non-viable. Urology team decided for Right Orchidectomy based on intraoperative findings and also did Left Orchidopexy on the Left Testis to prevent future torsion.

Patient was discharged well the following day.

### 3. DISCUSSION

Historically case of Torsion of scrotal organs dating back to 1703, the first described case of surgically treated testicular torsion was by Delasiauve in 1810.

Testicular torsion is a condition where blood supply to the testis is cut off, the age distribution for testicular torsion is bimodal where one peak at neonates and another at puberty. In neonates, Extravaginal predominates with the entire cord, including the processus vaginalis, twisting. While in older children and adults, the testicular torsion is usually intravaginal (twisting of the cord within the tunica vaginalis). It usually presented with the Bell Clapper Deformity in which there is abnormal fixation of the tunica vaginalis to the testicle, results in increased mobility of the testicle within the tunica vaginalis.

As the testicle twists around the spermatic cord, venous blood flow is cut off, leading to venous congestion and ischemia of the testicle. The testicle will become tender, swollen, and possibly erythematous. As the testicle further twists, the arterial blood supply is cut off which leads to further testicular ischemia and eventually necrosis.

The patient usually come to Emergency Department with a complaint acute onset unilateral testicular pain followed by nausea and vomiting. Other non-specific symptoms are fever and urinary problems. A high riding testis is the hallmark of testicular torsion and the cremasteric reflexes usually absent in this condition.

Gold standard imaging for diagnosing Testicular Torsion is Doppler Ultrasonography. It is highly sensitive (88.9%) & specific (98.8%) preoperative diagnostic tool with 1% false negative rate. Doppler Ultrasonography demonstrate relative decrease or absent blood flow to the affected testis.

In Emergency setting where Ultrasonography is not available and may delay the treatment Barbosa *et al.* created Testicular Workup for Ischemia and Suspected Torsion (TWIST) score based on clinical parameters for clinical diagnosis of testicular torsion. The scoring system consists of:

Table 1 : Torsion (TWIST) score based on clinical parameters for clinical diagnosis of testicular torsion

SIGN & SYMPTOMS	POINTS
TESTICULAR SWELLING	2
HARD TESTICLE	2
ABSCENT CREMASTERIC REFLEX	1
NAUSEA OR VOMITING	1
HIGH RIDING TESTIS	1

Based on this scoring, high suspicious patient with testicular torsion can skip the Doppler Ultrasonography and proceeds with the surgery.

Study has shown that salvage rate 90-100% if surgical exploration is done within 6 hours, eventually decrease to 50% if symptoms are present for more than 12 hours, and are typically less than 10% if symptom duration is 24 hours or more

### 4. CONCLUSION

Testicular torsion is acute surgical emergency, early diagnosing helps in salvaging the testis. Doppler Ultrasonography is the imaging of choice in diagnosing however in high suspicious case with high TWIST score, can proceed with urgent referral to Urology team and Scrotal Exploration.

## CONSENT (WHEREEVER APPLICABLE)

NOT APPLICABLE

## ETHICAL APPROVAL (WHEREEVER APPLICABLE)

NOT APPLICABLE

## REFERENCES

1. Thomas S Z, Diaz V I, Rosario J, et al. Emergency Department Approach to Testicular Torsion: Two Illustrative Cases. *Cureus* 11(10): e5967. doi:10.7759/cureus.5967
2. Manohara Maruti, Fiko Ryantono, Hamzah Muhammad Hafiq, Akhmad Makhmudi, Gunadi. Prognostic Factors for Pediatric Testicular Torsion Outcomes. *Malaysian Journal of Medicine and Health Sciences* 16(SUPP3): 15-17, June 2020
3. Henry Oscar, FRCR (UK), Jeevesh Kapur, FRCR (UK). Role of Ultrasound in Management of Scrotal Abnormalities in Children. *Med J Malaysia* Vol 67 No 5 October 2012. Available: <https://www.e-mjm.org/2012/v67n5/ultrasound.pdf>
4. Schick MA, Sternard BT. Testicular Torsion. 2023 Jun 12. In: StatPearls [Internet]. Treasure Island (FL): StatPearls Publishing; 2023 Jan-. PMID: 28846325.
5. Gustavo García-Fernández, Alberto Bravo-Hernández, Raúl Bautista-Cruz. Testicular torsion: A case report. *Elsevier* Vol. 85. Issue 5:432-435 (September - October 2017)
6. Xuxin Lim, Mark Ian Angus, Vivekandan Panchalingam, Kim Im Chng, Candy SC Choo, et al. Revisiting testicular torsion scores in an Asian healthcare system. *Journal of Pediatric Urology* Volume 16, Issue 6, December 2020, Pages 821.e1-821.e7
7. Victoria J Sharp, Kathleen Kieran, Angela M Arlen. Testicular torsion: diagnosis, evaluation, and management. *Am Fam Physician* 2013 Dec 15;88(12):835-40.
8. Kapoor S. Testicular torsion: a race against time. *Int J Clin Pract*. 2008 May;62(5):821-7. doi: 10.1111/j.1742-1241.2008.01727.x. PMID: 18412935.
9. Saleh O, El-Sharkawi MS, Imran MB. Scrotal Scintigraphy in Testicular Torsion: An Experience at a Tertiary Care Centre. *THE INTERNATIONAL MEDICAL JOURNAL Malaysia* 2012 Vol11No1:9-16
10. John M. Gatti MD, J. Patrick Murphy MD. Current management of the acute scrotum. *Seminars in Pediatric Surgery* Volume 16, Issue 1, February 2007:58-63
11. Nöske HD, Kraus SW, Altinkilic BM, Weidner W. Historical milestones regarding torsion of the scrotal organs. *J Urol*. 1998 Jan;159(1):13-6. doi: 10.1016/s0022-5347(01)63997-1. PMID: 9400427.
12. Manohar CS, Gupta A, Keshavamurthy R, Shivalingaiah M, Sharanbasappa BR, Singh VK. Evaluation of Testicular Workup for Ischemia and Suspected Torsion score in patients presenting with acute scrotum. *Urol Ann*. 2018 Jan-Mar;10(1):20-23. doi: 10.4103/UA.UA\_35\_17. PMID: 29416270; PMCID: PMC5791452.