

# Deciphering Pancreatitis, Panniculitis, Polyarthriti (PPP) Syndrome: Case Report

---

## ABSTRACT

**Aims:** Comprehensive objective: This study aims to comprehensively elucidate the clinical characteristics, intricate diagnostic challenges, and nuanced management strategies encountered in a rare and intricate case of PPP syndrome, encompassing pancreatitis, panniculitis, and polyarthriti.

**Presentation of Case:** An 82-year-old male patient presented with a week-long progressive nodular eruption on the lower limbs, accompanied by bilateral ankle swelling and difficulty walking. Laboratory tests revealed elevated inflammatory markers. Physical examination indicated bilateral ankle arthritis, subcutaneous nodules, and tender knee and elbow joints with limited movement. Imaging and further investigations confirmed the diagnosis of PPP syndrome. Management involved conservative measures, NSAIDs, and systemic corticosteroids.

**Discussion:** PPP syndrome's pathogenesis remains obscure due to its rarity. It involves a complex interplay of pancreatic enzymes leading to fat necrosis and subsequent tissue inflammation. Clinical manifestations encompass joint pain, skin lesions, and potential visceral involvement. Differential diagnoses include erythema nodosum, pancreatic tumors, and other arthritic conditions. Timely diagnosis and interdisciplinary collaboration are crucial in navigating the diagnostic hurdles and initiating appropriate interventions.

**Conclusion:** This case highlights the diagnostic intricacies and therapeutic complexities inherent in managing PPP syndrome. Prompt recognition, comprehensive evaluation, and multidisciplinary collaboration are pivotal for effective treatment. Although prognosis varies, vigilance for associated pancreatic malignancies underscores the necessity for continuous monitoring and tailored interventions. Further research and heightened clinical awareness are imperative for enhancing understanding and managing this multifaceted syndrome

*Keywords: [PPP syndrome; Therapeutic Strategies ; Differential Diagnoses ; Diagnostic challenges ; Multidisciplinary management]*

## 1. INTRODUCTION

Pancreatitis, Panniculitis, Polyarthriti (PPP) syndrome is a rare condition associated with serious complications and high mortality [1]. It is characterized by cutaneous panniculitis and polyarthriti on the basis of pancreatic diseases [2]. The diagnosis of PPP syndrome can be challenging due to its inconsistent clinical presentation [3]. The occurrence of arthrosis and skin lesions is not completely synchronous with pancreatic diseases, leading to missed or misdiagnosed cases [4].

Through this study, we aim to provide essential insights for a better understanding of the PPP Syndrome, highlighting the diagnostic challenges encountered and the multidisciplinary approaches necessary for optimal management. By documenting this specific case, we hope to contribute to the expansion of knowledge regarding this rare and complex disease.

## 2. PRESENTATION OF CASE

A 82-year-old male patient was admitted to the emergency department due to a progressive nodular eruption over a week, localized on the lower limbs. This eruption was accompanied by swelling in both ankles, causing difficulty in walking. The patient denied having fever, general discomfort, loss of appetite, weight loss, as well as respiratory or abdominal symptoms. His medical history includes surgery for bilateral inguinal hernia repair 10 years ago.

On physical examination, bilateral ankle arthritis was observed, along with several subcutaneous nodules in the area (Fig. 2b). Tenderness upon palpation of the knees and elbows was noted, accompanied by limited movement, without apparent skin lesions.

Laboratory analyses showed elevated inflammatory markers, with a C-reactive protein level of 89 mg/L and a normocytic and normochromic anemia. The patient was hospitalized for further investigations.

Joint X-rays (Figure 2) did not show signs of osteoarthritis or osteitis. Soft tissue ultrasound confirmed the suspicion of arthritis, revealing a heterogeneous aspect with mobile echoes and infiltration of the soft tissues on the dorsal aspect of the foot.

The patient underwent an incision for drainage in the area of the left foot, with a bacteriological study of the puncture fluid showing a non-purulent serous aspect; however, the culture remained sterile.

Subsequently, the patient reported intense epigastric pain aggravated by meals, suggesting a diagnosis of acute pancreatitis. Lipase levels revealed a value of 600 IU. Abdominal CT scan (Figure 3) depicted a Balthazar stage D pancreatitis, showing a globular pancreas with homogeneous density associated with peripancreatic fat infiltration, peritoneal effusion, a lithiasis gallbladder, and Bosniak type 1 renal cyst.

The diagnosis of pancreatitis-panniculitis-polyarthritis syndrome was established at this point. Subacute pancreatitis was managed conservatively with digestive rest, proton pump inhibitor (PPI) therapy, analgesics, and gradual reintroduction of food, resulting in pain resolution. However, the polyarthritis did not respond to treatment with NSAIDs, including meloxicam 15 mg once daily. Due to walking disability and the absence of pathogens in the culture, a high-dose systemic corticosteroid treatment (prednisone 40 mg) with rapid tapering was initiated. This led to polyarthritis resolution after 4 days and improvement in panniculitis after 2 weeks. A laparoscopic cholecystectomy was performed without incident, 3 months after admission.

The patient has been followed up in consultation for 1 year, without any signs of recurrent joint pain or pancreatitis

## 3. DISCUSSION

The association between pancreatic disease, panniculitis, and polyarthritis was described for the first time by *Boswell et al.* in 1973 [5].

Polyarthritis can have numerous reasons and may thus constitute a challenge for differential diagnosis. One rare potential reason for sterile polyarthritis is underlying pancreatic disease with systemic hyperlipasemia, most often accompanied by painful skin lesions caused by a subcutaneous inflammatory process known as panniculitis. [6]

Pancreatic panniculitis affects 2 to 3 percent of pancreatic disease patients. [7]

The actual pathogenesis of PPP syndrome is obscure since extensive mechanistic investigations are insufficient and difficult to conduct due to the syndrome's rarity. [6]

The current agreement is that the extra-pancreatic symptoms are caused by the release of enzymes produced by the pancreas, particularly lipase, into the circulatory system. Fat necrosis and the production of fat emboli occur as a result, with subsequent inflammation of fatty tissues such as periarticular bone marrow and fat in the subcutaneous area.[8] .Fat necrosis in biopsies of skin lesions or periarticular tissue from affected joints lends credibility to this theory, as does evidence of broad intramedullary fat necrosis in MRI investigations. [9]

Male sex, appearance in the 4th to 7th decades of life, as well as a history of consumption of alcohol and acute or chronic pancreatitis, are the most typically recognized risk factors. [8]

### **Arthritis**

Other, less common, extra-pancreatic manifestations include polyserositis [7] and intramedullary fat necrosis [11]. The radiological appearance is characteristic, with osteolytic lesions and moth-eaten bone destruction and periostitis of the tubular bones of the extremities, which correlate pathologically with areas of extensive intramedullary fat necrosis and trabecular bone destruction. [10]

Magnetic Resonance Imaging is the most sensitive for detecting abnormalities in bone marrow, which may precede frank necrosis. Radiographic images classically feature multiple osteolytic lesions and loss of joint space, as in this case. Occasionally, periostitis, osteonecrosis, osteosclerosis, and fractures may also be seen. [8]

### **Skin**

Skin lesions are the prominent characteristic in around 40% of patients, and in certain cases, they precede pancreatic disease progression.[7]

Skin lesions differ in size and usually affect the lower limbs, despite compared to erythema nodosum, they can progress proximally across the arms and trunk. Sterile abscess development, as seen in our patient, might result in the production of thick material high in triglycerides.[10]

Panniculitis is characterized by painful, erythematous nodules. These lesions can become ulcerated and exude an oily discharge. [7]

### **Differential diagnosis**

PPP syndrome exhibits clinical similarities with several conditions, necessitating meticulous differentiation for an accurate diagnosis. Among frequently confused conditions,

erythema nodosum distinguishes itself by its distribution of skin lesions predominantly on the anterior aspects of the lower limbs, often linked to infections or systemic illnesses. Conversely, PPP presents localized skin lesions, mainly on the lower limbs, progressing to subcutaneous nodules and a possible association with pancreatic conditions[12].

Moreover, differences in clinical features and test results can aid in distinguishing PPP from other diseases.

For instance, septic arthritis manifests as acute joint pain and a marked systemic inflammatory response, with joint fluid analyses often indicating the presence of microorganisms. Gout, on the other hand, is characterized by severe inflammatory arthritis attacks, typically in the joints of the big toe, and is associated with elevated serum uric acid levels.

Rheumatoid arthritis, a systemic autoimmune disease, may present symptoms akin to PPP but is differentiated by symmetrical joint involvement and specific blood tests, such as the presence of rheumatoid factors and anti-citrullinated protein antibodies.

Furthermore, pancreatic tumors, albeit rare, can mimic certain manifestations of PPP but require specific evaluation through imaging tests and pancreatic-specific serum markers for precise differentiation[11].

## **Treatment**

Treatment is an interdisciplinary task since PPP impacts several organ systems. Whatever discipline a patient initially presents to, additional specialists, such as gastroenterologists, rheumatologists, dermatologists, or visceral surgeons, should always be contacted. [6]

Conservative therapy includes supportive measures and subsequent infection management. Steroids, NSAIDs, and immunosuppressants are frequently ineffective for skin lesions or arthritis. [5] The use of octreotide might enhance subcutaneous lesions. [5]

Patients, particularly those with an underlying malignancy, should be sent to a center with extensive oncological competence. [6]

In the event of pancreatic cancer and gallbladder illness, surgery is advised. Endoscopic techniques, including pancreatic stenting and pseudocyst drainage, have also been discussed. [5]

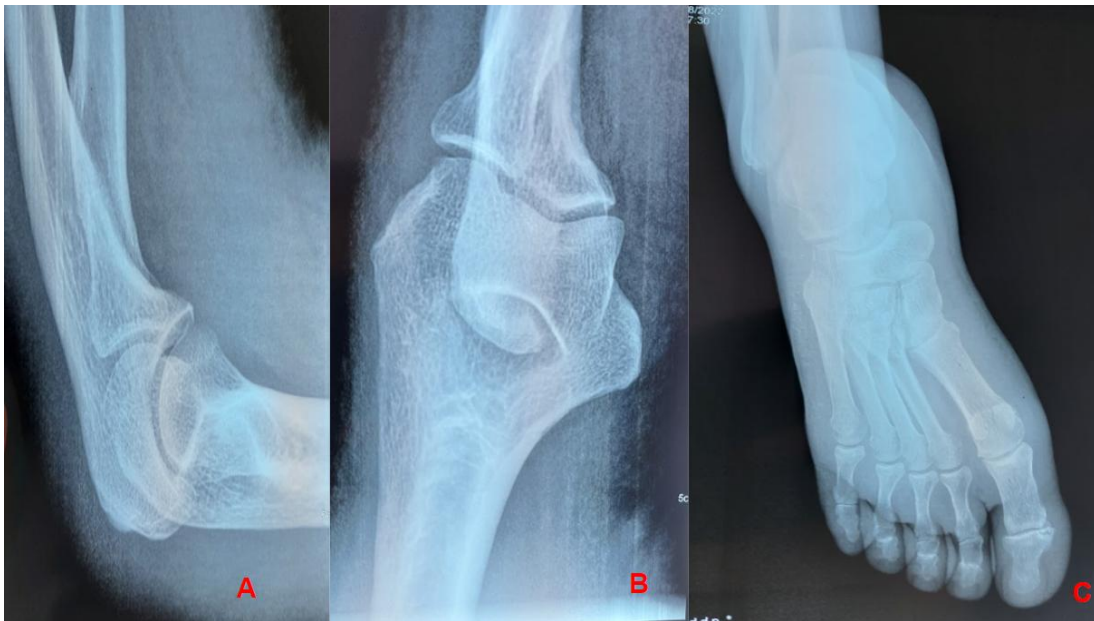
Different scenarios should be envisioned regarding specific practical approaches. First, patients presenting with unclear panniculitis or polyarthritis. As mentioned above, PP or PPP will rarely rank high in the initially considered differential diagnoses due to the condition's rarity. However, it is important to include PPP in differential diagnostic considerations and, thus, as a practical approach, we suggest that the determination of blood lipase levels should be included in the work-up of every case of unclear panniculitis or polyarthritis since this diagnostic test is broadly available, cheap, and highly specific. Second, patients with suspected PPP, but unclear pancreatic disease. If not already evident from patient history and examination [e.g., typical history and symptoms of acute pancreatitis after binge drinking], the first step should be to screen for acute or chronic pancreatitis as well as a pancreatic neoplasm with ultrasound, endoscopic ultrasound, and/or computed tomography.

The prognosis of PPP syndrome is variable and can be severe, with a high mortality rate [13]. The mortality rate is mainly associated with pancreatic malignancy, which is found in about one-third of cases [14].

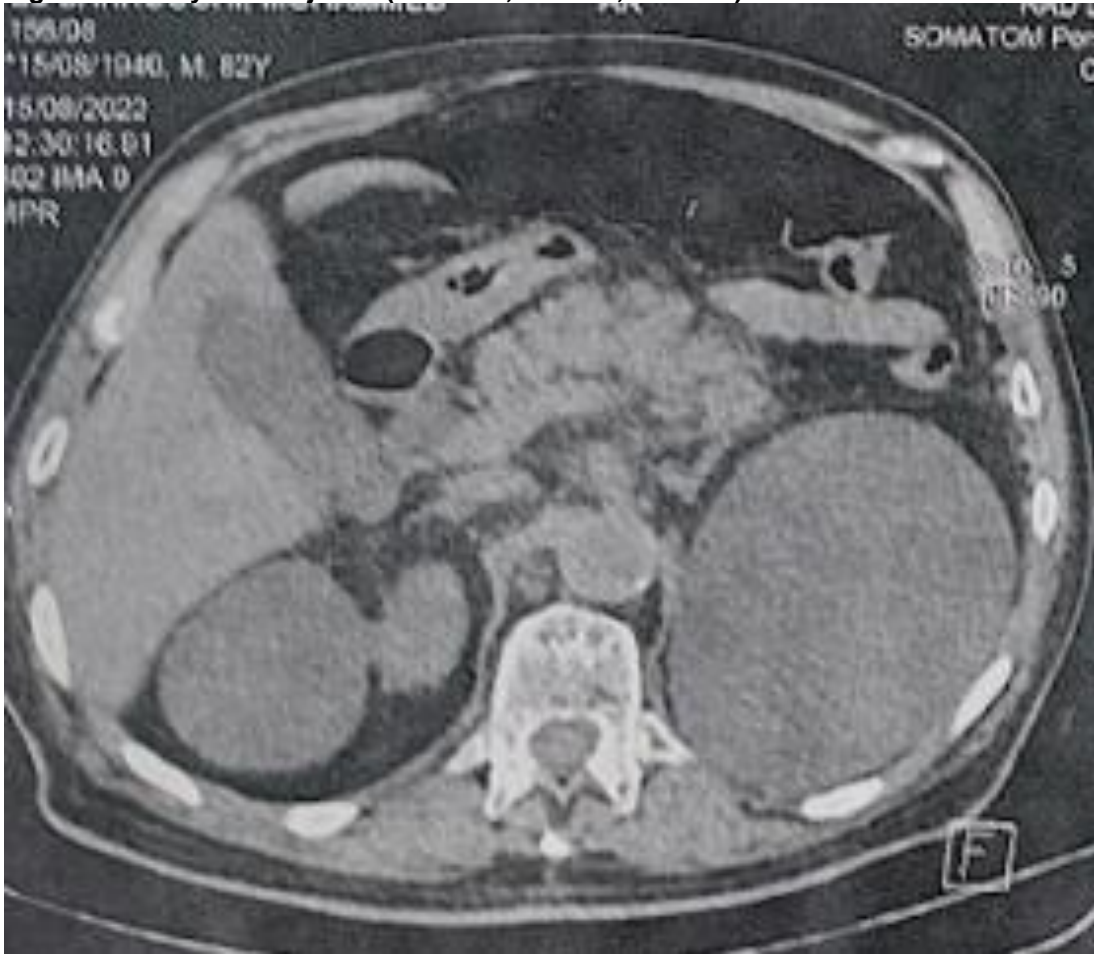
. Pancreatitis and panniculitis associated with PPP syndrome can resolve spontaneously over time, but polyarthritis may persist despite treatment [15].

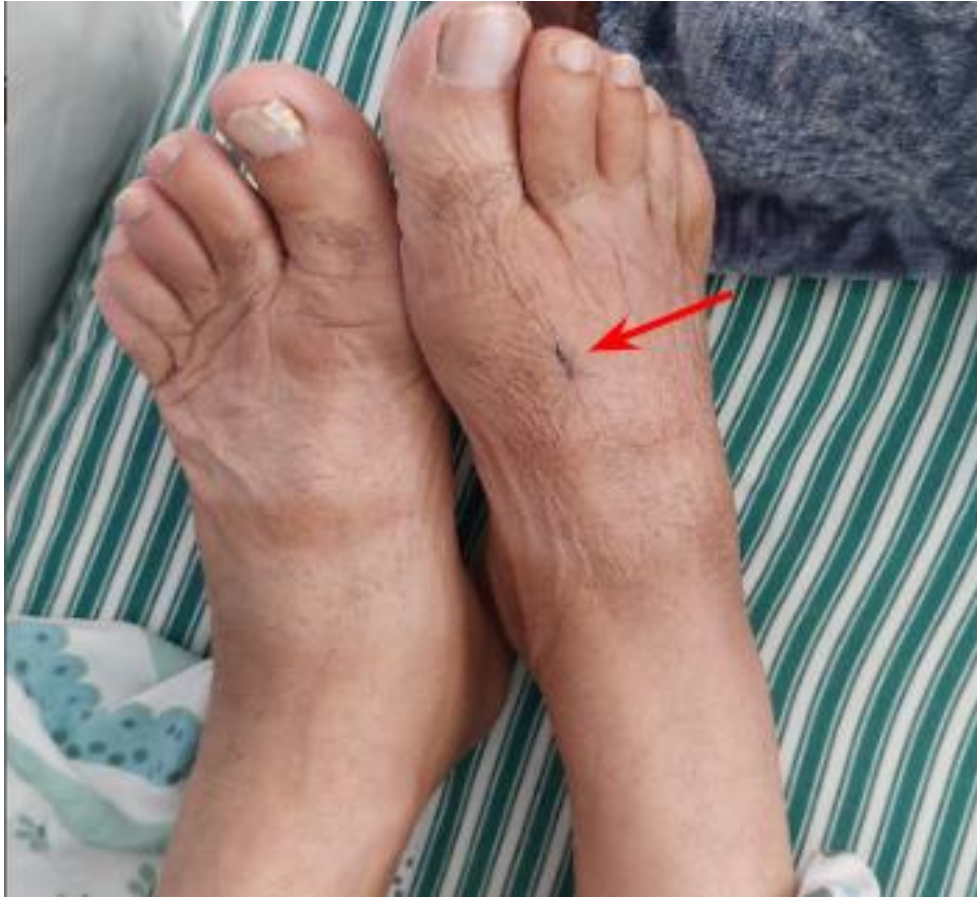

Figure 1. Appearance of the skin lesions."



**Figure. 2. X-rays of the joints (A: elbow, B: knee, C: ankle)**



**Figure.3.CT scan slice showing Balthazar stage D pancreatitis**

#### **4. CONCLUSION**

the presented case underscores the diagnostic complexity and therapeutic challenges inherent in managing PPP syndrome. Despite its rarity, awareness among clinicians is crucial for prompt identification and effective management. Interdisciplinary collaboration involving gastroenterologists, rheumatologists, dermatologists, and surgeons is pivotal for comprehensive care.

## Ethical Approval:

As per international standard or university standards written ethical approval has been collected and preserved by the author(s).

## Consent

As per international standards or university standards, patient(s) written consent has been collected and preserved by the author(s).

## REFERENCES

- 1 Pichler H, Stumpner T, Schiller D, Bischofreiter M, Ortmaier R. Pancreatitis, panniculitis and polyarthritis syndrome: A case report. *World Journal of Clinical Cases*. 2023 Jun 26;11(18):4412-8.
- 2 Pancreatitis, panniculitis, and polyarthritis syndrome complicated with systemic intraosseous fat necrosis. *Revista Espanola De Enfermedades Digestivas*, (2023). doi: 10.17235/reed.2023.9766/2023
- 3 Thomas, Döbler. Pancreatitis, panniculitis and polyarthralgia syndrome: A rare complication of pancreatic pathology. *Radiology Case Reports*, (2023). doi: 10.1016/j.radcr.2023.02.056
- 4 Houssein, Ammar., Fathia, Harrabi., Mohamed, Amine, Said., Rahul, Gupta., Ali, Ben, Ali. Pancreatitis, Panniculitis, and Polyarthritis (PPP) Syndrome in the Setting of Severe Acute Pancreatitis. *Cureus*, (2023). doi: 10.7759/cureus.35768
5. Ferri V, Ielpo B, Duran H, Diaz E, Fabra I, Caruso R, et al. Pancreatic disease, panniculitis, polyarthrititis syndrome successfully treated with total pancreatectomy: Case report and literature review. *Int J Surg Case Rep*. 2016 Jan 1;28:223–6.
6. Zundler S, Strobel D, Manger B, Neurath MF, Wildner D. Pancreatic Panniculitis and Polyarthritis. *Curr Rheumatol Rep*. 2017 Oct 1;19[14]:1–7.
7. Chee C. Panniculitis in a patient presenting with a pancreatic tumour and polyarthritis: a case report. *J Med Case Reports*. 2009 Jul 6;3:7331.
8. Agarwal S, Sasi A, Ray A, Jadon RS, Vikram N. Pancreatitis panniculitis polyarthritis syndrome with multiple bone infarcts. *QJM Mon J Assoc Physicians*. 2019 Jan 1;112[5]:43–4.
9. Narváez J, Bianchi MM, Santo P, de la Fuente D, Ríos-Rodríguez V, Bolao F, et al. Pancreatitis, panniculitis, and polyarthritis. *Semin Arthritis Rheum*. 2010 Apr;39[9]:417–23.
10. Price-Forbes AN, Filer A, Udeshi UL, Rai A. Progression of imaging in pancreatitis panniculitis polyarthritis [PPP] syndrome. *Scand J Rheumatol*. 2006 Jan 1;35[5]:72–4.
11. Pichler H, Stumpner T, Schiller D, Bischofreiter M, Ortmaier R. Pancreatitis, panniculitis and polyarthritis syndrome: A case report. *World J Clin Cases*. 2023 Jun 26;11[18]:4412–8.
12. Kim EJ, Park MS, Son HG, Oh WS, Moon KW, Park JM, et al. Pancreatitis, Panniculitis, and Polyarthritis Syndrome Simulating Cellulitis and Gouty Arthritis. *Korean J Gastroenterol*. 2019;175–82.
13. Zhuang ZF, Ye ZH, Zhong ZS, He GH, Wang J, Huang SP. A case report of a post-polypectomy syndrome with severe sepsis and organ dysfunction. *Ann Palliat Med*. 2020 Mar;9[6]:488–92.
14. Lehto J, Kiviniemi T. Postpericardiotomy syndrome after cardiac surgery. *Ann Med*. 2020 Sep 1;52[10]:243–64.
15. Dong E, Attam R, Wu BU. Board Review Vignette: PPP Syndrome: Pancreatitis, Panniculitis, Polyarthritis. *Am J Gastroenterol*. 2017 Aug;112[12]:1215–6.