

# Current Management of Liver Abscess : A Narrative review

## Abstract

Liver abscess can be divided into pyogenic and amoebic liver abscess. The common organisms that cause pyogenic liver abscess include *Escherichia Coli*, with amoebic liver abscess being caused by *Entamoebahistoltytica*. The diagnosis is made by ultrasound, computerized tomography, and magnetic resonance imaging of the liver. The treatment can be divided into medical therapy which involves percutaneous drainage and intravenous antibiotics, and surgical therapy which includes surgical drainage either by open or laparoscopic surgery. Surgical drainage is indicated for patients who have failed medical therapy. We have conducted this review article to look at the current management of liver abscess with regards to the role of percutaneous drainage and surgical drainage.

Keywords-Liver abscess, Pyogenic liver abscess, Amoebic liver abscess, Percutaneous drainage, Treatment of liver abscess

## Introduction

A liver abscess is defined as a collection of suppurative material that is encapsulated within the liver parenchyma. It is caused by bacterial, fungal, or parasitic organisms. Bacterial infections are the most common with *Escherichia Coli* being the most common organism in the western population and *Klebsiella Pneumonia* being the emerging organism in Asia. The risk factors for developing liver abscess include advanced age, male gender, immune compromised state, diabetes mellitus and liver cirrhosis.(1,2)

Liver abscess can be divided into pyogenic and amoebic liver abscess. Amoebic liver abscess is due to infection with *Entamoebahistoltytica* and is usually seen in Asia, Africa, and central America. It is commonly seen in young patients and in immunocompromised individuals. The route of infection can be by direct extension, biliary seedling, portal vein seedling, hepatic artery seedling, penetrating injuries and cryptogenic.(3)

The clinical presentation of liver abscess is usually with pain over the right hypochondrium, fever and jaundice and blood investigations will reveal leukocytosis and elevated serum bilirubin, aspartate aminotransferase, alanine aminotransferase and alkaline phosphatase.(4,5)

The diagnosis of liver abscess can be done imaging, with ultrasound, computerized tomography and magnetic resonance imaging can lead to a diagnosis in more than 80% of cases.

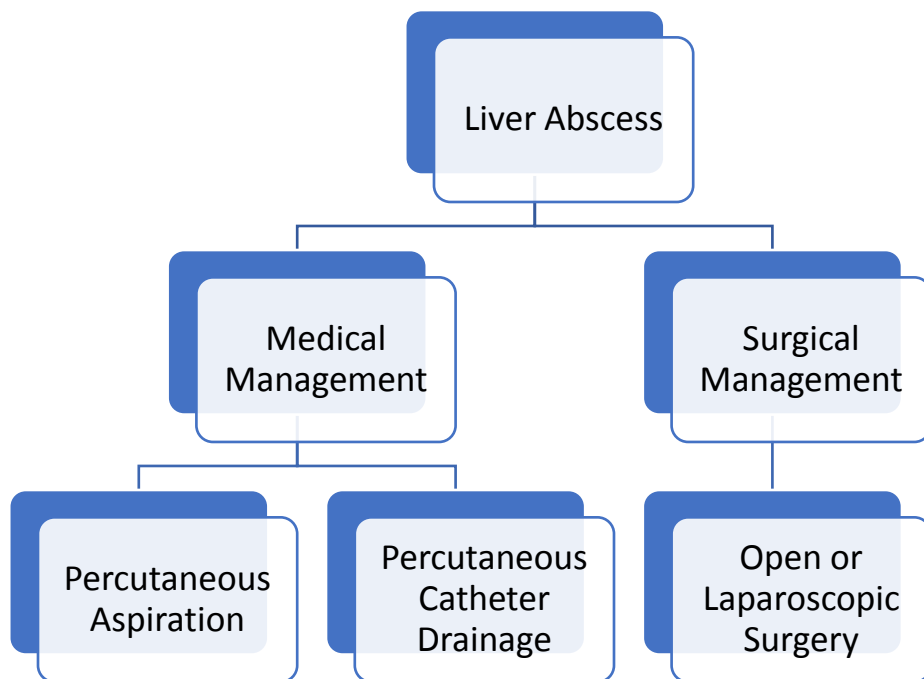
Computerized tomography is more sensitive than ultrasound in diagnosing a liver abscess.(6,7)

The treatment of liver abscess involves antibiotics for six to eight weeks, which consist of two weeks of intravenous antibiotics followed by oral antibiotics for the remaining 4 weeks. Antibiotic therapy is effective for liver abscess that are less than 6cm in size. For liver abscess that are larger than 6cm, percutaneous drainage of abscess can be performed. Percutaneous drainage can be divided into percutaneous aspiration and percutaneous catheter drainage.(8–12)

Surgical management of liver abscess is reserved for large,multiloculated liver abscess that have failed percutaneous therapy. It can be divided into open surgery or laparoscopic surgery. The current preferred method of surgical treatment is laparoscopic drainage of liver abscess as it is associated with reduced morbidity and faster recovery.(13)

As there is no current consensus in the management of liver abscess, we have conducted this review article looking into the etiology, diagnosis, and management of liver abscess. We conducted a literature review using PUBMED, the Cochrane database of systemic reviews, Google scholar and semantic scholar looking for randomized control trials, non-randomized trials, observational and cohort studies, clinical reviews, systemic reviews, and meta-analysis from 1990 to 2023.The following keywords were used, “liver abscess”, “pyogenic liver abscess”, “amoebic liver abscess”, “percutaneous drainage “and “treatment of liver abscess”. All articles were in English and were assessed by manual cross referencing of the literature. Commentaries and case reports were excluded from this review. Adult patients were included in this study and pregnant patients and pediatric patients were excluded.

**Image 1 The outline of the management of liver abscess**



## **Discussion**

### **Etiology of liver abscess**

Liver abscess can be divided into pyogenic and amoebic liver abscess. The most common organism that causes pyogenic liver abscess include *Escherichia coli* and *enterococcus* species especially in western patients, but there has been a growing increase in *Klebsiella Pneumonia* infections especially in Asian patients. Amoebic liver abscess is due to *Entamoeba Histolytica* and is commonly seen in young patient in Africa and Asia.(14,15)

There has been a growing trend in *Klebsiella Pneumonia* associated pyogenic liver abscess, especially in patients in Asia and Europe, where it has been replacing the more common organisms like *Escherichia Coli*, *Staphylococcus*, and *Streptococcus*. *Klebsiella Pneumonia* associated pyogenic liver abscess are also seen in patients with underlying diabetes mellitus.(16,17)

**Table 1 Organisms that cause pyogenic and amoebic liver abscess**

Pyogenic liver abscess	Escherichia Coli, Klebsiella Pneumoniae, Enterococcus, Streptococcus Milleri, Staphylococcus aureus
Amoebic liver abscess	Entamoeba Histolytica, Entamoeba Dispar

### **Diagnosis of liver abscess**

The diagnosis of liver abscess is often by imaging with ultrasound, computerized tomography and magnetic resonance imaging being the most common imaging modalities that are performed. Computerized tomography is more sensitive than ultrasound in diagnosing liver abscess. The appearance will vary according to the stage of the liver abscess. (18)

The presence of multiple liver abscesses is usually seen in older patients and have clinical symptoms that are of longer duration. They are also associated with higher morbidity and mortality. (19)

Blood investigations are also helpful in aiding in the diagnosis with leukocytosis, elevated serum aspartate amino transferase, alkaline phosphates and low serum albumin are all risk factors for development of liver abscess. (20)

### **Non operative management of liver abscess**

The non operative management of liver abscess includes the use of intravenous antibiotics and percutaneous drainage of the abscess. The most common antibiotics prescribed are

cephalosporins, metronidazole and quinolones. The duration of antibiotic therapy is up to 6 to 8 weeks.(21,22)

Percutaneous drainage of liver abscess has become the primary treatment option for the management of liver abscess. It can be divided into percutaneous aspiration and percutaneous catheter drainage. Percutaneous aspiration involves aspiration of the abscess and percutaneous catheter drainage involves drainage of the abscess and inserting a drain that facilitates further drainage of the abscess. The predictive factors for drainage include advancing age, abscess larger than 5cm and duration of symptoms. This procedure is associated with reduced morbidity and mortality when compared to surgical management.(23–28)

Percutaneous drainage of liver abscess was effective and cost effective in the management of liver abscess of up to 10cm in size and whether they are single or multiple in nature. It is associated with early recovery and reduced hospital stay.(29–31)

Percutaneous aspiration of liver abscess is easier to perform as the initial treatment for liver abscess as it is safe, effective, and associated with fewer complications. Percutaneous catheter drainage is indicated for larger liver abscess and is slowly becoming the first line therapy in the management of liver abscess.(32,33)

A prospective randomized control trial by Ahmed et al and Kulhari et al comparing percutaneous catheter drainage versus needle aspiration in the management of liver abscess found that percutaneous catheter drainage was more efficient and is the preferred choice for treatment of large liver abscess.(34,35)

A systemic review and meta-analysis by Mahmoud et al comparing percutaneous catheter drainage versus needle aspiration for liver abscess management found that percutaneous catheter drainage was superior to needle aspiration with regards to success rate, time to achieve reduction of abscess size, recurrence rate and duration of antibiotic therapy. However, the adverse rates were similar with both procedures. This was also confirmed by another systemic review and meta-analysis by Wei Lin et al who came with the same conclusions.(36,37)

A meta-analysis on the therapeutic dilemma in the management of uncomplicated amoebic liver abscess also concluded that percutaneous drainage followed by intravenous metronidazole was effective in the management of this condition. For large abscesses, insertion of a catheter drain may be indicated.(38)

Amoebic liver abscess is seen in young patients and percutaneous drainage is indicated for abscesses that are more than 5cm in diameter and it is accompanied by intravenous metronidazole. Percutaneous drainage is indicated for patients who fail conventional therapy with intravenous antibiotics.(39)

**Table 2** the success rate for percutaneous aspiration and percutaneous catheter drainage of liver abscess

Study	Study type	year	Success rate for percutaneous aspiration (%)	Success rate for percutaneous catheter drainage (%)	N=numbers
Ling Cai et al	Systemic review and meta-analysis	2014	77.8%	96.1%	306
Ahmed et al	Randomized control trial	2020	89.3%	96.2%	543
Mahmod et al	Systemic review and meta-analysis	2023	85.8%	96.8%	1546

### **Surgical treatment of liver abscess**

Surgical treatment of liver abscess is indicated if there is failure of medical therapy. The surgical management can be divided into open surgery or laparoscopic surgery. The advantage of surgical drainage is the ability to visualize the peritoneal cavity and liver. The biliary system can also be visualized properly, and cholecystectomy and bile duct exploration may be performed.(40,41)

Liver abscess that is due to biliary disease or tumors, duration of symptoms that are more than 10 days are risk factors that favor surgical drainage. In patients who present with large multiloculated liver abscess and those who have underlying sepsis, surgical drainage should be the treatment of choice.(42,43)

A systemic review and meta-analysis on the efficacy of laparoscopic surgery in the treatment of liver abscess by Ndong et al concluded that laparoscopic surgery was safe and effective in the

management of liver abscess. It was also associated with early recovery and reduced post operative analgesia.(44)

## **Conclusion**

The management of liver abscess has seen a trend towards percutaneous drainage and intravenous antibiotics with open surgery being reserved for patients who have failed medical therapy. Klebsiella Pneumonia is slowly emerging as the most common organism that causes liver abscess especially in Asia and is slowly emerging in most western countries. Liverabscesses are seen in older patients with co-morbidities and the clinical presentation is atypical. Percutaneous catheter drainage is associated with better outcomes when compared to percutaneous aspiration and antibiotics should be prescribed for up to 6 weeks. Laparoscopic surgical drainage is emerging as the method of choice for surgical management of liver abscess.

## **Conflict of interest**

There is no conflict of interest.

## **References**

1. Mavilia MG, Molina M, Wu GY. The Evolving Nature of Hepatic Abscess: A Review. J ClinTranslHepatol. 2016;4(2):158-168. doi:10.14218/JCTH.2016.00004
2. Albenmousa A, Sanai FM, Singhal A, Babatin MA, Alzanbagi AA, Al-Otaibi MM, et al. Liver abscess presentation and management in Saudi Arabia and the United Kingdom. Ann Saudi Med. 2011 Sep;31(5):528–32.
3. Kurland JE, Brann OS. Pyogenic and amebic liver abscesses. CurrGastroenterol Rep. 2004;6(4):273-279. doi:10.1007/s11894-004-0078-2

4. Donovan AJ, Yellin AE, Ralls PW. Hepatic abscess. *World J Surg.* 1991;15(2):162-169. doi:10.1007/BF01659049
5. Chen CH, Wu SS, Chang HC, Chang YJ. Initial presentations and final outcomes of primary pyogenic liver abscess: A cross-sectional study. *BMC Gastroenterol.* 2014 Jul 28;14(1).
6. Lardièrre-Deguelte S, Ragot E, Amroun K, Piardi T, Dokmak S, Bruno O, et al. Hepatic abscess: Diagnosis and management. Vol. 152, *Journal of Visceral Surgery*. Elsevier Masson s.r.l.; 2015. p. 231–43.
7. Bowers ED, Robison DJ, Doberneck RC. Pyogenic liver abscess. *World J Surg.* 1990;14(1):128-132. doi:10.1007/BF01670563
8. Webb GJ, Chapman TP, Cadman PJ, Gorard DA. Pyogenic liver abscess. *Frontline Gastroenterol.* 2014;5(1):60-67. doi:10.1136/flgastro-2013-100371
9. Barakate MS, Stephen MS, Waugh RC, et al. Pyogenic liver abscess: a review of 10 years' experience in management. *Aust N Z J Surg.* 1999;69(3):205-209. doi:10.1046/j.1440-1622.1999.01523.x
10. Mezhir JJ, Fong Y, Jacks LM, Getrajdman GI, Brody LA, Covey AM, et al. Current Management of Pyogenic Liver Abscess: Surgery is Now Second-Line Treatment. *J Am Coll Surg.* 2010 Jun;210(6):975–83.
11. Santos-Rosa OM Dos, Lunardelli HS, Ribeiro-Junior MAF. PYOGENIC LIVER ABSCESS: DIAGNOSTIC AND THERAPEUTIC MANAGEMENT. *Arq Bras Cir Dig.* 2016 Jul 1;29(3):194–7.
12. F A CY, M TY, F LH, H TK, H G LR, H TB. Management of pyogenic liver abscesses-percutaneous or open drainage? Vol. 48, *Pictorial Essay Singapore Med J.* 2007.
13. Trillos-Almanza MC, Restrepo Gutierrez JC. How to manage: Liver abscess. *Frontline Gastroenterol.* 2021 May 1;12(3):225–31.
14. Rahimian J, Wilson T, Oram V, Holzman RS. Pyogenic Liver Abscess: Recent Trends in Etiology and Mortality [Internet]. 2004. Available from: <http://cid.oxfordjournals.org/>
15. Wells CD, Arguedas M. Amebic liver abscess. *South Med J.* 2004;97(7):673-682. doi:10.1097/00007611-200407000-00013
16. Cerwenka H. Pyogenic liver abscess: Differences in etiology and treatment in Southeast Asia and central Europe. *World J Gastroenterol.* 2010 May 28;16(20):2458–62.
17. Yin D, Ji C, Zhang S, Wang J, Lu Z, Song X, et al. Clinical characteristics and management of 1572 patients with pyogenic liver abscess: A 12-year retrospective study. *Liver International.* 2021 Apr 1;41(4):810–8.
18. Roediger R, Lisker-Melman M. Pyogenic and Amebic Infections of the Liver. Vol. 49, *Gastroenterology Clinics of North America*. W.B. Saunders; 2020. p. 361–77.

19. Alvarez JA, González JJ, Baldonado RF, Sanz L, Carreño G, Jorge JI. Single and multiple pyogenic liver abscesses: etiology, clinical course, and outcome. *Dig Surg.* 2001;18(4):283-288. doi:10.1159/000050153
20. Lee KT, Wong SR, Sheen PC. Pyogenic liver abscess: an audit of 10 years' experience and analysis of risk factors. *Dig Surg.* 2001;18(6):459-466. doi:10.1159/000050194
21. Pearce NW, Knight R, Irving H, Menon K, Prasad KR, Pollard SG, et al. Non-operative management of pyogenic liver abscess. *HPB.* 2003;5(2):91-5.
22. O'Farrell N, Collins CG, McEntee GP. Pyogenic liver abscesses: Diminished role for operative treatment. *Surgeon.* 2010 Aug;8(4):192-6.
23. Rismiller K, Haaga J, Siegel C, Ammori JB. Pyogenic liver abscesses: a contemporary analysis of management strategies at a tertiary institution. *HPB.* 2017 Oct 1;19(10):889-93.
24. Petri A, Höhn J, Hódi Z, Wolfárd A, Balogh Á. Pyogenic liver abscess - 20 Years' experience: Comparison of results of treatment in two periods. *Langenbecks Arch Surg.* 2002;387(1):27-31.
25. Ferraioli G, Garlaschelli A, Zanaboni D, Gulizia R, Brunetti E, Tinozzi FP, et al. Percutaneous and surgical treatment of pyogenic liver abscesses: Observation over a 21-year period in 148 patients. *Digestive and Liver Disease.* 2008 Aug;40(8):690-6.
26. Malik AA. Pyogenic liver abscess: Changing patterns in approach. *World J Gastrointest Surg.* 2010;2(12):395.
27. Khan R, Hamid S, Abid S, Jafri W, Abbas Z, Islam M, et al. Predictive factors for early aspiration in liver abscess. *World J Gastroenterol.* 2008 Apr 7;14(13):2089-93.
28. McNeil T, Daniel S, Gordon DL. Management of pyogenic liver abscess: a South Australian experience. *ANZ J Surg.* 2020 Nov 1;90(11):2274-8.
29. Mangukiya DO, Darshan JR, Kanani VK, Gupta ST. A Prospective Series Case Study of Pyogenic Liver Abscess: Recent Trends in Etiology and Management. *Indian Journal of Surgery.* 2012 Oct;74(5):385-90.
30. Mišek T, Ciostek P. Percutaneous treatment of liver abscess – outcomes. *PrzGastroenterol.* 2019;14(2):129-32.
31. Ogawa, T., Shimizu, S., Morisaki, T. et al. The role of percutaneous transhepatic abscess drainage for liver abscess. *J HepBilPancrSurg* 6, 263-266 (1999). <https://doi.org/10.1007/s005340050116>
32. Dulku G, Mohan G, Samuelson S, Ferguson J, Tibballs J. Percutaneous aspiration versus catheter drainage of liver abscess: A retrospective review. *Australasian Medical Journal.* 2015;8(1):7-18.
33. Haider SJ, Tarulli M, McNulty NJ, Hoffer EK. Liver Abscesses: Factors That Influence Outcome of Percutaneous Drainage. *AJR Am J Roentgenol.* 2017;209(1):205-213. doi:10.2214/AJR.16.17713
34. Ahmed M, Alam J, Hussain S, Aslam M. Prospective randomized comparative study of percutaneous catheter drainage and percutaneous needle aspiration in the treatment of liver abscess. *ANZ J Surg.* 2021 Mar 1;91(3):E86-90.

35. Kulhari M, Mandia R. Prospective randomized comparative study of pigtail catheter drainage versus percutaneous needle aspiration in treatment of liver abscess. *ANZ J Surg.* 2019 Mar 1;89(3):E81–6.
36. Mahmoud A, Abuelazm M, Ahmed AAS, Elshinawy M, Abdelwahab OA, Abdalshafy H, et al. Percutaneous catheter drainage versus needle aspiration for liver abscess management: an updated systematic review, meta-analysis, and meta-regression of randomized controlled trials. *Ann Transl Med.* 2023 Mar;11(5):190–190.
37. Lin JW, Chen CT, Hsieh MS, Lee IH, Yen DHT, Cheng HM, et al. Percutaneous catheter drainage versus percutaneous needle aspiration for liver abscess: a systematic review, meta-analysis and trial sequential analysis. *BMJ Open.* 2023 Jul 30;13(7).
38. Kumar R, Ranjan A, Narayan R, Priyadarshi RN, Anand U, Shalimar. Evidence-based therapeutic dilemma in the management of uncomplicated amebic liver abscess: A systematic review and meta-analysis. *Indian Journal of Gastroenterology.* 2019 Dec 1;38(6):498–508.
39. Akgun, Y., Tacyildiz, I. &Çelik, Y. Amebic Liver Abscess: Changing Trends over 20 Years RID="" ID="" This study was presented to the Turkish Surgical Congress in Izmir, Turkey. . *World J. Surg.* 23, 102–106 (1999). <https://doi.org/10.1007/s002689900573>
40. Alkofer B, Dufay C, Parienti JJ, Lepennec V, Dargere S, Chiche L. Are pyogenic liver abscesses still a surgical concern? A Western experience. *HPB Surg.* 2012;2012:316013. doi:10.1155/2012/316013
41. Pitt HA. Surgical management of hepatic abscesses. *World J Surg.* 1990;14(4):498-504. doi:10.1007/BF01658675
42. Justo I, Vega V, Marcacuzco A, Caso Ó, García-Conde M, Manrique A, et al. Risk factors indicating the need for surgical therapy in patients with pyogenic liver abscesses. *Langenbecks Arch Surg.* 2023 Dec 1;408(1).
43. Ng SSM, Lee JFY, Lai PBS. Role and outcome of conventional surgery in the treatment of pyogenic liver abscess in the modern era of minimally invasive therapy. *World J Gastroenterol.* 2008 Feb 7;14(5):747–51.
44. Ndong A, Tendeng JN, Diallo AC, et al. Efficacy of laparoscopic surgery in the treatment of hepatic abscess: A systematic review and meta-analysis. *Ann Med Surg (Lond).* 2022;75:103308. Published 2022 Jan 31. doi:10.1016/j.amsu.2022.103308