

A waistline skin cancer (Dhoti cancer) In India : Case Report

Abstract

Squamous cell carcinomas developing along the waistline as a result of prolonged wearing of cotton garments such as dhoti in males and sarees in females are predominantly observed in the traditional Indian population. This specific type of waistline squamous cell cancer in Indian males who exclusively wear dhoti has been rarely documented in English literature. The continuous irritation caused by years of wearing these clothes leads to skin degeneration, glazing, dermatosis, acanthosis, scar formation, and eventually malignant transformation. Any hypo-pigmented patch and acanthosis in the waist area of a man wearing a dhoti should raise suspicion, necessitating ongoing surveillance.

We present the case of a 70-year-old male with a 4x3 cm ulceroproliferative growth on the right waistline, associated with a history of prolonged dhoti use. The treatment involved wide local excision of the growth with a 2 cm margin, and the wound was closed primarily by mobilizing the surrounding skin. Continuous monitoring is essential for early detection and intervention in such cases.

Key words

Acanthosis dhoti cancer, squamous cell cancer, waistline skin cancer case report

Introduction

“Skin cancer accounts for less than 1% of all cancers in India, with basal cell carcinoma being the most prevalent cutaneous malignancy. Following basal cell carcinoma, squamous cell carcinoma is the second most common. Traditional Indian garments, saree worn by females and dhoti by males, are used to cover the lower parts of the body”. [1,2,3]

The term "dhoti cancer" was coined by Khanolkar in 1945 to describe a specific type of waistline squamous cell cancer observed in Indian males who wear dhoti. “This condition can be considered a variant of scar cancer, as described by Marjolin in 1828. Prolonged friction from the tight knot of the dhoti around the waist at a consistent position leads to pigmentation and scale-like changes in the skin, eventually progressing to malignant transformation”. [2,3,4]

The knowledge and awareness of this rare malignancy are limited within the Indian medical community, despite it being predominantly observed in this population. Therefore, there is a crucial need to publish and disseminate information about such cases to enhance awareness and understanding within the medical fraternity. [1,2,5]

Case Report

On February 15, 2017, a 70-year-old male patient presented at our centre with a painless, gradually progressive ulceroproliferative growth on the right side of the waist, persisting for the past 12 months. The patient reported a history of tightly tying a cotton dhoti around the waist for the last 50 years.

Upon local examination, the right waist exhibited a non-tender, hypopigmented skin area, accompanied by an ulceroproliferative growth measuring 4x3 cm with an irregular surface and everted margins. A small white patch of hypopigmented skin was noted beneath the aforementioned lesion. Bilateral groin examination revealed no inguinal lymphadenopathy. The rest of the systemic examination yielded normal results, and all laboratory blood investigations were within normal limits. Based on clinical suspicion, the patient underwent a wide local excision of the growth under spinal anaesthesia, ensuring a clearance margin of 2 cm. The resulting skin defect was closed primarily by mobilizing the skin flap.

Histopathology reports confirmed the presence of squamous cell carcinoma with tumour-free margins. Postoperatively, the wound healed well without any complications. After a five-year follow-up, no locoregional recurrence was observed. (Fig 1-4)

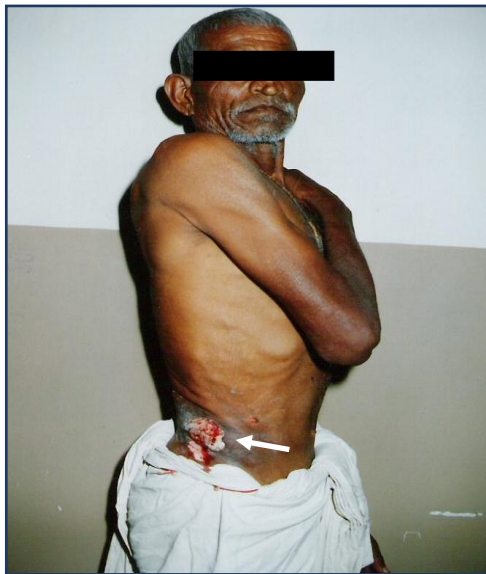

Fig-1 photographs showing ulceroproliferative growth On Right waist

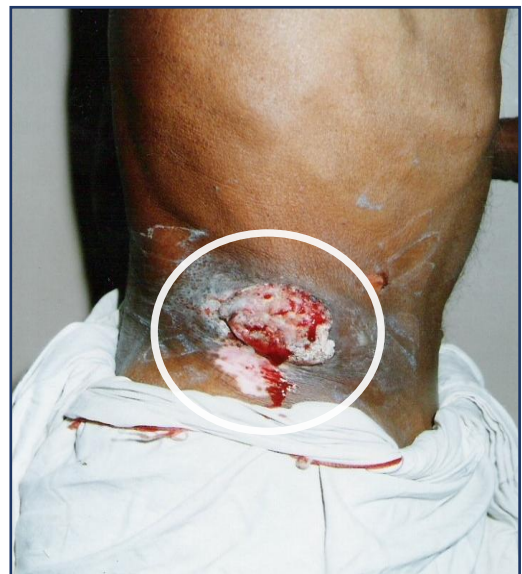

Fig-2 photographs showing ulcerative growth of size 4x3 cm with everted edges

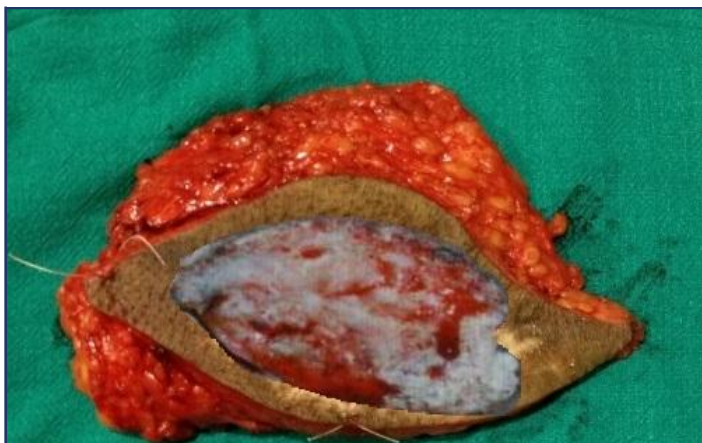

Fig-3 photographs showing wide excision of growth with 2 cm margin

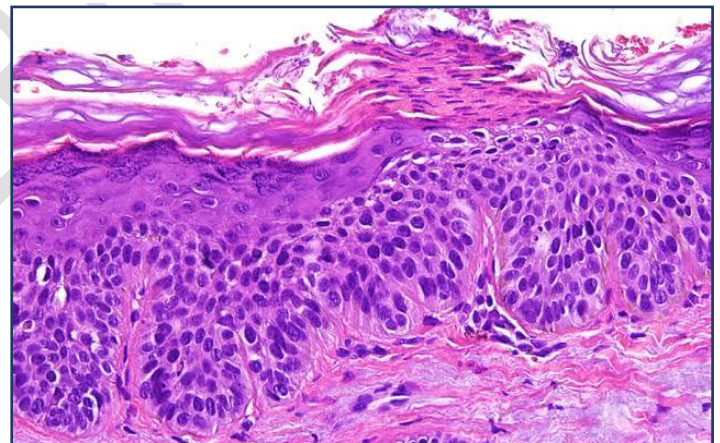


Fig-4 Histopathological photographs showing Squamous cell carcinoma

Discussion

In 1945, Khanolkar and Suryabhai coined the term "Dhoti cancer" to describe a form of waistline squamous cell carcinoma associated with the traditional practice of wearing dhoti by Indian males in the subcontinent. Similarly, the term "saree cancer" was used to denote squamous cell carcinoma of the waistline caused by the wearing of sarees by Indian women. Vasant Ramji Khanolkar, the first pathologist in India, made significant contributions to the epidemiology of skin cancer and was referred to as the "father of pathology and medical research in India." [1,2,9]

"The typical manner in which a dhoti is worn involves a tightly knotted waist with one end extending below the groin and tucked at the back. The prolonged presence of a tight knot around the waist, compounded by the hot and humid tropical climate and poor hygiene, particularly in rural India, leads to skin friction. This persistent irritation, exacerbated by the accumulation of sweat and dust within the knot tying area, results in pigmentation, dermatoses, glazing of the skin, acanthosis, scar formation, and eventually malignant transformation". [1,4,7]

“Several hypotheses exist for the development of this waistline skin malignancy, including continuous irritation causing cellular damage and repair leading to malignant transformation. Another hypothesis suggests a depressed immunological state due to surrounding scar tissue and lymphatic damage, potentially affecting the antitumor immunogenic response”. [11]“Dhoti and saree cancer may be considered variants of scar cancer, with Marjolin describing squamous cell carcinoma developing in scars in 1928. A genetic hypothesis implicates human leukocyte antigen (HLA-DRG) and mutations in P53 or FAS genes in scar-related malignancies”. [5,6,8]

“The surgical treatment for well-localized dhoti cancer involves wide local excision of the skin with a 2 cm margin, followed by primary closure or split skin grafting to cover the raw area. Squamous cell carcinoma is most curable in its early stages, with a five-year survival rate of approximately 99% if diagnosed early. In cases where the growth infiltrates the surrounding skin or underlying muscles, or if inguinal lymph nodes are involved, wide excision of the skin with skin grafting, radiotherapy to inguinal lymph nodes, and chemotherapy may be required”. [1,2,10]

Radiological investigations such as CT scans or PET scans have limited roles, primarily to evaluate metastasis. Non-surgical options include the topical application of 5-fluorouracil and imatinib in low-risk groups. Local radiotherapy and chemotherapy are also potential treatment modalities. [2,3,5]

In the presented case, which was diagnosed as stage 1 squamous cell carcinoma with no spread to inguinal lymph nodes, wide local excision with a minimum 2 cm surgical margin and primary skin closure was deemed appropriate. The treatment was successful, and there was no recurrence observed during the 5-year follow-up period. [2,5,6]

Conclusion

Dhoti cancer or waistline cancer is one among the rare malignancy reported in the Indian subcontinent. Wide local excision with a surgical margin of at least 2 cm together with primary skin closure or skin grafting is considered as the appropriate treatment. Any hypopigmented patch and acanthosis on the waist area in a dhoti clad man should be viewed with suspicion and continuous surveillance is needed thereof.

Ethical Approval:

As per international standard or university standards written ethical approval has been collected and preserved by the author(s).

Consent

As per international standards or university standards, patient(s) written consent has been collected and preserved by the author(s).

References

1. Midya M, Sukheeja D, Rao J, Prakash G. Dhoti cancer revisited. J Family Med Prim Care. 2019 Mar;8(3):1235-1238. doi: 10.4103/jfmpc.jfmpc_113_19. PMID: 31041280; PMCID: PMC6482766.
2. Akhtar, M.A., Saxena, D.K., Chikhlikar, A.A. et al. Dhoti cancer: a waistline skin cancer with review of literature. World J SurgOnc 13, 281 (2015). <https://doi.org/10.1186/s12957-015-0698-z>
3. S Labani S Asthana K Rathore K Sardana Incidence of melanoma and nonmelanoma skin cancers in Indian and the global regions J Can Res Ther 2021;17(4):906-1110. doi:10.4103/jcrt.JCRT_785_19

4. S. Lal, Jayanta Bain, A.K.Singh, P.K. Shukla, Saree Cancer: The Malignant Changes in Chronic Irritation, ID: JCDR/2012/4333:2248
5. Rawat S, Haritha VS. Dhoti cancer – A name forgotten, IP Int J Med PaediatrOncol 2022;8(2):69-72
6. Kaveri Shaw, JagadishwarGoud G, Vikas Kumar MB, ArunKatari, KiranmaiGottapu V. Waist line skin cancer: A case report. J Med Sci Res 2014; 2(1):21-23.
DOI: <http://dx.doi.org/10.17727/JMSR.2014/2-004>
7. Tiwari SJ, Yadgire AY, Umale NP. A precancerous saree lesion: a rare occurrence. Int J Sci Rep 2015;1(4):206-9
8. Gargade CB, Desai AY. Saree cancer: A case report. South Asian J Cancer 2019;8:101-7. © 2019 The South Asian Journal of Cancer | Published by Wolters Kluwer – Medknow
9. Sanjay A. Pai, V.R. Khanolkar: Father of pathology and medical research in India, Annals of Diagnostic Pathology, Volume 6, Issue 5, 2002, <https://doi.org/10.1053/adpa.2002.35754>.
10. Takalkar, Unmesh Vidyadhar et al. "Saree Cancer in Indian Woman Treated Successfully with Multimodality Management." *Dermatology Reports* 6 (2014): n. pag.
11. Akhtar MA, Saxena DK, Chikhlikar AA, Bangde AP, Rangwala M. Dhoti cancer: a waistline skin cancer with review of literature. World Journal of Surgical Oncology. 2015 Dec;13(1):1-3.