

Original Research Article

Efficacy of Eye Drops Extracted From *Lycium Shawii* Schult & Roem In Treating Old Corneal Scar In Rabbits.

Abstract

The purpose of the study to evaluate the efficacy of eye drops extracted from *Lycium Shawii* Roem & Schult leaves in treating old corneal scars in rabbit corneas. A corneal scar is a condition in which the cornea becomes opaque. The cornea is a transparent, avascular tissue. Corneal scars are the fifth leading causes of vision impairment worldwide. In a randomized controlled trial, twelve European pigmented rabbits with a twenty four eyes with a mean weight of 1.12 kg (SD ± 0.16 kg), aged 5 to 6 months old, were subjected to a partial thickness (120–180 µm) sterile surgical excision on the anterior central part of the cornea with a 7 mm diameter. After the surgical procedures, we waited six weeks for stable, old corneal scars to develop, after that rabbits received topical drops as one eye drops three time /day for two months, *lyciumshawii* leaves extract for treatment group (10%; n=12), placebo (normal saline 9% ;n=00) for control group. Therapy effects on corneal scar and ocular safety were evaluated by slit-lamp microscope, Modified Fantes haze scale for grading. The results demonstrated the treatment group had a statistically significant reduction in corneal scar ($P < 0.000$), mean 2.75 degree, standard deviation ± 0.45, and a 68.75% improvement in corneal clarity ($P < 0.000$), mean 0.25 degree, standard deviation ± 0.45. In conclusion therapy is effective and safe in treating old corneal scar in rabbit and restores the transparency without ocular toxicity even after 2.5 years of follow up.

Key word : Corneal scar /opacity; *lyciumshawii*; Awsaj.

1. Introduction

Corneal scar is a condition in which the cornea becomes cloudy or opaque. The cornea is a transparent, avascular tissue that covers the outermost part of the eye ball and provides approximately two-thirds of the refractive power of the eye. The human cornea is composed of five layers:

1. Epithelium.
2. Bowman.
3. Stroma.
4. Descemet membrane.
5. Endothelium (1).

The most common causes of corneal scarring include trachoma, infectious keratitis, xerophthalmia and ocular trauma (2). According to WHO corneal scar is the fifth cause of vision impairment. Approximately 2.2 billion people worldwide are visually impaired. The annual global costs of productivity losses associated with vision impairment estimated to be US\$ 411 billion (WHO). Corneal opacity is estimated to account for 3.2% of all causes of blindness. In general, infectious keratitis is the most common problem in low and middle income countries. The most popular treatments of corneal scar is corneal transplantation, but this is not always possible, practical, or successful, and thus the mission to eliminate corneal blindness requires more than simply increasing access to transplantation

(3). Following corneal transplantation, a visually significant complication that can occur even years after initial surgery known as post- penetrating keratoplasty, corneal ectasia. Endothelial failure caused long-term failure (4,5). Drug delivery to the corneal tissues is difficult and challenge because the mechanical barriers that protect the cornea as multi layered epithelium, tight junctions that limit ocular drug delivery. Lipophilicity, partition coefficient, and molecule size are the primary factors that affect corneal medication absorption. Nano carriers may be a viable option for targeted ocular medication delivery (6). The breakdown of these suspended particles contributes to ocular medication absorption. The biopharmaceutical influence and interplay of formulation parameters such as viscosity and particle size have not been studied or analyzed in depth. These factors may have a major impact on ocular medication absorption in the eye. Ocular bioavailability of drugs after eye drop administration to rabbits is limited to less than 5% of the instilled dose, often less than 1% . This is due to several limiting factors:

1- The permeation barrier of the corneal epithelium. 2- Rapid drainage of the instilled drug from the ocular surface. 3- Effective trans conjunctival drug absorption into the systemic blood circulation (7).

The aim of this study is to evaluate the efficacy of Lycium Shawii Roem & scutleaves extracts as eye drops on old corneal scars and to find a treatment in the form of eye drops that can be used anywhere, is easily accessible to patients in need, and is inexpensive for the treatment of corneal scars.

The rabbit model was chosen in ophthalmic experimental studies because the eyes of rats, hamsters, guinea pigs, and mice are small that surgery is difficult to perform. Rabbit corneas, on the other hand, have a large diameter of about 15 mm. the arrangement of the corneal epithelium, stromal lamellae, and endothelium is also somewhat similar to that of human corneas (8).

There are some differences between the human and rabbit corneas, which we will explain as follows:

1. Differences in drug delivery between rabbit and human. The fact that the conjunctival corneal surface area ratio in man is approximately twice that of rabbit shows that there is a substantially large surface area for drug adsorption via the conjunctiva in man vs. rabbit, as well as a smaller surface area for drug absorption via the cornea in man (9). 2. The rabbit stroma fibrils are more organized than human stroma fibrils may be due to variances in the state of the final implanted tissue rather than an actual quantitative difference between species (10). 3- In adults human , the cornea measures around 12 mm in the horizontal meridian and approximately 11 mm in the vertical meridian (11). Rabbit corneas, on the other hand, have a large diameter of about 15 mm. 4. Rabbit corneas do not have a well developed Bowman's membrane, The descemet's membrane is also present, but the collagen arrangement is different from that of the human cornea (8). 5. The pigmented rabbit's central corneal thickness is nearly 150 μ m thinner than the human's. Similar to the human cornea distribution, the inferior temporal quadrant has the thinnest corneal thickness (12). The central cornea in humans is 0.5 mm thinner than the peripheral cornea, which is 1.0 mm thicker, with an average radius of curvature of 7.8 mm (11). The central corneal thickness in rabbits is $341 \pm 14 \mu$ m at one month, $391 \pm 16 \mu$ m at

six months, and 404 ± 12 mm at twelve months. 6. The central corneal thickness (CCT), corneal curvature, and refractive state of the rabbit's cornea change dramatically during the first few months of life. Keratometry decreases with age, while CCT and spherical equivalent refraction increase. In the human newborn to 6-month old group, the mean keratometry in diopter (D) was 46.82 ± 2.11 D (range: 44.08 - 49.50 D). Keratometry gradually dropped and appeared to stabilize at about 54 months. The mean corneal keratometry in rabbits aged 1-6 months was 45.60 ± 2.77 D (range: 41.24 - 51.88 D) and appeared to settle at around 9 months (41.30 ± 1.37 D). In corneal experimental studies using rabbits as an animal model, it is critical to account for ocular parametric changes (8).

The old corneal scars formed in a rabbit model of a deep corneal wound between 6-8 weeks of healing, resulting in deep and dense scars. (13,14) and other studies discovered no significant change in measurements from day 28 to day 56, indicating that the opacity and its optical and morphological properties stabilized between these time-points (15). Previous studies have shown that 4 weeks following a corneal wound, the stable scar time in mice is ideal (16).

Mechanism of scar formation

Corneal wound closure following a serious ocular trauma commences the process of corneal fibrosis, transforming a healthy cornea into a scarred cornea. The migration and proliferation of corneal epithelial cells is followed by the differentiation of stromal keratocytes into myofibroblasts, the excess deposition of extracellular matrix (ECM) components, an increase in alpha smooth muscle actin (α -SMA) expression, and ECM remodeling, resulting in corneal opacity. The corneal scarring process continues long after the wound has healed, exacerbating the problem. Keratocytes resume their dormant condition during wound healing, and the immune cells are no longer present. Due to its low regenerative capacity, the disrupted Bowman's membrane does not regenerate. This causes extracellular vesicles and persistent fibroblast cells to invade the stromal layer on a continuous basis, accumulating Transforming growth factor- β (TGF- β) and Platelet-derived growth factors (PDGF) and (17). promote tissue repair (18). Repetition of corneal ECM remodeling as a result, scarring of the cornea is a direct result of the multiplexed corneal wound-healing process (17). *The corneal epithelium* is made up of 4-6 layers, including 1-2 layers of superficial squamous cells, 2-3 layers of broad wing cells, and a layer of columnar basal cells in the innermost layer. Tight junction between surface epithelial cells prevent tear fluid from penetrating the stroma. The replacement of damaged layers is caused by the constant proliferation of limbal stem cells. This process takes between 7 and 14 days, which results in a layer with a nearly uniform refractive index and minimal light scattering. *Bowman layer* is an acellular membrane that lies anterior to corneal stroma layer that helps maintain the shape of the cornea. When there is a damage it will not regenerate. *Corneal stroma* accounts for roughly 90% of total corneal thickness. A clear cornea requires a regular arrangement of stromal cells (keratocytes), fibers, and extracellular matrix. They are fibroblasts that have been flattened and are found between the stromal collagen lamellae. The stroma is made up of an extracellular matrix made up of collagens and proteoglycans. Type I and type V fibrillar collagens are intertwined with type VI collagen filaments. Decorin (associated with dermatan sulfate) and lumican (associated with keratan

sulfate) are the two most important corneal proteoglycans. Corneal transparency is dependent on keeping the corneal stroma's water content at 78%. Corneal hydration is largely controlled by intact epithelial and endothelial barriers, as well as the endothelial pump's function. *Descemet membrane* is the corneal endothelial basement membrane. Corneal endothelial cells form a monolayer of closely interdigitated cells on the cornea's posterior surface. Human endothelial cells are thought to have limited proliferate, but they can divide in culture. Cell density decreases with age at an average rate of about 0.6% per year, starting at about 3400 cells/mm². through its functions as a barrier to the aqueous humor and as a metabolic pump that moves ions and draws water somatically from the stroma into the aqueous humor, the endothelium maintains corneal transparency by controlling corneal hydration and maintaining stromal deturgescence (1). The cornea endothelium When injured, it heals through migration and enlargement of the cells. existing cells. interleukin-1(IL-1) which causes keratocytes in the stroma to die, helps to increase cell migration during endothelial healing Endothelial damage causes to keratocyte apoptosis in the stroma posterior. It is unknown whether endothelial Myofibroblasts are formed in the stroma as a result of injury. Endothelial cells, on the other hand, acquire the myofibroblastic phenotype, also known as endothelial to the transition from the mesenchymal to the epidermis, this transition results in a potentially hazardous situation. endothelial fibrosis complication that forms a retrocorneal membrane (19).

To the best of our knowledge, there are no effective topical ocular medications that can be easily used or manufactured to treat corneal scars right now. Furthermore, this is the first study to evaluate the efficacy of Lyciumshawii Roem & Shult leaves extract in treating an old corneal scar in vivo.

Treatment of corneal scar

Corneal transplantation is the gold treatment for corneal opacity, alternative techniques to penetrating keratoplasty (PK) include: Lamellar corneal transplants, which replace only the damaged layers, Both the anterior (deep anterior lamellar keratoplasty, (DALK) and posterior modalities, Descemet's membrane endothelial keratoplasty (DMEK) and its modifications, of these lamellar methods are now in use and are replacing PK in the majority of referral centers worldwide. To present, clinical studies and meta-analyses have shown that PK has similar results and prognoses to lamellar corneal transplantation (20). Post penetrating keratoplasty corneal ectasia is a visually significant complication that can occur even years after initial surgery. Long-term failure was caused by endothelial failure (4,5). The most common reasons for high failure rates are lax corneoscleral tissue, a more aggressive inflammatory response, persistent intraocular inflammation and glaucoma. The survival rates of grafts treated for acquired traumatic corneal opacities are poor (63% failure rate). Regraft procedures also have failure rates of up to 80%. Graft survival in pediatric patients is less promising than in adult patients and is heavily dependent on the patient's age (5). With penetrating keratoplasty, the Australian Corneal Graft Registry reported 89% graft survival at 5 years, 49% at 15 years, and 17% at 23 years. There are approximately 12.7 million people on the global waiting list for corneal transplantation (21). Corneal transplantation surgery treatments are limited due to postoperative complications such as infection and delayed healing, immune rejection and

failure of the transplant, intraocular pressure elevation, and a general scarcity of donor corneas as a result of the increased popularity of laser refractive surgery (22,23). Femtosecond lasers (FSLs) are a recent technological breakthrough in ophthalmic surgery. Theoretically, refractive surgery and corneal surgery have advantages over manual techniques that involve cutting corneal tissue. Femtosecond laser-assisted ophthalmic surgery. FS-LASIK: femtosecond laser-assisted laser in situ keratomileusis. SMILE: small incision lenticular extraction. FS-AK: femtosecond laser assisted astigmatic keratotomy. FSPKP: femtosecond laser-assisted penetrating keratoplasty. FSDALK: femtosecond laser-assisted deep anterior lamellar keratoplasty. FSDSEK: femtosecond laser-assisted Descemet's stripping endothelial keratoplasty. FS-DMEK: femtosecond laser-assisted Descemet's membrane endothelial keratoplasty (24).

Stem cell therapy: A variety of treatments have been attempted to improve scarless corneal regeneration. Stem cell therapy using various types of stem cells can rebuild the cornea by renewing and restoring damaged cells and breaking down the scar extracellular matrix. Stem cell secretions (secretomes, extracellular vesicles, and exosomes) have also recently been employed in corneal regeneration. Stem cell therapy can stimulate corneal regeneration by differentiating into corneal epithelial cells, keratocytes, or endothelial cells to replenish the lost/damaged cells; and activating the resident stem cells at the site of injury to aid in damage repair. Secreting regenerative cytokines or growth factors that can reduce inflammation, remodel scar deposits, and boost regeneration by activation of various signaling pathways (21). The use of the amniotic membrane as an ocular bandage because of its antiangiogenic and antifibrotic properties is a popular treatment method. However, their use is limited because of ethical problems related to tissue donation, potential risks of the transmission of diseases, inter-amnion variability, and reproducibility (27). The amnion's bandaging function dampens the cascade of fibrogenic signaling during the various phases of repair. Alternative therapy options include the creation of amniotic membrane extract drops (18). There was a study that discovered the group that only received amniotic stem cells to treat corneal opacity caused by chemical alkaline burn showed transient improvement, while the other two groups that received limbal stem cells alone or in combination with amniotic stem cells improved their recovery time quickly (25). Another study revealed that mesenchymal stem cells might restore corneal transparency by secreting hepatocyte growth factor. The ability of umbilical mesenchymal stem cell transplantation to cure corneal opacity in the congenital mice model but not in acquired (22).

The most common available treatments

Steroids and other medications that entail the danger of various side effects, necessitate repeated administrations, and are frequently inefficient in entirely recovering vision. Although mitomycin C (MMC) is common topical treatment for corneal fibrosis, its usage remains controversial due to long-term negative effects. MMC, toxicity, and DNA damage to endothelial cells may have long-term deleterious effects on ocular health (21,26). Topical eye drops are a simple method of administration, but their limited bioavailability and fast ocular surface drainage limit their popularity (27).

New methods therapy or trail therapy

Gene therapy: Exosomes, micro RNAs (miRNAs), recombinant viral vectors, bioactive molecules, growth factors, histone deacetylase inhibitors, and nanotechnology have been targeted as therapeutic tools for treating scarred cornea (17). Cholesterol-conjugated completely modified asymmetric small interfering RNAs (siRNAs) (self-deliverable siRNAs [sdRNAs]) are a unique method for in vivo gene knockdown that transfects cells and tissues without the need of any extra formulations (28). Nonviral gene delivery techniques based on synthetic polycations, such as polyethylene amine (PEI), demonstrate potential as delivery systems in order to use gene therapy (29). A gold-standard method for preventing corneal scarring is still being researched. Decorin, glucosamine, acetylcholine, and chitosan are examples of biomolecules (17).

Decorin: Decorin consistently produces a surface coat on collagen fibrils on a regular basis, decorin expression is not elevated during mechanical and surgical damage in rabbits because of the surface coat. Decorin expression is adequate to sustain normal collagen fibrillogenesis in biglycan deficient mice and does not result in a compensatory increase. It is uncertain whether or if these compensatory interactions occur in humans during development and adulthood (19).

Glucosamine: This amino sugar has medicinal use in the treatment of osteoarthritis. However, it considerably enhances intraocular pressure. Park et al. discovered that glucosamine attenuated renal fibrosis by inhibiting SMAD2 phosphorylation.

Acetylcholine: Cholinergic receptors release acetylcholine, a neurotransmitter. Acetylcholine binds to its nicotine receptor, generating an influx of Na⁺ or Ca²⁺ ions as well as an efflux of K⁺ ions. This affects several signaling pathways via protein kinases and phosphatases, and it can also activate many downstream signaling pathways via a murine receptor (mAChR) by activating protein kinase C. CECs include mAChR (M1, M3) and nAChR, and acetylcholine can induce reepithelialization in a damaged rat cornea (27).

LyciumShawii Roem& Shult.

Is a thorny shrub of the Solanaceae family, a genus of flowering plants in the nightshade family. There are around 90 different varieties of (Solanaceae). Because of the availability of diverse physiologically active components, they play key roles in nutritional and therapeutic applications (30). *LyciumShawii* Roem & Shult (L.S) has the Arabic name Awsaj and the Yemeni local name Awsaj or Zarb. It found throughout the Arabian Peninsula, Southwest Africa, and the Mediterranean basin. It has the potential to grow to a height of 4 meters. It is densely branched and has small thorns. The little dark green leaves are 7 mm broad, the blooms are star-like white or lilac in hue, and the fruit is pea-size crimson berries (31). L.S contains peptides, flavonoids, polysaccharides, alkaloids, ceramides, anthraquinones, coumarins, steroids, terpenoids, organic acids, carotenoids, cinnamic acid amides, lignans, neo-lignan amides, and lignan amides (32). Plant leaves had a higher percentage of total flavonoids, tannins, saponins, and alkaloids than the stem. Arginine had the highest concentration of protein amino acids in plant leaves. The biologically active elements of L.S. leaves

are: 2, 3 dihydroxy benzoic acid, quercetin, gallic acid, rutin, p-coumaric acid, ferulic acid, quercetin 3-methoxy glucoside, quercetin 3,7 diglucoside and quercetin 3-O- glucoside. L.S. leaves have a variable chemical composition depending on the season, total flavonoids increase gradually from autumn to spring, whereas total nitrogen, protein, and lipid are highest in winter, the percentage of (total and soluble) carbohydrates peaks in the summer. Flavonoids and phenolics perform a variety of functions, including antioxidants, superoxide radical scavengers, mineral uptake chelators, enzyme inhibitors, and regulators (33). L.S. leaves are used to treat eye diseases and stomach tumors in Yemeni folk medicine (34). The Lycium genus has anti-diabetic, anti-cancer, and antioxidant properties. In folk medicine, the aerial parts of the plant are used as a laxative and diuretic, while the fruit is used to heal jaundice and protect the liver from damage (35).

2. Material and Methods

2.1. Sample collection and authentication

The leaves of Lycium Shawii Roem & Schult (L.S) were collected in December 2016 from the city of Sana'a, Yemen, at an altitude of 2,200 meters (7,200ft), Coordinates: 15°20'54"N 44°12'23"E, with the agreement of the authorities and in accordance with the United Nations Convention on Biodiversity, and with the assistance of traditional medical practitioners.

The plant material was authenticated by Professor Hasan Ibrahim (botanist from faculty of science - Sana'a University) and a voucher specimen was deposited in the herbarium of the botany department.

2.2. Samples preparation and extraction

Lycium shawii roem & schult leaves were washed with distilled water and dried in room temperature for one week in the semi dark room. The aqueous plant extract was prepared by adding 500ml distilled water to the 200 mg leaves powder ground in mortar and boiling for 30 minutes. Decoctions were allowed to cool at ambient temperature before being filtered using Whatman Grade No.1 filter paper and evaporated to dryness using a rotary evaporator (Yamato Scientific Co., Ltd. USA) at 40 C, then freeze-dried and stored (36).

2.3. Study design, location, duration and approvals

A randomized controlled trial (RCT) was conducted from December 19, 2017 to July 31, 2023. The experiment lasted eight months, beginning on February 19, 2017 and ending on October 17, 2017. However, due to the nature of the war and blockade that erupted in our country from 2015 to the present, the analysis of the results and publication of the study had to be postponed for five years. Over the course of five months, the results were analyzed, and the study was written and printed.

The study was conducted at the Ziad scientific research unit in Sana'a, Yemen. The ethics committees of the respective institutes approved the study, and the animals were handled in accordance with the Association for Research in Vision and Ophthalmology (ARVO) statement on the use of animals in Ophthalmic and Vision Research (ARVO) statement on the use of animals in Ophthalmic and Vision Research. The IACUC Guidelines for Rodent and Rabbit Anesthesia, Analgesia and Tranquilization, and Euthanasia were followed.

2.4. Experimental animal model of corneal scar

Twelve European pigmented rabbits weighing 1.00 to 1.200 kg (mean 1.12kg. SD \pm 0.16) at 5-6 monthold (young adult of both genders, seven female and five male), provided by a local contractor. As both eyes of each rabbit (n=24 eyes) were subjected to a partial thickness (120–180 μ m) sterile surgical excision on the anterior central part of the cornea with a 7 mm diameter. All of the rabbits were healthy, and the general clinical and ophthalmic examinations revealed that they were within normal. They were brought a week before starting anesthesia and surgical procedures to allow rabbits to acclimate to the facility and reduce stress (37). They were housed in a light-controlled environment at a predetermined room temperature, and they were fed on a regular basis. The cages were chosen with a single cage for each member, and the cages were placed on the ground and identified by letters and numbers on a metal plate. The sample size was relatively small because of the scarcity of resources and the country's current state of war.

2.5. Surgical and anesthesia procedures

Rabbits were fasted for 2 hours before being anesthetized by diazepam 2.5 mg/kg (diazepam-Hamlin 5 mg/ml ampoules 10 mg/2 ml, Hamlin Pharma, Germany) with ketamine hydrochloride 70–100 mg/kg (Ketamine 50 mg/ml Rotexmedica, Bach: 20905, Tritan, Germany) as a subcutaneous injection into the dorsum of the neck using a 25-gauge needle of a 1 cc syringe (tuberculin syringe/1 cc needle). cub e) 25ga. Household brand, USA). Topical lidocaine 2% (K.M. Lidocain HCL inj. 2%, Huons, Korea) was instilled to block corneal sensation, and supplemental heat was provided during anesthesia and recovery procedures, with monitoring for fetal signs.

Under aseptic condition the rabbit was placed on a surgical table, slightly tilted up with the head to the left. The peri-ocular area was cleaned with a gauze dipped in 10% povidone iodine (Povidone iodine extra 10%, pharmacare int. mfg. co, BNO: 21148, Yemen) and then covered with a sterile surgical towel. The eye was exposed using an eye speculum (Murdock, Eyespeculum with locking screw, AA 1080 small# appasamy), one drop of povidone-iodine 5% was instilled in the conjunctival cul-de-sac, waited 5 minutes, then irrigated with 15 ml. of 0.9 normal saline. The surgical procedure was carried out with the aid of a surgical magnifying loupe (3.5X loupe Bp fram surgical, Nanchang Micare medical equipment's, China) by assisted of a head light, with the incision made as follows: The corneas were trephined by 7.0 mm single used vacuum trephine (Barron Radial vacuum trephine, Corza medical ophthalmology, India) to induce corneal incision by rotated gently to create a circular incision about anterior one third to half of corneal thickness (120-180 μ m) then the trephined area dissected carefully by crescent 2.5 mm bevel up blade (Bioblade, Bio-Tech Vision Care Pvt. Ltd., India), the end of the incision was completed with a corneal scissor (micro corneal scissor curved, pointed tip, medium blade 11mm, AA 4105, Appasamy, India) assisted by corneal forceps (Calibri forceps 0.4 mm, 1x2 teeth with tie platform, AA 3035, Appasamy, India) to raise the corneal flap. Topical 1% tetracycline hydrochloride eye ointment (Zhejiang Jinwei pharmaceutical co., Ltd., China) was applied to the corneal wound before closing the eye lid. The wound is left to heal naturally. We had one case of corneal perforation as a surgical complication in the beginning of the operation, so we decided to stop the surgical procedure for this rabbit, moxifloxacin hydrochloride 0.5% preservative free eye drops (vigamox 5% Alcon, USA) 3 drops were instilled, the eye lid was closed with a plaster eye pad, this rabbit was excluded and replaced by another, and the corneal perforated wound was closed in the next day by wound healing processes, and the moxifloxacin 0.5% eye drops were administered four times daily for two weeks. Each operation took about 20 minutes. The rabbits are closely monitored after surgery to ensure that there are no complications, and appropriate postoperative care is provided. To make the rabbits more comfortable, they were placed in a quiet, semi-dark environment. The anesthetics and surgical procedures were both performed by the same trained ophthalmologist, who was also the only person who was aware of the treatment group allocation. Gentamicin sulphate 0.3% eye drops (gentamicin

sulfate eye/ear drops 0.3% 10 ml, E.I.P.I.Co.Egypt) were instilled in the operated eyes one drop five times per day for two weeks. For a week after surgery, oral analgesic 0.2% meloxicam (meloxicam tablets 7.5mg, Mobic — Boehringer Ingelheim ,Germany) was mixed into the drinking water.

2.6. Post-processing , photography and grading

Fluorescein sodium ophthalmic strip (1mg per fluorescein strip, Madhu Instruments, India) used to detect corneal epithelia defects (corneal ulcer) assisted by portable slit lamp (Shin-Nippon XL-1 LED Slit Lamp, Ohira Co. Ltd. Japan) with cobalt blue filter every 2 days was started in the third day then at 5, 7, 9, 11, 13 day post operative day, until reach complete corneal epithelial healing. The corneal wounds completely reepithelialized in all corneas from 11- 13 day Post operative ly.

After the surgical procedure, the rabbits were randomly distributed and divided into two experimental groups: the treatment group and the control group, with six rabbits in each group. This was achieved by using the standard = RAND() function in Microsoft Excel to generate random numbers. There was no systemic difference between the two groups of rabbits. After the surgical procedure, we waited six weeks for stable, old corneal scars to develop. (13, 14, 15). After that we started the instillation of eye drops for both groups, prepared as follows:

For the treatment group, the solid material extracted from L.S. leaves was diluted with distilled water at a concentration of 10% (L.S.D). For the control group, they received the placebo isotonic solution of 0.9% normal saline (N.S.).

The eye drops were then put inside a 5 cc syringe container to prevent the withdrawal of air from the surroundings, which could potentially be polluted during the instillation process. The needle was broken at the plastic junction. The instillation was performed vertically with a volume of approximately 25 μ m per eye drop. Samples were discarded and replaced with fresh drops after 72 hours. The remaining drops were kept in a refrigerator at a temperature between 4 and 8 °C. For both groups, the instillation was administered as one eye drop three times a day for two months. The eye drops were coded by numbers and were administered by the pharmacist using a randomization table. The same ophthalmologist monitored all rabbits every day and examined the corneas with a surgical magnifying loupe every three days, as well as with a portable slit lamp every week. The examinations were done without anesthesia and used a diffused, narrow slit light that was 1-1.5 mm wide, 10-mm long, and angled at 45 degrees between the observation and illumination axes.

2.7. Digital photography

Photography was taken according to IACUC protocol as much as possible by smart phone camera of Samsung galaxy S5 camera (Verizon G900V, 16 mega pixel, F22, 145s, 48mm, iso 40, white balance, with auto flash) before installation of the first dose of the treatment and after at 3, and 7 days, then 2, 4, 8, and 16 weeks (\pm 1 day) until the end of the study. Funduscopy was performed with direct ophthalmoscope (haene, Germany) before the surgical procedure, before treatment instillation, and at the end of the study with of mydriasis pupils by instillation of tropicamide 1% eye drops (mediacyl 1%, Alcon, UK) to identify any abnormal findings that could appear as side effects of the eye drop extracted from (L.S.D). The following procedures were used in photography rabbits' eyes: hold rabbit gently against assistant torso with their head tucked under one of assistant arms and assistant opposite hand grasping the rabbit's scruff, eye opened by using examiner thumb and index fingers with gentle pressure against periocular bones especially in lower lid without anesthesia, phone camera placed vertically to corneal plane with auto flashing in quiet light place, the same condition was used, the name of the group, the number of rabbits, the date, and the time were all recorded in the follow up chart.

At the end of the experiments stage, the rotating Scheimpflug camera corneal tomography (Pentacam, Oculus GmbH, Wetzlar, Germany) was used to capture corneal images. However, this imaging was only performed for half of the eyes in the treatment group. This limitation was due to the high cost of the imaging procedure and a shortage of Pentacam devices in our country due to the circumstances of the war in which the country passed for years. The procedure was performed under general anesthesia with ketamine hydrochloride 70mg/kg and diazepam 0.6 mg/kg injected subcutaneously in the dorsum of the neck, the outcome of the Scheimpflug corneal tomography parameters were used to compare to previous references.

2.8. Euthanization

Were humanely euthanized with an intra-peritoneal injection of pentobarbitone (150 mg/kg) (pentobarbital injection 6 grains of pentobarbital sodium, 250ml. bottles. Dechra, USA) while under general anesthesia.

2.9. Evaluation of Test Results

Corneal scars were evaluated and graded using slit lamp examination, as described previously. Scar Quantification based on modified Fantes haze scale for grading the corneal scar. Two external expert ophthalmologists who were unaware of the treatment allocation in each experimental group were involved in the evaluation process.

The following criteria were used to evaluate the outcomes of corneal scars:

- a. Subtract the initial opacity reading from the final post-treatment opacity reading for each individual cornea, including the negative control. Then calculate the average change in opacity for the negative control corneas.
- b. For each treated cornea, calculate a corrected opacity value by subtracting the average change in opacity of the negative control corneas from the change in opacity of that treated cornea.
- c. Determine the mean opacity value of each treatment group by averaging the corrected opacity values of the treated corneas for each treatment group (38).

2.10. Exclusion criteria. It will be excluded if the scar is less than one-third of the corneal thickness.

2.11. Statistical analysis

The slit lamp examination data, which comprised the categorization and grading of each cornea using the modified Fantes haze scale. Tables were used to record them. To compare various characteristics, suitable parametric tests were utilized. The paired T-test was used to compare changes in each outcome measure in rabbit corneal scar before and after eyedrop instillation, for treatment and control groups, and the independent t-test was used to compare the percentage change in each parameter between treatment and negative control group. A P value < 0.05 was deemed statistically significant. Graph pad prism excel software was used for all statistical analyses. Commercial software (SPSS version 25.) was used for statistical analyses.

3. The Results

The treatment group has a statistically significant reduction in corneal scar ($P < 0.000$ independent samples t-test), mean 2.75 score and a standard deviation (Std. Dev.) ± 0.45 compared with the

control group. It also restored corneal transparency in treatment group by a mean of 68.75% ($P < 0.000$, paired t-test), mean = 0.25, Std. Dev. \pm 0.45.

3.1. Descriptive Data

In the current randomized controlled trial, the outcomes included only 22 out of 24 eyes that underwent sterile excision of partial thickness (one-third to half) of the anterior central part of the cornea with a diameter of 7 mm. One rabbit was excluded from the control group due to heart failure. We noticed signs such as weight loss, decreased appetite, weakness, and irregular heart beat by auscultation. For these criteria we decided to humanely euthanize the rabbit. Ketamine anesthesia may be the probable cause of heart failure (39, 40). No rabbits were excluded from the treatment group. The number of rabbit corneas included in the results analysis for each group was as follows: Treatment group, $n=12$; control group, $n=10$ corneas. After the surgical procedures, we waited six weeks for stable, old corneal scars to develop. Afterward, the rabbits' corneas received topical drops as one drop three times per day for two months.

The treatment group received *Lycium shawii* leaves extract (10%; $n=12$), while the control group received a placebo (normal saline 9%; $n=10$). The only five rabbits from the treatment group were sent to the countryside and kept by our relatives for monitoring, allowing them to live in a natural environment and mate. Out of the five rabbits, one was male and four were females, while the other male rabbit was excluded. Almost two and a half years after the experiment began, a final check-up was performed as a follow-up. Only three rabbits were found, identified by signs of individuality such as the colors and unique pattern of a rabbit's fur, which were subjected to a general and ophthalmic examination.

3.2. Evaluation of the Corneal Scar

The effects of therapy on corneal scars and ocular safety were evaluated using a slit-lamp microscope, a modified Fantes haze scale for grading, and a direct ophthalmoscope. The corneal wounds in all rabbit eyes had completely reepithelialized within 11 to 13 days after surgery. The modified Fantes haze scale, as depicted in Table 1, was used to grade the corneal opacification, ranging from 3 to 0. Grade 3 indicates severe opacity.

Table 1. Modified Fantes haze scale.

| Grade | Description |
|---------|---|
| Grade 0 | Trace haze seen with careful oblique illumination. |
| Grade 1 | Minimal obscuration of iris details and haze larger than $\frac{1}{4}$ corneal area with or without neovascularization. |
| Grade 2 | Mild obscuration of iris details and haze larger than $\frac{1}{4}$ corneal area with or without neovascularization. |
| Grade 3 | Obscuration of the iris and lens with or without neovascularization (16). |

3.3. The results were as follows:

The quantitative corneal scar scores based on the modified Fantes haze scale were obtained as follows: The average of the initial, final, and change in corneal scar score were obtained by subtracting the mean change in corneal scar of the control group's from the change in scar of each cornea of the treatment group after using the treatment, as well as the average corrected scar value obtained by subtracting the mean change in corneal scar of the control group's from the mean change in corneal scar of the treatment group. These grades were assigned by two independent ophthalmologists who were masked to the treatment group after two months of instillation, Table 2. shows the average degree of scarring of the rabbits corneas in the treatment group, which before instillation was at the grade three, and after giving them the treatment, it improved and became in grade 0.25, with an average change equivalent to 2.75 degrees and an average correction of 2.75 degrees, with a percentage improvement of 68.75%. While the average degree of scarring in the rabbit corneas of the control group rabbits was at the third degree before and after instillation, there was no change or correction in the average scarring.

Table 2 . Shows the quantification of corneal opacity in both groups of rabbits using the Modified .Fantes haze scale, as well as the average of the initial, final, and changed corneal scar score.

| Group | Mean of Intial scar grade | Mean of Final scar grade | Mean of Change in scar grade | Average of corrected scar value | Percentage of scar reduction |
|-----------------|---------------------------|--------------------------|------------------------------|---------------------------------|------------------------------|
| Treatment group | 3 | 0.25 | 2.75 | 2.75 | 68.75% |
| Control group | 3 | 3 | 0 | 0 | 0 |

Figure 1. show the digital photography of corneal scars of control group before and after instillation of the placebo for a duration of two months. No significant change in corneal scar was observed.

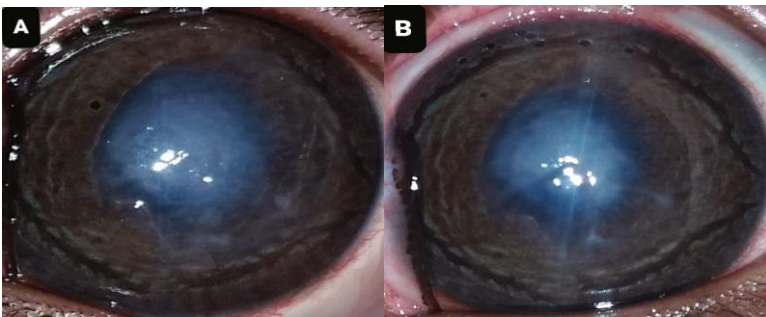


Figure 1. presents the digital photography of the old corneal scar of rabbits in the control group. (A) Rabbit cornea 40 days after surgical ablation, and before instillation, when the old stable scar (opacity) had formed, shows the scar is dense, severe and was at a grade 3 on the modified Fantes haze scale. (B) Rabbit cornea two months after instillation of the placebo (0.9% normal saline, one drop three times daily for two months), and it shows no improvement or decrease in the degree of the scar, and the degree of opacity remained the same at grade 3 on the modified Fantes haze scale.

The figure 2. shows the digital photography of treatment group's corneas before and after topical instillation of L.S.D. 10% over a period of two months. Shows Significant reduction in corneal scar with improvement in corneal transparency.

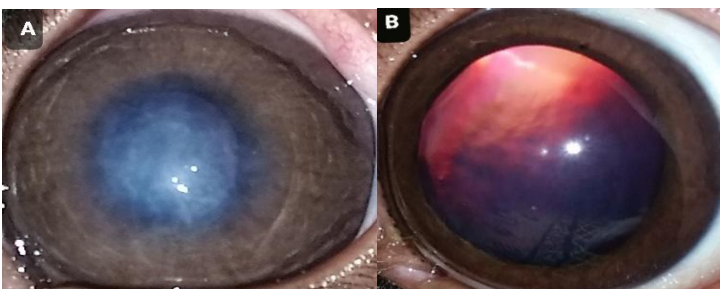
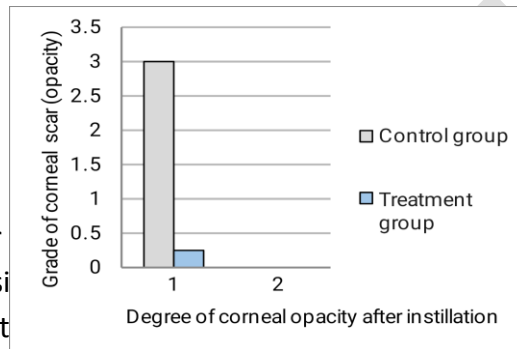


Figure 2. presents the reduction in corneal scar in treatment group.

(A) Rabbit cornea 40 days after surgical ablation, and before instillation of treatment, when the old stable scar (opacity) had formed, shows the scar is dense, severe and was at a grade 3 on the modified Fantes haze scale. (B) Rabbit cornea two months after administering of aqueous extracts derived from Lycium Shawii leaves as eye drops (10% concentration, one drop three times per day for two months), shows significant improvement in scar severity and was reduced to grade 0. These images vividly show the treatment's efficacy in reducing the size and severity of corneal scars in rabbits, eventually leading to near-complete recovery in the treated corneas with a statistically significant ($P < 0.000$) and Std. Dev. of ± 0.45 .

The Figure 3. displays a bar graph that compares the treatment groups with the control groups in terms of corneal scarring. The corneal scars (opacity) in rabbits was evaluated using a modified Fantes haze scale. The results demonstrate a significant reduction in corneal scarring in the treatment



control groups two months after instillation, which shows a significant reduction in corneal scarring in the treatment

Figure 3. displays a bar graph that compares the treatment groups with the control groups in terms of corneal scarring. The corneal scars (opacity) in rabbits was evaluated using a modified Fantes haze scale. The results demonstrate a significant reduction in corneal scarring in the treatment

group compared to the control group ($P < 0.000$), Std. Dev. ± 0.45 in the treatment group, the degree of scar decreased to grade 0.25, which closely resembles a normal cornea. On the other hand, the control group maintained a degree of scar at grade three, similar to the state before the instillation.

The corneal parameters in the treatment group are shown in Figure 4. which allows a comparative study, the corneal parameters of the treatment group in the current study are compared to the corneal parameters reported in previous references in Table 3.

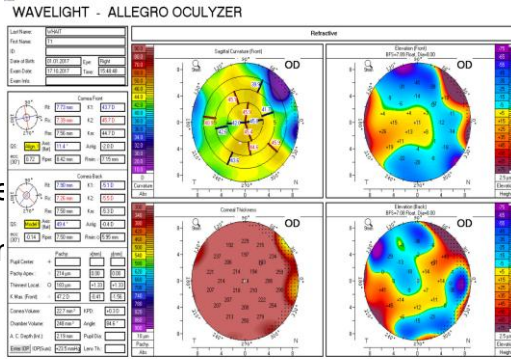


Figure 4. presents a schematic image of rabbit corneas after two weeks of treatment. The parameters that were close to normal value.

(am) image of treatment group parameters that were close to

Table 3. Displays the comparison of the outcome of corneal parameters in the treatment group of the current study with previously established reference values for normal and scarred corneas. Data from a previous study on densitometry, keratometry, and thickness were used as a reference point (15). In addition, parameters for the normal range of intraocular pressure (IOP) in rabbits were obtained from another reference (44). The parameters in our study were obtained from corneal tomography schiempflug (pentacam) image measurements performed under general anesthesia with ketamine 70 mg/kg and diazepam 2 mg/kg, that lead to a temporary rise in intraocular pressure during anesthesia (44).

| Parameter (mmhg) | Densitometry(mm ²). | | Keratometry (D). | | thickness(mM). | | Intraocular | | |
|---|---------------------------------|-----|------------------|--------|----------------|--------|-------------|---------|-------------|
| | Mean | SD. | Mean. | SD | mean. | SD. | Mean. | SD | |
| .Rabbit Normal .cornea (Reference) | | | 18.7. | ±3.8. | 45.80 | ±0.9. | 407.3 | ±10.25. | 16 ± |
| Our study .Rabbit cornea after treatment. | | | 23.92 | ±1.1 | 43.13 | ±0. | 199. | ±85.48 | 24.55 ±0.91 |
| Rabbit scarred .cornea (Reference) | | | 54.5. | ±11.7. | 40.40 | ±2.25. | 273. | ±51.3) | |

.Keratometric Diopters

D = Keratometric Diopters.

The treatment group (L.S.D. 10% therapy) showed a significant reduction in corneal scar scores compared to the corresponding control corneas (0.9% normal saline).

The treatment group has a statistically significant reduction in corneal scar ($P < 0.000$) mean 2.75 degree, Std. De ± 0.45 , and with 68.75% mean improvement in corneal transparency ($P < 0.000$), mean 0.25 degree, Std. De ± 0.45 .

In the treatment group, nine corneal scars improved from grade three to grade zero, while three corneal scars improved from grade three to grade one. This variation in improvement may be attributed to differences in the depth of keratectomy or other factors.

On the other hand, the control group showed no significant change in corneal scar. The degree of scar remained the same at grade 3, with no signs of improvement.

Two and a half years later, during the follow-up period, there were no abnormal findings detected (NAD) other than a slight degree of opacification noticed in the corneas under evaluation. The opacification was only noticeable in side illumination. The opacification scored as grade 0 on Modified fantes haze scale, as seen in Figure 5. with only slight variations observed among corneas.

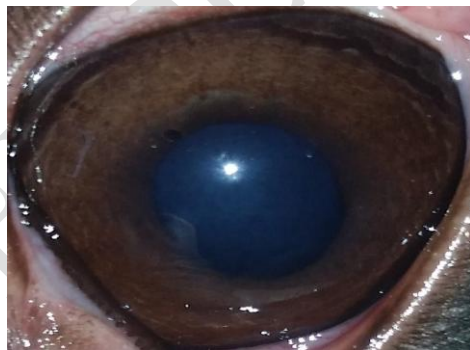


Figure 5. Represents the digital photography of the treatment group's rabbit cornea after about two and a half years of follow-up, which shows the degree of corneal clarity, which was grade zero according to the modified Fantes haze scale, as no potential side effects or complications were observed.

4. Discussion of the results:

4.2. Discussion

In our study, we demonstrated and approved the effectiveness of this topical drug extracted from leaves of L.S. in treating old corneal scars in rabbits. Corneal scar remains one of the main causes of blindness worldwide, which poses a challenge and an intractable dilemma for conventional medical treatment. Surgery is the only currently available and efficient method of treating corneal scars, but surgery has many limitations and complications.

To the best of our knowledge there are no effective, easy-to-prepare and use drops that treat corneal opacity and are at the same time inexpensive and easy to access. Additionally, our study is the first to evaluate the effectiveness of L. s. leaves in treating corneal scars in vivo, as the results showed that it has high effectiveness in treating corneal scars.

Based on the findings of our preliminary study and our review of many of the manuscripts of Yemeni folk medicine, ethno botany textbooks, peer-reviewed academic publications, and research repositories that were used to gather the extensive review of literature, we have reached the conclusion that an extract derived from L.S. leaves has the potential to effectively treat corneal scar at all degrees, layers and stages of corneal opacity formation. This conclusion is supported by interviews conducted with many traditional medicine practitioners in Yemen, as well as our own observation which included ophthalmic examination of many patients with varying degrees of corneal opacity before and after their use of drops extracted from the L.S. by manual-squeezing methods.

Before conducting the preliminary study we met with traditional therapists and obtained participants consent to conduct these examinations and document observations lasted for years before conducting this current study, as we did not notice any adverse potential effects, but rather On the contrary, we observed some benefits of this treatment on some other eye diseases that will require extensive scientific study in the future, and we will not discuss them in this topic.

When assessing the safety of the treatment approach, we observed no potential adverse effects during the experiment periods. There has been previous research on the toxicity of L.S leaves in animals (rats), there were no abnormal clinical signs and no deaths following oral administration of the methanol extract at the highest concentration of 4000 mg/kg body weight, indicating that oral

use was safe. There are no toxicological studies on human L.S. leaves extracts. L.S. leaves could be used safely in pharmaceutical and natural therapies (41).

Based on the results of current study and our observations, we conclude that this treatment is effective in treating corneal scars, and it is a promising treatment that is simple to prepare, manufacture, and inexpensive. It also foresees a bright future in the treatment of corneal scars, and the restoration of vision for many blind people.

As a result of our country's ongoing war from 2015 to the present, which has had an impact on the study, particularly since the air craft attacks by warplanes were very intense at the beginning of the experiment at the time of giving treatments to the experimental groups, as it led to us stopping giving treatments to groups of rabbits for intermittent periods that sometimes led to interruption for a period of almost two weeks while continuing to care for them, due to the noises of severe shelling and the vibration of the building, which may have an effect on the overall state of the animals and the results, we were afraid of being targeted at the location of the trials, which we were decided to keep secret for safety and security considerations. For all experimental groups, the treatment time was two months.

We were unable to complete the study and analyze the results after we completed the experimental part (giving the treatments to all of the rabbits in the groups, evaluating the degree of opacity, photographing the rabbits' eyes, and documenting the outcome) due to the previously mentioned reasons, as well as other factors that caused the study to be suspended for several years, and when the war subsided in 2023, we found an opportunity to complete the statistics.

The suggested mechanism of action in treatment of the scar are:

Although the aim of the current study is to evaluate the degree of effectiveness of L.S. extracts in the treatment of corneal scars, particularly old ones, there have been previous studies on the role of polysaccharide extracted from *Lycium barbarum* in preventing the formation of Fibrosis in the corneas to evaluate the effectiveness of a pretreatment agent for corneal scarring made of polysaccharide from *Lycium Barbarum* (LBP) solution. To obtain significant physiological responses, fibroblasts were treated with LBP for 24 hours before matrix destruction and after that incubated with transforming growth factor 1 (TGF-1). LBP treatment reduced the expression of -smooth muscle actin, myofibroblast marker, vimentin, and type II and type III collagen extracellular matrix proteins. LBP therapy. Fibroblasts pretreated with LBP showed a reduction in angiogenic factor expression and inhibited unwanted proliferation (42).

The length of the course of treatment may have been affected by a number of factors, which may have increased the amount of time needed for corneal clarity. These elements are listed below

Drug ocular bioavailability in rabbits is restricted to less than 5% of the dose administered, and frequently less than 1%. This is because of a variety of limitations: 1. the corneal epithelium's permeability barrier. 2. quick ocular surface drainage of the administered medication (7). 3. Protein binding is metabolized or destroyed by protease and esterase enzymes. 4. The cornea's presence of

static barriers. Therefore the logical design of the ocular therapeutic system necessitated increasing the drug holding duration and deeper penetration of the medication, which improved the drug's total bioavailability in the ocular tissue. Nano micelles, nanoparticles, Nano suspensions, liposomes, in situ gel, dendrimers, prodrugs, and contact lenses are examples of novel drug delivery methods (43). One of the other factors that contributed to the treatment period being extended was that the rabbits used to shake their heads after receiving the drops, which caused the treatment to leak out of their eyes and they wiped their eyes with their hands before licking it. We did not notice this until about a month after they began administering the treatment, and in an attempt to prevent this, we placed masks over their eyes for ten to fifteen minutes after receiving the drops. When we used this method, the treatment effect was increased, resulting in a shorter treatment period. The cornea is a transparent organ, making it a perfect model for evaluating fibrolysis and antiscar treatments. We think that using inexpensive, effective eye drops and herbal remedies can help to treat this issue.

Following the completion of the experiment's data collection we decided that the remaining rabbits in the control group should be rehabilitated and integrated into nature. So the rabbits of the control group were treated with drops extracted from L.S. one drop three times a day, and their corneal scar improved between five and eight weeks after treatment. They were then sent to the countryside to live and mate in the wild.

Conclusion

The results of the study showed that the L.S leaves extract was effective in treating scars on rabbit corneas and restoring their transparency in vivo. This innovative drug is expected to lead to the development of the first non-surgical treatment to treat old corneal scar. No significant adverse effects were observed, even after 2.5 years of follow-up.

The therapy group exhibits a statistically significant decrease in corneal scarring

($P > 0.000$), mean 2.75 degree, Std. De. ± 0.45 , as well as a mean improvement in corneal clarity of 68.75% ($P > 0.000$), mean = 0.25 degree, and Std. De. ± 0.45 . Since this treatment significantly reduced the degree of corneal scarring in treatment group, which improved from grade three (the highest degree of corneal scar severity on the modified Fantes haze scale) to grade zero (the closest to normal cornea clarity) in 75% of all corneas and from grade 3 to grade 1 in the remaining corneas.

The eye drops extracted from S.L. provide a non-surgical alternative treatment option for corneal scars, particularly old stable type. That is likely safe, simple to manufacture, and inexpensive. Further studies are needed to evaluate the safety and efficacy of L.S. eye drops in humans.

DisclosureStatement

Supplementary Materials

Access to all necessary documents and data is made possible through direct communication with the main author.

References

- 1-Feder, R. S. (2021). External disease and cornea. *American Academy of Ophthalmology*, page (7).
- 2-World Health Organization. (n.d.). World Report on vision. World Health Organization. <https://www.who.int/publications-detail-redirect/9789241516570> -
- 3- Jeng, B. H., & Ahmad, S. (2021). In pursuit of the elimination of corneal blindness: Is Establishing Eye Banks and training surgeons enough? *Ophthalmology*, 128(6), 813–815. <https://doi.org/10.1016/j.ophtha.2020.06.042>
- 4-Wang, E. Y., Kong, X., Wolle, M., Gasquet, N., Ssekasanvu, J., Mariotti, S. P., Bourne, R., Taylor, H., Resnikoff, S., & West, S. (2023). Global trends in blindness and vision impairment resulting from corneal opacity 1984–2020. *Ophthalmology*. <https://doi.org/10.1016/j.ophtha.2023.03.012> .
- 5- Wong, Y. L., Liu, S., & Walkden, A. (2022). Current perspectives on corneal transplantation(Part 2). *Clinical Ophthalmology*, Volume 16, 647–659. <https://doi.org/10.2147/OPHTH.S349582>.
- 6-Sriram, S., Gibson, D., Robinson, P., Tuli, S., Lewin, A. S., & Schultz, G. (2013). Reduction of corneal scarring in rabbits by targeting the TGFB1 pathway with a triple siRNA combination. *Advances in Bioscience and Biotechnology*, 04(10), 47–55. <https://doi.org/10.4236/abb.2013.410A4005>.
- 7- Toropainen, E., Fraser-Miller, S. J., Novakovic, D., Del Amo, E. M., Vellonen, K.-S., Ruponen, M., Viitala, T., Korhonen, O., Auriola, S., Hellinen, L., Reinisalo, M., Tengvall, U., Choi, S., Absar, M., Strachan, C., &Urtti, A. (2021). Biopharmaceutics of topical ophthalmic suspensions: Importance of viscosity and particle size in ocular absorption of indomethacin. *Pharmaceutics*, 13(4), 452. <https://doi.org/10.3390/pharmaceutics13040452>.
- 8- Riau, A. K., Tan, N. Y., Angunawela, R. I., Htoon, H. M., Chaurasia, S. S., & Mehta, J. S. (2012). Reproducibility and age-related changes of ocular parametric measurements in rabbits. *BMC Veterinary Research*, 8(1), 138. <https://doi.org/10.1186/1746-6148-8-138>.

- 9- Watsky, M. A., Jablonski, M. M., & Edelhauser, H. F. (1988). Comparison of conjunctival and corneal surface areas in rabbit and human. *Current Eye Research*, 7(5), 483–486. <https://doi.org/10.3109/02713688809031801>.
- 10-Freund DE;McCallyRL;FarrellRA;CristoISM;L'HernaultNL;Edelhauser HF; (n.d.). Ultrastructure in anterior and posterior stroma of perfused human and rabbit corneas. relation to transparency. *Investigative ophthalmology & visual science*. <https://pubmed.ncbi.nlm.nih.gov/7601631/>
- 11-2019-2020 basic and clinical science course, section 02: Fundamentals and principles of ophthalmology. (2019). *American Academy of Ophthalmology*, Page (78).
- 12-Wang, X., & Wu, Q. (2013). Normal corneal thickness measurements in pigmented rabbits using spectral-domain anterior segment optical coherence tomography: THICKNESS MEASUREMENT OF PIGMENTED RABBIT CORNEA BY SD-OCT. *Veterinary Ophthalmology*, 16(2), 130–134. <https://doi.org/10.1111/j.1463-5224.2012.01041.x>.
- 13-Ke, L., Wu, Q. Y. S., Zhang, N., Liu, H. W., Teo, E. P. W., Mehta, J. S., & Liu, Y.-C. (2021). Ex vivo sensing and imaging of corneal scar tissues using terahertz time domain spectroscopy. *Spectrochimica Acta Part A: Molecular and Biomolecular Spectroscopy*, 255, 119667. <https://doi.org/10.1016/j.saa.2021.119667>.
- 14- Rawe, I. M., Zabel, R. W., Tuft, S. J., Chen, V., & Meek, K. M. (1992). A morphological study of rabbit corneas after laser keratectomy. *Eye*, 6(6), 637–642. <https://doi.org/10.1038/eye.1992.137>.
- 15- Joshi, V. P., Vaishnavi K, S., Ojha, S. K., Singh, V., & Basu, S. (2020). A reliable animal model of corneal stromal opacity: Development and validation using in vivo imaging. *The Ocular Surface*, 18(4), 681–688. <https://doi.org/10.1016/j.jtos.2020.07.017>.
- 16- Cogswell, D., Sun, M., Greenberg, E., Margo, C. E., & Espana, E. M. (2021). Creation and grading of experimental corneal scars in mice models. *The Ocular Surface*, 19, 53–62. <https://doi.org/10.1016/j.jtos.2020.11.008>.
- 17- Ghosh, A., Singh, V. K., Singh, V., Basu, S., & Pati, F. (2022). Recent advancements in molecular therapeutics for corneal scar treatment. *Cells*, 11(20), 3310. <https://doi.org/10.3390/cells11203310>.
- 18-Chouhan, G., Moakes, R. J. A., Esmaili, M., Hill, L. J., deCogan, F., Hardwicke, J., Rauz, S., Logan, A., & Grover, L. M. (2019). A self-healing hydrogel eye drop for the sustained delivery of decorin to prevent corneal scarring. *Biomaterials*, 210, 41–50. <https://doi.org/10.1016/j.biomaterials.2019.04.013>.
- 19- Kamil, S., & Mohan, R. R. (2021). Corneal stromal wound healing: Major regulators and therapeutic targets. *The Ocular Surface*, 19, 290–306. <https://doi.org/10.1016/j.jtos.2020.10.006>.
- 20-Antunes-Foschini, R., Adriano, L., Murashima, A. D. A. B., Barbosa, A. P., Nominato, L. F., Dias, L. C., Fantucci, M. Z., Garcia, D. M., Alves, M., & Rocha, E. M. (2021). Limitations and advances in new treatments and future perspectives of corneal blindness. *Arquivos Brasileiros de Oftalmologia*, 84(3). <https://doi.org/10.5935/0004-2749.20210042>.
- 21- Kumar, A., Yun, H., Funderburgh, M. L., & Du, Y. (2022). Regenerative therapy for the Cornea. *Progress in Retinal and Eye Research*, 87, 101011. <https://doi.org/10.1016/j.preteyeres.2021.101011>.

- 22- Giva, S., Abdelrahim, A., Ojinna, B. T., Putrevu, V. P., Bornemann, E. A., Farhat, H., Amaravadi, K., Ben Abdallah, M., Gutlapalli, S. D., & Penumetcha, S. S. (2022). Safety and efficacy of mesenchymal stem cells for the treatment of evolving and established bronchopulmonary dysplasia: A systematic literature review. *Cureus*. <https://doi.org/10.7759/cureus.32598>.
23. Escudero Bodenlle, L., & Domingo, E. O. (2019). "Sclero-DALK": New approach for treatment of superficial corneal leukoma. *American Journal of Ophthalmology Case Reports*, 16, 100561. <https://doi.org/10.1016/j.ajoc.2019.100561>.
- 24- Yan, Q., Han, B., & Ma, Z.-C. (2022). Femtosecond laser-assisted ophthalmic surgery: From laser fundamentals to clinical applications. *Micromachines*, 13(10), 1653. <https://doi.org/10.3390/mi13101653>.
- 25- Salama, A., Abudunia, A.-M., Al-kaf, A. G., Ziad, N. M., Ibrahim, A., & Chabraoui, L. (2020). Comparative study of the efficacy of stem cells in corneal regeneration in a chemical burn in rabbits. *Universal Journal of Pharmaceutical Research*. <https://doi.org/10.22270/ujpr.v5i4.445>.
- 26- Talpan, D., Salla, S., Seidelmann, N., Walter, P., & Fuest, M. (2023). Antifibrotic effects of caffeine, curcumin and pirfenidone in primary human keratocytes. *International Journal of Molecular Sciences*, 24(2), 1461. <https://doi.org/10.3390/ijms24021461>.
- 27- Ghosh, A., Singh, V. K., Singh, V., Basu, S., & Pati, F. (2022). Recent advancements in molecular therapeutics for corneal scar treatment. *Cells*, 11(20), 3310. <https://doi.org/10.3390/cells11203310>.
- 28- Boumil, E. F., Castro, N., Phillips, A. T., Chatterton, J. E., McCauley, S. M., Wolfson, A. D., Shmushkovich, T., Ridilla, M., & Bernstein, A. M. (2020). Usp10 targeted self-deliverable sirna to prevent scarring in the cornea. *Molecular Therapy - Nucleic Acids*, 21, 1029–1043. <https://doi.org/10.1016/j.omtn.2020.07.032>.
- 29- Gupta, S., Fink, M. K., Ghosh, A., Tripathi, R., Sinha, P. R., Sharma, A., Hesemann, N. P., Chaurasia, S. S., Giuliano, E. A., & Mohan, R. R. (2018). Novel combination bmp7 and hgf gene therapy instigates selective myofibroblast apoptosis and reduces corneal haze in vivo. *Investigative Ophthalmology & Visual Science*, 59(2), 1045. <https://doi.org/10.1167/iovs.17-23308>.
- 30- M Albarrak, S. (2021). Supplementation with the methanolic extract of lyciumshawii or rhanteriumepapposum enhances immune responses of broilers. *Advances in Animal and Veterinary Sciences*, 9(11). <https://doi.org/10.17582/journal.aavs/2021/9.11.1816.1828>.
- 32- Rehman, N. U., Hussain, H., Al-Riyami, S. A., Green, Ivan. R., & Al-Harrasi, A. (2018). Chemical constituents isolated from lyciumshawii and their chemotaxonomic significance. *Records of Natural Products*, 12(4), 380–384. <https://doi.org/10.25135/rnp.34.17.09.160>.
- 33- Ahmed, F. A., Abdallah, N. M., Ezz, M. K., & El-Azab, M. M. (2017). Seasonal variations and identification of biologically active constituents of lyciumshawii plant roem. & shult.(family solanaceae). *International Journal of Innovative Science, Engineering & Technology*, 4(11), 2348-7968
- 34- Frtwot, N. (2016). (النباتات الطبية الشعبية اليمن) النباتات الطبية المستخدمة شعبيا لاغراض علاجية في بعض مناطق اليمن. *j.yemen*, 36, p.241. https://www.researchgate.net/publication/336285528_alnbatat_altbyt_almstkhdmshbya_laghrad_lajyt_fy_bd_mnatq_alymn.)-

34-Nihad M. Fartout. (2016). Medicinal plants popularly used for therapeutic purposes in some regions of Yemen. *Yemen journal*, 36, 214-246

35- Gaweesh A, Sengab AENB, El-Hefnawy HM, Osman SM, Abdou AM

the Aerial Parts of *Lycium shawii* R. Growing in Egypt. *Med Aromat Plants* 4: 180. doi:10.4172/2167-0412.1000180.)

36- Mikropoulou, E., Vougianniopoulou, K., Kalpoutzakis, E., Sklirou, A., Skaperda, Z., Houriet, J., Wolfender, J.-L., Trougakos, I., Kouretas, D., Halabalaki, M., & Mitakou, S. (2018). Phytochemical composition of the decoctions of greek edible greens (Chórta) and evaluation of antioxidant and cytotoxic properties. *Molecules*, 23(7), 1541. <https://doi.org/10.3390/molecules23071541>.

37- (1998). Aldine press books at Harry Ransom Humanities Research Center, Kallendorf, C., & Wells, M. X. Z the harry ransom humanities research center, the university of texas at austin: A descriptive catalog. Harry Ransom Humanities Research Center : Distributed by The University of Texas Press.

38-Cater, K. C., & Harbell, J. W. (2013). Prediction of eye irritation potential of liquid and granular laundry detergent formulas using the bovine corneal opacity and permeability (Bcop) assay. *Cutaneous and Ocular Toxicology*, 32(3), 210–221. <https://doi.org/10.3109/15569527.2012.754459>.

39-Rabbit_Anesthesia_guidance_ARC.the university of texas austin ,animal resources center. (n.d.).

40-Li, Y., Shi, J., Yang, B., Liu, L., Han, C., Li, W., Dong, D., Pan, Z., Liu, G., Geng, J., Sheng, L., Tan, X., Sun, D., Gong, Z., & Gong, Y. (2012). Ketamine-induced ventricular structural, sympathetic and electrophysiological remodelling: Pathological consequences and protective effects of metoprolol: Metoprolol's effects on ketamine-induced remodelling. *British Journal of Pharmacology*, 165(6), 1748–1756. <https://doi.org/10.1111/j.1476-5381.2011.01635.x>.

41- Ali, S. S., El-Zawawy, N. A., Al-Tohamy, R., El-Sapagh, S., Mustafa, A. M., & Sun, J. (2020). *Lycium shawii* Roem. & Schult.: A new bioactive antimicrobial and antioxidant agent to combat multi-drug/pan-drug resistant pathogens of wound burn infections. *Journal of Traditional and Complementary Medicine*, 10(1), 13–25. <https://doi.org/10.1016/j.jtcme.2019.01.004>

42-Wang, B., Han, L., Liu, J.-M., Zhang, J., Wang, W., Li, B.-G., Dong, C.-X., & Bai, C.-C. (2022). *Lycium* genus polysaccharide: An overview of its extraction, structures, pharmacological activities and biological applications. *Separations*, 9(8), 197. <https://doi.org/10.3390/separations9080197>.

43-Akhter, M. H., Ahmad, I., Alshahrani, M. Y., Al-Harbi, A. I., Khalilullah, H., Afzal, O., Altamimi, A. S. A., Najib Ullah, S. N. M., Ojha, A., & Karim, S. (2022). Drug delivery challenges and current progress in nanocarrier-based ocular therapeutic system. *Gels*, 8(2), 82. <https://doi.org/10.3390/gels8020082>

44-Ghaffari, M. S., & Moghaddassi, A. P. (2010). Effects of ketamine-diazepam and ketamine-acepromazine combinations on intraocular pressure in rabbits. *Veterinary Anaesthesia and Analgesia*, 37(3), 269–272. <https://doi.org/10.1111/j.1467-2995.2010.00531.x>.

45- Wang, B., Han, L., Liu, J.-M., Zhang, J., Wang, W., Li, B.-G., Dong, C.-X., & Bai, C.-C. (2022). Lycium genus polysaccharide: An overview of its extraction, structures, pharmacological activities and biological applications. *Separations*, 9(8), 197. <https://doi.org/10.3390/separations9080197>.

UNDER PEER REVIEW