

Case report

ERYSEPILOTHRIX RHUSIOPATHIAE : AN EMERGING ORGANISM CAUSING PLEURAL EFFUSION IN AN IMMUNOCOMPETENT CHILD

ABSTRACT:

AIMS : *Erysipelothrix rhusiopathiae* is a Gram-positive bacillus attributed to zoonotic infections primarily. In humans they usually cause localized cutaneous infections namely erysipeloid, occasionally becomes diffuse and may lead to septicemia and endocarditis in opportunistic immunocompromised individuals. The growing and evolving disease spectrum of this organism in human beings is a potential future threat. This case report addresses a common disease manifestation with this unusual organism which is needs to be highlighted.

PRESENTATION OF CASE : Herein we report a case of 1 year 9 month old immunocompetent male child belonging to a shepherd family who presented with long standing left sided pleural effusion. Pleural fluid culture yielded *Erysipelothrix rhusiopathiae*. Despite a culture sensitive antibiotic therapy a sequelae of residual effusion with subpleural collapse and fibrous septations developed, hence left lateral thoracotomy along with decortication surgery was performed.

DISCUSSION : This case report highlights the drug sensitivity and resistance pattern in detail and also points out the prognosis and possible sequelae of the disease which in turn can increase treatment awareness regarding the organism.

CONCLUSION : *Erysipelothrix* is an unusual organism which was found in our patient causing pleural effusion is a very unlikely coalition and needs a separate mention as this emerging microbe can be a cause of concern due to its novelty and scarce medical evidence.

KEYWORDS: *Erysipelothrix rhusiopathiae*, Pleural effusion, Thoracotomy

INTRODUCTION:

Erysipelothrix is a gram positive pleomorphic fastidious rod shaped organism mostly known for localized cutaneous manifestations is rarely linked with systemic infections in human being. Although some sporadic cases are reported worldwide, most of them occurred in immunocompromised individuals which

led to a belief that it as an opportunistic pathogen. In the last two decade this belief changed drastically as cases like septicemia, endocarditis, arthritis emerged linked to this organism. There is very limited resources pertaining to respiratory system involvement with this organism present in the extensive medical literature. This case report highlights an association of a very common respiratory manifestation, pleural effusion caused by the organism in an immunocompetent paediatric patient and also stresses upon the nature of the emerging microbe and disease prognosis.

PRESENTATION OF CASE :

A 1 year 9 month old male child from Ranaghat, India presented with complain of cough and cold for 20 days, fever for 10 days and respiratory distress for last 6 days after initial days of ineffective outpatient basis treatment. The child's father was a shepherd by occupation and the child was used to play in their backyard among sheep. On examination, the child was lethargic, febrile, tachypnoeic having severe intercostal retractions with no skin or chest wall deformity. There was diminished air entry and crepitations in left middle and left lower zone area. An initial chest x ray and lung ultrasonography confirmed pleural effusion hence diagnostic thoracentesis done for pleural fluid assay. Empirically the patient was started on ceftriaxone and vancomycin. The blood reports were as followed: haemoglobin 11.8 gm/dl, total leucocytic count of 16700/ cumm with neutrophilic predominance, Erythrocyte sedimentation rate (ESR) - 50 mm/hr, C reactive protein (CRP) 9 mg/dl with serology negative for tropical infections like dengue, scrub typhus, enteric fever. Associated liver function test and renal function test were within normal limits and tests for tuberculosis were non yielding.

Pleural fluid was hazy, straw coloured with coagulum, cell 96/mm³: mononuclear 70 % polymorph 20 %, Sugar 12 mg/dl, protein 5.9 mg/dl. The organism isolated from pleural fluid on gram stain was non-motile, non-sporulating pleomorphic gram-positive bacillus [Figure 1b], were cultured in VITEK 2 system which is a fully automated system performing concomitant bacterial identification and antibiotic susceptibility testing and α -Haemolytic, round shaped colonies [Figure 1a] that grew on the blood agar after overnight incubation at 35 °C and similar isolates were obtained from two specimens drawn 24 hours apart. The organism was catalase and oxidase negative with nonreactive to indole test. The unusual organism was further confirmed with MALDI-TOF (matrix assisted laser desorption ionization time-of-flight) mass spectrometry. The organism identified was *Erysipelothrix rhusiopathiae* and culture sensitivity report is as followed : resistant

to ceftriaxone, vancomycin, cotrimoxazole and ceftazidime and sensitive to erythromycin, clindamycin, gentamicin, levofloxacin, ciprofloxacin, linezolid, tetracycline and tigecycline. Immunoglobulin levels were within normal limit, and both mother and child were negative for HIV.

Afterwards a cocktail of Clindamycin and Linezolid was continued for 21 days to which the fever responded well but the respiratory distress was not decreased. HRCT thorax report revealed left sided large pleural effusion with sub pleural collapse with fibrous septations without any mediastinal shift (Figure 2). Echocardiography was normal. Finally left lateral thoracotomy and decortication surgery was performed. The child is on follow up for last 6 months and doing well.

DISCUSSION:

E. rhusiopathiae has an ubiquitous nature, found as a facultative anaerobe of zoonotic origin and is a catalase and oxidase negative non motile gram positive coccobacilli. Human *E. rhusiopathiae* infections can arise from exposure to infected animals or animal wastes and are often under diagnosed because of its slow and fastidious growth and enigmatic colony morphology on gram staining as sometimes the rough colonies decolorize themselves appearing as gram negative and they have structural similarities with *Lactobacillus spp.* and *Enterococcus spp.* [1-4]. The advancement in medical microbiology in terms of newer technologies has eased the species identification erasing the dilemmas once and for all. Availability of MALDI-TOF mass spectrometry and modern biochemical methods such as VITEK® 2 GP ID card (Biomérieux, Nürtingen, Germany) has made identification of *Erysepilothrix* very easy [18] as used in our setup. The primary portal of entry of *E. Rhusiopathiae* in human body through percutaneous penetration or through the gastrointestinal system. [2] In our case, there was neither any cutaneous infection in the child nor any known history of physical wound. The likely route of spread is that he might have been infected with *E. rhusiopathiae* via respiratory route, through deep inhalation of blended dust particles in the mews which the child acquired from playing with sheep. A similar pathogenesis of spread was also described by M Meric et al. where this organism caused pneumonia. [13] Apart from the localized cellulitic form and diffuse cutaneous forms other emerging systemic human infections associated with *E. rhusiopathiae* include vertebral osteomyelitis [4], septic arthritis [5], encephalitis [6], meningitis [7] and intra-abdominal abscess [8] and it is found that the first human systemic disease manifestation was reported in 2001 [17]. A detailed emerging spectrum of systemic disease in paediatric age group caused by *erysepilothrix*

istabulated in Table 1. In the last two decades only one case report of pleural effusion linked to positive *E. rhusiopathiae* was found, and additionally in terms of respiratory system involvement another case of aspiration pneumonia was found linked to a patient of oropharyngeal carcinoma.[9, 17] A repeat aseptic sampling yielding same organism with same sensitivity pattern ruled out the possibility of contamination and immunocompetence of the child without any risk factors like chest trauma, non healing wounds, renal insufficiency, diabetes mellitus, rheumatological disorders, chronic haematological malignancies [10] makes the case report more baffling. We believe this to be the first report of *E. rhusiopathiae* pleural effusion. In our case, blood culture did not yield a growth of *E. rhusiopathiae* and the probable justification behind undetectable bacteraemia in spite of such massive pleural effusion could be that the child was immunocompetent, without any other risk factors and the previous antimicrobial treatment received outpatient basis similar to the study of M Meric et al. [13] For treatment penicillin and cephalosporins are often first line choice, although they are intrinsically resistant to vancomycin despite its gram-positive nature [1]. Combination of ceftriaxone and vancomycin which is often an empiric first choice for pleural effusion did not work because the organism showed resistance to both cephalosporins and vancomycin. In our case the patient received a combination of clindamycin and linezolid as per sensitivity pattern however resistance to clindamycin and erythromycin has also been reported.[11] Some infections are also said to be self limiting but in our case the child had residual lung damage even after an exhaustive 21 days antibiotic course. However no consensus exist regarding exact duration of treatment, in cutaneous forms it may vary from one weeks to a prolonged 4-6 weeks course in other systemic forms .[12] The child had to undergo left lateral thoracotomy and decortication to counter the residual lung disease and treatment was continued for another 3 weeks and is now on follow-up for last 6 months without any further respiratory difficulty.

CONCLUSION:

Data on human systemic manifestations caused by *Erysipelothrix* is very scarce in medical literature. Some sporadic cases have been reported in immunocompromised individuals. A common disease like pleural effusion linked with such unusual organism is very baffling and worth mentioning. Additionally the extensive drug resistance variation and disease prognostication showed by this organism is also a potential threat for the clinicians which is the main highlight of the case report.

CONSENT FROM PARENTS OF THE PATIENT : Taken

REFERENCE:

1. Reboli AC, Farrar WE. Erysipelothrixrhusiopathiae: an occupational pathogen. *ClinMicrobiol Rev.* 1989;2(4):354-59.
2. Brooke CJ, Riley TV. Erysipelothrixrhusiopathiae: bacteriology, epidemiology andclinical manifestations of an occupational pathogen. *J Med Microbiol.*1999;48(9):789-99.
3. Wang Q, Chang BJ, Riley TV. Erysipelothrixrhusiopathiae. *Vet Microbiol.*2010;140(3-4):405-17.
4. Lorenz ML, Bouton TC, Caliendo AM. First reported case of vertebral osteomyelitisdue to Erysipelothrixrhusiopathiae. *IDCases.* 2018;11:3-5.
5. Ehrlich JC. Erysipelothrixrhusiopathiae infection in man: report of a case withcutaneous bullae, in which cure was achieved with penicillin. *Arch Intern Med.*1946;78(5):565-77.
6. Silberstein EB. Erysipelothrix endocarditis: report of a case with cerebralmanifestations. *Jama.* 1965;191(10):862-64.
7. Kim SR, Kwon MJ, Lee JH, Lee NY. Chronic meningitis caused by Erysipelothrixrhusiopathiae. *J Med Microbiol.* 2007;56(10):1405-06.
8. Feasi M, Bacigalupo L, Cappato S, Pontali E, Usiglio D, Rollandi GA et al.Erysipelothrixrhusiopathiae intra-abdominal abscess. *Int J Infect Dis.*2010;14(1):e81-3.
9. Sheng WH, Hsueh P, Hung CC, Fang C, Chang SC, Luh K. Fatal outcome ofErysipelothrixrhusiopathiae bacteremia in a patient with oropharyngeal cancer. *JFormos Med Assoc.* 2000;99(5):431-34.
10. Mukhopadhyay C, Shah H, Vandana KE, Munim F, Vijayan S. A child withErysipelothrix arthritis–beware of the little known. *Asian Pac J Trop Biomed.*2012;2(6):503-04.
11. J. Jorgensen, M. Pfaller, *Manual of clinical microbiology* [e-book] ASM Press (2015)available from: eBook Academic Collection (EBSCOhost).
12. Cooke LJ, Bowles KM, Craig JI, Sule O. Occupational injury in a fishmonger with amacular rash, hepatosplenomegaly and pancytopenia. *J Clin Pathol.* 2006;59(9):993-94.
13. Meric M, Ozcan S. Erysipelothrixrhusiopathiae pneumonia in an immunocompetentpatient. *J Med Microbiol.* 2012;61(3).
14. Jones N, Khoosal M. Erysipelothrixrhusiopathiae septicemia in a neonate. *Clin InfectDis* 1997;24(3):511.

15. Coman G, Miron I, Pânzaru C, Cârlan M, Petraru E. Erysipelothrixrhusiopathiaebacteremia in a child with acute leukemia. Rev Med Chir Soc Med Nat Iasi.1997;101(1-2):218-21.
16. Alawdah LS, Campbell JN, Pollock N, Watnick PI. Erysipelothrixrhusiopathiaesuppurative arthritis in a 12-year-old boy after an unusual fresh water exposure.Pediatr Infect Dis J 2017;36(4):431-33.
17. Rostamian M, Rahmati D, Akya A. Clinical manifestations, associated diseases, diagnosis, and treatment of human infections caused by *Erysipelothrixrhusiopathiae*: a systematic review. Germs. 2022 Mar 31;12(1):16-31.
18. Zautner AE, Tersteegen A, Schiffner CJ, Dilas M, Marquardt P, Riediger M, Delker AM, Mäde D, Kaasch AJ. Human *Erysipelothrixrhusiopathiae* infection via bath water - case report and genome announcement. Front Cell Infect Microbiol. 2022 Oct 24;12:981477

FIGURE 1a: Alpha hemolytic circular colonies on blood agar after overnight incubation at 35 °C. on culturing pleural fluid.

UNDER PEER REVIEW

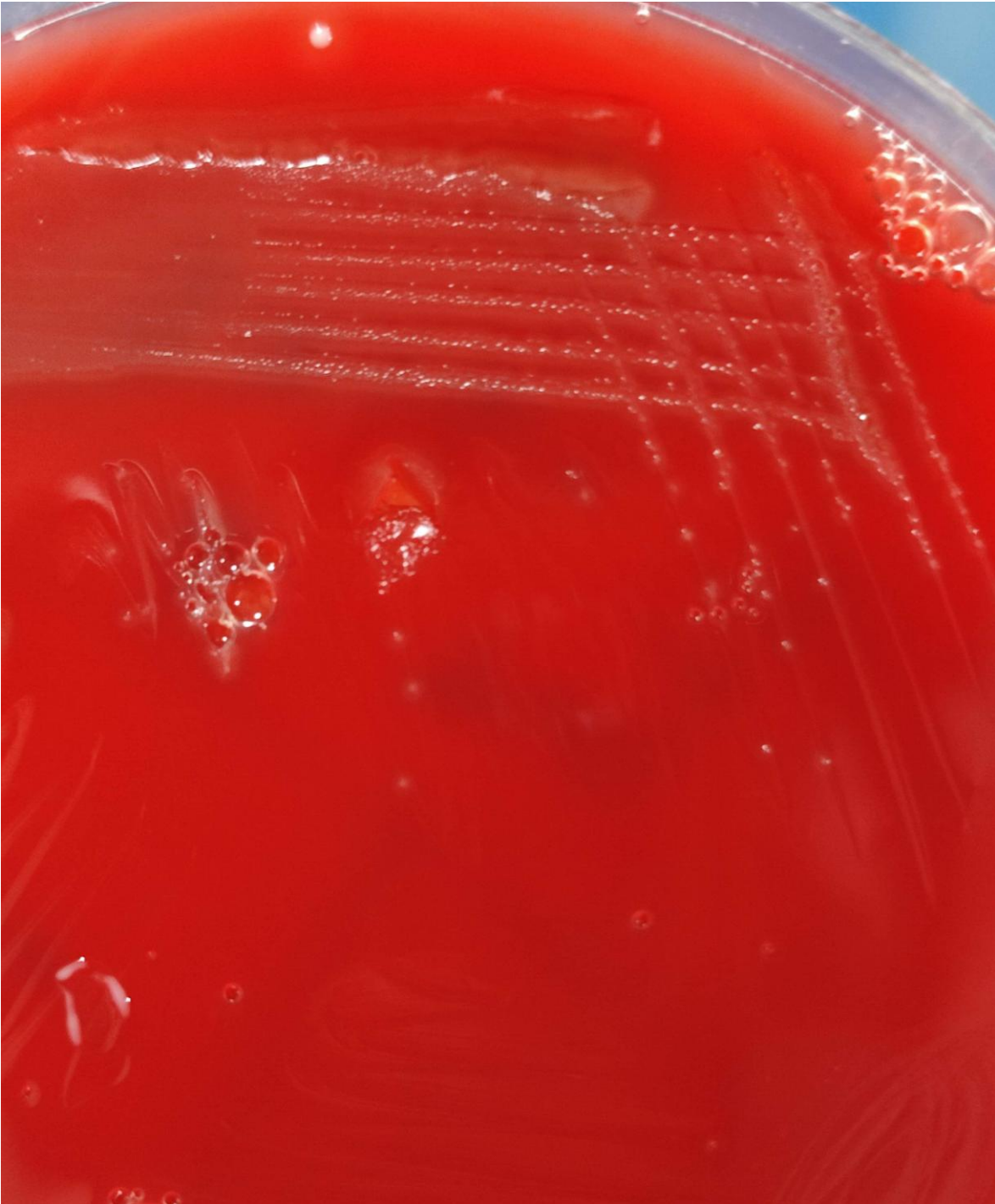
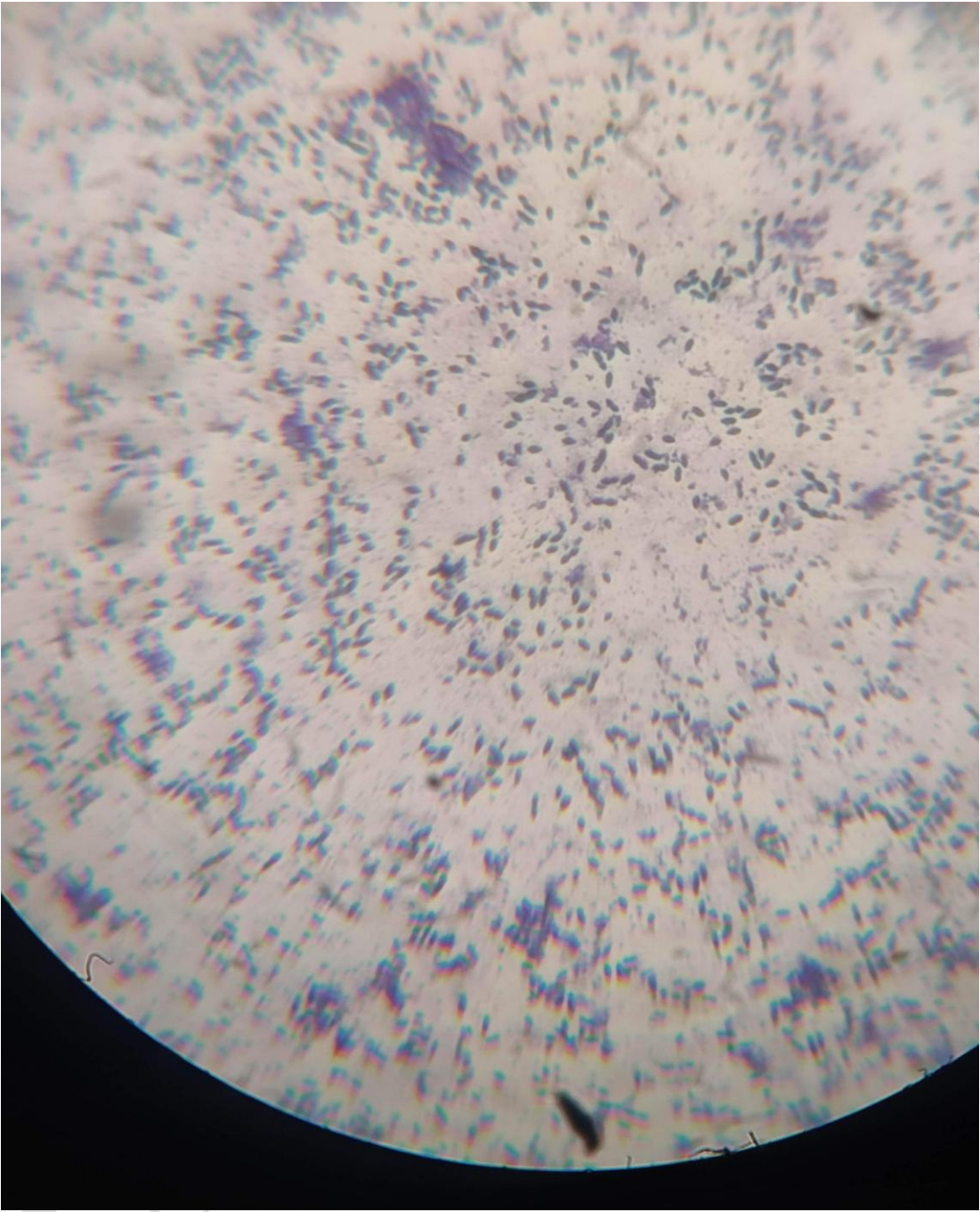


FIGURE 1b. Gram positive pleomorphic bacilli identified as *Erysipelothrix rhusiopathiae* under microscope.

UNDER PEER REVIEW



REVIEW

*FIGURE 2:*HRCT thorax yielding left sided large pleural effusion with sub pleural collapse with fibrous septations without any mediastinal shift.

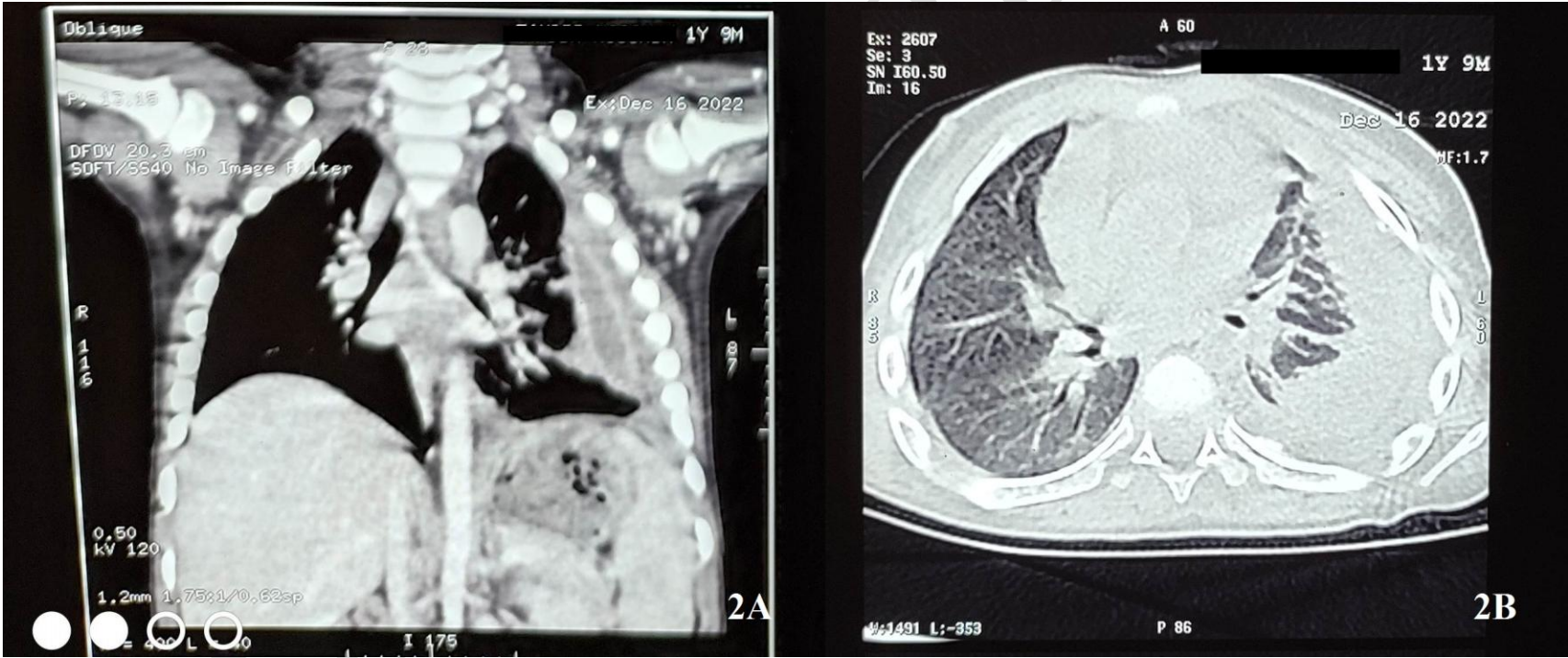

TABLE1:Detailed review of paediatric emerging systemic infections caused by *Erysepilothrixrhusiopathiae*

AUTHOR	YEAR	AGE	RISK FACTORS	ANIMAL CONTACT	INFECTIONS
NJonesetal. [14]	1997	Day4		Not known	Septicaemia
GComanetal. [15]	1997		Acute leukaemia	Not known	Septicaemia
C Mukhopadhyay et al. [10]	2012	5years	Trauma	Not known	Septic Arthritis
LSAlawdahet al.[16]	2017	12years		Frog, Dog, Lakewater	Suppurative arthritis
IndexCase	2023	1y9m		Sheep	PleuralEffusion