

Case report

NON-TRAUMATIC SUBCAPSULAR HEMATOMA OF THE LIVER IN A PATIENT UNDER RIVAROXABAN: A RARE CLINICAL OCCURRENCE

Abstract

Direct oral anticoagulants are used in the management and prophylaxis of venous thromboembolism (VTE) and other thrombotic diseases including non-valvular atrial fibrillation. The most serious complication of DOAC agents is bleeding, dominated by gastrointestinal hemorrhages, even if the bleeding risk is much rarer compared to VKA therapy. DOACs are sometimes linked to hepatotoxicity which can sometimes lead to severe hepatocellular insufficiency and also to non-hemorrhagic gastrointestinal disorders. We present a rare clinical entity of a spontaneous subcapsular hematoma of the liver in patient diagnosed with thrombosis of the right internal jugular vein treated with rivaroxaban, undergoing chemotherapy and hormonotherapy after surgery for breast cancer. The diagnosis was confirmed by imagery (abdominal CT scan) after clinical manifestation of an onset pain at the right hypochondrium of the abdomen. Conservative treatment was used in the patient with close follow up after hospital discharge.

Key words: Hematoma, oral anticoagulants, Rivaroxaban

Introduction:

Direct oral anticoagulants (DOACs) constitute a therapeutic option in preventive and therapeutic treatment of numerous thromboembolic diseases, and are therefore a pharmacological class with wide and frequent use, which increasingly replaces the use of Vitamin K antagonist (VKA)[1]. The most serious complication of antithrombotic agents is bleeding, dominated by gastrointestinal hemorrhages, even if the bleeding risk is much rarer compared to VKA[1,2]. Although DOACs can be linked to other types of hemorrhage, non-traumatic subcapsular hematoma (NTSH) of the liver is an entity that remains poorly understood and very rare. The clinical case presented here highlights a new rare anatomical location of bleeding caused by Rivaroxaban anticoagulation treatment.

Case Report:

A 49-year-old woman presented to the emergency room with intense right upper quadrant abdominal pain, radiating towards the shoulder and aggravated by movements during 24 hours, associated with nausea and a single episode of vomiting, without jaundice or fever and without having a traumatic context. Patient has a medical history of breast cancer having benefited a lumpectomy and chemotherapy then put on Tamoxifen. Three months before her admission to our department, patient presented a thrombosis of the left internal jugular vein of which she was put on Rivaroxaban 20 mg daily for two and a half months. The clinical examination reveals a pale, conscious patient, hemodynamically stable with a heart rate of

103 beats per minute (bpm) Figure 1, without abdomen distension. Abdominal palpation reveals sensitivity of the right hypochondrium without defense or contracture, cardiovascular examinations, neurological and lymph node examinations were also normal. The rest of the clinical examination did not find other hemorrhagic signs.

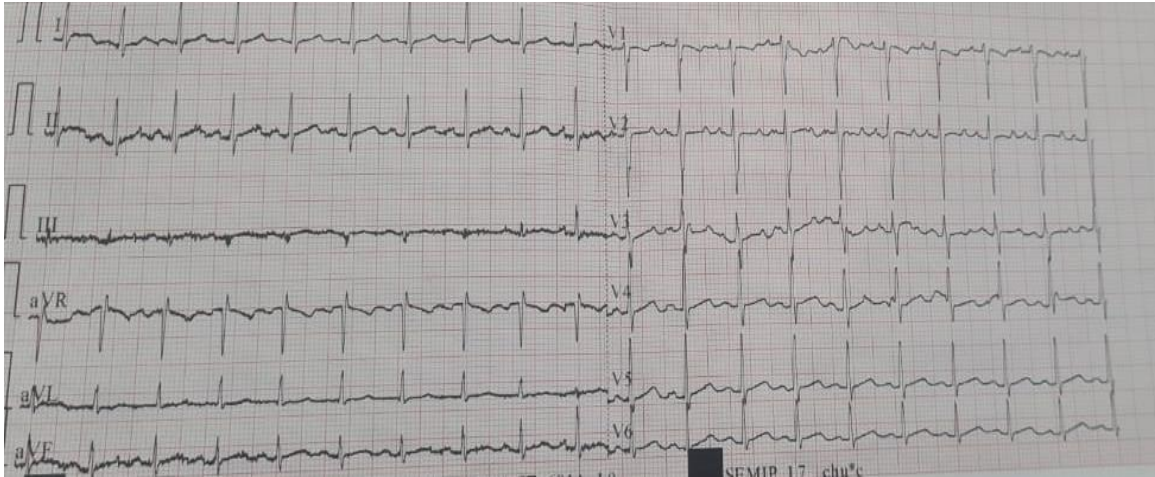


Figure 1: 12 leads Electrocardiogram: Sinus tachycardia without repolarization disorders.

The biological results showed a hemoglobin level of 10.8 g/dL (MGV: 92.5 fHMC: 32.3 g/dL), white blood cells at 7210 /uL, platelets at 221000/uL, Prothrombin rate at 89% and a cephalin activated time of 2.8. The rest of the electrolytes assessment were normal. Abdominal ultrasound shows subcapsular hematomas of the liver next to segments II, III, IV, VI and VII. For more precise diagnostic, an abdominal CT scan performed revealed a hepatic subcapsular collections next to segments II, III, IV, VI and VII in favor of hematomas with perfusion disorder of segment IV measuring 160x57 mm at its widest length (figure 2).

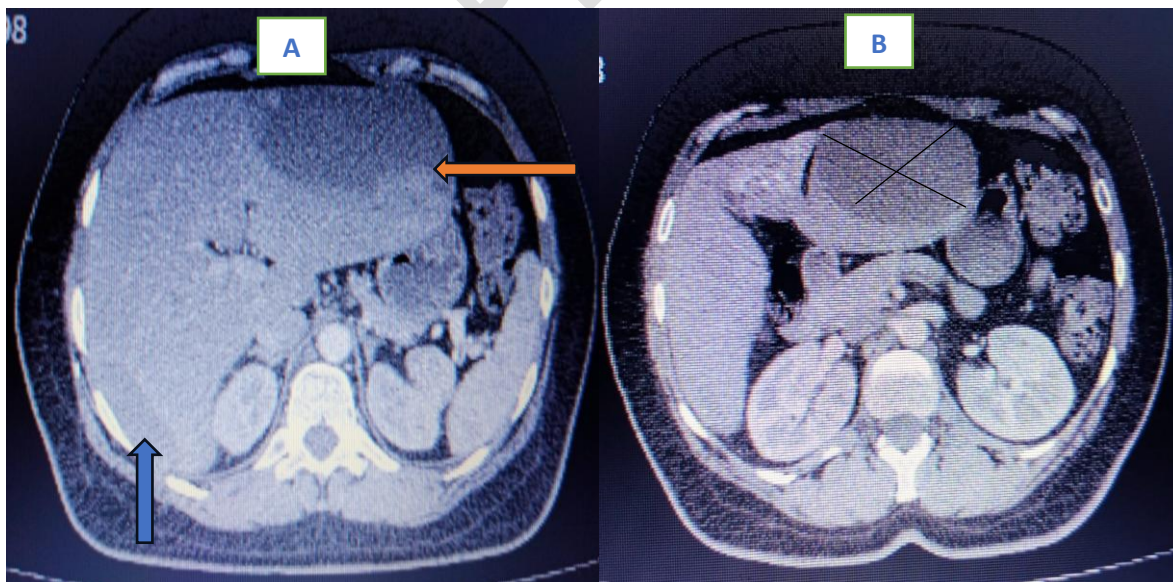


Figure 2: A-B: Transverse cross section of the abdomen passing through T4: showing a spontaneous subcapsular hematoma of the liver affecting the II, III, IV, VI and VII segments (arrows) measuring 160x57mm wide.

The diagnosis of hemorrhagic accident due to Rivaroxaban treatment responsible of a spontaneous subcapsular hematoma of the liver was retained. Conservative treatment was chosen with discontinuation of Rivaroxaban, then administration of analgesics and strict bed rest without the need for blood transfusion was indicated. A good clinical evolution was observed during hospitalization, the hemodynamic constants were normal and the pain subsided from the 2nd day whereas the biology control assessment shows a quasi-stable hemoglobin at 10,4g/dl. The patient was declared discharged from the 5th day with weekly monitoring. There was no need for further anticoagulant treatment after echography control of the neck which concluded the absence of signs of thrombosis in the jugular veins.

Discussion:

Direct oral anticoagulants are used in the management and prophylaxis of venous thromboembolism (VTE) and other thrombotic diseases including non-valvular atrial fibrillation[1]. In addition to their effectiveness, DOACs, unlike VKAs, can be administered to patients with underlying cancer[1,2].

The main complication is bleeding, which depends on the presence of pre-existing comorbidities: arterial hypertension, chronic obstructive pulmonary disease, diabetes, renal failure, liver disease, and other risk factors such as advanced age, underweight subjects with low blood pressure index, low body mass, smoking, a history of gastrointestinal hemorrhage, intracranial hemorrhage, invasive malignancy, hematological damage, collagen vascular disease, thrombocytopenia and the use of other medications which may increase this risk of bleeding such as steroids, NSAIDs, aspirin, Clopidogrel[3, 4].

Bleeding can be classified into major bleeding and clinically relevant non-major bleeding (CRNMB). Major bleeding is represented by intracranial hemorrhages, intraspinal hemorrhage, intraocular hemorrhages, hemopericardium, retroperitoneal hematoma, digestive hemorrhages, intra-articular hematomas (traumatic or non-traumatic), hemoperitoneum, splenic hematoma. CRNMB includes genitourinary and gynecological hemorrhages, hemoptysis, epistaxis, gingival bleeding, muscular hematomas and cutaneous ecchymoses and subcutaneous hematomas[4,5]. Major bleeding is 30% less observed in patients taking VKA[6], but according to S. Schulman and al, patients with cancer and treated for venous thromboembolism with DOACs, the risk of bleeding seems to be similar to AVK [7].

Although rare, DOACs are linked to hepatotoxicity which can sometimes lead to severe hepatocellular insufficiency and also to non-hemorrhagic gastrointestinal disorders[8].

With time, other hemorrhagic manifestations linked to DOACs are discovered. In a case reported by P.M. Mulendelénd al. A hematoma of the rectus abdominis muscle was reported in a 61-year-old woman, diabetic, with heart failure placed on Rivaroxaban 20 mg/day for prophylactic treatment for atrial fibrillation[9]. Another case reported by S. Chenna et al. a subcapsular and intra-renal hematoma was observed in a 74-year-old diabetic man, followed for stage 3 chronic kidney disease associated with heart failure and a

history of coronary artery disease, was placed on Rivaroxaban 20 mg/day for prophylactic treatment of atrial fibrillation[10]. In a case reported by ML. Labaki and al. a non-traumatic rupture of the spleen was observed in a 64-year-old hypertensive man placed on Rivaroxaban for prophylaxis treatment against atrial fibrillation[11]. Non-traumatic rupture of the spleen is reported in H.O.C.V Yau and al, S. Basnet and al, A. Jank and al, V. Nagaraja and al and L.E lowry and al either in patients under apixaban or Rivaroxaban and the therapeutic management varies depending on the clinical picture of the patients.

However, subcapsular hematoma of the liver is a rare complication in patients on anticoagulant treatment and much rarer in patients on DOACs. A case reported by M. Clementi and al in an 84-year-old hypertensive man treated with Warfarin and enoxaparin sodium for femoral vein thrombosis [12]. Another case reported by H.Dizadji and al objective NTSH of the liver in a 73-year-old woman years treated with warfarin sodium[13]. R. Badea et al reports a case of a 68-year-old man treated with VKA and aspirin for a bilateral aorto-femoral bypass in front of PAD, which associates NTSH with a retroperitoneal hematoma[14].

The particularity of our case is that this HSC of the liver is directly linked to the use of Rivaroxaban 20 mg per day, and in the absence of a traumatic context or associated medications.

Subcapsular hematoma of the liver is an anatomico-clinical entity which corresponds to the appearance of a hematic collection between the GLISSON capsule and the hepatic parenchyma, with or without rupture, frequently located around the right lobe of the liver in 75% of cases[15,16]. The etiologies are dominated by abdominal trauma, hepatic tumors, hepatic cirrhosis, HELLP syndrome in preeclampsia complicating pregnancy[17, 18], iatrogenic (drug-induced) or post-CPRE[13, 15, 16, 19] and more rarely spontaneous [17, 20]. It can occur from the neonatal period until old age 21.

The diagnosis is based on clinical examination and confirmation by imaging: abdominal ultrasound, abdominal CT scan or even liver MRI [16]. Clinically, abdominal pain in the right hypochondrium is observed in the majority of patients, with or without hemodynamic instability [15,17, 16, 20, 22]. Imaging represented by abdominal ultrasound and abdominal CT confirms the diagnosis of NTSH of the liver [14 22], highlighting the presence of a peri-hepatic collection by determining its density and looking for associated liver lesions [23]. Biological assessment generally identifies associated anemia depending on the gravity of the hematoma [16].

The fearsome complications are superinfection of an HSC, rupture and hemorrhagic shock [16].

Treatment must be started, once the diagnosis is established, in an intensive care unit with close clinical-biological monitoring [23]. Treatment can either be conservative[16,20, 22,23, 24] or surgery which is generally reserved for complicated cases such as capsule rupture [20 22 23 24].

The management of bleeding due to DOACs begins first with preventive measures which focus on the justification of anticoagulant treatment according to the pathology that we aim to treat, patient's profile and its comorbidities, as well as the choice of the adequate and appropriate molecule for the patient's profile and the stratification of the hemorrhagic risk[3, 25]. Temporary or permanent cessation of anticoagulant treatment with DOACs is a therapeutic option, this decision takes into account the type of bleeding (major or CRNMB) [6]. In the event of uncontrolled major bleeding, recourse to neutralizing agents and antidotes (Idarucizumab, Adexanat, PCC) can be a therapeutic option [6, 26, 27], without forgetting hemodialysis in the event of treatment with Dabigatran [6, 26].

In our case, treatment was conservative with definitive cessation of Rivaroxaban and analgesia, as well as strict clinical and biological monitoring (hemogram) in the intensive care unit.

Conclusion:

The indications for DOACs are numerous, dominated by thromboembolic disease and non-valvular atrial fibrillation, their main complication is bleeding. Non traumatic Subscapular hematoma of the liver is a little-known and very rare hemorrhagic complication linked to DOACs, which must be looked for by an abdominal examination in the event of any hemorrhagic accident due to DOACs.

EthicalApproval:

As per international standards or university standards writtenethicalapproval has been collected and preserved by the author(s).

Consent

As per international standards or university standards, patient(s) written consent has been collected and preserved by the author(s).

References

1.Sikorska, J., The Centre for Haemostasis and Thrombosis, Department of Haematology, St George's Hospital, London, UK, Uprichard, J., & The Centre for Haemostasis and Thrombosis, Department of Haematology, St George's Hospital, London, UK. Direct Oral Anticoagulants: A Quick Guide. *Eur. Cardiol. Rev.***12**, 40 (2017).

2. Vedovati MC, Germini F, Agnelli G, Becattini C. Direct oral anticoagulants in patients with VTE and cancer: a systematic review and meta-analysis. *Chest*. 2015 Feb;147(2):475-483. doi: 10.1378/chest.14-0402. PMID: 25211264.
3. Ballestri, S. *et al.* Risk and Management of Bleeding Complications with Direct Oral Anticoagulants in Patients with Atrial Fibrillation and Venous Thromboembolism: a Narrative Review. *Adv. Ther.* **40**, 41–66 (2023).
4. Milling, T. J. & Ziebell, C. M. A review of reversal of oral anticoagulants, old and new, in major bleeding and the need for urgent surgery. (2020).
5. Kaatz, S., Ahmad, D., Spyropoulos, A. C. & Schulman, S. Definition of clinically relevant non-major bleeding in studies of anticoagulants in atrial fibrillation and venous thromboembolic disease in non-surgical patients: communication from the SSC of the ISTH. *J. Thromb. Haemost.* **13**, 2119–2126 (2015).
6. Piran S, Schulman S. Treatment of bleeding complications in patients on anticoagulant therapy. *Blood*. 2019 Jan 31;133(5):425-435. doi: 10.1182/blood-2018-06-820746. Epub 2018 Dec 17. PMID: 30559261.
7. Schulman, S., Shrum, J. & Majeed, A. Management of bleeding complications in patients with cancer on DOACs. *Thromb. Res.* **140**, S142–S147 (2016).
8. Maura, G. *et al.* Non-bleeding Adverse Events with the Use of Direct Oral Anticoagulants: A Sequence Symmetry Analysis. *Drug Saf.* **41**, 881–897 (2018).
9. Mulendele, P. *et al.* Spontaneous Hematoma of the Rectus Abdominis Muscle During Treatment with Non-vitamin K Oral Anticoagulant: A Rare Clinical Occurrence and Review of the Literature. *Cardiology and Angiology: An International Journal* **12**, 256–261 (2023).
10. S, C. *et al.* Spontaneous Subcapsular Hematoma from Rivaroxaban. *Arch. Hematol. Case Rep. Rev.* 004–006 (2018) doi:10.17352/ahcrr.000012.
11. Labaki, M. & De Kock, M. Atraumatic splenic rupture in a patient treated with rivaroxaban: A case report and a narrative review. *Clin. Case Rep.* **10**, e6462 (2022).
12. Clementi M, Colozzi S, Guadagni S, Pessia B, Sista F, Schietroma M, Della Penna A, Amicucci G. Spontaneous liver rupture associated with anticoagulant therapy A case report. *Ann Ital Chir.* 2017 Jan 20;6:S2239253X17026408. PMID: 28630388.
13. Dizadji H, Hammer R, Strzyz B, Weisenberger J. Spontaneous rupture of the liver. A complication of oral anticoagulant therapy. *Arch Surg.* 1979 Jun;114(6):734-5. doi: 10.1001/archsurg.1979.01370300088017. PMID: 454157.
14. Badea R, Chiorean L, Mitre C, Botar-Jid C, Caraiani C. Spontaneous retroperitoneal and subcapsular liver hematoma. The diagnostic contribution of CT, US and CEUS. Case report. *Med Ultrason.* 2013 Jun;15(2):157-60. doi: 10.11152/mu.2013.2066.152.rb1lc2. PMID: 23702507.

15. Ndzengue, A. et al. An Obscure Case of Hepatic Subcapsular Hematoma. *Case reports in gastroenterology* 5, 223–6 (2011).
16. Pivetta LGA, da Costa Ferreira CP, de Carvalho JPV, Konichi RYL, Kawamoto VKF, Assef JC, Ribeiro MA. Hepatic subcapsular hematoma post-ERCP: Case report and literature review. *Int J Surg Case Rep.* 2020;72:219-228. doi: 10.1016/j.ijscr.2020.05.074. Epub 2020 Jun 6. PMID: 32544833; PMCID: PMC7298556.
17. Doumiri M, Elombila M, Oudghiri N, Saoud AT. Hématome sous-capsulaire du foie rompu compliquant une stéatose hépatique aiguë gravidique [Ruptured subcapsular hematoma of the liver complicating acute fatty liver of pregnancy]. *Pan Afr Med J.* 2014 Sep 16;19:38. French. doi: 10.11604/pamj.2014.19.38.4009. PMID: 25667700; PMCID: PMC4314140.
18. Liu J, Liu L, Liao G, Yao L. Conservative Treatment of Huge Hepatic Subcapsular Hematoma Complicated with Hepatic Infarction after Cesarean Section Caused by HELLP Syndrome - a Case Report and Literature Review. *Z Geburtshilfe Neonatol.* 2023 Jun;227(3):219-226. doi: 10.1055/a-1967-2451. Epub 2023 Feb 27. PMID: 36849111; PMCID: PMC10243897.
19. Safi M, Khareshi I, Memaryan M, Naderian M. Subcapsular liver hematoma after fibrinolytic therapy for acute myocardial infarction: a rare case report. *Acta Biomed.* 2016 Jan 16;87(3):318-320. PMID: 28112701; PMCID: PMC10521882.
20. Chen ZY, Qi QH, Dong ZL. Etiology and management of hemorrhage in spontaneous liver rupture: a report of 70 cases. *World J Gastroenterol.* 2002 Dec;8(6):1063-6. doi: 10.3748/wjg.v8.i6.1063. PMID: 12439926; PMCID: PMC4656381.
21. Gonçalves C, Aguilar S, Prior AR, Oliveira G. Hepatic subcapsular haematoma in a premature newborn. *BMJ Case Rep.* 2013 Jun 3;2013:bcr2013009074. doi: 10.1136/bcr-2013-009074. PMID: 23737575; PMCID: PMC3702791.
22. Tamimi AA, Alawad AA. Large spontaneous subcapsular hematoma of the liver: a rare case report. *Pan Afr Med J.* 2019 Jan 10;32:16. doi: 10.11604/pamj.2019.32.16.17083. PMID: 31143321; PMCID: PMC6522160.
23. Ndzengue A, Hammoudeh F, Brutus P, Ajah O, Purcell R, Leadon J, Rafal RB, Balmir S, Enriquez DA, Posner GL, Jaffe EA, Chandra P. An obscure case of hepatic subcapsular hematoma. *Case Rep Gastroenterol.* 2011 Apr 13;5(1):223-6. doi: 10.1159/000326998. PMID: 21552450; PMCID: PMC3088753.
24. Carlson KL, Bader CL. Ruptured subcapsular liver hematoma in pregnancy: a case report of nonsurgical management. *Am J Obstet Gynecol.* 2004 Feb;190(2):558-60. doi: 10.1016/s0002-9378(03)00759-2. PMID: 14981407.
25. Fawole A, Daw HA, Crowther MA. Practical management of bleeding due to the anticoagulants dabigatran, rivaroxaban, and apixaban. *Cleve Clin J Med.* 2013 Jul;80(7):443-51. doi: 10.3949/ccjm.80a.13025. PMID: 23821689.

26. Wei, S. *et al.* An update on applications and limitations of direct oral anticoagulants. *Egypt. J. Intern. Med.* **35**, 26 (2023).

27. Gómez-Outes, A. *et al.* Meta-Analysis of Reversal Agents for Severe Bleeding Associated With Direct Oral Anticoagulants. *J. Am. Coll. Cardiol.* **77**, 2987–3001 (2021).

UNDER PEER REVIEW