

AUTOIMMUNE HAEMOLYTIC ANAEMIA AS INITIAL AND ONLY PRESENTATION OF SYSTEMIC LUPUS ERYTHEMATOSUS: A CASE REPORT

ABSTRACT

Autoimmune haemolytic anaemia (AIHA) is an acquired disorder resulting in the presence of antibodies against red blood cell antigens which leads to intravascular haemolysis. It can occur as the initial and sometimes the only presenting feature of Systemic Lupus Erythematosus (SLE). In this report, we describe the diagnostic evaluation and ongoing management of a 13-year-old female with AIHA as the first clinical feature of SLE. She presented with paleness of the body and yellowish discoloration of the eyes. Initial examination showed severe pallor with moderate jaundice. Investigations revealed severe anaemia with slightly elevated reticulocyte count and positive direct coombs test (DCT). Peripheral blood film showed microcytic, hypochromic anaemia. Bone marrow aspiration showed a hypocellular marrow for the age of the child. Immunological screening results were positive for antinuclear antibody (ANA) and anti-double stranded DNA (Anti-ds DNA). Patient is currently on Prednisolone, hydroxychloroquine and mycophenolate mofetil (MMF). The diagnosis of SLE with AIHA requires a good history, physical examination, high index of suspicion and extensive investigations. Management entails multidisciplinary approach, supportive care, initiation of treatment with steroids and immunosuppressive drugs if necessary to minimize morbidity and mortality.

Key words: systemic lupus erythematosus; haemolytic anaemia; jaundice; autoimmune; immunological indicators.

Abbreviations:

AIHA: Autoimmune haemolytic anaemia

SLE: Systemic lupus erythematosus

ANA: Antinuclear antibody

Anti-ds DNA: Anti-double stranded DNA

CAS: Cold agglutinin syndrome

ESR: Erythrocyte sedimentation rate

DCT: Direct Coombs Test

DAT: Direct antiglobulin test

CBC: Complete blood count

BMA: Bone marrow aspiration

1. INTRODUCTION

Autoimmune haemolytic anaemia (AIHA) is a congenital or acquired disorder caused by autoantibodies directed against red blood cell membrane antigens leading to intravascular haemolysis, anaemia and jaundice.¹ AIHA can be due to warm or cold autoantibody types, or rarely, mixed types.²

AIHA is rare in children and in some cases, may be the primary and only presenting clinical feature in SLE.³ The most common form of AIHA in paediatric population is due to warm reactive auto antibodies also known as secondary AIHA. Coldreactive auto antibodies are responsible for the less frequent form of the disease, also known as primary or cold agglutinin syndrome (CAS). A small subset of cases may have both warm and cold antibodies known as mixed AIHA.⁴

AIHA may be suspected with thorough history (recurrent anaemia, jaundice), investigations viz **complete blood count(CBC)**, and erythrocyte sedimentation rate (ESR), reticulocyte count, peripheral blood smear and direct coombs test (direct antiglobulin test). Direct antiglobulin test (DAT) is the gold standard for AIHA diagnosis. Early supportive care, initiation of treatment with steroids for warm AIHA and transfusion for symptomatic anaemia is paramount for a positive outcome.²

Systemic lupus erythematosus is a chronic autoimmune disease with variable presentations. Diagnosis of childhood SLE is rare before 5 years of age and this diagnosis is more common in adolescents and teenagers, with a median age at diagnosis of 11 – 12 years.⁵ Haematological abnormalities which include haemolytic anaemia, leucopaenia, thrombocytopenia is common in children with SLE, with an incidence ranging from 34% to 82.7% in different studies.⁶ This case report shows that haemolytic anaemia may be the first and only presentation of SLE in paediatric patients.⁶

2. CASE PRESENTATION

A 13-year-old female presented to our facility with a four-day history of yellowish discoloration of the eyes, paleness of the body, headache, and fever. She also had a two-day history of abdominal pain with generalized body weakness, but no history of bone pain or gingival bleeding. There was also no history of trauma, blood loss, joint pain, skin rash, and hair loss or mouth/nasal ulcer. Patient's blood group is A positive, both parents had blood group A positive and there was no history of similar symptoms in other siblings.

A physical examination showed she was severely pale, moderately icteric with no significant peripheral lymphadenopathy. Patient had tachycardia with pulse rate of 107 beats/ minute while respiratory rate was normal for age. Abdomen was full and moved with respiration with palpable liver 4cm below the right costal margin, smooth surface, and sharp edge, non-tender. No splenomegaly. **Venous blood was collected under strict asepsis and analyzed in the hospital's research laboratory.**

Complete blood count (CBC) on presentation showed haemoglobin (HB) of 4.3g/dl, white cell count with differentials and platelet count were all normal. The other investigations done viz genotype was AA, hepatitis B surface antigen (HBsAg), hepatitis C antigen, human immunodeficiency virus (HIV) screening were all negative. Urinalysis showed presence of bilirubin and urobilinogen while urine and blood culture yielded no growth. Reticulocyte count was elevated. Liver function test (LFT) was essentially normal. Erythrocyte sedimentation rate (ESR) was elevated and serum electrolytes were within normal range.

She was transfused severally, however within 48 to 72 hours after each transfusion, haemoglobin(HB) would drop back to very low levels and jaundice would deepen. This led to a suspicion of antigen-antibody reaction involving the red cells. Subsequent peripheral blood film revealed moderate to severe anaemia which was microcytic, hypochromic. White cells and platelets were adequate on film, but showed marked variations in sizes.

Bone marrow aspiration (BMA) showed hypocellular marrow for age as well as increased erythropoiesis with erythroid hyperplasia. Myelopoiesis was present but mildly depressed. Lymphopoiesis was also depressed. Megakaryopoiesis was present and few plasma cells were seen. Patient had multiple transfusions while on admission and further investigations done include serum ferritin, transferrin percentage saturation were all within normal range.

A provisional diagnosis of systemic lupus erythematosus (SLE) with autoimmune haemolytic anaemia (AIHA) was made and further investigations were requested. Direct anti globulin test(DAT) also known as direct coombs test(DCT) was positive and Anti-nuclear antibody (ANA) factor titre was markedly elevated with a titre of 1:5120, Anti double-stranded DNA (anti-dsDNA) showed 3.1 (++) positive while AntiRo, AntiLa, Anti Jo-1, Anti Sci, Anti Sm, Anti-SM/RNP, Anti Centromere, Anti-Histone, Ribosomal P-Protein were all negative. Complements C3 and C4 were reduced.

In view of positive DCT, very high ANA titre and positive double stranded anti-DNA, and reduced complements. a definitive diagnosis of SLE with AIHA was then made and patient was commenced on tablet prednisolone 40mg 12 hourly, iron, folic acid, B complex and vitamin c. A rheumatology consult was requested and after review by the rheumatologist, hydroxychloroquine tablet 200mg daily was added.

Her clinical condition improved and she was discharged home after about a week. She continued to do well for about 2 months with no further need for transfusions and returned back to school. However, with initial tapering of tablet prednisolone, she had a relapse of AIHA with severe anaemia and jaundice. She was transfused again and placed back on the initial dose of prednisolone with a plan to taper slower than what was previously done. Hydroxychloroquine was continued while mycophenolate mofetil tablet at 1000mg daily was added. She was discharged few days later and has remained stable. Slower tapering of the prednisolone was restarted a few weeks later and she has remained stable. She has also remained on the mycophenolate mofetil and hydroxychloroquine. She is being followed up by both the rheumatology and the haemato-oncology unit.

Fig. 1. The result of the study of a 13-year old girl

Sex	F	Mobile
ID Number	QMLIS476256	Telephone
Date of Birth	2008 / 10 / 01	Email
Age	13	Address

Report Details		
Requisition Number	373023655	Specimen Type
Order Reference		Comments
Collection Date	06:17 09 Oct 2021	Diagnosis
Request Date	17:48 10 Oct 2021	MEGALOBlastic ANAEMIA +IRON DEFIC
Report Date	08:34 30 Oct 2021	
Report Updated Date	08:38 30 Oct 2021	Tests Resulted
Report Type	FINAL REPORT	% Saturation; ANA (Antinuclear Antibodies)
Priority	ROUTINE	Ferritin; Folate Serum; Intrinsic Factor Ab; I
		Methylmalonic Acid Serum; Transferrin

Auto-Immune Results

Name	Result	Range	Units
ANA (Antinuclear Antibodies) (IFA):			
Antinuclear Factor Screen	POSITIVE	NEGATIVE <1:80	
Antinuclear Factor Titre ANA (IFA)	1:5120	NEGATIVE <1:80 Titre	Titre
ANA Fluorescence Pattern	ANA Fluorescence pattern : speckled Antinuclear antibodies with speckled pattern are typically to find in systemic lupus erythematoses (SLE), Sjogren syndrome, mixed collagenosis (MCTD/SHARP syndrome) as well as in sclerodermia or other rheumatic diseases.		
ENA 17 profile:			
U1-snRNP	NEGATIVE	NEGATIVE	
PCNA	NEGATIVE	NEGATIVE	
PM-Scl	NEGATIVE	NEGATIVE	
Mi-2	NEGATIVE	NEGATIVE	

Fig. 2. The result of the study of a 13-year-old girl

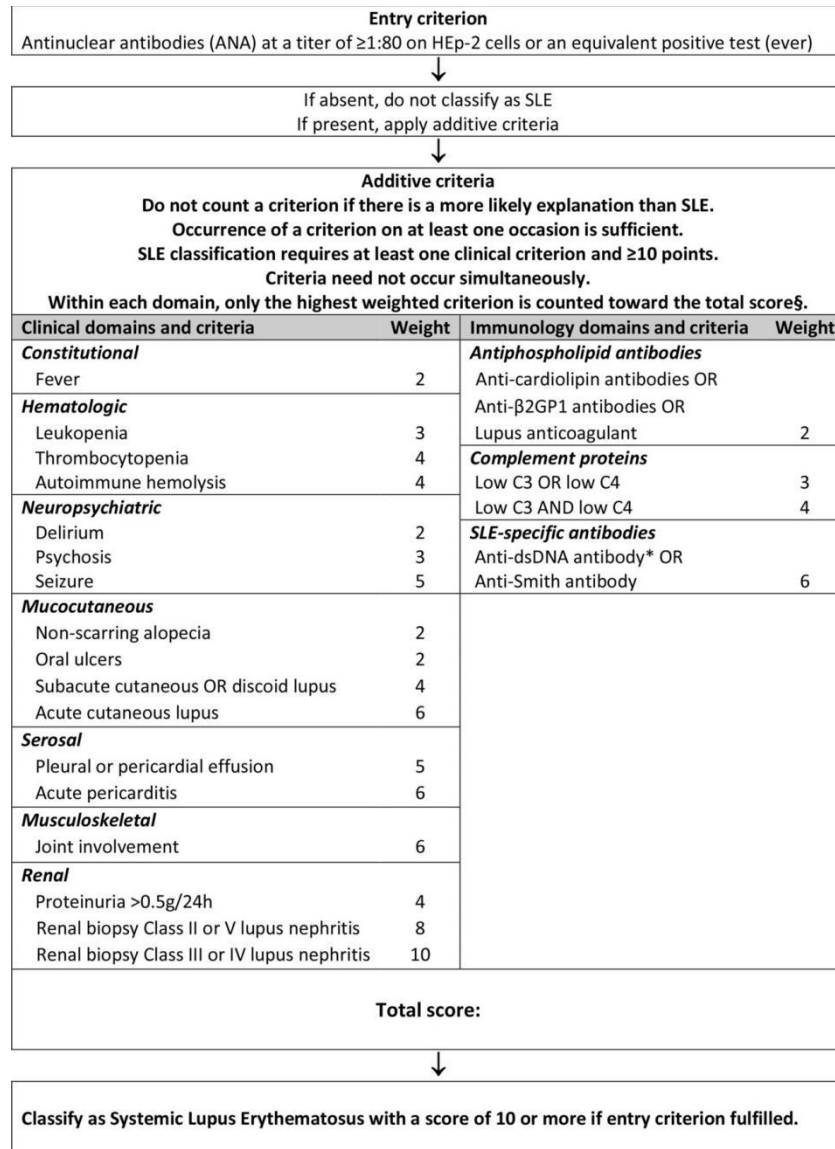
Sex	F	Mobile
ID Number	QMLIS476256	Telephone
Date of Birth	2008 / 10 / 01	Email
Age	13	Address

Name	Result	Range	Units
Ku	NEGATIVE		
Anti ds DNA	3.1 (++) POSITIVE	NEGATIVE	
SS-A AntiRo 52- (Immunoblot)	NEGATIVE	NEGATIVE	
SS-A AntiRo 60- (Immunoblot)	NEGATIVE	NEGATIVE	
SS-B AntiLa- (Immunoblot)	NEGATIVE	NEGATIVE	
Anti Jo-1 (Immunoblot)	NEGATIVE	NEGATIVE	
Anti Scl 70 (Immunoblot)	NEGATIVE	NEGATIVE	
Anti Sm (Immunoblot)	NEGATIVE	NEGATIVE	
Anti-SM/RNP- (Immunoblot)	NEGATIVE	NEGATIVE	
Anti-Centromere	NEGATIVE	NEGATIVE	
Anti-Histon abs	NEGATIVE	NEGATIVE	
Ribosomal P-Protein (RIB)	NEGATIVE	NEGATIVE	
Nucleosom	NEGATIVE	NEGATIVE	
Intrinsic Factor Ab	2.70	0-6.0	U/mL

Comments:

Negative: <6.0

Fig. 3. EULAR/ACR DIAGNOSTIC CRITERIA FOR DIAGNOSIS OF SLE



3. DISCUSSION

Systemic lupus erythematosus (SLE) is a multi systemic inflammatory disease with presence of circulating auto antibodies directed against self-antigens. The pathogenesis of SLE remains largely unknown though genetics, hormones and environmental exposures may increase the risk and severity of disease. SLE preferentially affects females especially during their reproductive years. It can involve any organ system and may lead to significant morbidity and mortality.⁶The presentation and clinical courses are different among various ages at the onset of the disease. Hence in children, making a diagnosis from clinical features alone can sometimes be challenging.⁷

Children and adolescents with SLE have more severe disease and widespread organ involvement with a higher prevalence of haematologic anomalies in paediatric patients compared to adults.⁸ Haematologic manifestations include anaemia of chronic disease (70%), leucopaenia (65%), lymphopaenia (50%), thrombocytopenia (15%), lymphadenopathy (15%), splenomegaly (15%), and haemolytic anaemia (10%). These haematologic involvements may result from bone marrow failure or excessive peripheral cell destruction, both of which may be immune-mediated.⁹

The American college of Rheumatology (ACR) and Systemic Lupus International Collaborating Clinics (SLICC) acknowledge AIHA as one of the diagnostic criteria for SLE. The 2019 European League against Rheumatism/American College of Rheumatology classification criteria for systemic lupus erythematosus (EULAR/ACR 2019); see figure 3, also recognizes AIHA as one of the diagnostic criteria for SLE. AIHA may be the first and only manifestation of SLE and can appear earlier before SLE is diagnosed as well as occur as part of an SLE flare.^{1,6,10} The mechanism is thought to be immune-mediated destruction of red blood cells.

AIHA is classified by the temperature at which autoantibodies optimally bind to RBCs. In cold antibody AIHA, the antibodies are of IgM class which react at temperatures of $<37^{\circ}\text{C}$, require complement for activity and produce spontaneous agglutination of red blood cells in vitro while in warm antibody AIHA, haemolysis is mediated by antibodies which bind to RBCs at 37°C (98.6°F).² The most common presenting complaints of children with SLE include fever, fatigue, hematologic abnormalities, arthralgia, and arthritis.⁵ In our patient, haematological abnormality was the initial and only presentation so far. Clinically, AIHA can range from mild haemolysis with compensatory reticulocytosis to rapid, life-threatening haemolysis which can result in hemodynamic compromise.^{11,12}

SLE can be diagnosed based on clinical manifestations and presence of auto antibodies. Antinuclear antibodies (ANA) are positive in $>98\%$ of patients during the course of disease while antibodies to Smith antigen and high titre Immunoglobulin G antibodies to double stranded DNA are both specific for SLE.¹³ The Coombs test(DCT) or direct antiglobulin test (DAT) is used to screen for erythrocyte antibodies, and positive results are common in patients with AIHA. However, it may be absent in some paediatric cases with a frequency ranging from 6% to 23%.¹⁴⁻¹⁶

In treatment of AIHA, targeted goals include decreasing haemolysis, stabilizing haemoglobin levels and preventing complications. First-line treatments include the use of corticosteroids either as pulsed intravenous methylprednisolone or high-dose oral prednisolone.¹¹ Steroids should be tapered slowly over approximately 6 months because rapid tapering or discontinuation have been associated with disease relapse. Also, steroid-sparing drugs such as azathioprine, hydroxychloroquine, mycophenolate mofetil, rituximab and tacrolimus are also used.¹¹ Supportive therapy which include administration of packed red blood cells, platelets, fresh frozen plasma can be given in children with severe anaemia.¹⁷

Here, we report the case of a 13-year-old with AIHA as the first and only manifestation of SLE. Patient is still on prednisolone at 20mg 12 hourly(initial dose was 40mg 12 hourly) hydroxychloroquine 100mg daily and MMF at 1000mg daily and has not developed any other symptom since diagnosis.

Giriyan et al,¹³ reported the case of a 12-year-old female with AIHA as an initial presentation of SLE similar to the index patient, however, she later developed malar rash and haematuria during the course of the disease. In contrast, our patient is yet to develop any other clinical feature other than haemolytic anaemia.

Yan et al in China,¹⁸ also reported the cases of two children 4 and 11 years respectively who presented with AIHA as initial feature of SLE as seen in the index patient. Both patients also had positive coombs test, anaemia, positive ANA and anti-double-stranded DNA. However in contrast, the 4 year old was diagnosed with lupus anticoagulant hypoprothrombinaemia syndrome (LAHPS) in addition to SLE on further work up, while the 11-year old had thyroiditis.

SLE is a generalized immunological disorder which results from a loss of contact over the B-cell response. This leads to polyclonal gammopathy and the production of autoantibodies. The results of the case study will add to and improve the existing knowledge on the AIHA in human beings and may help in their proper diagnosis and treatment.

4. CONCLUSION

SLE is a chronic autoimmune disease with affectation of multiple organs. AIHA can be the initial and only presentation of SLE, emphasizing the importance of a high index of suspicion and thorough work-up in children with clinical evidence of haemolytic anaemia to aid timely diagnosis and management of underlying secondary conditions.

Ethical Approval:

As per international standards or university standards written ethical approval has been collected and preserved by the author(s).

Consent

As per international standards, parental written consent has been collected and preserved by the author(s).

REFERENCES

1. Liebman HA, Weitz IC. Autoimmune haemolytic anaemia. *Med Clin North Am* 2017; 101: 351–59. doi: [10.1016/j.mcna.2016.09.007](https://doi.org/10.1016/j.mcna.2016.09.007)
2. Voulgaridou A, Kalfa TA. Autoimmune Haemolytic Anaemia in the Paediatric Setting. *J Clin Med* 2021; 10: 216-218. doi: [10.3390/jcm10020216](https://doi.org/10.3390/jcm10020216)
3. Singh A, Mandal A, Patel A, Mishra S. Autoimmune Haemolytic Anaemia-A Spectrum of Presentation in Children. *J Clin Diagn Res* 2017; 11: 1-2. doi: 10.7860/JCDR/2017/27895.10646.
4. Wołowiec M, Adamowicz-Salach A, Gołębiowska-Staroszczyk S, Demkow U, Skrzypczak-Pamięta M, Michalewska B, *et al.* Autoimmune haemolytic anaemia in

children during 2004-2014 in the Department of Paediatrics, Haematology and Oncology, Warsaw Medical University. *Polish Annals of Medicine* 2015; 22: 119–123. <https://doi.org/10.1016/j.poamed.2015.04.012>.

5. Rebecca E, Stacy P, Laura E. Systemic Lupus Erythematosus. Nelson Textbook of Paediatrics. 21st ed. Philadelphia: Elsevier; 2020. p 1176-1181.
6. Akca ÜK, Batu ED, Kisaarslan AP, *et al.* Haematological involvement in paediatric systemic lupus erythematosus: a multi-center study. *Lupus* 2021; 30: 1983-1990. doi: 10.1177/09612033211038824.
7. Smith EMD, Lythgoe H, Midgley A, *et al.* Juvenile-onset systemic lupus erythematosus: update on clinical presentation, pathophysiology and treatment options. *Clin immunol* 2019; 209: 108274. doi: 10.1016/j.clim.2019.108274.
8. Ardoin SP, Daly R, Merzoug L, *et al.* Research priorities in childhood-onset lupus: results of a multidisciplinary prioritization exercise. *Pediatr Rheumatol* 2019; 17: 32-34. <https://doi.org/10.1186/s12969-019-0327-4>
9. Hahn BH. Systemic Lupus Erythematosus. In: Longo DL, Kasper DL, Jameson JL, Fauci AS, Hauser SL, Loscalzo J, editors. Harrison's Principles of Internal Medicine. 18th edition. United States of America: The McGraw-Hill Companies. 2012; 1:2724- 2735.
10. Velo-García A, Castro SG, Isenberg DA. The diagnosis and management of the haematologic manifestations of lupus. *J Autoimmun* 2016; 74: 139-160. doi: 10.1016/j.jaut.2016.07.001
11. Neely J, Von Scheven E. Autoimmune haemolytic anaemia and autoimmune thrombocytopenia in childhood-onset systemic lupus erythematosus: updates on pathogenesis and treatment. *Curr Opin Rheumatol* 2018; 30: 498–505. doi: 10.1097/BOR.0000000000000523
12. Artim-Esen B, Çene E, Şahinkaya Y, *et al.* Autoimmune haemolytic anaemia and thrombocytopaenia in a single-centre cohort of patients with systemic lupus erythematosus from Turkey: clinical associations and effect on disease damage and survival. *Lupus* 2019; 28: 1480–1487. doi: 10.1177/0961203319877245.
13. Giriyan SS, Priya, Reddy P. Autoimmune haemolytic anaemia- an initial presentation in childhood systemic lupus erythematosus. *Trop J Path Micro* 2019; 5: 745-749. DOI: <https://doi.org/10.17511/jopm.2019.i09.21>

14. Fan J, He H, Zhao W, Wang Y, Lu J, Li J, *et al.* Clinical Features and Treatment Outcomes of Childhood Autoimmune Haemolytic Anaemia: A Retrospective Analysis of 68 Cases. *J Pediatr Hematol Oncol* 2016; 38 : 50-55. doi: 10.1097/MPH.0000000000000476.
15. Abdel-Salam A, Bassiouni ST, Goher AM, *et al.* Autoimmune Haemolytic Anaemia in the Paediatric Age Group: The Egyptian Experience. *Ann Hematol* 2023; 24: 1-8. doi: 10.1007/s00277-023-05230-5
16. Skare T, Picelli L, Dos Santos TAG, *et al.* Direct antiglobulin (Coombs) test in systemic lupus erythematosus patients. *Clin Rheumatol* 2017; 36: 2141–2144. doi: 10.1007/s10067-017-3778-3
17. Kocheril AP, Vettiyil GI, George AS, *et al.* Paediatric systemic lupus erythematosus with lupus anticoagulant hypoprothrombinemia syndrome - a case series with review of literature. *Lupus* 2021; 30: 641–648. doi: 10.1177/0961203321988934.
18. Lu Y, Huang X-M. Autoimmune hemolytic anemia as an initial presentation in children with systemic lupus erythematosus: two case reports. *Journal of International Medical Research*. 2022;50 (8). doi:10.1177/03000605221115390