

Case study

**CASE REPORT OF A PATIENT WITH AUTOIMMUNE HAEMOLYTIC ANAEMIA AS INITIAL AND ONLY PRESENTATION OF SYSTEMIC LUPUS ERYTHEMATOSUS**

**The Autoimmune Haemolytic Anaemia Whit Initial and Only Presentation of Systemic Lupus Erythematosus: Cases Report**

**Comment [PW1]:** I recommend changing the title of the article

**ABSTRACT**

Autoimmune haemolytic anaemia (AIHA) is an acquired disorder resulting in the presence of antibodies against red blood cell antigens which leads to intravascular haemolysis. It can occur as the initial and sometimes the only presenting feature of Systemic Lupus Erythematosus (SLE). In this report, we describe the diagnostic evaluation and ongoing management of a 13-year-old female with AIHA as the first clinical feature of SLE. She presented with paleness of the body and yellowish discoloration of the eyes. Initial examination showed severe pallor with moderate jaundice. Investigations revealed severe anaemia with slightly elevated reticulocyte count. Peripheral blood film showed microcytic, hypochromic anaemia. Bone marrow aspiration showed a hypocellular marrow for the age of the child. Immunological screening results were positive for antinuclear antibody (ANA) and anti-double stranded DNA (Anti-ds DNA). The diagnosis of SLE with AIHA requires a good history, physical examination, high index of suspicion and extensive investigations. Management entails multidisciplinary approach, supportive care, initiation of treatment with steroids, immunosuppressive drugs if necessary to minimize morbidity and mortality.

**Comment [PW2]:**

**Comment [PW3]:**

**Comment [PW4]:** Give clear practical recommendations

**Formatted:** English (United States)

**Formatted:** English (United States)

**Comment [PW5]:**

**Formatted:** English (United States)

**Formatted:** English (United States)

**Formatted:** English (United States)

**Formatted:** English (United States)

**Key words:** systemic lupus erythematosus; haemolytic anaemia; jaundice; autoimmune; immunological indicators.

Abbreviations:

AIHA: Autoimmune haemolytic anaemia

Formatted: English (United States)

Formatted: Russian (Russia)

## 1. INTRODUCTION

Formatted: Font: (Default) Times New Roman, 12 pt, Bold

Formatted: List Paragraph, Numbered + Level: 1 + Numbering Style: 1, 2, 3, ... + Start at: 1 + Alignment: Left + Aligned at: 0.25" + Indent at: 0.5"

Comment [PW6]:

Comment [PW7]: make the correct references here and further in the text [ ]

Autoimmune haemolytic anaemia (AIHA) is a congenital or acquired disorder caused by autoantibodies directed against red blood cell membrane antigens leading to intravascular haemolysis, anaemia and jaundice.<sup>1</sup> AIHA can be due to warm or cold autoantibody types, or rarely, mixed types.<sup>2</sup>

Formatted: Highlight

AIHA is rare in children and in some cases, may be the primary and only presenting clinical feature in SLE.<sup>3</sup> The most common form of AIHA in paediatric population is due to warm reactive auto antibodies also known as secondary AIHA. Cold reactive auto-antibodies are responsible for the less frequent form of the disease, also known as primary or cold agglutinin syndrome (CAS). A small subset of cases may have both warm and cold antibodies known as mixed AIHA.<sup>4</sup>

AIHA may be suspected with thorough history (recurrent anaemia, jaundice), investigations viz full blood count, and erythrocyte sedimentation rate (ESR), reticulocyte count, peripheral blood smear and direct coombs test (direct antiglobulin test). Direct antiglobulin test is the gold standard for AIHA diagnosis. Early supportive care, initiation of treatment with steroids for warm AIHA and transfusion for symptomatic anaemia is paramount for a positive outcome.<sup>2</sup>

Systemic lupus erythematosus (SLE) is a chronic autoimmune disease with variable presentations. Diagnosis of childhood SLE is rare before 5 years of age and this diagnosis is more common in adolescents and teenagers, with a median age at diagnosis of 11 – 12 years.<sup>5</sup>

Haematological abnormalities which include haemolytic anaemia, leucopaenia, leucocopaenia, thrombocytopenia is common in children with SLE, with an incidence ranging from 34% to 82.7% in different studies.<sup>6</sup> This case report shows that haemolytic anaemia may be the first and only presentation of SLE in paediatric patients.

Formatted: Font: (Default) Times New Roman, 12 pt, Bold

Formatted: List Paragraph, Numbered + Level: 1 + Numbering Style: 1, 2, 3, ... + Start at: 1 + Alignment: Left + Aligned at: 0.25" + Indent at: 0.5"

## 2. CASE PRESENTATION

A 13-year-old female presented to our facility with a four-day history of yellowish discoloration of the eyes, paleness of the body, headache, and fever. She also had a two-day history of abdominal pain with generalized body weakness, but no history of bone pain or gingival bleeding. There was also no history of trauma, blood loss, joint pain, skin rash, and hair loss or mouth/nasal ulcer. Patient's blood group is A- positive, and there was no history of similar symptoms in other siblings.

A physical examination showed she was severely pale, moderately icteric with no significant peripheral lymphadenopathy. Patient had tachycardia with pulse rate of 107 beats/ minute while respiratory rate was normal for age. Abdomen was full and moved with respiration with liver 4cm below the right costal margin, smooth surface, and sharp edge, non-tender. No splenomegaly.

Full blood count (FBC) on presentation showed haemoglobin (HB) of 4.3g/dl, white cell count with differentials and platelet count were all normal. The other investigations done viz genotype was AA, hepatitis B surface antigen (HBsAg), hepatitis C antigen, human immunodeficiency virus (HIV) screening were all negative. Urinalysis showed presence of bilirubin and urobilinogen while urine and blood culture yielded no growth. Reticulocyte count was elevated. Liver function test (LFT) was essentially normal. Erythrocyte sedimentation rate (ESR) was elevated and serum electrolytes were within normal range. She was transfused severally, however within 48 to 72 hours after each transfusion, HB would drop back to very low levels and jaundice would deepen. This led to a suspicion of antigen-antibody reaction involving the red cells.

Subsequent peripheral blood film revealed moderate to severe anaemia which was microcytic, hypochromic. White cells and platelets were adequate on film, but showed marked variations in sizes.

Bone marrow aspiration (BMA) showed hypocellular marrow for age as well as increased erythropoiesis with erythroid hyperplasia. Myelopoiesis was present but mildly depressed. Lymphopoiesis was also depressed. Megakaryopoiesis was present and few plasma cells were seen.

**Comment [PW8]:**

**Comment [PW9]:** specify the parameter clearly ???

**Comment [PW10]:** Clearly indicate which analyzers were used, how the samples were taken, and how the patient's values changed???

**Comment [PW11]:**

Patient had multiple transfusions while on admission and further investigations done include serum ferritin, transferrin percentage saturation were all within normal range.

A provisional diagnosis of systemic lupus erythematosus (SLE) with autoimmune haemolytic anaemia (AIHA) was made and further investigations were requested. Direct Coombs test (DCT) was positive and Anti-nuclear antibody (ANA) factor titre was markedly elevated with a titre of 1:5120, Anti double-stranded DNA (anti-dsDNA) showed 3.1 (++) positive while AntiRo, AntiLa, Anti Jo-1, Anti Sci, Anti Sm, Anti-SM/RNP, Anti Centromere, Anti-Histone, Ribosomal P-Protein were all negative complements C<sub>3</sub> and C<sub>4</sub> were reduced.

In view of positive DCT, very high ANA titre and positive double stranded anti-DNA, and reduced complements, a definitive diagnosis of SLE with AIHA was then made and patient was commenced on tablet prednisolone, iron, folic acid, B complex and vitamin c. A rheumatology consult was requested and after review by the rheumatologist, hydroxychloroquine was added.

Her clinical condition improved and she was discharged home after about a week. She continued to do well for about 2 months with no further need for transfusions and returned back to school. However, with initial tapering of tablet prednisolone, she had a relapse of AIHA with severe anaemia and jaundice. She was transfused again and placed back on the initial dose of prednisolone with a plan to taper slower than what was previously done, hydroxychloroquine was continued while mycophenolate mofetil was added. She was discharged few days later and has remained stable. Slower tapering of the prednisolone was restarted again a few weeks later and she has remained stable. She is being followed up by both the rheumatology and the haemato-oncology unit.

**Comment [PW12]:**

**Comment [PW13]:** Clearly describe the methodology and equipment, the test of the immunological research system

**Comment [PW14]:**

**Comment [PW15]:** Specify the name of the drugs, their dose, the course of treatment

**FIGURE 1. Clinical profile 1**

UNDER PEER REVIEW

<b>Sex</b>	F	<b>Mobile</b>
<b>ID Number</b>	QMLIS476256	<b>Telephone</b>
<b>Date of Birth</b>	2008 / 10 / 01	<b>Email</b>
<b>Age</b>	13	<b>Address</b>

Report Details		
<b>Requisition Number</b>	373023655	<b>Specimen Type</b>
<b>Order Reference</b>		<b>Comments</b>
<b>Collection Date</b>	06:17 09 Oct 2021	<b>Diagnosis</b>
<b>Request Date</b>	17:48 10 Oct 2021	MEGALOBlastic ANAEMIA +IRON DEFIC
<b>Report Date</b>	08:34 30 Oct 2021	
<b>Report Updated Date</b>	08:38 30 Oct 2021	<b>Tests Resulted</b>
<b>Report Type</b>	FINAL REPORT	% Saturation; ANA (Antinuclear Antibodies)
<b>Priority</b>	ROUTINE	Ferritin; Folate Serum; Intrinsic Factor Ab; I Methylmalonic Acid Serum; Transferrin

## Auto-Immune Results

Name	Result	Range	Units
<b>ANA (Antinuclear Antibodies) (IFA):</b>			
Antinuclear Factor Screen	POSITIVE	NEGATIVE <1:80	
Antinuclear Factor Titre ANA (IFA)	1:5120	NEGATIVE <1:80 Titre	Titre
ANA Fluorescence Pattern	ANA Fluorescence pattern : speckled Antinuclear antibodies with speckled pattern are typically to find in systemic lupus erythematoses (SLE), Sjogren syndrome, mixed collagenosis (MCTD/SHARP syndrome) as well as in sclerodermia or other rheumatic diseases.		
<b>ENA 17 profile:</b>			
U1-snRNP	NEGATIVE	NEGATIVE	
PCNA	NEGATIVE	NEGATIVE	
PM-Scl	NEGATIVE	NEGATIVE	
Mi-2	NEGATIVE	NEGATIVE	

SYNLAB Portal 2021 / Requisition Number: 373023655

**Fig. 1. Clinical profile 1.** The result of the study of a 13-year-old girl at...

**Comment [PW16]:**

**Comment [PW17]:** In the figure legend, enter clear comments and decipher abbreviations and acronyms

**Comment [PW18]:**

**Comment [PW19]:**

Formatted: Ukrainian (Ukraine)

## FIGURE 2. Clinical profile 2

Sex	F	Mobile
ID Number	QMLIS476256	Telephone
Date of Birth	2008 / 10 / 01	Email
Age	13	Address

Name	Result	Range	Units
Ku	NEGATIVE		
Anti ds DNA	3.1 (++) POSITIVE	NEGATIVE	
SS-A AntiRo 52- (Immunoblot)	NEGATIVE	NEGATIVE	
SS-A AntiRo 60- (Immunoblot)	NEGATIVE	NEGATIVE	
SS-B AntiLa- (Immunoblot)	NEGATIVE	NEGATIVE	
Anti Jo-1 (Immunoblot)	NEGATIVE	NEGATIVE	
Anti Scl 70 (Immunoblot)	NEGATIVE	NEGATIVE	
Anti Sm (Immunoblot)	NEGATIVE	NEGATIVE	
Anti-SM/RNP- (Immunoblot)	NEGATIVE	NEGATIVE	
Anti-Centromere	NEGATIVE	NEGATIVE	
Anti-Histon abs	NEGATIVE	NEGATIVE	
Ribosomal P-Protein (RIB)	NEGATIVE	NEGATIVE	
Nucleosom	NEGATIVE	NEGATIVE	
Intrinsic Factor Ab	2.70	0-6.0	U/mL

Comments:

Negative: <6.0

Comment [PW20]:

Comment [PW21]:

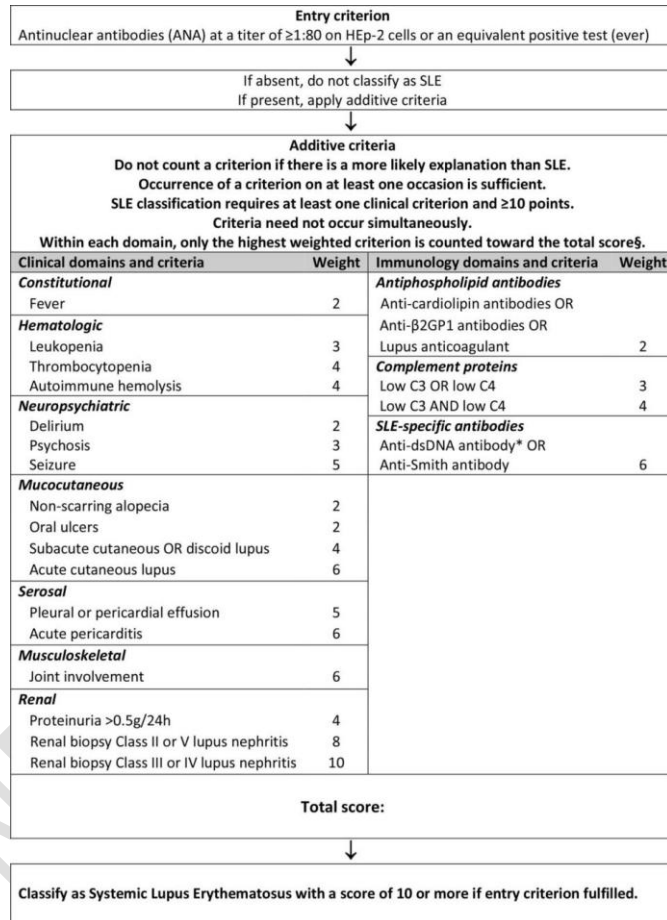
Comment [PW22]:

Comment [PW23]:

Comment [PW24]: In the figure legend, enter clear comments and decipher abbreviations and acronyms

Fig. 2. FIGURE The result of the study of a 13-year-old girl at... 2. Clinical profile 2

**FIGURE 3. Clinical profile 3**



**Fig. ICURE 3.** The result of the study of a 13-year-old girl at... **Clinical profile 3**

### 3. DISCUSSION

Systemic lupus erythematosus (SLE) is a multisystemic inflammatory disease with presence of circulating auto antibodies directed against self-antigens. The pathogenesis of SLE remains largely unknown though genetics, hormones and environmental exposures may increase the risk and severity of disease. SLE preferentially affects females especially during their reproductive years. It can involve any organ system and may lead to significant morbidity and mortality.<sup>6</sup> The presentation and clinical courses are different among various ages at the onset of the disease. Hence in children, making a diagnosis from clinical features alone can sometimes be challenging.<sup>7</sup>

Children and adolescents with SLE have more severe disease and widespread organ involvement with a higher prevalence of haematologic anomalies in paediatric patients compared to adults.<sup>8</sup> Haematologic manifestations include anaemia of chronic disease (70%), leucopaenia (65%), lymphopaenia (50%), thrombocytopenia (15%), lymphadenopathy (15%), splenomegaly (15%), and haemolytic anaemia (10%). These haematologic involvements may result from bone marrow failure or excessive peripheral cell destruction, both of which may be immune-mediated.<sup>9</sup>

The American college of Rheumatology (ACR) and Systemic Lupus International Collaborating Clinics (SLICC) acknowledge AIHA as one of the diagnostic criteria for SLE. The 2019 European League against Rheumatism/American College of Rheumatology classification criteria for systemic lupus erythematosus (EULAR/ACR 2019) also recognises AIHA as one of the diagnostic criteria for SLE. AIHA may be the first and only manifestation of SLE and can appear earlier before SLE is diagnosed as well as occur as part of an SLE flare.<sup>1,6,10</sup> The mechanism is thought to be immune-mediated destruction of red blood cells.

AIHA is classified by the temperature at which autoantibodies optimally bind to RBCs. In cold antibody AIHA, the antibodies are of IgM class which react at temperatures of <37°C, require complement for activity and produce spontaneous agglutination of red blood cells in vitro while

**Comment [PW25]:**

**Comment [PW26]:**

**Comment [PW27]:** The result of the study of a 13-year-old girl at...

**Comment [PW28]:**

**Comment [PW29]:** In the figure legend, enter clear comments and decipher abbreviations and acronyms

**Comment [PW30]:** In the figure legend, enter clear comments and decipher abbreviations and acronyms

**Formatted:** Font: (Default) Times New Roman, 12 pt

**Formatted:** List Paragraph, Line spacing: single, Numbered + Level: 1 + Numbering Style: 1, 2, 3, ... + Start at: 1 + Alignment: Left + Aligned at: 0.25" + Indent at: 0.5"

in warm antibody AIHA, haemolysis is mediated by antibodies which bind to RBCs at 37°C (98.6 °F).<sup>2</sup> The most common presenting complaints of children with SLE include fever, fatigue, hematologic abnormalities, arthralgia, and arthritis.<sup>5</sup> In our patient, haematological abnormality was the initial and only presentation so far. Clinically, AIHA can range from mild haemolysis with compensatory reticulocytosis to rapid, life-threatening haemolysis which can result in hemodynamic compromise.<sup>11, 12</sup>

SLE can be diagnosed based on clinical manifestations and presence of auto antibodies.

Antinuclear antibodies (ANA) are positive in >98% of patients during the course of disease while antibodies to Smith antigen and high titre Immunoglobulin G antibodies to double stranded DNA are both specific for SLE.<sup>13</sup> The Coombs test or direct antiglobulin test (DAT) is used to screen for erythrocyte antibodies, and positive results are common in patients with AIHA.

However, it may be absent in some paediatric cases with a frequency ranging from 6% to 23%.<sup>14-16</sup>

In treatment of AIHA, targeted goals include decreasing haemolysis, stabilizing haemoglobin levels and preventing complications. First-line treatments include the use of corticosteroids either as pulsed intravenous methylprednisolone or high-dose oral prednisolone.<sup>11</sup> Steroids should be tapered slowly over approximately 6 months because rapid tapering or discontinuation have been associated with disease relapse. Also, steroid-sparing drugs such as azathioprine, hydroxychloroquine, mycophenolate mofetil, rituximab and tacrolimus are also used.<sup>11</sup> Supportive therapy which include administration of packed red blood cells, platelets, fresh frozen plasma can be given in children with severe anaemia.<sup>17</sup>

Here, we report the case of a 13-year-old with AIHA the first and only manifestation of SLE. Patient is still on prednisolone and immunosuppressant and has not developed any other symptom since diagnosis. Giriyan et al,<sup>13</sup> also reported the case of a 12-year-old female with AIHA as an initial presentation of SLE but later developed malar rash and haematuria during the course of the disease but in our case, patient is yet to develop any other symptom other than the AIHA.

#### **4. CONCLUSION**

Formatted: Numbered + Level: 1 +  
Numbering Style: 1, 2, 3, ... + Start at: 1 +  
Alignment: Left + Aligned at: 0.25" + Indent  
at: 0.5"

SLE is a chronic autoimmune disease with affection of multiple organs. AIHA can be the initial and only presentation of SLE, emphasizing the importance of a high index of suspicion and thorough work-up in children with clinical evidence of haemolytic anaemia to aid timely diagnosis and management of underlying secondary conditions.

**Comment [PW31]:**

**Comment [PW32]:** Change the text. To give a clear recommendation for practicing doctors

**Comment [PW33]:**

**Comment [PW34]:** Enter data into sections ETHICAL APPROVAL, CONSENT, COMPETING INTERETS

**Comment [PW35]:**

## REFERENCES

1. Liebman HA, Weitz IC. Autoimmune haemolytic anaemia. *Med Clin North Am* 2017; 101: 351–59
2. Voulgaridou A, Kalfa TA. Autoimmune Haemolytic Anaemia in the Paediatric Setting. *J Clin Med* 2021; 10: 216-218.
3. Singh A, Mandal A, Patel A, Mishra S. Autoimmune Haemolytic Anaemia-A Spectrum of Presentation in Children. *J Clin Diagn Res* 2017; 11: 1-2.
4. Wołowiec M, Adamowicz-Salach A, Gołębiowska-Staroszczyk S, Demkow U, Skrzypczak-Pamięta M, Michalewska B, *et al.* Autoimmune haemolytic anaemia in children during 2004-2014 in the Department of Paediatrics, Haematology and Oncology, Warsaw Medical University. *Polish Annals of Medicine* 2015; 22: 119–123.
5. Rebecca E, Stacy P, Laura E. Systemic Lupus Erythematosus. Nelson Textbook of Paediatrics. 21<sup>st</sup> ed. Philadelphia: Elsevier; 2020. p 1176-1181.
6. Akca ÜK, Batu ED, Kisaarslan AP, *et al.* Haematological involvement in paediatric systemic lupus erythematosus: a multi-center study. *Lupus* 2021; 30: 1983-1990.
7. Smith EMD, Lythgoe H, Midgley A, *et al.* Juvenile-onset systemic lupus erythematosus: update on clinical presentation, pathophysiology and treatment options. *Clin immunol* 2019; 209: 108274.
8. Ardoin SP, Daly R, Merzoug L, *et al.* Research priorities in childhood-onset lupus: results of a multidisciplinary prioritization exercise. *Pediatr Rheumatol* 2019; 17: 32-34.
9. Hahn BH. Systemic Lupus Erythematosus. In: Longo DL, Kasper DL, Jameson JL, Fauci AS, Hauser SL, Loscalzo J, editors. Harrison's Principles of Internal Medicine. 18th edition. United States of America: The McGraw-Hill Companies. 2012; 1:2724- 2735.

10. Velo-García A, Castro SG, Isenberg DA. The diagnosis and management of the haematologic manifestations of lupus. *J Autoimmun* 2016; 74: 139-160.
11. Neely J, Von Scheven E. Autoimmune haemolytic anaemia and autoimmune thrombocytopenia in childhood-onset systemic lupus erythematosus: updates on pathogenesis and treatment. *Curr Opin Rheumatol* 2018; 30: 498–505.
12. Artim-Esen B, Çene E, Şahinkaya Y, *et al.* Autoimmune haemolytic anaemia and thrombocytopenia in a single-centre cohort of patients with systemic lupus erythematosus from Turkey: clinical associations and effect on disease damage and survival. *Lupus* 2019; 28: 1480–1487.
13. Giriyan SS, Priya, Reddy P. Autoimmune haemolytic anaemia- an initial presentation in childhood systemic lupus erythematosus. *Trop J Path Micro* 2019; 5: 745-749.
14. Fan J, He H, Zhao W, Wang Y, Lu J, Li J, *et al.* Clinical Features and Treatment Outcomes of Childhood Autoimmune Haemolytic Anaemia: A Retrospective Analysis of 68 Cases. *J Pediatr Hematol Oncol* 2016; 38 : 50-55.
15. Abdel-Salam A, Bassiouni ST, Goher AM, *et al.* Autoimmune Haemolytic Anaemia in the Paediatric Age Group: The Egyptian Experience. *Ann Hematol* 2023; 24: 1-8.
16. Skare T, Picelli L, Dos Santos TAG, *et al.* Direct antiglobulin (Coombs) test in systemic lupus erythematosus patients. *Clin Rheumatol* 2017; 36: 2141–2144.
17. Kocheril AP, Vettiyil GI, George AS, *et al.* Paediatric systemic lupus erythematosus with lupus anticoagulant hypoprothrombinemia syndrome - a case series with review of literature. *Lupus* 2021; 30: 641–648.

**Comment [PW36]:**

**Comment [PW37]:** Strictly follow the registration rules. Add DOI, change style