

An exceptional cardiac myxoma case defying convention

Abstract:

Background: Cardiac myxomas, the most common primary heart neoplasms, primarily originate in the left atrium and carry the potential for serious complications, including mitral valve obstruction and embolic events. Here, we report a rare case of a left atrial myxoma leading to complete atrioventricular block.

Case Presentation: A 60-year-old male, with no history of diabetes or hypertension, presented with exertional dyspnea (NYHA class III), lipothymia, and a diastolic murmur in the mitral area. Extensive evaluation revealed a third-degree atrioventricular block. Urgent surgery successfully removed the myxoma, and a permanent pacemaker was implanted postoperatively. The patient had an uneventful recovery and improved during follow-up.

Discussion: Cardiac myxomas are rare, accounting for approximately 0.2% of all neoplasms. Clinical presentations vary, with many patients remaining asymptomatic until complications occur. Echocardiography is essential for detection, while electrocardiographic abnormalities may provide diagnostic insights. Surgical removal is the standard treatment, emphasizing the importance of timely intervention.

Conclusion: Cardiac myxomas present a diverse clinical spectrum, highlighting the need for timely detection and intervention. Surgical removal remains crucial to prevent complications and secure favorable patient outcomes.

Keywords : *Cardiac myxomas; third-degree atrioventricular block ; mitral valve obstruction; embolic risk*

1. Introduction:

Cardiac myxomas are common primary neoplasms arising mostly from the left atrium. They are benign tumors but potentially “malignant” due to their high potential for complications including the obstruction of the mitral valve and embolic event. Here, we report a rare case of a prolapsing left atrial myxoma obstructing the mitral valve and manifesting as complete atrioventricular block.

2. Case presentation:

We hereby describe the case of a 60-year-old man, with no history of diabetes nor hypertension, our patient was admitted with exerting dyspneastage III of NYHA for 3 months leading to a lipothymia, upon admission our patient’s initial vital signs were as follows: blood pressure was 111/56 mm Hg; respiratory rate was 19 breaths/min; and pulse rate was 43 beats/min. Physical examination found a normal neurological examination and revealed a diastolic murmur in mitral area and no signs of heart failure. A full blood work up was conducted, including complete blood cell count, kidney function, liver function, electrolytes, thyroid function, hs-Troponin and infection indicators, the results were unremarkable. The electrocardiogram (ECG) revealed a third-degree atrioventricular block (AVB). We performed trans-thoracic echocardiography (TTE) in order to further evaluate the dyspnea, which revealed a large mobile mass in the left atrium attached to the interatrial septum prolapsing into the left ventricle during diastole and causing mitral valve obstruction (**Figure 1 and 2**). There was no evidence of systemic thromboembolism or malignancy. A coronary angiography was conducted and did not reveal any coronary lesions.

Surgery was planned urgently to remove the mass given the hemodynamic and embolic risk and for evaluation of the mitral valve. A temporary transvenous pacing was performed, and the patient was sent to the operating room. The mass, which was attached to the fossa ovalis, was removed and the septal defect was repaired. Histological findings were compatible with myxoma with no evidence of malignancy or atypical mitosis. **(Figure 3)** Follow-up echocardiography showed neither remnant mass or shunts, but a permanent pacing was performed given the persisting high degree atrioventricular block even after surgery.

The patient had an unremarkable ICU course and was discharged home, frequent follow up showed improvement in the dyspnea NYHA stage II and a stable condition with no recurrence so far

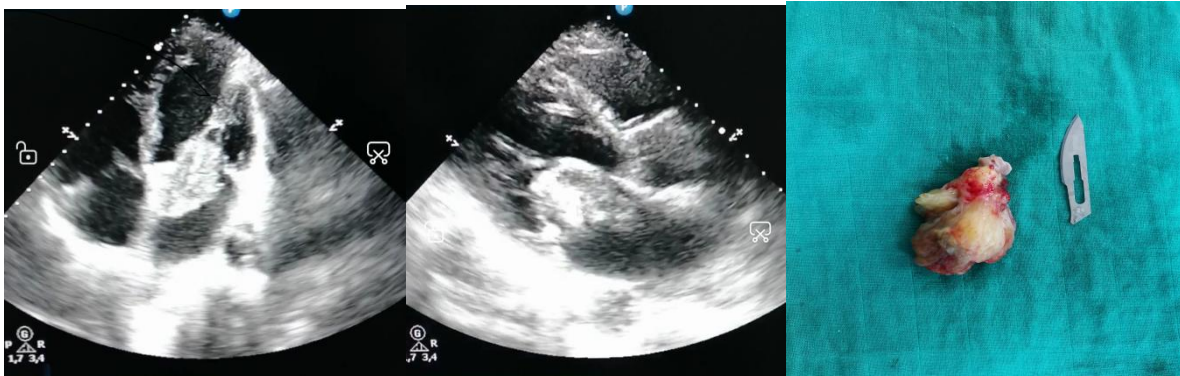


Figure 1 and 2: Transthoracic echocardiography showing a large left atrial myxoma protruding into the left ventricular cavity across the mitral valve **Figure 3:** the excised tumor in one piece

3. Discussion:

Cardiac myxoma is the most common type of cardiac tumor, although it is a relatively rare condition, accounting for only about 0.2% of all neoplasm. (1)

The clinical presentation can vary depending mainly on the size, positioning, and mobility of the tumor. Notably, approximately 3.2% to 46.4% of patients with cardiac myxomas remain asymptomatic. Symptoms typically manifest when the myxoma obstructs blood flow by prolapsing through a valvular orifice. Common symptoms include dyspnea, palpitations, syncope, tachycardia, and, in severe cases, sudden death. Systemic embolization can lead to neurologic deficits when emboli reach the brain.(2)(3)

Echocardiography is an invaluable diagnostic tool, offering a sensitivity of 95 to 99% for detecting myxomas. Additionally, three-dimensional reconstruction allows for a detailed assessment of the mass, evaluation of mitral valve compromise, and a thorough examination of left atrial morphology. This aids in ruling out alternative diagnoses. (3)(4)

Electrocardiographic abnormalities associated with myxomas are also variable. Left atrial hypertrophy is the most frequent finding. While ST-segment abnormalities, nonspecific ECG changes, and ventricular hypertrophy can occur. However, atrial flutter and conduction disturbances are uncommon.(5)(6)

Potential complications of cardiac myxomas include partial obstruction of the mitral valve, leading to pulmonary vein congestion, pulmonary edema, elevated pulmonary artery pressure, and reduced cardiac output. Atrial dysrhythmia is also a considerable risk.(2)(3)(7)(8)(9)

Recent immunologic studies suggest the expression of multiple macrophage phenotypes and the release of various inflammatory mediators, including tumor necrosis factor α , which may be related to mechanical stress within the atrial cavity caused by the tumor. These responses correlate directly with the tumor's size, with more pronounced effects seen in larger tumors, often contributing to the development of constitutional symptoms. (10)

Notable research findings include Keeling et al.'s report on myxomas in the left atrium, indicating a significant risk of embolism when they occur in rhythms other than sinus. Pinede et al. associated ECG abnormalities with systemic manifestations and cardiac signs but not with embolic or neurological symptoms. Conversely, Nadeem et al. reported a case of left atrial myxoma presenting with ventricular fibrillation, which was significantly associated with embolic symptoms. (5)

The gold standard for treating cardiac myxomas is surgical removal, and this should be done promptly due to the risk of embolic complications.(11)It's note worthy that the literature reviews revealed limited reports of left atrial myxoma causing conduction disturbances.

4. Conclusion :

Within the intricate landscape of cardiac disorders, cardiac myxomas stand as both the most common and enigmatic of cardiac tumors. Uncommon yet unpredictable, they reveal a wide spectrum of clinical presentations. Their elusive nature underscores the importance of early identification and refined diagnostics, supported by cutting-edge imaging technologies. Surgical removal emerges as the decisive strategy to avert potential embolic perils. As we delve deeper into the intricate mysteries of cardiac myxomas, timely intervention takes center stage in shaping brighter outcomes and preserving the well-being of our patients.

CONSENT

As per international standard or university standard, patient(s) written consent has been collected and preserved by the author(s).

ETHICAL APPROVAL

As per international standard or university standard written ethical approval has been collected and preserved by the author(s).

References

1. Nguyen T, Vaidya Y. Atrial Myxoma. In: StatPearls [Internet]. Treasure Island (FL): StatPearls Publishing; 2023 [cité 23 oct 2023]. Disponible sur: <http://www.ncbi.nlm.nih.gov/books/NBK556040/>
2. Snoussi NEH, Serroukh Y, El Hattab FZ, Cherti M. Giant Left Atrial Myxoma Revealed by Syncopal Attacks. J Saudi Heart Assoc. 22 juill 2022;34(2):113.
3. Gutierrez SE, Valero W, Melendez A. Giant Left Atrial Myxoma Obstructing Mitral Valve Bloodflow. Anesthesiology. 1 juill 2019;131(1):151- 2.
4. Vilela EP, Moura L, Pepe D, Nunes E, Erthal F, Campana E. Giant atrial myxoma mimicking severe mitral stenosis in young patient. Arq Bras Cardiol. oct 2010;95:e125- 7.
5. Lee JH, Lee GW, Kim OK, Hur JH, Choi BJ, Choi KJ, et al. A Case of Large Left Atrial Myxoma Presenting as Atrial Flutter. J Cardiovasc Ultrasound. 1 juin 2008;16(2):59- 62.
6. Surabhi S, Fasseas P, VanDecker W, Hanau C, Wolf N. Right Atrial Myxoma in a Patient Presenting with Syncope. Tex Heart Inst J Tex Heart Inst St Lukes Episcop Hosp Tex Child Hosp. 1 févr 2001;28:228- 9.
7. Rajani AR, Muaz RN, Govindaswamy PR, Mian MH. Arrhythmias are not to blame for all cardiac syncope patients: left atrial myxoma causing syncope in a middle-aged man. Case Rep. 15 avr 2015;2015:bcr2014209119.

8. Kaya M, Ersoy B, Yeniterzi M. Mitral valve regurgitation due to annular dilatation caused by a huge and floating left atrial myxoma. *Kardiochirurgia Torakochirurgia Pol J Thorac Cardiovasc Surg.* 2015;12(3):248- 58.
9. Wu HY, Shou XL, Cao YW. An Unusual Cause of Complete Atrioventricular Block in a Patient With Pedal Swelling. *JAMA Intern Med.* 1 déc 2021;181(12):1650-1.
10. Al-Ameri A, Salerno TA. Commentary: The immunologic mystery of cardiac myxoma. *JTCVS Tech.* 1 mars 2020;1:73- 4.
11. Kurnick A, Burkhanova U, Friedman A, John S, Bukharovich I. A Rare Case of Massive Left Atrial Myxoma Presenting as Syncope. *Cureus.* 15(7):e41249.

UNDER PEER REVIEW