

# LATE MANIFESTATION OF CONGENITAL HEART DISEASE:RIGHT-SIDE INFECTIVE ENDOCARDITIS AND THE MYSTERY OF THE UNSEEN VENTRICULAR SEPTAL DEFECT: CASE REPORT

## ABSTRACT :

Infective endocarditis (IE) is a severe complication in patients with congenital heart disease. However, CHD-associated mortality has decreased to 10% because of improvements in the diagnosis of infective endocarditis, antibiotic therapy, cardiac surgery, and interventional procedures. Herein, we aimed to illustrate a case of right-sided infective endocarditis associated with an unknown ventricular septal defect, complicated by septic pulmonary emboli as a rare form of delayed presentation of congenital heart disease.

The significant occurrence of infective endocarditis prompts the need for additional investigations into the current utilization, necessity, and effectiveness of antibiotic prophylaxis in patients with congenital heart disease (CHD).

*Keywords: Ventricular septal defect; right side infective endocarditis; pulmonary embolism;*

## 1. INTRODUCTION

Infective endocarditis (IE) is a prevalent cause of life-threatening infections. In contrast to left-sided endocarditis, right-sided infective endocarditis is less common. We present the case of a previously seemingly healthy young woman with a belated diagnosis of congenital heart disease (CHD), wherein IE served as the initial manifestation of the disease.

## 2. PRESENTATION OF CASES

We describe the case of a 27-year-old woman with no prior history of illness or medical check-ups during childhood. She has a history of repeated corticosteroid injections for weight gain. She sought emergency care due to a three-week history of breathlessness, asthenia, and fever.

At his admission, the physical examination found, a blood pressure at 122/62 mmHg, regular heart rate at 130 beats per minute, a respiratory rate at 28 breaths per minute, SpO<sub>2</sub> at 83%, temperature at 38.9°C. Cardiac auscultation revealed a diastolic murmur at the right second intercostal space, pulmonary auscultation revealed crackles in both lung fields without any other signs of congestion, The abdomen was soft with hepatosplenomegaly

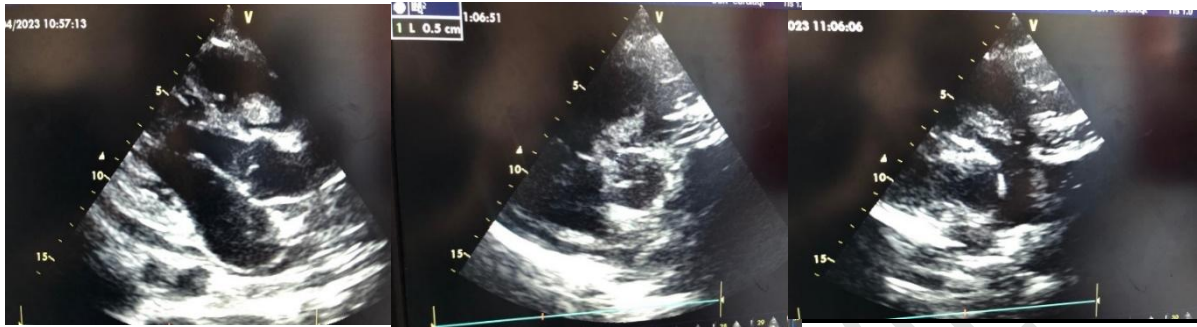Laboratory tests showed microcytic hypochromic anaemia with a haemoglobin level of 6.2 g/dl and no ferritin deficiency explained by inflammatory systemic disease, with an active infection (neutrophilic leukocytosis: 26 103/μl, with 20 × 103/μl neutrophils, and C-reactive protein 242 mg/dl), procalcitonin 32,2,

Transthoracic echocardiography with a Doppler study was performed which revealed a small perimembranous restrictive VSD, with a left to right shunt, with large vegetation measuring 35 x33 mm inserted on the perimembranous ventricular septal defect extended through the pulmonary infundibulum to the main pulmonary artery during systole, Moderate tricuspid regurgitation was documented, The other valves presented no vegetation or severe regurgitation. Left ventricular function was preserved.

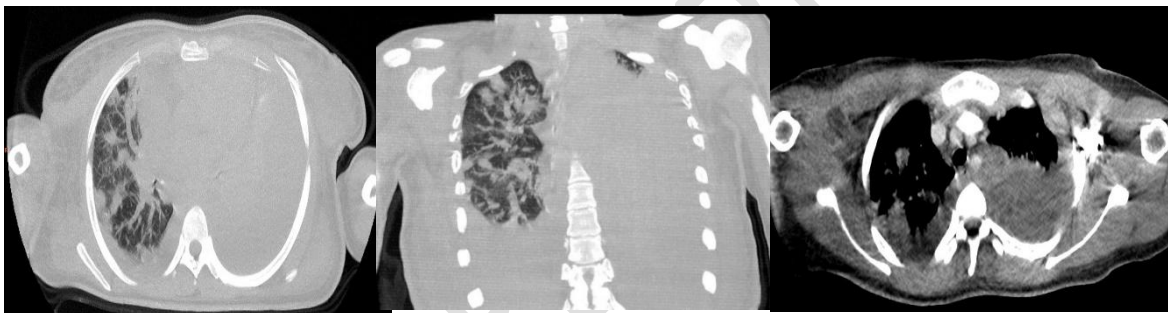
A chest X-ray revealed bilateral alveolar infiltrates, In addition, a CT scan of the thorax demonstrated septic pulmonary emboli, as well as mild right pleural effusion

Microbiology studies were conducted concurrently with empiric synergic dual antibiotic therapy: ceftriaxone at 2g/day and gentamicin at 3mg/kg/day while awaiting the antibiogram results. At least two sets of blood cultures confirmed the presence of methicillin-sensitive *Staphylococcus aureus*. The patient was diagnosed with endocarditis complicating perimembranous VSD following the 2023 European Society of Cardiology modified diagnostic criteria of infective endocarditis, Despite 1 week

of appropriate antibiotic therapy, she had persistent fever with rising CRP, repeated a CT scan of the thorax demonstrated multiple septic pulmonary emboli. Therefore, in consensus with our endocarditis team, including a cardiac surgery evaluation, and given the hemodynamic and embolic risk, we decided to perform surgical treatment, segmentectomy, VSD patch closure and tricuspid valve plasty depending on surgical exploration. The patient's postoperative course was uneventful and he was discharged 2 weeks after surgery.



**Figure 1:** Transthoracic echocardiography showed an enormous vegetation measuring 35 x33 mm inserted on the perimembranous ventricular septal defect extended through the pulmonary infundibulum to the main pulmonary artery during systole



**Figure 2:** A CT scan of the thorax demonstrated foci of pulmonary condensation associated with masses and pulmonary nodules that are scattered and excavated in places with pleural effusion of great abundance on the right and little on the left, suggesting an infectious origin (septic emboli).

### 3. DISCUSSION

Right-sided infective endocarditis (IE) is uncommon, constituting only 5–10% of all IE cases (1). IE is a rare complication associated with ventricular septal defects, with an estimated incidence of 2 cases per 1000 patient years.(1)(2)(3)

Congenital heart disease predisposes to IE via several mechanisms including turbulent non-laminar blood flow causing shear stress and endothelial damage,

Risk factors for right-sided infective endocarditis (IE) encompass patients with congenital heart disease (CHD), indwelling catheters, and cardiac implantable electronic devices (CIED), along with immunocompromised individuals and those who inject drugs (PWID).(1)

The most common microorganism causing right-side EI is *S.aureus*, accounting for the majority of patients, the tricuspid valve is much more commonly infected (4)(5), Right-sided IE patients generally present with fever, bacteraemia, and pulmonary complaints such as cough, chest pain, or haemoptysis. "Right-sided HF may also occur due to tricuspid or pulmonary regurgitation, or to pulmonary hypertension induced by multiple pulmonary septic emboli". (5)(6)(7)

It has been recommended that patients presenting with multiple lung cavity lesions accompanied by fever should undergo an evaluation for right-sided infective endocarditis (IE) using transesophageal echocardiography, even in the absence of significant risk factors(8)

An active investigation for embolization is always recommended in patients with endocarditis, particularly in those with large (>10 mm) and mobile vegetation

Pulmonary septic embolization is a common complication of right-sided IE, and computed tomography scan is the imaging modality of choice.(8), In a retrospective analysis conducted by Hecht and

Berger in 1992 (9) they found approximately 55% of patients with chest radiograph infiltration on presentation consistent with pulmonary septic emboli. Our patient had embolization of vegetation into the main pulmonary trunk, resulting in septic atelectasis, pneumonia, and pleural effusion. Right-sided infective endocarditis (IE) is generally considered a less severe clinical condition compared to left-sided IE. It can be managed medically in approximately 90% of patients, with surgery reserved for those who do not respond to medical therapy(10)

According to the ESC guidelines for the management of infective endocarditis (EI), surgery is recommended in certain cases of right-sided EI. "This includes situations where patients are receiving appropriate antibiotic therapy, but surgery is advised under the following conditions: right ventricular dysfunction due to acute severe tricuspid regurgitation that does not respond to diuretics, persistent vegetation with respiratory insufficiency requiring ventilatory support after recurrent pulmonary emboli, the presence of large residual tricuspid vegetations (>20 mm) after recurrent septic pulmonary emboli, and in patients with simultaneous involvement of left-heart structures"(2)

#### **4. CONCLUSION**

One of the significant long-term complications in patients with congenital heart disease (CHD) is infective endocarditis (IE). Additionally, a proactive examination for clinical and radiological indicators of pulmonary embolization is imperative for patients with right-sided endocarditis, particularly those exhibiting substantial and mobile vegetation. Ensuring primary prevention of IE in CHD patients and providing corresponding patient education is crucial.

#### **CONSENT**

As per international standards or university standards, patient(s) written consent has been collected and preserved by the author(s).

#### **ETHICAL APPROVAL**

As per international standards or university standards written ethical approval has been collected and preserved by the author(s).

#### **REFERENCES :**

1. 2020 ESC Guidelines for the management of adult congenital heart disease | European Heart Journal | Oxford Academic [Internet]. [cité 22 Oct 2023]. Disponible sur: <https://academic.oup.com/eurheartj/article/42/6/563/5898606?login=false>
2. 2023 ESC Guidelines for the management of endocarditis | European Heart Journal | Oxford Academic [Internet]. [cité 22 oct 2023]. Disponible sur: <https://academic.oup.com/eurheartj/article/44/39/3948/7243107?login=false>
3. Zijlstra F, Fioretti P, Roelandt JR. Echocardiographic demonstration of free wall vegetative endocarditis complicated by a pulmonary embolism in a patient with ventricular septal defect. *Br Heart J*. mai 1986;55(5):497- 9.
4. Elmasrioui J, Islah Y, Eljamili M, Karimi SE, Elhattaoui M, Benfaddoul O, et al. Double Outlet Right Ventricle Infective Endocarditis: A Rare Combination and a Therapeutic Challenge. mai 2023 [cité 22 oct 2023]; Disponible sur: <https://imsear.searo.who.int/handle/123456789/220315>
5. Nakagawa N. Infective Endocarditis in Congenital Heart Disease [Internet]. IntechOpen; 2022 [cité 22 oct 2023]. Disponible sur: <https://www.intechopen.com/online-first/83994>
6. Falicov RE, O'Donoghue JK, Cassels DE. Anomalous Right Ventricular Muscle Bundles and Ventricular Septal Defect Complicated by Subacute Bacterial Endocarditis. *Arch Intern Med*. 1 sept 1972;130(3):404- 7.
7. Yousra H, Salma H, Seydou HI, Fatiha K, Hanane C, Muhammed OS, et al. Right-sided Infective Endocarditis with Unknown Ventricular Septal Defect in Adult Complicated by Septic Pulmonary Emboli and Acute Renal Failure: Case Report. *Asian J Cardiol Res*. 20 mai 2023;152- 8.

8. Lim WJ, Kaisbain N, Kim HS. Septic pulmonary emboli in pulmonary valve endocarditis with concurrent ventricular septal defect and coronary artery disease: a case report. *Eur Heart J Case Rep.* avr 2022;6(4):ytac162.
9. Hecht SR, Berger M. Right-sided endocarditis in intravenous drug users. Prognostic features in 102 episodes. *Ann Intern Med.* 1 oct 1992;117(7):560- 6.
10. Mulder BJM. Endocarditis in congenital heart disease: who is at highest risk? *Circulation.* 24 sept 2013;128(13):1396- 7.

UNDER PEER REVIEW