

Case report

Fabrication of Customized Ocular Prosthesis using a Surface Sealant and Modified Laboratory Technique using Stainless Steel Wire

ABSTRACT

Eye defects are surgically classified as evisceration, enucleation, and exenteration. It causes psychological trauma as an individual is visually and esthetically compromised. Eye defects can be restored with silicone or acrylic-based prosthesis. This is a case report of a patient with a customized ocular prosthesis. Particular attention has been given to securing the iris shell during the laboratory process. The appearance of the patient was enhanced with the eye prosthesis. A surface sealant has been used to provide glossiness to the prosthesis.

Keywords: ocular, prosthesis, iris shell, surface sealant

1. INTRODUCTION

The main causes of eye defects in the Indian subcontinent are trauma, tumors, and congenital absence of orbit [1, 2, 3]. Besides loss of vision, these patients become aesthetically challenged and psychologically compromised [4, 5]. A prosthetic eye can be replaced in cases where surgical correction is not amenable. This may involve replacing the entire eye or the part that replaces the outer scleral portion. A multidisciplinary approach including an ophthalmologist, prosthodontist, surgeon, and maxillofacial prosthetist should be considered for a stable outcome. These eyes can be prefabricated or custom-made, the latter offering better fit and aesthetics [2, 6, 7]

Presented here is a simple technique for ocular rehabilitation which is very effective and aesthetically satisfactory.

2. CASE REPORT

A 62-year-old female patient reported to the Department of Prosthodontics and Crown and Bridge with a defect in her left eye seeking prosthetic replacement [Figure 1].



Figure 1: Pretreatment Photograph.

The defect was caused by domestic trauma five years back. On inspection, the sclera and iris were not completely present which left behind only the socket with the eye lids intact [Figure 2].

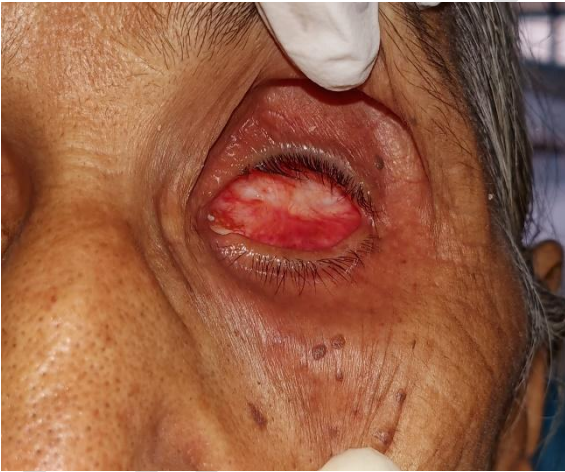

Figure 2: Examination of the eye socket.

The upper and lower eyelid muscle function seemed normal. No inflammation was present. A customised ocular prosthesis was proposed to the patient and a written consent was taken for the procedure.

Primary Impression

An intraocular tray of autopolymerising acrylic resin ((DPI- Bombay Burmah Trading Corporation Ltd. Mumbai) was made using the convex surface of thumb as an index to fit into the confines of the socket. The margins were smoothed with a finishing bur to prevent any irritation to the tissues inside the socket. The mucosa of the socket and eyelashes were lined with petroleum jelly prior to impression to avoid sticking of impression material. Irreversible hydrocolloid impression material (Septodont Saint-Maure-Des-Fosses-Cedex, France) was injected into the socket [Figure 3].

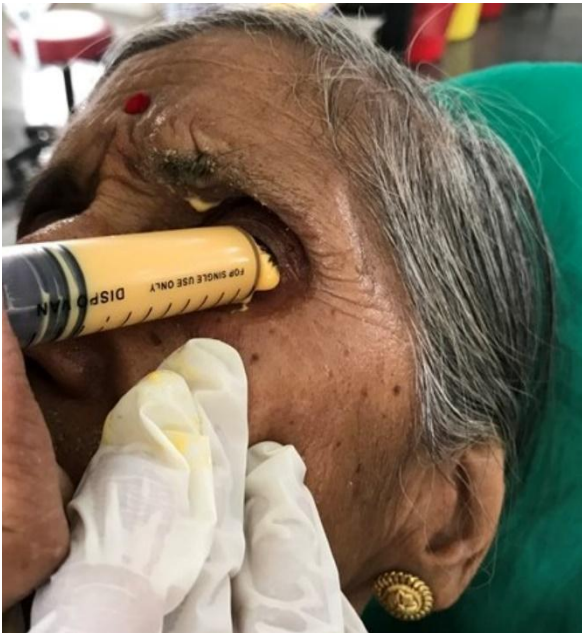

Figure 3: Primry Impression

The patient was instructed to move her eyes both up and down, to the right and to the left side. This facilitated the flow of impression material into all aspects of the socket. Later the patient was asked to gaze at a fixed point 6 feet away at the dimension of the eye to achieve a neutral gaze position. The impression was gently removed by massaging the lower lid downwards and away from the nose and then sliding the impression out from the upper eyelid. The impression was then washed and checked for accuracy and precision. The eye socket impression was poured in type III dental stone using the two-pour technique, and after setting the cast was removed. Once the cast was set, it was immersed in hot water for few minutes. A layer of separating media was applied over the impression surface of the cast. Using a wax pattern for final impression was decided after evaluating the depth of the socket in the primary cast. Molten wax (MAARC Shiva Product, Palghar- 401208) was then poured on the cast. On solidification the wax pattern was removed. Sharp edges and undesirable irregularities were eliminated and the portion of the wax that represented the palpebral fissure was re-contoured to form a smooth convex surface.

Final Impression

The final impression of the socket was made with a light viscosity rubber base impression material, with an auto-mixing tip using the wax pattern [Figure 5]. The patient was asked to perform various eye movements to facilitate the flow of the impression material into all aspects of the socket. The impression was carefully removed from the socket once the material had set [Figure 5].

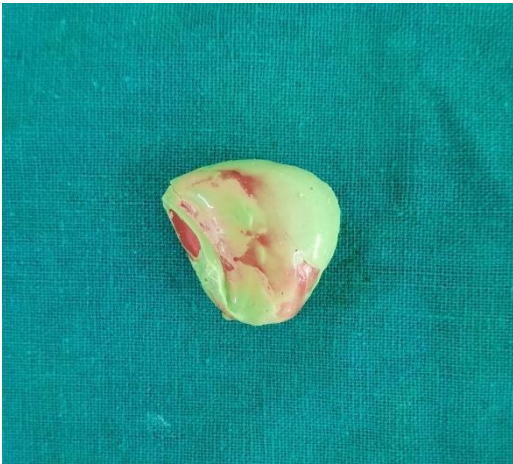

Figure 4: Final impression made with light body impression material and wax pattern.

The final impression was poured using the two pour technique and wax pattern was fabricated accordingly. The tissue surface of the wax pattern was not manipulated. The wax pattern was tried in the patient's eye for fit, bulkiness, comfort, drape and mobility of the eyelids [Figure 5].

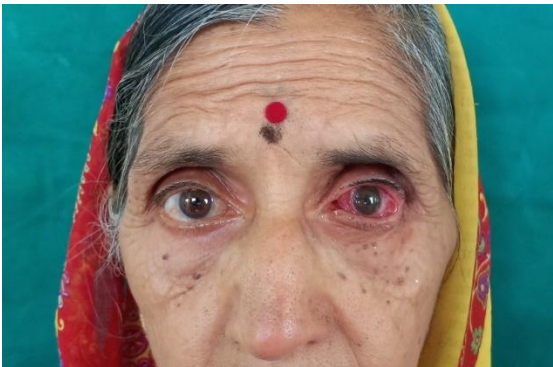

Figure 5: Wax Try-in.

Required adjustments were made. Corneal prominence was checked by standing behind the patient, making her look downwards and retracted her eyelids. This was done until the palpebral tissue and the soft tissue contour resembled the patient's natural eye. The shade and size of the eye shell was determined comparing the natural eye as a guide. Transparent graphical grid was used to attach the iris [Figure 6].



Figure 6: Positioning of Eye Shell using Transparent Grid.

Facial markings were transferred to the grid by placing it on the face. A vertical line was drawn on the patient's face traversing through the forehead crease, glabella, tip of the nose and chin. The distance between the right eye medial canthus to the midline and left eye medial canthus to the midline was measured and marked on the wax pattern. The patient was instructed to gaze straight at an object kept 6 feet away. The vertical lines marking the medial and distal extremities of the natural eye were marked on the graphical grid. Similarly, the horizontal lines traversing the centre, superior and inferior limit were marked on the graphical grid and transferred on the wax pattern and the iris button was attached to it. The eye movements were checked for symmetry and function. The wax pattern showed movements in harmony with the patient's normal eye movements.

Laboratory Procedure:

A 21 gauge stainless steel wire was embedded in the wax pattern on the superior, medial and lateral position to orient its position after deflasking [Figure 7].

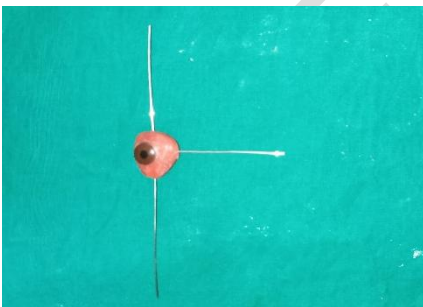


Figure 7: stainless steel wire embedded superiorly, medially and laterally.

Dewaxing was done after the final set and the flask was packed with Shade E heat polymerizing tooth moulding powder (DPI- Bombay Burmah Trading Corporation Ltd. Mumbai). Red nylon fibres were added to mimic veins present in natural eye during packing of tooth moulding powder [Figure 8].

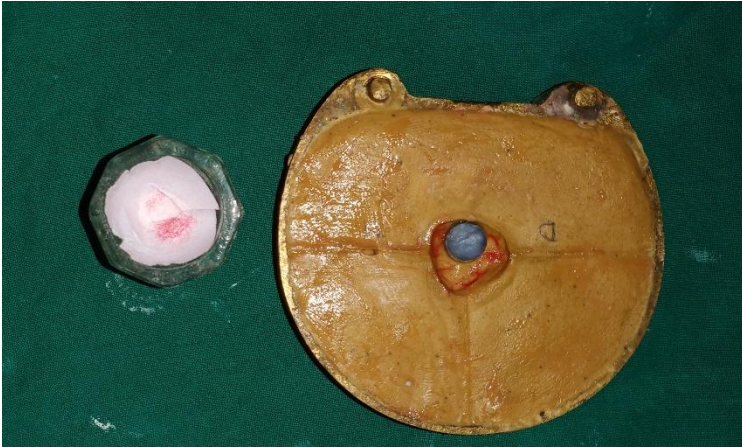


Figure 8: Nylon fibers added during packing.

Processing was done by heating flasks in water bath at 74°C for 2 hours and 100°C for 1 hour as it results in complete polymerization. Rough edges of the prosthesis were trimmed off. It was polished with the help of polishing burs, pumice and a buff to give the prosthesis a natural glossy finish. The iris was colored using pigments (BredentMultisil Epithetic Kit). The prosthesis was applied a coat of Biscover LV surface sealant (Bisco Ltd, USA) and light cured for 90 seconds in a light cure machine [Figure 9].




Figure 9: Light curing of surface sealant BiscoverLV applied on the eye prosthesis.

Prior to insertion of polished eye prosthesis, it was disinfected in 0.5% chlorhexidine solution for 5 minutes. The prosthesis was rinsed in sterile saline solution after disinfection to avoid chemical irritation. At the time of insertion, aesthetics, fit and the movement of the prosthesis were assessed. Insertion of ocular prosthesis was done [Figure 10] and post insertion instructions were given to the patient.



Figure 10: Post-Treatment Photograph.

3. DISCUSSION

This technique describes the fabrication of a prosthesis with materials that are easily available and regularly used by Maxillofacial Prosthodontist and Ocularist. The procedure ensures a good fit and natural esthetics of the artificial eye. It must be emphasized that the polish of the eye is also crucial in preventing conjunctival irritation and must be done with due diligence under magnification.

An ocular prosthesis is a simulation of human eye anatomy using prosthetic materials. The basic role of an ocular prosthesis is to keep up the volume of the eye socket and create an illusion of a perfectly normal healthy eye that can facilitate excellent eye movements. It upgrades the appearance and self-esteem and confidence of the patient [8].

Early management of an ophthalmic socket prevents volume loss in the anterior orbital area and facial asymmetry. There are two types of eye prosthesis, one is a pre-fabricated ocular prosthesis and the other is custom-made. Pre-fabricated prostheses can have disservices of poor fit, poor aesthetics, and poor eye movements [9]. According to Beumer et al. intimate contact between the ocular prosthesis and the tissue bed is expected to disseminate even pressure therefore a prefabricated prosthesis is avoided [10].

The voids in the prefabricated prosthesis collect debris and mucus, which can irritate mucosa and act as a foci of contamination, which are limited in custom-made prosthesis [11].

In this technique, the wax pattern was used for border molding and the secondary impression has been used as an alternative to other impression materials because of the advantages of giving sufficient time for recording borders and making an impression, moldability and ease of availability.

The surface sealant agents fill the micro fissures & micro defects that form after finishing & polishing & thus improve optical properties. The application of surface sealant agents onto the resin restoration fills surface defects, increases wear resistance and provides better stain resistance [12]. However, the use of Biscover LV surface sealant for polishing may require further study.

A plastic cylinder to secure the position of the iris has been demonstrated in past studies, but the strength of the plastic cylinder to withstand high compressive forces and high temperature during packing, flasking dewaxing and curing procedures was questionable [8]. The orthodontic wire embedded superiorly, medially, and laterally in the wax pattern is a new strategy used in this case to secure the shell firmly in the flask during laboratory processing.

4. CONCLUSION

A prosthetic eye goes a long way in completing psychological rehabilitation in situations where loss of vision is permanent. The use of custom-made ocular prostheses has proven to be an economical alternative for patients who cannot afford the expensive treatment options available. The procedure used here is economical, affordable, and can be carried out in a small clinical set-up. The technique used for securing the eye shell during processing ensures proper orientation of the eye shell within the prosthesis. The modified functional impression technique in this case recorded the depth and eye movements which allowed the artificial eye to move in unison with the patient's natural eye without being dislodged. The surface sealant application had a significant effect on surface roughness and gave a glossy layer to the prosthesis.

CONSENT AND ETHICAL APPROVAL

As per international standard or university standard guideline patient's consent and ethical approval has been collected and preserved by the authors.

REFERENCES

1. Raflo GT. Enucleation and evisceration. In: Tasman W, Jager E, editors: Duane's Clinical Ophthalmology. Vol. 5, 2 [sup]nd ed. Philadelphia, PA. Lippincott Williams and Wilkins; 1995:125.
2. Patil SB, Meshramkar R, Naveen BH, Patil N P: Ocular prosthesis: A brief review and fabrication of an ocular prosthesis for a geriatric patient. Gerodontology. 2008, 25:57-62.
3. Taicher S, Steinberg HM, Tubiana I, Sela M: Modified stock-eye ocular prosthesis . J Prosthet Dent. 1985, 54:95-8.
4. Guttal SS, Joshi SM, Pillai LK, Nadiger RK: Gerodontology. Ocular prosthesis for a geriatric patient with customised iris: A report of two cases. Gerodontology. 2011, 28:152-6. 5. Schneider RL: Modified ocular prosthesis impression technique . J Prosthet Dent. 1986, 55:482-5.
6. Artopoulou I, Montgomery CP, Wesley IP, Lemon CJ: Digital imaging in the fabrication of ocular prostheses. J Prosthet Dent. 2006, 95:227-30.
7. Bartlett SO, Moore DJ: Ocular prosthesis: A physiologic system . J Prosthet Dent. 1973, 29:450-9.
8. Ponnanna A.A., Gaurav Tripathi: Art and Science behind Esthetic Ocular Prosthesis: A Case Report . Int J Dent Case. 2012, 2:103-109.
9. Cain JR. Custom Ocular Prosthesis: J Prosthet Dent. 1982;48, 690-4.
10. Grisius MM, Robert L. 1993: Treatment of Lagophthalmos of the Eye with a Custom Prosthesis . J Prosthet Dent. 1993, 70:333-5.
11. Silva Santana SV, Bombana AC, Flório FM, Basting RT: Effect of surface sealants on marginal microleakage in class V resin composite restorations. J Esthet Restor Dent. 2009, 21:397-404.