

Original Research Article

Sensitivity and Specificity of Magnetic Resonance Spectroscopy (MRS) in the Diagnosis of Meningiomas

ABSTRACT

Background: Meningiomas are the most common extra axial tumors of brain accounting 13-26% of primary intracranial neoplasm. They are the most common non glial tumor of central nervous system (CNS). Meningiomas arise from the arachnoid cells called meningothelial cell and appear as extra axial, sharply demarcated, solid mushroom imaging pattern with dense homogenous contrast enhancement on CT and MRI. **Objective:** To determine the sensitivity and specificity of Magnetic Resonance Spectroscopy (MRS) in the Diagnosis of Meningiomas. **Methods and Materials:** This cross-sectional study was conducted on 45 patients with suspected meningioma who were referred to the Radiology and Imaging Department of Bangabandhu Sheikh Mujib Medical University (BSMMU) from the Department of Neurology and Neurosurgery during period from October 2019 to September 2021. Magnetic Resonance Spectroscopy (MRS) findings were evaluated taking into account the histopathology as a gold standard. Statistical analyses were carried out by using SPSS version 23.0. The quantitative observations were indicated by frequencies. Receiver operating characteristic (ROC) curve was generated to determine the cutoff value for the best sensitivity, specificity, negative and positive predictive values of choline /N-acetyl aspartate ratio with regard to diagnosis and characterization of meningiomas. **Results:** In MRS out of 45 patients 36(80%) patients were diagnosed as meningioma among them 30(67%) patients had increased alanine, 38(84%) patients had increased choline, 22(49%) patients NAA had not detected, 20(44%) patients NAA were minimally detected. Remaining 9(20%) patients had non-meningioma. In histopathology out of 45 patients 38(84%) patients had meningioma and 7(16%) patients had non meningioma. Histopathology showed 27(71%) patients was grade I, 3(8%) was grade II and 8(21%) was grade III. Increased lactate was detected in 11 patients, out of which 9(82%) patients were found high grade and 2(18%) patients were low grade meningiomas. The validity of meningioma by MRS was represented by calculating sensitivity, specificity, accuracy, positive and negative predictive values taking into account histopathology as gold standard. Sensitivity was 89.47%, specificity was 71.43%, accuracy was 86.67%, PPV was 94.44% and NPV was 55.56%. Based on the receiver-operator characteristic (ROC) curve choline/N-acetyl aspartate ratio had area under curve 0.850. Receiver-operator characteristic (ROC) was constructed by using choline /N-acetyl aspartate ratio, which gave a cut off value ≥ 2.99 , with 80.0% sensitivity and 62.5% specificity for prediction of high grade. **Conclusion:** The study suggested that MRS findings were consistent with low specificity in the diagnosis of meningiomas but MRS can characterize the types of meningiomas keeping histopathology as a gold standard. Increased alanine, decreased or absent NAA, increased choline, decreased creatine could be the spectroscopic parameters for the diagnosis of meningiomas and by using choline/N-acetyl aspartate ratio more sensitivity was found to predicted high grade along with lactate peak.

Keywords: MRI, MRS, Histopathology, Choline/creatine ratio, Choline /N-acetyl aspartate ratio.

INTRODUCTION

Meningiomas are the most common extra axial tumors of brain accounting 13-26% of primary intracranial neoplasm [1]. They are the most common non glial tumor of central nervous system (CNS) [2]. Meningiomas arise from the arachnoid cells called meningothelial cell [3] and appear as extra axial, sharply demarcated, solid mushroom imaging pattern with dense homogenous contrast enhancement on CT and MRI. Meningiomas are solid, well-circumscribed, highly cellular, slow growing tumours that are usually benign histologically (WHO grade I). Most commonly they project inward from the dura matter, indenting and compressing the underlying brain causing neurological signs and symptoms through compression of adjacent cortex [4]. However, approximately 10-15% of meningioma follow an atypical pattern with rim like enhancement, prominent cyst formation, intra tumoral hemorrhage, or even metaplasia [3]. They mainly occur in middle and old age, with peak incidence in fifth to seventh decades of life, however can be found in all age groups. Meningiomas exhibit a strong sex predilection, occurring predominantly in females, with a male to female ratio of 1:2. Meningiomas associated with hereditary tumour syndromes such as NF2 generally occur in younger patients and do not demonstrate a gender predilection [4]. Magnetic Resonance Imaging has largely replaced CT for delineating the location and soft tissue imaging characteristics of meningiomas [5]. Regarding signal intensities, meningiomas show isointense or

hypo intense signals on T1W1 images, isointense to hyper intense signals on T2W1 images [6]. A minority of meningiomas appear heterogenous in signal intensity on both T1 and T2 weighted images because of the presence of intratumoral lipoblastic or cystic changes, calcifications, or prominent vessels. Meningioma usually demonstrate rapid and pronounced contrast enhancement after IV administration of paramagnetic contrast agent, and the strong (often striking) homogenous contrast enhancement seen in most meningiomas enable their accurate detection and localization. A thickened tapered extension of contrast enhancing dura is commonly identified at the margin of the tumor may indicate the presence of tumor infiltration or may be reactive dural proliferation [4]. MRS is a noninvasive technique of showing the biochemical content of living tissues, which gives information about metabolism of tumors which can be useful in diagnosis [7]. MR spectroscopy has the ability to evaluate the concentration of metabolites within a given ROI (region of interest). Rather than detecting the resonance signal of protons (predominantly water) resonance signal of the protons from the different molecular groups within the lesion of interest, such as N-acetylaspartate (NAA), Choline(Cho), Creatine(Cr), Glutamin/glutamate(Glx), Alanine(Ala), and Lactate, can be detected [8]. In MRI collected data are analyzed in the time domain (signal intensity vs. time) to obtain relaxation time (TR) information of the nuclei, namely T1 and into T2. The data from the time domain information is used to generate an anatomical image. In MRS, the time domain information is converted to frequency domain (signal intensity vs. frequency) and used to form a distribution of the intensities of the chemical groups associated with their various metabolites versus their Larmor resonance frequencies to give spectral profile of the metabolites within the regions of anatomical images [4]. Addition of Magnetic Resonance Spectroscopy (MRS) in preoperative imaging is even more beneficial in making a plan for accurate extent of resection. MRS is considered to be useful for the diagnosis of meningioma whose radiological appearance is atypical and it may also play role in the evaluation of malignant potential [9]. Prominent Alanine (Ala) is seen in meningioma, much more than others neoplastic processes and is considered a spectroscopic signature for meningioma [8]. Alanine is not always present in all meningioma and seen to be inversely correlate with necrosis within these tumors [10]. However, alanine is also observed in high grade gliomas or other brain tumors. Meningiomas have been shown to have elevated choline (Cho) and decreased N-acetylaspartate (NAA). There is also decreased in creatine (Cr) [11]. Lactate has also been shown in some studies to be more frequently observed in non-benign meningiomas, WHO grade II and III, but is not always a marker for aggressive meningiomas. Similarly, lipid (Lip, 0.9/1.3 ppm), whilst usually regarded as a marker of an aggressive meningioma, does not always represent micro necrosis and therefore cannot always be taken as proof of a non-benign meningioma [9], with lipid observed in microcystic and in fatty degeneration in lipomatous tumors. In a study Cho/NAA ratio, which is easily and widely obtained during MRS, may predict high grade meningioma when its value is >2.409 (sensitivity=61.54%; specificity=86.36%) [12]. H-MRS alone can reach up to 82.5% accuracy (58.7-82.1% CI), 100% sensitivity and 91.1% specificity on predicting tumor type [13]. At long TE (Time to Echo) sensitivity and specificity of MRS is 86% and 97% respectively [14]. Histological grading of meningiomas is based on current WHO classification. The majority of lesions are benign WHO grade I lesions, representing approximately 90% of cases. The histological subtypes of grade I meningiomas include meningothelial, psammomatous, secretory, fibroblastic, angiomatous, lymphoplasmacyte rich, transitional, metaplastic and microcytic. They differ from the more aggressive meningiomas, WHO grade II (atypical) and WHO grade III (anaplastic), 5-7% and 1-3% respectively, in their number of mitoses, cellularity, nuclear-to-cytoplasmic ratio, histological pattern, and their relatively low risk of recurrence or aggressive growth pattern [15]. The objective of this study is to determine the diagnostic accuracy, sensitivity, specificity, positive predictive value and negative predictive value of Magnetic Resonance Spectroscopy (MRS) in the diagnosis of meningioma keeping histopathological findings as a gold standard. [Split this paragraph into four parts](#)

Comment [APBS1]:

Comment [APBS2]:

OBJECTIVES

General objective:

To determine the sensitivity, specificity and accuracy of Magnetic Resonance Spectroscopy (MRS) in the diagnosis of meningiomas.

Specific objectives:

- To assess the meningiomas by Magnetic Resonance Spectroscopy (MRS).
- Comparison between Magnetic Resonance Spectroscopy (MRS) and histopathology.

MATERIAL AND METHODS

This was a cross-sectional diagnostic accuracy study was carried out in the Department of Radiology and Imaging, Bangabandhu Sheikh Mujib Medical University (BSMMU) during period from October 2019 to September 2021. A total of 45 patients with meningiomas of in-patient and out-patient department of neurology and neurosurgery of BSMMU, Dhaka for Magnetic Resonance Spectroscopy during the study period irrespective of any sex was enrolled for the study. Purposive sampling technique was followed for sample selection.

Inclusion criteria:

Patients with diagnosed case of meningioma on initial MRI

Exclusion criteria:

Patients having strong contraindication to MRI including those with cardiac pacemaker, prosthetic heart valves, cochlear implants, brain aneurysm clips or coils, already diagnosed, operated or on treatment.

Study procedure:

This cross-sectional study was conducted on 45 patients with diagnosed case of meningioma who was referred to the Radiology Department of BSMMU from the Department of Neurology and Neurosurgery. Permission from the Institutional Review Board was obtained prior to the study and informed consent of study subjects was taken before undergoing MRS and subsequent histopathology was done. Data capturing master sheet was maintained throughout. At enrollment patient's demographic and baseline characteristics was recorded. Magnetic Resonance Spectroscopy (MRS) findings was evaluated taking into account the histopathology as gold standard method.

Imaging technique:

Before performing MRI, proper counseling and reassurance to the patients regarding the procedure was done. Patient was asked to empty their bladder and lied on supine position. Head coil is used to improve image resolution. MRI was obtained on 1.5 T machine (Avanto, Siemens) using T1W (TR-195, TE-4.8), T2W (TR-3280, TE-96), FLAIR (TR-8000, TE- 93) and T1W post contrast. Field of view (FOV) 20-38cm, matrix size 380/75. To reduce the motion artifact's, the head of the patient was supported with soft supportive wedges and straps. For MRS global shimming (process of making the magnetic field homogenous) is done which provide the starting value of local shimming. Localization in MRS is done by slice selection and phase encoding gradients. Phase encoding is done in one, two, or three directions to get one-, two-, or three-dimensional spectroscopy respectively. Good local shim results into narrower metabolite peaks, better spatial resolution and good SNR (sound to noise ratio). The water peak is suppressed so that smaller metabolites peaks are visible by CHESS (chemical shift selective spectroscopy) technique. Then MRS data is obtained by CSI (Chemical shift imaging) which usually takes up to 12 minutes. At long TE (more than 135ms) major brain metabolites like choline, creatine, NAA and lactate are visible. Lipid, glutamate, glutamine, alanine, GABA and inositol peaks are suppressed at higher TEs because of their short T2. Shorter TEs (20-30ms) are used for them [16].

Statistical analysis:

Statistical analyses were carried out by using the SPSS version 23.0. A descriptive analysis was performed for all data. The mean values were calculated for continuous variables. The quantitative observations were indicated by frequencies. Fisher Exact test was used to analyze the categorical variables, shown with cross tabulation. For the validity of study outcome, sensitivity, specificity, accuracy, positive predictive value and negative predictive value of the MRS diagnosis evaluation for meningiomas was calculated. Receiver operating characteristic (ROC) curves was generated to determine the cutoff value for the best sensitivity, specificity negative and positive predictive values of choline /N-acetyl aspartate ratio with regard to diagnosis of meningiomas. A "p" value <0.05 was considered as statistically significant.

Ethical clearance:

The study was approved by the ethical committee of Institutional Review Board (Memo no: BSMMU/2020/9455) and department of Radiology and Imaging, BSMMU. The aims and objectives of the study along with its procedure, risks and benefits were explained to the respondents. Written consent was taken from the participants.

RESULTS

Table 1: Distribution of the study patients by demographic variables. (N=45)

Demographic variables	Frequency (n)	Percentage (%)
Age (years)		
36-40 yrs.	5	11
41-50 yrs.	16	36
51-60 yrs.	10	22
61-70 yrs.	11	24
71-75 yrs.	3	7
Mean± SD	52.7±10.4	
Range (min-max)	36.0-75.0	
Sex		
Male	8	18
Female	37	82

Table 1 shows that more than one third (36%) patients belonged to age 41-50 years. The mean age was found 52.7±10.4 years with range from 36 to 75 years. Majority (82%) patients were female. Male female ratio was 1:4.

Table 2: Distribution of the study patients by MRI findings. (N=45)

MRI findings	Frequency (n)	Percentage (%)
Position		
Supra tentorial	38	84
Infra tentorial	7	16
Location		
Frontal	10	22
Parasagittal	12	27
Temporal	4	9
Parietal	9	20
Intraventricular	2	4
Posterior fossa	7	15
Supra seller region	1	2
Number of the lesion		
One	40	89
Multiple	5	11
Shape of the lesion		
Rounded	33	73
Lobulated	12	27
T1 weighted images		
Isointense	22	49
Hypo intense	15	33
Heterogenous	8	18
T2 weighted images		
Isointense	4	9
Hyperintense	33	73
Heterogenous	8	18
FLAIR images		
Isointense	3	7

Comment [APBS3]: Make it center! The same to all Tables

Hyperintense	34	75
Heterogenous	8	18
Mass effect	37	82
Perilesional edema	20	44
Area of necrosis/cystic changes	17	38
Bony change	3	7
Characteristics of the lesion in post gadolinium study		
Homogenous enhancement	37	82
Heterogeneous enhancement	8	18

Table 2 showed in MRI findings, majority (84%) of lesions were found supra tentorial where 12(27%) were parasagittal in location. 40(89%) patient had single lesion and 33(73%) lesions were rounded in shape. 22(49%) lesions were isointense, 33(73%) hyperintense and 34(75%) hyperintense on T1 weighted, T2 weighted and FLAIR images respectively. 37(82%) lesions had mass effect, 20(44%) had perilesional edema, 17(38%) had necrosis/cystic changes and 3(7%) had features of bony changes. On post contrast with gadolinium all patients were found enhancement where more than three fourth 37(82%) had homogenous enhancement.

Table 3: Distribution of the study patients by MRS variables. (N=45)

MRS variables	Frequency (n)	Percentage (%)
Choline (Cho)		
Increased	38	84
Minimally detected	5	11
Not detected	2	5
Creatine (Cr)		
Decreased	2	5
Significantly decreased	38	84
Completely absent	5	11
N-acetyl aspartate (NAA)		
Not detected	22	49
Minimally detected	20	44
Detected	3	7
Alanine		
Increased	30	67
Detected	6	13
Not detected	9	20
Lipid		
Present	11	24
Absent	34	76
Lactate		
Increased	14	31
Minimally detected	22	49
Not detected	9	20

Myoinisitol		
Detected	10	22
Not detected	35	78
Choline/Creatine ratio	4.51±2.70	
Choline /N-acetyl aspartate ratio	3.76±3.18	

Table 3 showed in MRS, 38(84%) patients had increased choline and 38(84%) patients creatine were significantly decreased. NAA was not found in 22(49%) patients with minimally detected NAA was seen in 20 (44%) patients. 30(67%) patients had increased alanine. Lipid was present in 11(24%) patients. Increased lactate was found in 11(31%) study and 22(49%) patients had minimally detected lactate. In case of 10(22%) patients myoinisitol was detected. Mean choline/creatine ratio was 4.51±2.70 and choline /N-acetyl aspartate ratio was 3.76±3.18.

Table 4: Distribution of the study patients by MRS parameters in histopathologically proven meningioma (n=38)

MRS variables	Frequency (n)	Percentage (%)
Choline (Cho)		
Increased	34	89
Minimally detected	4	11
Creatine (Cr)		
Decreased	2	5
Significantly decreased	36	95
N-acetyl aspartate (NAA)		
Not detected	20	53
Minimally detected	18	47
Alanine		
Increased	28	74
Detected	6	16
Not detected	4	10
Lipid		
Present	6	16
Absent	32	84
Lactate		
Increased	11	29
Minimally detected	20	53
Not detected	7	18
Choline/creatine ratio	4.68±2.89	
Choline /N-acetyl aspartate ratio	4.66±3.34	

Table 4 showed in histopathologically proven meningioma, majority 34(89%) of the patients were found increased choline and 36(95%) had significantly decreased creatine, 20(53%) patients NAA had not detected and 28(74%) had increased alanine. Lipid was present in 6(16%) patients and 20(53%) had minimally detected level of lactate. Mean choline/creatine ratio was 4.68±2.89 and choline/N-acetyl aspartate ratio was 4.66±3.34.

Table 5: Distribution of the study patients according to MRS diagnosis. (N=45)

MRS diagnosis	Frequency (n)	Percentage (%)
Meningioma	36	80
Non- meningioma*	9	20

*lymphoma, Schwannoma, Hemangiopericytoma

Table 5 showed in MRS out of 45 patients, 36(80%) patients had meningioma and 9(20%) had non meningioma.

Table 6: Distribution of the study patients according to histopathological diagnosis. (N=45)

Histopathological diagnosis	Frequency (n)	Percentage (%)
Meningioma	38	84
High grade	11	24
Low grade	27	60
Non- meningioma*	7	16

*lymphoma (3), Schwannoma (2), Hemangiopericytoma (2)

Table 6 showed in histopathology, out of 45 patients, 38(84%) patients had meningioma and 7(16%) had non meningioma. 11(24%) patients were found as high grade and 27(60%) were low grade meningioma.

Table 7: Grading of the study patients based on histopathologically proven meningiomas. (n=38)

Histopathological findings	Frequency (n)	Percentage (%)
Grade		
I	27	71
Meningothelial	16	59
Transitional	05	19
Angiomatous	04	15
Fibroblastic	02	7
II	3	8
Clear cell	02	67
Atypical	01	33
III	8	21
Anaplastic	8	100

Table 7 showed that 27(71%) patients were found grade I, 3(8%) grade II and 8(21%) grade III meningioma.

Table 8: Grading of histopathologically proven meningioma based on increased lactate. (n=11)

Histopathological grade	Frequency (n)	Percentage (%)
High grade*	9	82
Low grade **	2	18

*High grade -Anaplastic (7), clear cell (2)

**Low grade- Meningothelial (2)

Table 8 showed that lactate peak was found in 11 patients in histopathologically proven meningiomas where 9(82%) patients had high grade and 2(18%) patients had low grade meningioma.

Table 9: Comparison between histopathological and MRS diagnosis of meningiomas. (N=45)

MRS	Histopathology	
	Positive (n=38)	Negative (n=7)
Positive (n=36)	34 (True positive)	2 (False positive)
Negative (n=9)	4 (False negative)	5 (True negative)

P= 0.003

P value reached from McNemar’s Chi-Square Test.

Table 9 showed out of all cases, 34 were diagnosed as meningiomas by MRS and confirmed by histopathological evaluation. They were true positive. Two cases were diagnosed as meningiomas by MRS but not confirmed by histopathological findings. They were false positive. Of 9 cases of non-meningioma, which were diagnosed by MRS, 4 were Mconfirmed as meningioma and 5 were non meningioma by histopathology. They were false negative and true negative respectively.

Table 10: Sensitivity, specificity, accuracy, positive and negative predictive values of MRS for evaluation of meningiomas. (N=45)

Validity test	Calculation	Result
Sensitivity	$\frac{34}{34+5} \times 100$	89.47%
Specificity	$\frac{4}{4+2} \times 100$	71.43%
Accuracy	$\frac{34+4}{34+5+4+2} \times 100$	86.67%
Positive predictive value	$\frac{34}{34+2} \times 100$	94.44%
Negative predictive value	$\frac{5}{5+4} \times 100$	55.56%

Table 10 showed the validity of meningioma by MRS was represented by calculating sensitivity, specificity, accuracy, positive and negative predictive values taken into account histopathology as a gold standard. Sensitivity was 89.47%, specificity was 71.43%, accuracy was 86.67%, PPV was 94.44% and NPV was 55.56%.

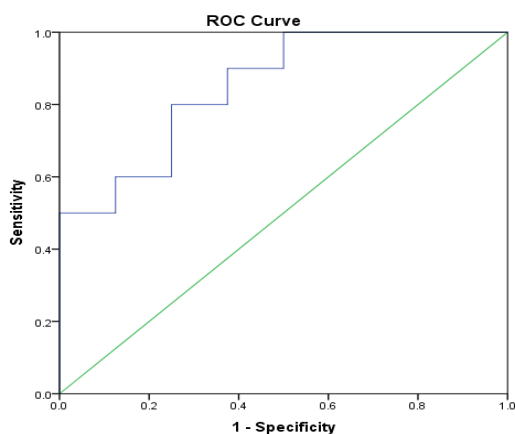
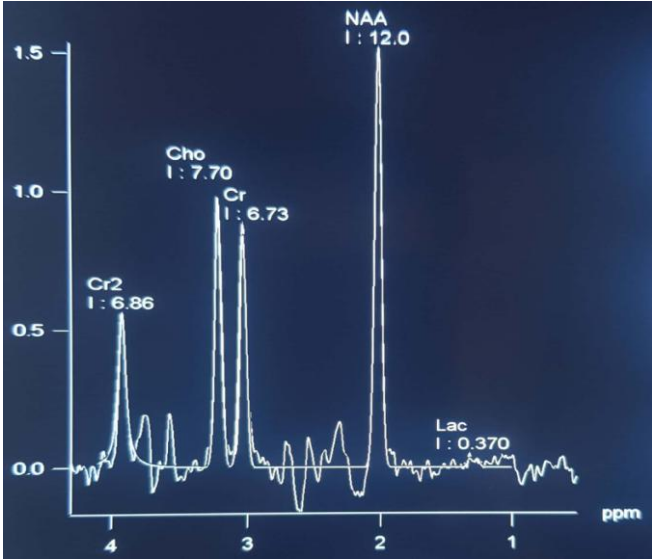
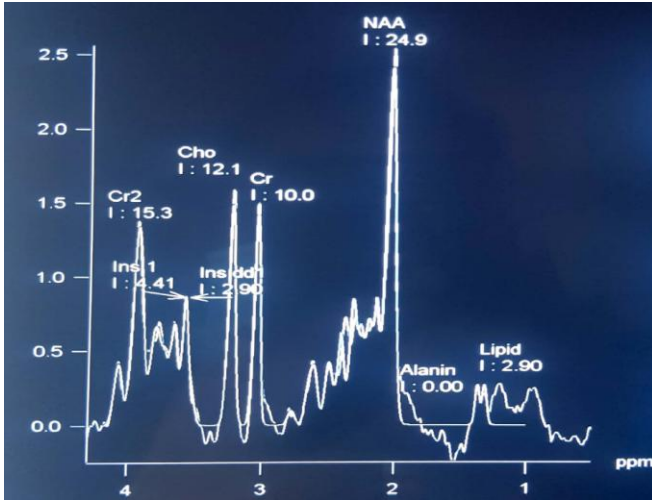


Figure 1: Receiver-operator characteristic (ROC) curve of choline /N-acetyl aspartate ratio for prediction of high grade.

The area under the receiver-operator characteristic (ROC) curves for prediction of high grade. Based on the receiver-operator characteristic (ROC) curves choline /N-acetyl aspartate ratio had area under curve 0.850. Receiver-operator characteristic (ROC) was constructed by using choline /N-acetyl aspartate ratio, which gave a cut off value ≥ 2.99 , with 80.0% sensitivity and 62.5% specificity for prediction of high grade. Positive likelihood ratio was 2.1 and negative likelihood ratio was 1.2.



A



B

Diagram 1: Normal brain spectra at (A) Long echo TE=135 ms and (B) short TE=30 ms

Comment [APBS4]: Instead of Diagram, it will be best if you use Figure

DISCUSSION

In this study observed that more than one third (35.56%) patients belonged to age 41-50 years. The mean age was found 52.7 ± 10.4 years with range from 36 to 75 years. Majority (82.22%) patients were female. Matsusue et al. (2021) [17] reported the mean age was 56 ± 17 years in meningiomas and 62 ± 16 years in non meningiomas. Jaskólski et al. (2013) [18] reported meningiomas were found in 14 patients: 2 males and 12 females who were 22 to 70 years old (mean age, 53 years). Lin et al. (2018) [12] also found 54.3% were female and 45.7% were male. Liu et al. (2021) [19] reported that the proportion of patients between 51 and 60 years old was the most (31.34%), followed by patients between 61 and 70 years old, accounting for 26.86%. Proportion of patients between 20 and 30 years old were the least, which was 5.97%. Buhl et al. (2010) [20] observed that the mean age was 58 years (37-81 years). Ten patients were male and 29 were female. All of which all are comparable with the current study. In MRI finding, it was found that majority (84.44%) of the lesions were supra tentorial. The location was mainly in cerebral convexity 19(42.22%) and parasagittal 12(26.67%). More than one third of the lesions 40(88.89%) were single and 33(73.33%) rounded in shape. On signal intensity 22(48.89%) lesion was isointense on T1 weighted images, 33(73.33%) hyperintense on T2 weighted images and 34(75.56%) lesions found hyperintense on FLAIR images. Mass effect, perilesional edema, necrotic/cystic changes and bony changes were present in 37(82.22%), 20(44.44%), 17(37.78%), 3(6.67%) cases respectively. More than three fourth cases 37(82.22%) found with homogenous contrast enhancement. Stefano Vic et al. (2011) [6] mentioned that the tumor was localized in the cerebral convexity in 43.33% patients, parasagittal region in 16.66% patients, parafalcine in 6.66% patients. With regard to signal intensities, intra cranial meningiomas are isointense to hypo intense on T1W1 images and isointense to hyper intense in T2W1 images. In MRS findings, out of 45 patient's majority (84%) of the patients had increased choline with significantly decreased creatine in 38(84%) patients. In case of 22(49%) patients NAA was not detected. Increased alanine was present in about three fourth 30(67%) cases and lipid was found in 11(24%) cases. Increased lactate was present in 14(31%) patients. Mean choline/creatine ratio was 4.51 ± 2.70 . Demir et al (2006) [21] stated that Prominent choline was found in all meningiomas, alanine was present in 21 cases of the 23, NAA (Acetyl aspartate) and creatine (Cr) were either not observed or detected in minimal amounts in both groups of meningiomas on long TE (144ms) spectra. They also demonstrated that Ala is seen in meningiomas, much more than other neoplastic processes and is considered a spectroscopic signature for meningiomas. Jaskólski, et al 2013[18] demonstrated that all the patients with meningiomas had a high Cho signal at long TE. There were very low signals of NAA and Cr in the spectra of 10 patients. Twelve spectra showed high Cho signals at short TE. In one case the Cho signal was extremely low. All spectra displayed a very low Cr signal, but high Glx and Lac-Lip signals. The mean Cho/Cr ratio was $5.97(1.12)$ in normal brain, $p < 0.05$. Lac-Lip was present in all the meningiomas. The Ala signal was seen only in 2 spectra with long TE and in 3 sequences of the short TE. These above findings are comparable with current study. In histopathologically proven 38 meningiomas present study showed that, majority 34(89.47%) of the patients had increased choline with significantly decreased creatine metabolite in 36(94.74%) patients. NAA was not detected in 20(52.63%) patients but observed minimally in rest of the cases 18(47.37%). Mean choline/creatine ratio was 4.68 ± 2.89 and mean Choline /N-acetyl aspartate ratio was 4.66 ± 3.34 . Domingo et al. (1998) [22] found high choline (Cho), low creatine (Cr) and low NAA in eight patients with meningiomas. Demir et al. (2006) [21] reported the Cho/Cr ratio was 4.44 ± 0.30 (mean \pm standard deviation) in four atypical meningiomas and 3.39 ± 0.52 in 12 typical group. Lin et al. (2018) also observed the Cho/NAA ratio in cases of high-grade meningioma was significantly higher than in cases of low grade meningioma (6.34 ± 7.90 vs. 1.58 ± 0.77 , $p < 0.05$). On the basis of histopathologically in our study 38(84.44%) patients had meningioma and 7(15.56%) had non meningioma. Out of 38 meningiomas we found 11(24.44%) as high grade (grade II and grade III) and 27(60.0%) low grade (grade I). Lin et al. (2018) [12] reported in his study that 62.9% were low grade and 37.1% were high grade. Matsusue et al. (2021) [17] reported 7(77.8%) patients were found in grade I and 2(22.2%) in grade II in their study. Demir et al. (2006) [21] reported in his study 6 (26%) patients out of 23 cases as atypical (WHO grade II), and the others as typical (WHO grade I) based on histopathological examination. Considering lactate peak, 9(81.82%) patients was found as high grade and 2(18.18%) patients as low grade. Buhl et al. (2007) [20] demonstrated that in five out of eight (62.5%) patients based on histology as atypical meningiomas (WHO Grade II), pre-operatively there was a lactate peak as a sign of higher proliferation and growth rate. In the other meningiomas WHO Grade I, there were only two patients with a lactate peak. In our study showed that the validity of meningioma by MRS was represented by calculating sensitivity, specificity, accuracy, positive and negative predictive values taken into account histopathology as gold standard. Sensitivity was 89.47%, specificity was 71.43%, accuracy was 86.67%, PPV was 94.44% and NPV was 55.56%. Majós, et al. (2004) [14] Meningiomas was the group in which sensitivity and specificity of diagnosis was better at long TE (sensitivity, 32 [86%] of 37 cases; specificity, 111 [97%] of 114 cases) than at short TE (sensitivity, 31 [84%]

of 37 cases; specificity, 108 [95%] of 114 cases). Receiver-operator characteristic (ROC) was constructed by using choline /N-acetyl aspartate (Cho/NAA) ratio, which gave a cut off value ≥ 2.99 , with 80.0% sensitivity and 62.5% specificity for prediction of high grade. Lin et al. (2018) [12] stated that according to conditional inference tree analysis, the optimal cutoff point for the Cho/NAA ratio between high-grade and low-grade meningioma was 2.409 (sensitivity=61.54%; specificity=86.36%). Liu et al. (2021) [19] reported that the ROC analysis of NAA/Cr ratio achieves a sensitivity of 85.7% and specificity of 46.7%. The finding of Cho/NAA ratio in this study shows a high sensitivity of 83.3% illustrating a high positive rate and a low negative rate. All of which are comparable to our study.

CONCLUSION

This study was undertaken to establish the diagnostic usefulness of MRS in evaluation of intracranial meningiomas and characterize them into benign, atypical and malignant meningiomas. Intracranial meningiomas were common in 4th decade and predominant in female subjects. In evaluation of intracranial meningiomas by MRS keeping histopathology as a gold standard was significantly associated because the test of validity was high. However, only MRS cannot be used as a reliable tool for the diagnosis of meningiomas as its specificity was low in this study (71.43%).

Comment [APBS5]: Split this paragraph into several parts

LIMITATIONS AND RECOMMENDATION

In this study interobserver variability was not assessed. In diagnostic evaluation of meningiomas by MRS, this study didn't show high specificity so further study can be carried out by adding glutamine-glutamate index and leucine as MRS variables.

REFERENCES

1. Kleihues, P. and Cavenee, W.K., 2000. Pathology and genetics of tumors of the nervous system. *IARC*
2. Toh, C.H., Castillo, M., Wong, A.C., Wei, K.C., Wong, H.F., Ng, S.H. and Wan, Y.L., 2008. Differentiation between classic and atypical meningiomas with use of diffusion tensor imaging. *American journal of neuroradiology*, 29(9), pp.1630-1635.
3. Buetow, M.P., Buetow, P.C. and Smirniotopoulos, J.G., 1991. Typical, atypical, and misleading features in meningioma. *Radiographics*, 11(6), pp.1087-1106.
4. Haaga, J.R. and Boll, D.T., 2017. CT and MRI of the whole body. 6th edition, Elsevier; pp.212-526.
5. D'Ambrosio, A.L. and Bruce, J.N., 2003. Treatment of meningioma: an update. *Current neurology and neuroscience reports*, 3(3), pp.206-214.
6. Stefanovic, J., Stojanov, D., Bosnjakovic, P. and Stojanov, N.I., 2011. Magnetic resonance presentation of intracranial meningiomas. *Global Journal of Medical Research*, 4, pp.33-8.
7. Majos, C., Alonso, J., Aguilera, C., Serrallonga, M., Coll, S., Acebes, J.J., Arus, C. and Gili, J., 2003. Utility of proton MR spectroscopy in the diagnosis of radiologically atypical intracranial meningiomas. *Neuroradiology*, 45(3), pp.129-136.
8. Tamrazi, B., Shiroishi, M.S. and Liu, C.S.J., 2016. Advanced imaging of intracranial meningiomas. *Neurosurgery clinics of North America*, 27(2), pp.137-43.
9. Yue, Q., Isobe, T., Shibata, Y., Anno, I., Kawamura, H., Yamamoto, Y., Takano, S. and Matsumura, A., 2008. New observations concerning the interpretation of magnetic resonance spectroscopy of meningioma. *European radiology*, 18(12), pp.2901-2911.
10. Castillo, M. and Kwock, L., 1999. Clinical applications of proton magnetic resonance spectroscopy in the evaluation of common intracranial tumors. *Topics in Magnetic Resonance Imaging*, 10(2), pp.104-113.
11. Kinoshita, Y., Kajiwara, H., Yokota, A. and Koga, Y., 1994. Proton magnetic resonance spectroscopy of brain tumors: an in vitro study. *Neurosurgery*, 35(4), pp.606-614.
12. Lin, M.C., Li, C.Z., Hsieh, C.C., Hong, K.T., Lin, B.J., Lin, C., Tsai, W.C., Lee, C.H., Lee, M.G., Chung, T.T. and Tang, C.T., 2018. Preoperative grading of intracranial meningioma by magnetic resonance spectroscopy (1H-MRS). *Plos one*, 13(11), p. e0207612.

13. Server, A., Josefsen, R., Kulle, B., Mæhlen, J., Schellhorn, T., Gadmar, Ø., Kumar, T., Haakonsen, M., Langberg, C.W. and Nakstad, P.H., 2010. Proton magnetic resonance spectroscopy in the distinction of high-grade cerebral gliomas from single metastatic brain tumors. *Acta Radiologica*, 51(3), pp.316-325.
14. Majos, C., Julià-Sapé, M., Alonso, J., Serrallonga, M., Aguilera, C., Acebes, J.J., Arús, C. and Gili, J., 2004. Brain tumor classification by proton MR spectroscopy: comparison of diagnostic accuracy at short and long TE. *American Journal of Neuroradiology*, 25(10), pp.1696-1704.
15. Watts, J., Box, G., Galvin, A., Brotchie, P., Trost, N. and Sutherland, T., 2014. Magnetic resonance imaging of meningiomas: a pictorial review. *Insights into imaging*, 5(1), pp.113-122.
16. Chavhan, G.B., 2013. MRI made easy (for beginners). 2nd edition, Jaypee Brothers Medical Publishers, India; pp.158-171.
17. Matsusue, E., Inoue, C., Tabuchi, S., Yoshioka, H., Nagao, Y., Matsumoto, K., Nakamura, K. and Fujii, S., 2021. Utility of 3T single-voxel proton MR spectroscopy for differentiating intracranial meningiomas from intracranial enhanced mass lesions. *Acta Radiologica Open*, 10(4), pp.1-10.
18. Jaskólski, D.J., Fortuniak, J., Stefańczyk, L., Majos, A., Gajewicz, W., Papierz, W., Liberski, P.P. and Sikorska, B., 2013. Differential diagnosis of intracranial meningiomas based on magnetic resonance spectroscopy. *Neurologia i neurochirurgia polska*, 47(3), pp.247-255.
19. Liu, J., Chen, J., Zha, Y., Huang, Y. and Zeng, F., 2021. Magnetic Resonance Imaging (MRI) Differential Diagnosis of Meningiomas Using ANOVA. *Contrast Media & Molecular Imaging*, 2021, pp.1-8.
20. Buhl, R., Nabavi, A., Wolff, S., Hugo, H.H., Alfke, K., Jansen, O. and Mehdorn, H.M., 2007. MR spectroscopy in patients with intracranial meningiomas. *Neurological research*, 29(1), pp.43-46.
21. Demir, M.K., Iplikcioglu, A.C., Dincer, A., Arslan, M. and Sav, A., 2006. Single voxel proton MR spectroscopy findings of typical and atypical intracranial meningiomas. *European journal of radiology*, 60(1), pp.48-55.
22. Domingo, Z., Rowe, G., Blamire, A.M. and Cadoux-Hudson, T.A.D., 1998. Role of ischaemia in the genesis of oedema surrounding meningiomas assessed using magnetic resonance imaging and spectroscopy. *British journal of neurosurgery*, 12(5), pp.414-418.