

Curious Case Of An Anterior Neck Swelling.

ABSTRACT :

A Thyroglossal cyst is amongst the most commonly encountered anterior painless neck swelling. Its usual presentation is seen in childhood and rarely it can present in adulthood. The management for Thyroglossal cyst is, the Sistrunk's Operation. The etiology is explained by embryonic development of the Thyroglossal duct and its deficiency to obliterate after birth. Here we present a case of a 45 year old gentleman who presented with a painless midline neck swelling since 6 years. Onset of the swelling was insidious and gradually increased in size over the years. Patient did not give any history suggestive of an infection or thyroid gland dysfunction. USG of the neck revealed a fluid filled cystic lesion below the hyoid bone. MRI of the Neck revealed a 3.5 x 3 x 3.5 cm well-defined lesion in the anterior neck suggesting a Thyroglossal Cyst. Patient was worked up for a sistrunk's procedure. Histopathology revealed a well-differentiated Papillary Thyroid Carcinoma. Thyroglossal duct Cyst in adulthood is a rare entity as most of the case usually presented at childhood. Presence of a Thyroglossal Cyst in an adult should prompt the caregiver to evaluate for a malignant change. Sistrunk's procedure remains the standard treatment of choice for all the age groups. Infection of the cyst remains the most common complication of Thyroglossal cyst.

KEYWORDS - Thyroglossal Cyst, Thyroglossal Duct, Sistrunk's Procedure, Papillary Thyroid Carcinoma, Malignancy.

INTRODUCTION

Thyroglossal duct cyst (TDC) is one of the most common midline swellings of the neck which arises from a unobliterated thyroglossal duct which is present in the embryonic period⁽³⁾. It represents the embryonic pathway of descent of the thyroid gland. As it is a congenital disease it presents most commonly in the childhood period and seldom presents in adulthood. Hence, most of the data available on this subject have a focus on management of this condition in the childhood period.

Sistrunk's Procedure is the procedure of choice for this disease and is accepted globally as the standard of care⁽⁴⁾. The operation includes the excision of the cyst with excision of the central part of the hyoid bone and coring of the tract till the foramen cecum. This is driven by the knowledge of the embryonic development of the Thyroglossal duct and its intimate relation with the Hyoid bone.

Data available reveals a satisfactory cure rates with Sistrunk's Operation for Thyroglossal cyst occurring in childhood and very few cases are reported in adult age group and hence less data is available for comparison⁽⁶⁾.

CASE REPORT

Here we present a case of a 45 year old gentleman with no comorbidities, who presented with a painless midline neck swelling since 6 years, the swelling was first noticed by the patient 6 years ago when it was the size of a pea gradually it progressed to the current size of a lemon. Patient did not give any history of Fever, Pus discharge from swelling. No history suggestive of thyroid dysfunction or difficulty in swelling/breathing/change of voice. Examination revealed a 4 cm x 4 cm midline neck swelling, moving with deglutition and protrusion of tongue, smooth surface with rounded edges, no tenderness or

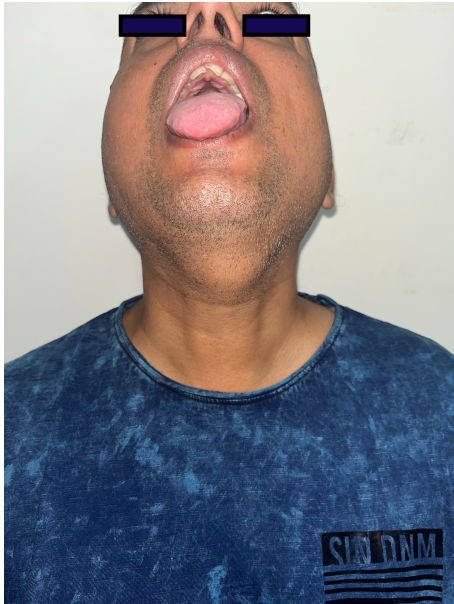

Fig 1. Movement with tongue protrusion.

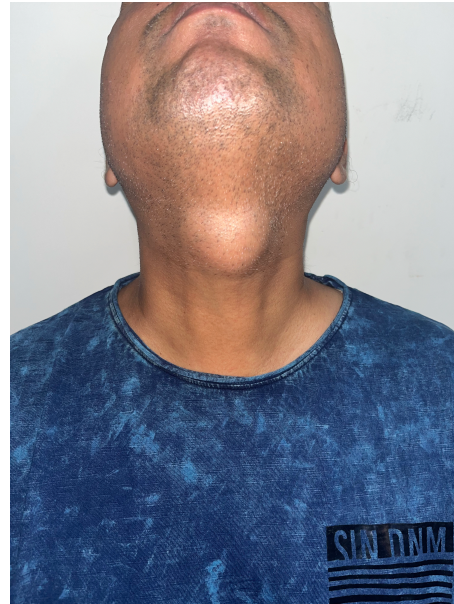

Fig 2. Midline neck swelling

rise of local temperature. Thyroid gland not palpable. No cervical lymph nodes palpated.

CECT of Neck revealed a well-defined peripherally enhancing cystic

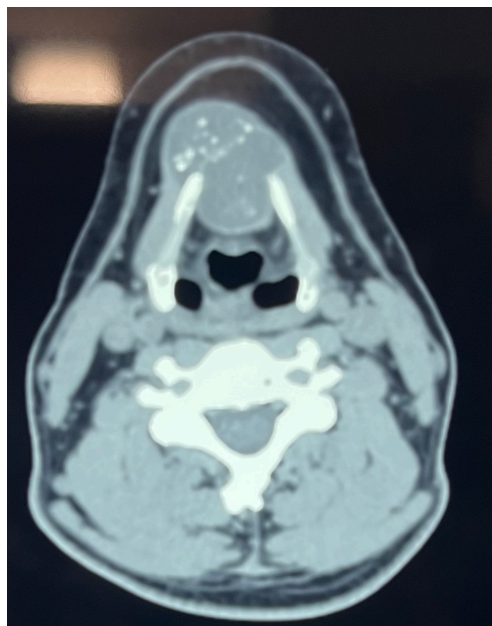


Fig 5. Image Showing calcifications.

structure in midline upper neck infra hyoid in location measuring 3.6 cm x 2.9 cm x 3.5 cm with foci of calcification.

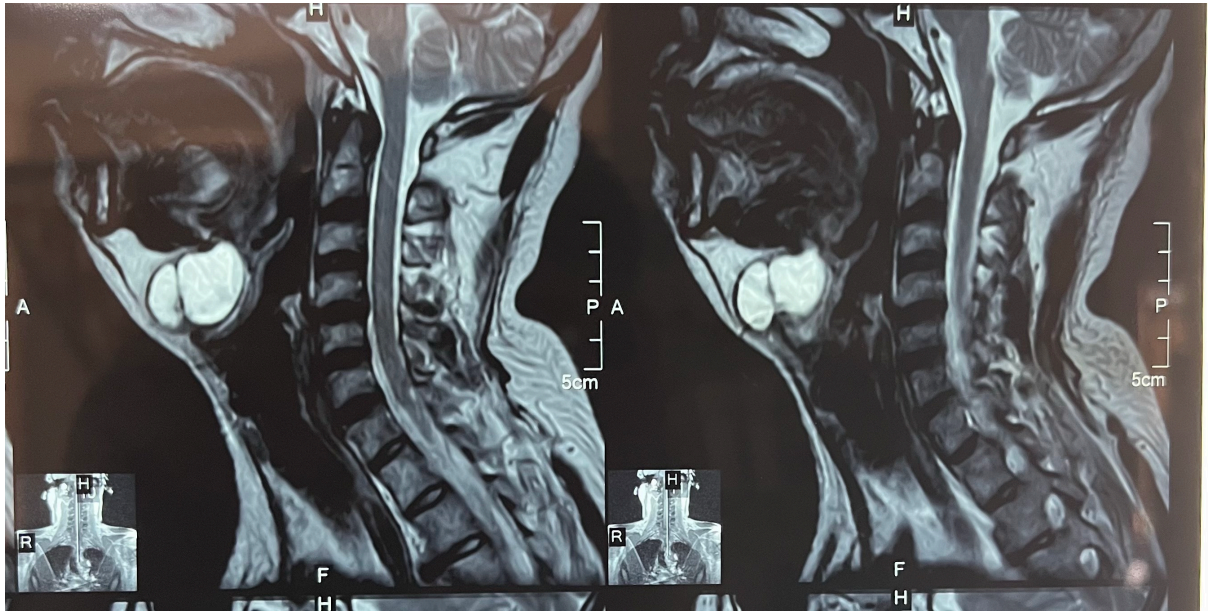


Fig 3. MRI Neck in sagittal view.

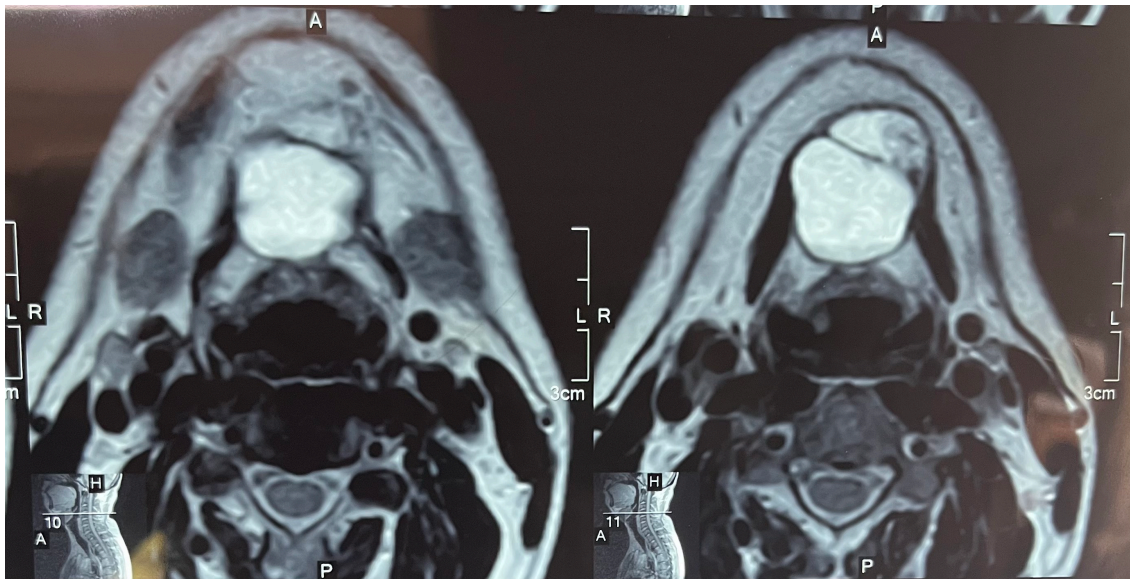


Fig 4. Antero-posterior view showing close relation the hyoid bone.

MRI Neck revealed well defined T1 hyper intense swelling in the infra hyoid region with multiple blooming spots suggestive of thyroglossal cyst with calcifications. **The thyroid gland was normal with no detectable cervical lymph nodes.**

Patient was posted for Sistrunk's procedure. Patient, under general anaesthesia, was taken in the supine position with neck extended and head supported with the help of a ring. A transverse incision was taken over the swelling and deepened till the investing layer of deep cervical fascia. Strap muscles were retracted laterally and swelling was freed from all adhesions. Hyoid bone was located superiorly to the swelling, off which, the muscle attachments from the central part were released. The hyoid bone was cut in the central part. The tract was then seen extending superiorly into floor of the mouth and cored upto the mylohyoid muscle. Wound was closed in layers after achieving homeostasis over a closed vacuum drain. Patient tolerated the procedure well and the specimen was sent for a Histopathological Exam. Post operative period was uneventful and the patient was discharged of POD-2 with drain in-situ.

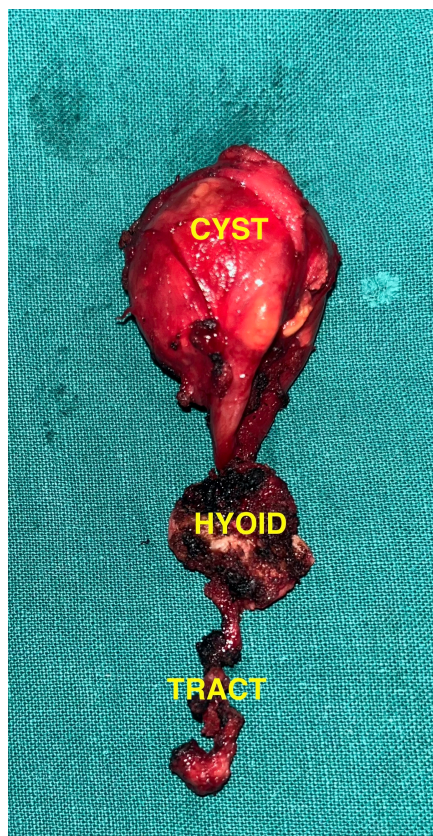


Fig 5. Post operative specimen.

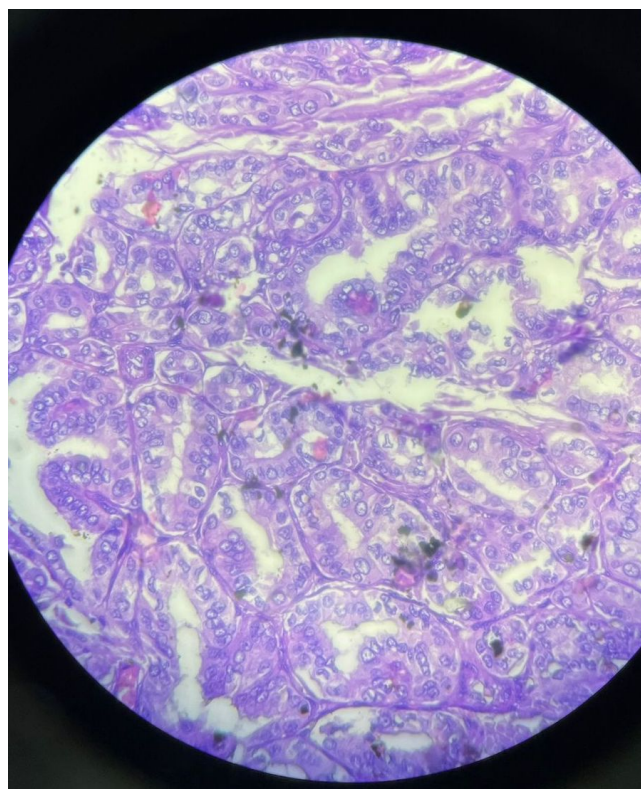


Fig 6. Papillary Fronds with Orphan-Annie Nuclei Noted.

Histopathological examination, on grossing revealed a 2.3x2x2 cm ovoid cystic mass with gray surface with yellowish solid and serous fluid containing cystic fluid, on microscopy a well-differentiated Papillary Thyroid Carcinoma involving the capsule with classical orphan Annie nuclei was noted.

DISCUSSION

Painless anterior midline neck swelling is the most common presentation of Thyroglossal Cyst in adult patients. The presence of other symptoms such as pain, odynophagia, dysphagia, and dyspnoea often indicates the presence of complications such as abscess formation. Location of thyroglossal cyst with respect to hyoid bone can be variable, while midline position is the dominant location in both children and adults, lateral deviation has been noted in adult presentation⁽³⁾. With respect to the hyoid bone, cysts can be above, over, or below the hyoid, most commonly they are infra-hyoid. The surgical management of thyroglossal cyst has changed with time. Earlier Incision & Drainage or simple cyst excision were presented with unacceptably high levels of recurrence, Schlang in 1893, suggested excision of the cyst and mid-portion of the hyoid bone and leaving behind the proximal tract – a technique which resulted in recurrence rates of 30%. In 1920 Walter Ellis Sistrunk reported the classical Sistrunk procedure which significantly improved postoperative outcomes and has since remained the gold standard to date⁽²⁾. Recent advancements such as robot-assisted, endoscope-assisted transoral, axillary & retro-auricular approaches have been attempted for thyroglossal cyst in adults. These procedures are cosmetically superior to the sistrunks operation but data on efficacy being the same are inadequate.

Recurrence is the most important post-op outcome following the Sistrunk procedure, with a recurrence noted in 3%–6% of cases. This is often attributed to technical shortcomings viz. incomplete excision of the duct or the presence

of ramification of ducts, which remain unrecognized at the time of surgery. Most recurrences occur in the first 6 months⁽⁶⁾. Another important possible complication is damage to the 12th Cranial nerve. Meticulous dissection of the central part of hyoid bone and preservation of the Superior Horn of Hyoid bone can help significantly in preventing injuries to the Hypoglossal nerve.

Incidence of Thyroglossal cyst in the adult population is about 7%. Thyroglossal Cyst present with a <1% chance of harbouring a malignant foci in adult population⁽⁷⁾. There are only around 300 cases of Papillary thyroid carcinoma reported in TDC since its first reporting by Brentano in 1911⁽⁷⁾. Most commonly on histopathology we find papillary thyroid carcinoma(90%)⁽⁵⁾. Many treatment options such as Total Thyroidectomy with Bilateral neck dissection , radioactive iodine, thyroid suppression have been suggested. Sistrunks operation is usually considered sufficient and need for further intervention is decided on the basis on the following findings a.) Thyroid nodule (cold) picked up on thyroid scan b.) cervical lymph nodes detected clinically or on imaging c.) prior history of irradiation to the neck. Calcification is the hallmark of papillary carcinoma in a thyroglossal duct cyst⁽⁵⁾. Pre-operative role of FNAC remains uncertain but should be recommended to pick up lesions early and to plan a definitive treatment⁽⁶⁾.**In our patient, since role of FNAC in Thyroglossal cyst is debated & since there was nothing to suggest a malignancy pre-op, an FNAC was not done. Also, no further treatment in the form of thyroidectomy or central neck dissection was not performed as it did not meet the above mentioned criterion.**

CONCLUSION

The rare occurrence of thyroglossal cyst in adults is the reason for the paucity of data in the adult population. The majority of patients are males. Reports in literature, however, do not come to a consensus with some reports

suggesting equal distribution, whilst some suggest male or female preponderance. After lingual thyroid, the Thyroglossal cyst is the second most common site for ectopic thyroid tissue. Incidence of which is approximately 60%. In most of the cases the thyroid gland is normal and the patients are often euthyroid or hypothyroid at presentation. Hence, pre-operative evaluation with a thyroid function test and thyroid scan should be undertaken, prior to its excision, so as to confirm whether the tissue in the cyst is not the only functioning thyroid tissue in the body.

FOLLOW-UP PROTOCOL

In our case, the patient has been advised a yearly follow up with thyroid function tests and USG of neck with thyroglobulin levels as he does not meet the criteria for warranting additional intervention for the papillary thyroid carcinoma.

CONFLICT OF INTEREST

The authors declare that there is no conflict of interest to declare with regards to the publication of this research material.

REFERENCES

1. Dedivitis RA, Guimarães AV (2000). Papillary thyroid carcinoma in thyroglossal duct cyst. *Int Surg*, 85(3): 198–201.
2. Carter Y, Yeutter N, Mazeh H. Thyroglossal duct remnant carcinoma: beyond the Sistrunk procedure. *Surg Oncol*. 2014;23(3):161–166.
3. Weiss SD, Orlich CC (1991). Primary papillary carcinoma of a thyroglossal duct cyst: report of a case and literature review. *Br J Surg*, 78(1): 87–89.
4. Taori K, Rohatgi S, Mahore DM, Dubey J, Saini T (2005).“Papillary carcinoma in a thyroglossal duct cyst” - a case report and review of literature. *Indian J Radiol Imaging*, 15(4): 531–533.
5. Zizic M, Faquin W, Stephen AE, et al. Upper neck papillary thyroid cancer (UPTC): a new proposed term for the composite of thyroglossal duct cyst-associated papillary thyroid cancer, pyramidal lobe papillary thyroid cancer, and Delphian node papillary thyroid cancer metastasis. *Laryngoscope*. 2016;126(7):1709–1714.
6. Rayess HM, Monk I, Svider PF, Gupta A, Raza SN, Lin HS. Thyroglossal duct cyst carcinoma: a systematic review of clinical features and outcomes. *Otolaryngol Head Neck Surg*. 2017;156(5):794–802.
7. Brentano H. Struma aberrata lingual mit druzen metastasen. *Deutsche Medizinische Wochenschrift*. 1911;37:665–666. [[Google Scholar](#)].
8. Plaza CP, Lopez ME, Carrasco CE, Meseguer LM, Perucho Ade L. Management of well-differentiated thyroglossal remnant thyroid carcinoma: time to close the debate? Report of five new cases and proposal of a definitive algorithm for treatment. *Ann Surg Oncol*. 2006;13(5):745–752.