

# Sigmoid Colon Perforation by Foreign Body Insertion

## Abstract

Sigmoid colon perforation caused by foreign body insertion is an uncommon but clinically significant presentation. We present a case of a 38-year-old male farmer who presented with acute abdominal pain and signs of peritonitis resulting from a foreign body-related sigmoid colon perforation. The patient reported progressively worsening abdominal pain, febrile illness, and constipation for four days. Clinical evaluation revealed abdominal rigidity, tenderness, and a dilated rectum with bloody discharge. Imaging studies confirmed pneumoperitoneum, indicative of bowel perforation. During the exploratory laparotomy, an 8cm longitudinal tear was identified on the rectosigmoid junction. Primary repair and diversion ileostomy were performed. Postoperatively, psychiatric consultation revealed rectal insertion of a foreign body to relieve constipation.

**Keywords:** Constipation Relief, Foreign Body Insertion, Sigmoid Colon Perforation

## Introduction

Sigmoid colon perforation is a serious medical condition characterized by the rupture or breach of the sigmoid colon wall, leading to the spillage of fecal matter and bacteria into the abdominal cavity.<sup>[1]</sup> This condition represents a significant surgical emergency that demands immediate intervention to prevent life-threatening complications such as peritonitis, sepsis, and multiple organ failure.

Sigmoid colon perforation is relatively rare, it can arise from various underlying causes, including diverticulitis, colorectal cancer, inflammatory bowel disease, trauma, or rarely by the foreign body.<sup>[2]</sup> In recent years, reports on foreign body perforation of the colon have increased.<sup>[3-5]</sup> Anorectal foreign bodies may be inserted into the rectum for purposes such as sexual eroticism, self-administered treatment of anorectal conditions, alleviating constipation, instances of sexual assault or accidental insertion, and even for illicit drug concealment.<sup>[6-8]</sup> Moreover, in 90.9% of cases involving an anorectal foreign body, the insertion occurred for erotic purposes, while in 9.1% of cases, it was driven by the intention to alleviate constipation.<sup>[9]</sup> The objects introduced into the anus include sex toys, bottles, cans, sticks, jars, pipes, tubes, fruits, vegetables, and stones. Furthermore, patients with impaired judgment, hallucinations, and delusions with psychosis may insert foreign bodies in atypical psychotic states.<sup>[10]</sup>

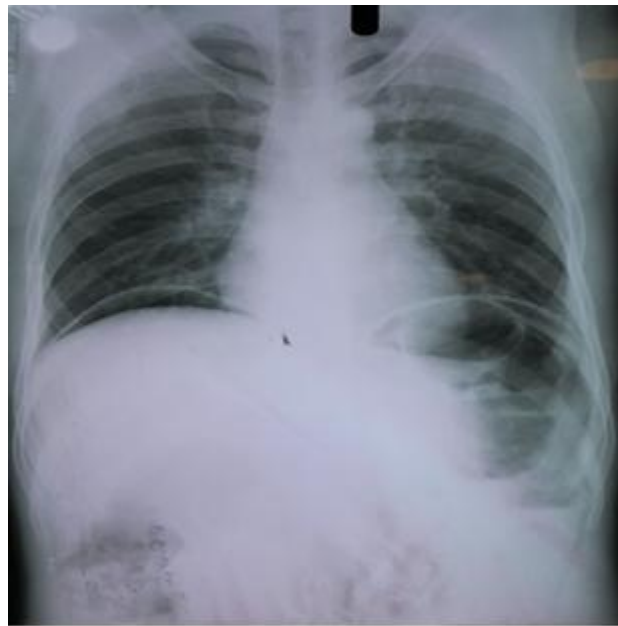Prompt diagnosis and surgical management are paramount to mitigate the associated morbidity and mortality risks. However, reaching a diagnosis and laying out a management plan can be a challenge for emergency physicians and surgeons. The history given is sometimes vague and inconsistent. A high index of suspicion, privacy, broad-minded history taking, physical examination, and choice of investigations are key to finding out the diagnosis and associated complications early.

This case report delves into the clinical presentation, diagnostic evaluation, and surgical intervention of a case of sigmoid colon perforation.

## Case presentation

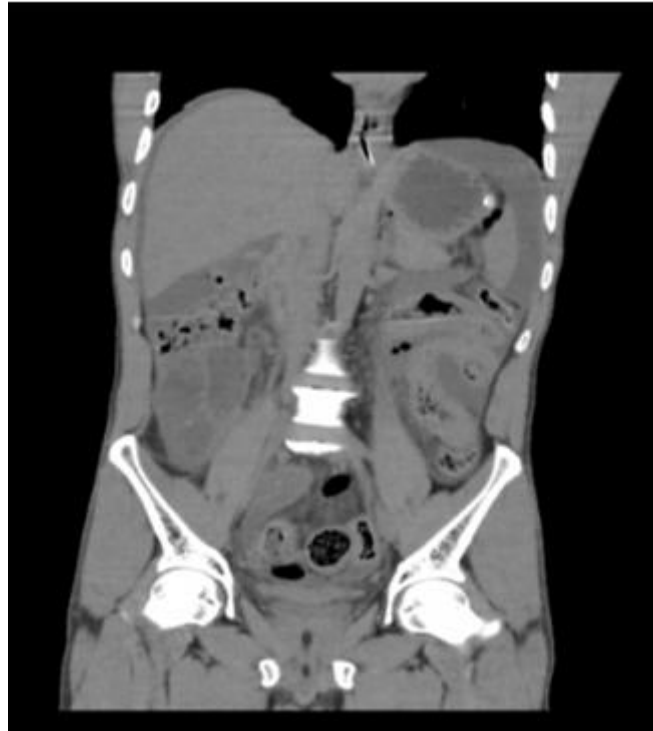**Patient Information:** A 38-year-old male presented to the emergency department with acute, progressive, vague, low-grade abdominal pain that had intensified over the past two days. He had not passed stools for four days and had no history of intestinal obstruction, malignancy, trauma, or previous similar complaints. There was no surgical intervention history.

**Clinical Findings:** Upon examination, the patient was conscious but febrile (temperature 101°F), with a pulse rate of 130 beats/minute, respiratory rate of 31 cycles/minute, and a blood pressure of 102/68 mmHg. Abdominal examination revealed mild distension, rigidity, and diffuse tenderness, with absent bowel sounds, suggesting perforation peritonitis. Per rectal examination showed a dilated rectum with bloody mucous discharge. A chest X-ray indicated gas under the right diaphragm. Abdominal ultrasound revealed peritonitis with pyoperitoneum (Figure 1).



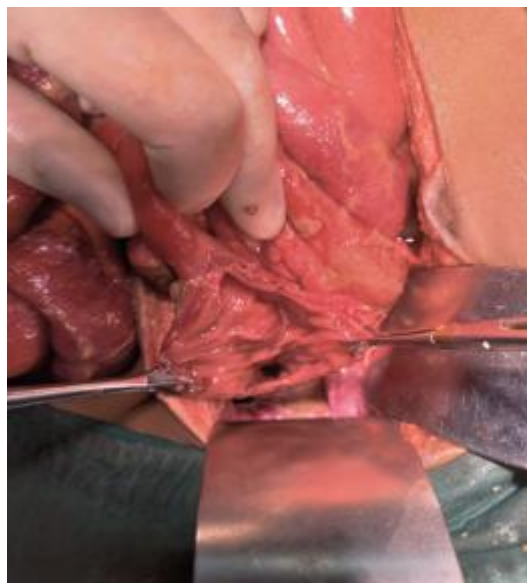
**Figure 1. Chest X-ray indicating gas under the right diaphragm**

**Diagnostic Assessment:** Blood tests showed a decreased white cell count (1820/c mm), a hemoglobin level of 14.4 g/dl, a normal platelet count of 199 x1000/cu mm, and normal liver and kidney function. Non-contrast computed tomography of the abdomen indicated pneumoperitoneum due to hollow viscus perforation, along with proctitis, sigmoid colitis, and enteritis (Figure 2).



**Figure 2. Non-contrast computed tomography showing pneumoperitoneum due to hollow viscus perforation, along with proctitis, sigmoid colitis, and enteritis**

Therapeutic Intervention: The patient received liberal fluid resuscitation and intravenous broad-spectrum antibiotics. Nasogastric aspiration yielded 100 cc of fecal material. An emergency exploratory laparotomy was performed after the site of perforation was not identified by radiological investigations. During the procedure, an 8cm full-thickness longitudinal tear was discovered on the rectosigmoid junction, with oedematous and dilated bowel loops proximal to it (Figure 3). No evidence of mass, fat wrapping, nodularity, or gangrenous intestinal changes was present. Primary repair of the sigmoid colon perforation was performed, and a diversion loop ileostomy was created.



**Figure 3. An intraoperative finding of an 8cm full-thickness longitudinal tear at rectosigmoid junction**

Follow-up and Outcomes: Postoperatively, psychiatric consultation revealed that the patient had inserted a long slender bottle gourd (dudhibhopala) per rectum to relieve constipation two days prior to presentation. The patient underwent psychiatric counselling, and on follow-up, he had no complaints, tolerated a full diet, and had a functional ileostomy with no evidence of electrolyte abnormalities. Ileostomy closure was successfully performed after 3 months.

## Discussion

Among the various etiology of large bowel perforation, it is estimated that less than 1% of inserted foreign bodies cause GI tract perforation.<sup>[11]</sup> The ileocecal and rectosigmoid regions of the large intestine are the most common areas for foreign body-associated complications.<sup>[12]</sup> The reason for the insertion of foreign bodies may be due to sexual gratification or psychiatric conditions or intellectual disability. Individuals experiencing impaired judgment, hallucinations, delusions, and psychosis may insert foreign bodies during episodes of atypical psychotic states.<sup>[13]</sup> Recurring episodes of depression can lead to multiple hospital admissions, often involving the insertion of foreign objects.<sup>[14,15]</sup> Attention-seeking disorders and individuals with factitious disorders may intentionally insert foreign bodies as a means of deception, accompanied by feigned illness and pathological lying.<sup>[16-17]</sup> In adolescents and middle-aged individuals with borderline personality disorders, there may be a motive for secondary gain, such as seeking shelter and evading responsibilities. It's important to note that patients experiencing delirium or dementia may become confused and inadvertently insert FB into the rectum.<sup>[18]</sup> Moreover, individuals with significant distress, anxiety, or compulsion related to their bowel movements or constipation may insert a foreign object.

The majority of cases reported in the literature involve middle-aged males with ages ranging between 20 and 40 years.<sup>[19]</sup> a meta-analysis on colorectal foreign bodies suggested that males were predominantly presented with foreign bodies including bottles, glassware, and sexual behaviour.<sup>[20]</sup> In our case, a 38-year-old male subject had sigmoid colon perforation due to the insertion of a vegetable (long slender bottle gourd) to relieve constipation.

In contemporary medical practice, when there are clinical indications and physical examination findings suggestive of perforated diverticulitis, the standard approach involves employing cross-sectional imaging to validate the diagnosis. Radiological observations may encompass the presence of free air within the abdomen, localized disruptions in the bowel wall, thickening of the bowel wall, signs of inflammation such as fat stranding, leakage of orally administered contrast material, and the identification of intra-abdominal fluid accumulations or abscesses.<sup>[20]</sup> The process of determining the location and reason for perforation on an abdominopelvic CT scan benefits from both contrast-enhanced and non-contrast scans. This approach enables the identification of indirect indicators of bowel perforation, such as irregularities in the bowel wall.

In the case of sigmoid colon perforation, it is crucial to promptly initiate resuscitation with intravenous fluids and administer broad-spectrum antibiotics. On the other hand, the patients who present early, those with minimal trauma, and those with little or no peritoneal contamination can be managed with primary repair and washout. However, the best surgical technique may be chosen based on the surgeon's experience, judgment, and comfort level.

## Conclusion

Sigmoid colon perforation due to foreign body insertion is a rare but serious condition. Timely diagnosis, surgical intervention, and psychiatric assessment are essential for optimal management. This case underscores the importance of considering unusual etiology in cases of bowel perforation, emphasizing the need for a comprehensive approach to diagnosis and treatment in such instances.

## Ethical Approval

As per international standard or university standard written ethical approval has been collected and preserved by the author(s)

## Consent

As per international standard or university standard, participant's written consent has been collected and preserved by the author(s)

## Reference

1. Joglekar S, Rajput I, Kamat S, Downey S. Sigmoid perforation caused by an ingested chicken bone presenting as right iliac fossa pain mimicking appendicitis: a case report. *Journal of medical case reports*. 2009 Dec;3(1):1-3.
2. Khadda S, Yadav AK, Ali A, Parmar A, Beniwal H, Nagar A. A rare case report of sigmoid colon perforation due to accidental swallowing of partial denture. *Indian Journal of Surgery*. 2015 Apr;77:152-4.
3. Alonso-Gómez S, Rubio-González E, Donat-Garrido M, Lomas-Espadas M, Solís-Herruzo JA, Moreno González E. Sigmoid colon perforation due to a foreign body ingestion. *Rev Esp Enferm Dig*. 2012Feb;104(2):90-1.
4. Lim DR, Kuk JC, Kim T, Shin EJ. Surgery for intra-abdominal abscess due to intestinal perforation caused by toothpick ingestion: Two case reports. *Medicine (Baltimore)*. 2019 Sep;98(36):e17032.
5. Morais R, Marques M, Macedo G. Endoscopic treatment of a foreign body-associated colonic perforation. *Int J Colorectal Dis*. 2020 Jan;35(1):165-167.
6. Goldberg JE, Steele SR. Rectal foreign bodies. *SurgClin North Am* 2010;90:173- 84.
7. Koornstra JJ, Weersma RK. Management of rectal foreign bodies: Description of a new technique and clinical practice guidelines. *World J Gastroenterol* 2008;14:4403- 6.
8. Barone JE, Sohn N, Nealon TF Jr. Perforations and foreign bodies of the rectum: Report of 28 cases. *Ann Surg*1976;184:601- 4.
9. Cinar H, Berkesoglu M, Derebey M, Karadeniz E, Yildirim C, Karabulut K, Kesicioglu T, et al Surgical management of anorectal foreign bodies. *Nigerian journal of clinical practice*. 2018 Jun 12;21(6):721-5.
10. Memon JM, Memon NA, Solangi RA, Khatri MK. Rectal foreign bodies. *Gomal J Med Sci* 2008;6:1.
11. Goh BK, Chow PK, Quah HM, Ong HS, Eu KW, Ooi LL, et al. Perforation of the gastrointestinal tract secondary to ingestion of foreign bodies. *World journal of surgery*. 2006 Mar;30:372-7.
12. Kuzmich S, Burke CJ, Harvey CJ, Kuzmich T, Andrews J, Reading N, et al. Perforation of gastrointestinal tract by poorly conspicuous ingested foreign bodies:

- radiological diagnosis. *The British Journal of Radiology*. 2015 Jun;88(1050):20150086.
13. Melamed Y, Dalyahu Y, Vaiman R, Bzura G, Bleich A. Foreign objects in the vagina of a mentally ill woman: case series. *Gen Hosp Psychiatry*. 2007;29(3):270-2.
  14. Forde JC, Casey RG, Grainger R. An unusual penpal: case report and literature review of posterior urethral injuries secondary to foreign body insertion. *Can J Urol*. 2009;16(4):4757-9.
  15. Zafrullah M. Unusual foreign body in the male urinary bladder and urethra. *Br J ClinPract*. 1969;23(3):123-4.
  16. Khan SA, Davey CA, Khan SA, Trigwell PJ, Chintapatla S. Munchausen's syndrome presenting as rectal foreign body insertion: a case report. *Cases J*. 2008;1(243).
  17. Huffman JC, Stern TA. The diagnosis and treatment of Munchausen's syndrome. *Gen Hosp Psychiatry*. 2003;25(5):358-63.
  18. Rada RT, James W. Urethral insertion of foreign bodies. A report of contagious self-mutilation in a maximum-security hospital. *Arch Gen Psychiatry*. 1982;39(4):423-9.
  19. Poylin VY, Opelka FG. Management of rectal foreign bodies. *Fischer's Mastery Surg Sixth Ed*. 2012;1:1-5.
  20. Borofsky S, Taffel M, Khati N, Zeman R, Hill M. The emergency room diagnosis of gastrointestinal tract perforation: the role of CT. *Emergency Radiology*. 2015 Jun;22:315-27.