

EVALUATION OF THE HISTOMORPHOLOGY OF SMALL INTESTINE OF WISTAR RATS EXPOSED TO ELIOZU DUMPSITE LEACHATE

Abstract

This study is aimed to evaluate the histomorphology of small intestine of Wistar rats exposed to ElioZu dumpsite leachate. The toxic effect of ElioZu dumpsite leachate has been studied, where the researcher has identified that the leachate has toxicological effects on some organ tissues like the blood, reproductive tracts and hormones, oxidative stress parameters and the cerebral cortex. Twenty-five female Wistar rats weighing between 120-140 g were obtained from the animal house unit of Faculty of Basic Medical Sciences, University of Port Harcourt, Nigeria. The rats were randomly assigned into five groups of five (5) rats in each group. Group 1 served as a control and orally received 1 ml of bottled water; group 2 orally received 1 ml of water from a borehole close to the dumpsite. Groups 3, 4 and 5 received 1 ml of 10%, 50%, and 100% leachate concentrations orally for 30 days. In the present study, an alteration in the histoarchitecture of the small intestine of the ElioZu dumpsite leachate treated animals was observed; the small intestine of the control group has shown normal intestinal histoarchitecture. The mucosa forms a series of finger-like villi, each showing lamina propria, blood capillaries etc. the simple columnar mucosal epithelium contains absorptive goblets cells, crypts of Liberkuhn in the mucosa and Brunner's glands. It is concluded that exposure to the ElioZu dumpsite leachate and the consumption of the nearby borehole water with significant heavy metals and microorganism have caused the histopathological alterations in gastrointestinal tracts (small intestines) of animals and it is recommend that Government and environmental regulatory agencies find an ecofriendly method to treat ElioZu dumpsite leachate.

Keywords: dumpsite leachate, histoarchitecture of the small intestine, environmental challenge, solid wastes

1.0. INTRODUCTION

Municipal solid waste (MSW) disposal constitutes an environmental challenge globally (Vincenzo *et al.*, 2017). Landfilling and /or open dumping is the preferred method of waste disposal in developing countries due to lack of suitable technology (Vaccari *et al.*, 2012,

Guerrero et al., 2013). This therefore could lead to environmental pollution and health risk to immediate community; because liquid containing significant concentration of undesirable materials may drain from the stock piled materials and contaminate underground water or nearby water sources. The water that drains from the stockpile of dumpsites is regarded as leachate; it may contain toxic compounds that may collate in water bodies and make them toxic to the body when taken [Alam *et al.*, 2008, Al Sabbagh *et al.*, 2012; Chatham-Stephens *et al.*, 2014]. Studies have reported that leachates samples of Aba-Eku landfill in Lagos and Elioizu landfill in Port Harcourt Nigeria, contain heavy metals and microbes [Ogbonna *et al.*, 2016, Weleh *et al.*, 2020]. The earlier study also reported that exposure of drinking water to landfill leachate from a nearby source may cause significant hepatological toxicity in Wistar rats [Weleh *et al.*, 2020]. Also, hematological toxicity has been reported in solid waste workers in Port Harcourt Nigeria; which was attributed to exposure to chemicals in solid wastes [Nwoke *et al.*, 2017]. The hepatotoxic effect of Elioizu dumpsite leachate has been studied, where the researcher deposited that the leachate has toxicological effect on the liver function parameters and the histoarchitecture of the liver (Weleh *et al.*, 2020), further study was reported in a work, where the Elioizu Dumpsite leachate destroyed the histology of the reproductive tract of animals exposed to the leachate. (Green *et al.*, 2022).

Interference with the morphology of the small intestine may lead to several ailments. The biological systems such as the gastrointestinal tract system are affected by environmental factors like pollutants. Some earlier reports stated that exposure to leachate cause a decrease in gonadosomatic index value and shrinking oocyte diameter of female Nile *Tilapia* (Zulfahmi *et al.*, 2019). There is however scanty literature on the effect of Elioizu dumpsite leachate on the histomorphology of small intestine; hence, the need for this study that is aimed at evaluating the histomorphology of small intestine exposed to Elioizu dumpsite leachate using Wistar rats as experimental model.

2.0. MATERIALS AND METHODS

Collection of Leachate Raw fluids was done from Elioizu dumpsite in Obio/Akpor, Nigeria. The leachate sample was taken to the laboratory in clean and dry plastic containers, where it was filtered using Whatmann No. 42 filter paper to remove suspended particles. The filtrate was centrifuged at 3000 rpm using Techmel and Techmel USA (model: 80-2) for 10 minutes and the

supernatant fluid obtained was considered as stock samples (100%) and labeled as Eliozi dumpsite leachate (EDL) and stored at 4°C. The following concentrations were thus determined, 10 %, 50 % by dilution of the leachate with distilled water.

2.1. Experimental Animals

Twenty-five female Wistar rats weighing between 120-140 g were obtained from the animal house unit of Faculty of Basic Medical Sciences, University of Port Harcourt, Nigeria. The animals were acclimatized for 14 days under standard laboratory conditions of 12- hour dark and light cycle with free access to drinking water and standard rodent chow ad libitum. The animals were treated according to the guide for the Care and use of laboratory animals

2.2. Experimental Design

The rats were randomly assigned into five groups of five (5) rats in each group. Group 1: served as a control and orally received 1 ml of bottled water, group 2: Orally received 1 ml of water from a borehole close to the dumpsite. Groups 3, 4 and 5 received 1 ml of 10%, 50%, and 100% leachate concentrations orally for 30 days. At the end of the leachate administration, the rats were anaesthetized using chloroform vapor and small intestine immediately collected for both histology and histochemical assays.

2.3. Histopathological Examination

Small intestines were harvested and processed for histological and histochemical analysis, the processed organs from all groups were fixed in 10 % formaldehyde, the tissue processing was done using routine paraffin wax processing technique and the prepared 5 μ thick section were mounted on slides and stained with Hematoxylin and Eosin (H&E). Alcian Blue special stain was used for histochemistry, its principle is to differentiate between neutral and acidic mucosubstances, probably the best pan-mucin stain available and the slides were evaluated by a consultant pathologist.

3.0. Results

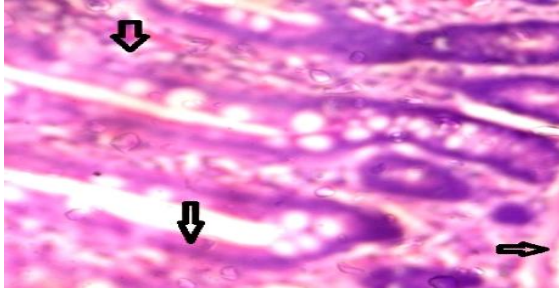


Plate 1: Mag X400 H&E

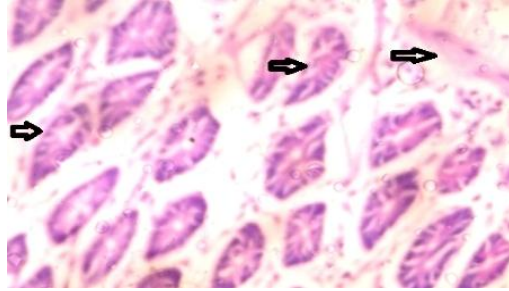


Plate 2: Mag X400 H&E

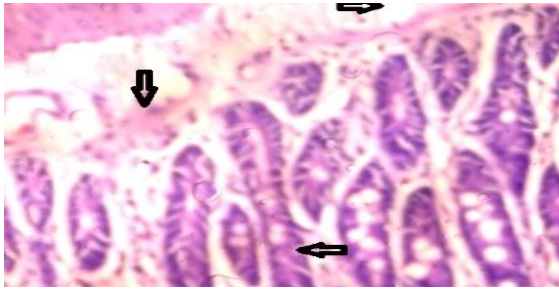


Plate 3: Mag X400 H&E

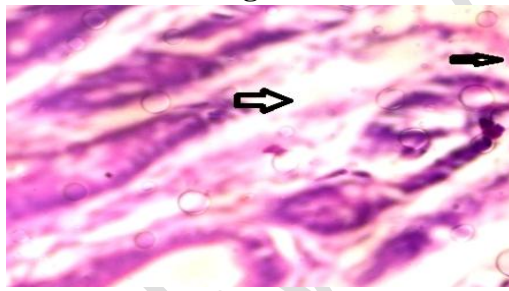


Plate 4: Mag X400 H&E

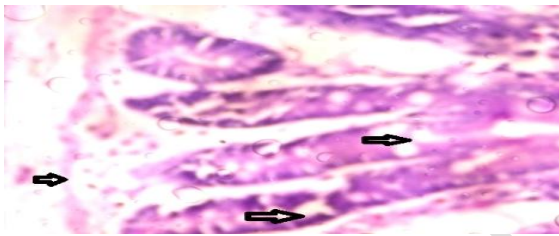


Plate 5: Mag X400 H&E

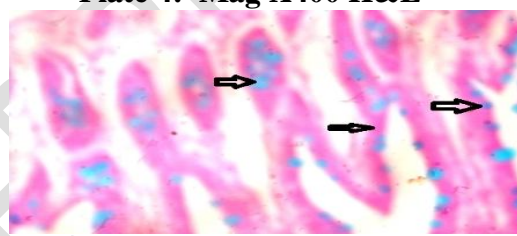


Plate 6: Mag X400 H&E

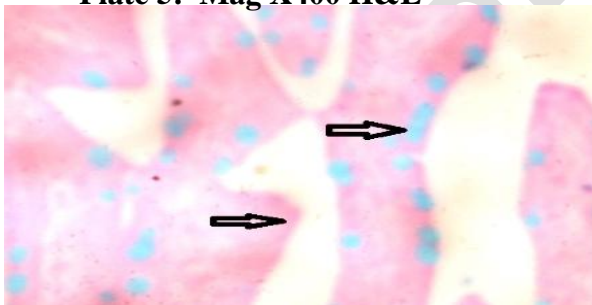


Plate 7: Mag X400 H&E



Plate 8: Mag X400 H&E

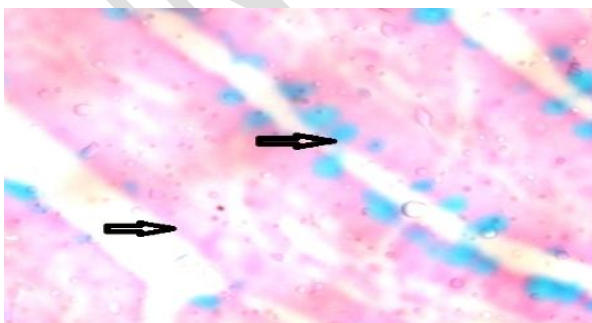


Plate 9: Mag X400 H&E

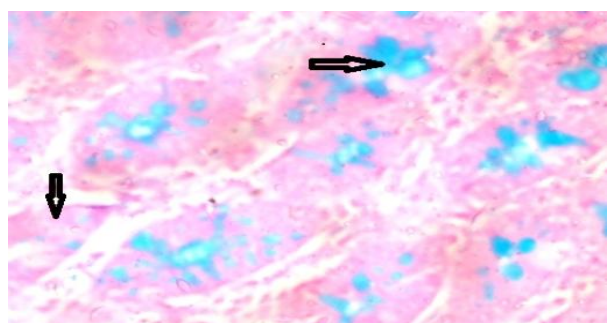


Plate 10: Mag X400 H&E

Plate 1 shows the photomicrograph of small intestine stained with H&E, from animals in group 1 (control), bottle water manifesting normal histology of small intestine with villi, goblet cells and glands. Plate 2 also shows photomicrograph of small intestine stained with H&E from animals in group 2 (borehole water 1 km from the dumpsite) manifesting histologically distorted small intestine with disrupted muscular mucosa and villi. Plates 3, 4, and 5, show photomicrograph of H&E stained small intestine in group of animals exposed to 10 %, 50 % and 100 % concentrations of Elioazu dumpsite leachate manifesting serious disruption of the histology of small intestine when compared with control group. They show disrupted muscular mucosa, vacuolations in the submucosa. Plate 6 shows photomicrograph of small intestine stained with Alcian Blue 2.5 animals from group 1 (control) commercial bottle water manifesting histochemically normal small intestine with mucopolysaccharides and acidic mucins, goblet cells show blue, acid mucin blue, cytoplasm shows pink coloration. Plate 7 also shows photomicrograph of Alcian Blue 2.5 stained small intestine of animals in group 2 (borehole water 1 km from dumpsite) manifesting mildly enlarged goblet cells with blue color and reduced pink coloration of the cytoplasm an indication of disrupted small intestine. Plates 8, 9 and 10 also show the photomicrograph of Alcian Blue 2.5 stained small intestine of animals exposed to 10 %, 50 % and 100 % concentrations of Elioazu Dumpsite Leachate manifesting damaged small intestine with enlarged goblet cells blue color, reduced coloration of pink in the cytoplasm.

4.0. DISCUSSION

The municipal solid waste (MSW) final disposal represents an environmental challenge globally (Vincenzo *et al.*, 2016) since landfilling and or open dumping is still most preferred solution. In developing countries (Vacearo *et al.*, 2012, Guerrero *et al.*, 2013), lack of suitable technological choices means environmental pollution and risk for health of population due to the exposure to toxic compounds caused by the release of leachate (Chathan *et al.*, 2014). Dump sites in developing and emerging countries suffer from the lack of leachate treatment and caption facilities; causing the contamination of water bodies and soil and threatening human health. (Alam *et al.*, 2008, Al Sabbagh *et al.*, 2012).

The paucity of data on waste generation and its effect on health environment around Port Harcourt metropolis continue to be a pivotal problem thus inhibiting exact regulation. There is very little known about leachates in Port Harcourt, so efforts to put exposure levels to protect humans often prove very ineffective. Worthy of note is that pollution decreases the quality of life

in different area and affects health and life span (Grover and Kaur, 1999). After analysis of the basic properties and chemical composition of leachates in Port Harcourt Elioazu dumpsite, it shows that landfill leachate is a mixture and contains varieties of contaminants; there are general underlying pollutants common to all landfill effluents (Anshu and Poulrag, 2015).

In the present study, we observed alteration in the histoarchitecture of the small intestine of the Elioazu dumpsite leachate treated animals, the small intestine of the control group has shown normal intestinal histoarchitecture. The mucosa forms a series of finger-like villi, each showing lamina propria, blood capillaries etc. the simple columnar mucosal epithelium contains absorptive goblets cells, crypts of Liberkuhn in the mucosa and Brunner's glands. Distortions of the villi were also prominent in leachate treated animals, absorptive goblet cells and columnar epithelium including cytoplasmic disruption leading to formation of mucous vacuoles.

There have been scanty reports on the alterations of the cellular architecture in the small intestine of animals in response to leachate toxicity. We observed in this study that oral administration of EDL resulted in significant histopathological abnormalities in the small intestine as evident by atrophy musculature, disintegration of sub-mucosal and connective tissue and disruption of serosa to different extent. The mucosa epithelium cells showed cytoplasmic vacuolization, necrotic nuclei indicated by clumped nuclear material and nuclear pycnosis, this is similar with earlier report that leachates disrupt kidney and liver function (Alimba *et al.*, 2012). It is similar with another finding that stated that aluminum chloride exposure was detrimental to the histology of small intestine (Buraimoh, 2012), it is also similar with the report that Aluminum chloride exposure was detrimental to the histology of the kidney of wistar rats (Buraimoh and Ojo, 2012).

Histochemically, the goblet cells of the control group stained positive with the Alcian Blue (pH 2.5) stain, with blue coloration. This is an indicator for sulfated mucin substance which are very important in digestion and subsequent absorption, this comply with an earlier report on the histology and histochemistry study of the small intestine of the striated scope Owl (*Otus Scors Brucei*) (Saffer *et al.*, 2016).

In this study, we observed abnormal mucus deposition in the enlarged goblet cells in the intestine of the EDL-treated animals this could be as a result of a proposed mechanism earlier (Zhang and

Wang, 1984), that the alteration could be disturbances in lipid inclusions and fat metabolism in response to toxic substances resulting in cytoplasmic vacuolization. This is also similar with an earlier report (Animesh *et al.*, 2009).

4.1. Possible mechanism of action of some heavy metals in Elioizu dumpsite leachate

The mechanisms of some heavy metals' toxicity are established. Lead toxicity occurs due to the ability of lead (Pb) metal ions to replace other bivalent cations such as Calcium ions (Ca^{2+}) Magnesium ion (Mg^{2+}), ferrous ion (Fe^{2+}) and monovalent cations like sodium ion (Na^+), which ultimately disturbs biological metabolism of the cell. These ionic mechanisms cause significant alterations in biological processes such as adhesion, intra and extracellular signaling, protein folding, maturation, apoptosis, ionic transportation, enzyme regulation and release of neurotransmitters this is similar with a mechanism proposed earlier (Flora *et al.*, 2008).

Mercury can cause disruption of membrane potential, interrupt intracellular calcium homeostasis, damage the tertiary and quaternary protein structure and alter cellular function. It can also intervene with the process transcription and translation, resulting in the disappearance of ribosomes and the eradication of endoplasmic reticulum and the activity of natural killer cells. Cellular integrity is also affected, causing free radical formation (Bernhoft, 2012; Jaishanker *et al.*, 2017).

5.0. Conclusion

From the study, we conclude that exposure to the Elioizu dumpsite leachate and the consumption of the nearby borehole water with significant heavy metals and microorganism have caused the histopathological alterations in gastrointestinal tracts (small intestines) of animals and we recommend that **Government and environmental regulatory agencies attempt an ecofriendly approach in treating Elioizu dumpsite leachate.**

Ethical Approval

The ethical approval for this work was sought from the University Ethical committee and an approval was gotten with reference number UPH/R&D/REC/04.

REFERENCES

1. Vincenzo Torretta, Navarro Ferronata, Ioannis A. Katsoyiannis, Anthanasia K. Tolkou, Michela Airoidi (2017). Novel and conventional technologies for landfill leachates treatment. *A Reviewed sustainability* 9(9):8-39.
2. Vaccari M, Torretta V, Collivignarelli C (2012). Effect of improving environmental sustainability in developing countries by upgrading solid waste management techniques: A case study. *Sustainability* 4:2852–2861.
3. Guerrero LA, Maas G, Hogland W (2013) Solid waste management challenges for cities in developing countries. *Waste Management* 33:220–232.
4. Chatham-Stephens K, Caravanos J, Ericson B, Landrigan P, Fuller R (2014). The pediatric burden of disease from lead exposure at toxic waste sites in low- and middle-income countries. *Environmental Research*.132:379–383.
5. Alam R, Chowdhury MAI, Hasan GMJ, Karanjit B, Shrestha LR (2008). Generation, storage, collection and transportation of municipal solid waste: A case study in the city of Kathmandu capital of Nepal, *Waste Management Research*. 28:1088–1097.
6. Al Sabbagh MK, Velis CA, Wilson DC, Cheeseman CR (2012). Resource management performance in Bahrain: A systematic analysis of municipal waste management, secondary material flows and organizational aspects, *Waste Management Research*. 30:813–824.
7. Ogbonna VA, Nwankwoala HO, Lawal O.(2016). Impacts of landfill on groundwater quality in Eligbolo-Eliozu, Obio/Akpor, Local Government Area, Rivers State, Nigeria. *African Journal of Basic and Applied Sciences* 8(4):232-239.
8. Iyke I. Weleh, Owunari A. Georgewill Victor D. Dapper (2020). Effect of Port Harcourt (Eliozu) landfill leachates on oxidative stress using oxidative stress markers in Wistar rats. *Journal of Environmental Science, Toxicology and Food Technology (IOSR-JESTFT)*. 14(4):01-04.
9. Nwoke K.U, Ezeh N.P, Adienbo O.M (2017).Some occupations and their effects on hematological parameters of exposed individuals in Port Harcourt, Nigeria. *International Journal of Science and Research Methodology* 8(2):50-57.

10. Robert M Beme, Mathew N. Levy. Physiology, (3rd edition). A mosby imprint of mosby year Book, Inc. 1993: 897-899.
11. Muliari Muliari, Ilham Zulfahmi, Yusrizal Akmal, Ni Wayan Kurniani Karja, Chairun Nisa, Kizar Ahmed Sumon (2019). Effects of palm oil mill effluent on reproductive hormone of female Nile tilapia, *Oreochromis niloticus* (Linnaeus). *Advances in animal and veterinary Sciences*. 11(7):1035- 1041.
12. Zulfahmi I, Ridwan A, Djamar TFL (2019). Perubahan struktur histologis insang dan ikan nila (*Oreochromis niloticus* Linnaeus 1758) yang terpapar merkuri [Histological changes of liver and gill of Nile Tilapia (*Oreochromis niloticus* Linnaeus 1758) after mercury exposure]. *Journal of Edukasi dan Sains Biology* 4(1):31-35.
13. Alimba CG, Bakere AA, Aina OO (2012). Liver and kidney dysfunction in Wistar rats exposed to municipal landfill leachate. *Scientific Academic publish* 2 (4) 150-163.
14. Bernthoft RA. (2012). Mercury toxicity treatment: A review of the literature. *Journal of Environmental Public Health* (cited 2017). Available at <http://www.ncbi.nlm/pmc>.
15. Chatham-Stephens, K.; Caravanos, J.; Ericson, B, Landrigan, P, Fuller, R (2014). The pediatric burden of disease from lead exposure at toxic waste sites in low and middle income countries. *Environmental Research*, 132, 379–383.
16. Flora SJS, Mittal M, Mehta A (2008). Heavy metals induced oxidative stress and its possible reversal by chelation therapy. *Indian Journal of Medical Research*. 128: 501-523.
17. Jaishankar.M, Tseten.T, Anbalagan.N, Mathew.BB, Beeregowda.KN (2014). Toxicity mechanism and health effects of some heavy metals. *Interdisciplinary toxicology*: 7 (2): 60-72.
18. Zhang.LY and Wang CX (1984). Histopathology and Histochemical studies on toxic effect of brodifacoum in mouse liver. *Acta Academic Medical Sciences*. 6 (5): 386-388.
19. Anshu Gupta, Paulraj (2015). Toxicity Assessment of municipal solid waste landfill leachate collected in different seasons from Okhala landfill site of Delhi. *Journal of Biomedical Sciences and Engineering* 8: 357-369.
20. Animesh K. Mohapatra, Poonam Kumari and Shirika Datta (2009). Cadmium induced histopathological changes in the Stomach and Small intestine of Swiss Albino Mice (*Mus Musculus*). *Journal of Applied and Natural Science* 1 (2):253-257.
21. Buraimoh AA, Ojo SA (2012). Effects of Aluminium Chloride Exposure on the histology of small intestine of Wistar rats. *International Journal of Applied Science and Technology* Volume 2 (10):123-132.

UNDER PEER REVIEW